

# A duplicated spinous process of the C7 vertebra

Srijit Das, Rajesh Suri, Vijay Kapur

*Department of Anatomy, Maulana Azad Medical College, Bahadur Shah Zafar Marg, New Delhi, India*

[Received 27 December 2005; Revised 19 April 2005; Accepted 19 April 2005]

*Normally the 7th cervical vertebra (C7) has a long non-bifid spine. A bifid spine is a feature of typical cervical vertebrae such as C3–C6. In contrast to past studies, which have described a bifid spine in the C3–C6 cervical vertebrae, this study is a report on the presence of a duplicated spinous process in the C7 vertebra with an intervening space. The presence of such anomalies may be associated with other congenital anomalies and needs a careful and thorough clinical approach. This is an extremely rare finding which may be of clinical interest to radiologists, neurologists, orthopaedic surgeons, anthropologists and forensic personnel. The present case report describes the anatomical details in the bone specimen along with its radiological picture in a case of a duplicated spinous process of the C7 vertebra.*

**Key words:** vertebra prominens, duplicated spinous process, anomaly, spine

## INTRODUCTION

The C7 vertebra is described as an atypical vertebra in the classical textbook of anatomy [7]. It has a long spinous process ending in a prominent tubercle [7]. This spinous process gives attachment to the *ligamentum nuchae* and the deep extensors [7]. A bifid spinous process is a feature of a typical cervical vertebra such as C3–C6.

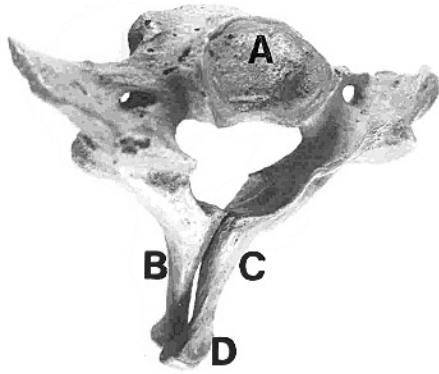
It has been rare for past research studies to report bifid spinous processes in the C7 vertebra. An exception is a single study which reports a non-bifid spinous process in 98% of cases [3]. The present study reports a duplicated spinous process in which the right spine over-rides the left with an intervening space. To the best of our knowledge, only one previous study has reported a duplicated spine of the C7 vertebra [4].

Congenital anomalies such as dermal sinuses and bony deformities are reported to be associated with bifid spinous processes [1]. The presence of a dupli-

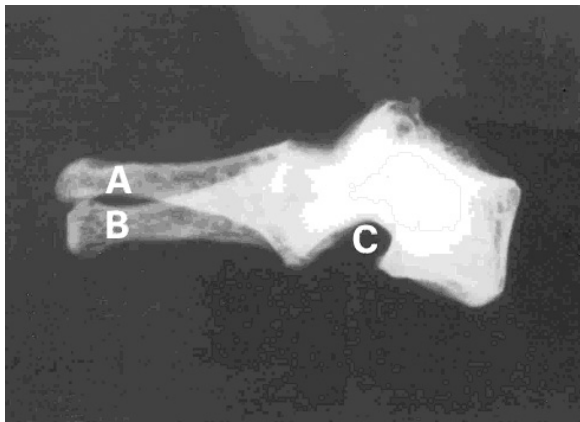
cated spinous process may be important for radiologists, neurologists and orthopaedists in day-to-day clinical practice. Such anomalies are also important for forensic and anthropological studies [3]. Among anatomists the topographical and radiological anatomy of a duplicated spinous process of the C7 vertebra is a subject of debate.

## CASE REPORT

During routine osteology teaching of undergraduate medical students in the Department of Anatomy, we noticed duplication of the spinous process of the C7 vertebra. The two spinous processes were completely separate, with the right one over-riding the left. The term “duplicated spinous process” would thus appear to be justified. There was an intervening gap between the two spinous processes. Both the spinous processes ended posteriorly in tubercles. The bone specimen was studied in detail, photographed and a skiagram was taken (Fig. 1, 2).



**Figure 1.** Photograph showing the anomalous C7 vertebra (superior view); A — superior surface of the body; B, C — duplicated spinous processes; D — extra facet on the superior surface of the spinous process of the right side.



**Figure 2.** Skiagram of the C7 vertebra (lateral view) showing; A, B — duplicated spinous process; C — inferior vertebral notch.

The length of the right and left spinous processes measured 3.4 cm and 3.3 cm respectively (Fig. 1). The *foramina transversaria* (FT) on either side were unequal in size. The antero-posterior diameters of the FT measured 0.4 cm and 0.3 cm on the right and left sides respectively. The transverse diameters of the FT measured 0.5 cm and 0.4 cm on the right and left sides respectively. The antero-posterior measurements of the superior articular facet were found to be 1 cm and 0.9 cm on the right and left sides respectively. The same measurement of the inferior articular facet was 0.7 cm on both sides. The superior aspect of the right spinous process near its posterior extremity displayed a distinct facet. No other abnormalities were seen.

## DISCUSSION

A spine is referred to as a bifid spine if it is split into two at the tip. A bifid spine is a feature of cer-

tain of the cervical vertebrae [7] and is rarely found in the C7 vertebra. Only one past research study has reported the presence of a bifid spine (only in 2% cases) in the C7 vertebra [3]. However, the present study reports another morphological variant in the form of duplication of the spinous process. This finding is extremely rare, having only once been reported in an isolated radiological study [4]. From an anatomist's point of view, the presence of a duplicated spinous process would not appear to accommodate to the classical description of a typical or atypical cervical vertebra.

The present study also highlights the difference in the size of the FT and superior articular facets on the right and left sides respectively. Interestingly, the right spine over-rode the left one with an intervening gap. This gap can be well appreciated in the skiagram (Fig. 2). The presence of a duplicated spine may be misinterpreted in radiological studies and may be responsible for erroneous counting of cervical spines in a skiagram. Such a finding represents a riddle for radiologists as well as for orthopaedists.

The spine develops from neural arches and at birth the two halves of the neural arches are joined by cartilage [7]. There is one primary centre for each neural arch. The bifid spinous process has been described as developing as a result of two ossification centres [7]. Past research studies have reported the incidence of bifid spinous processes as being higher in fetuses than in adults in European and Native Africans [5]. It is a known fact that the presence of bifid spinous processes is associated with racial origin [3]. The identity of an individual may be traced by the presence of such an anomaly and thus this feature may be important for forensic and anthropological studies [3].

The spinous process provides attachment to the *ligamentum nuchae* and other extensor muscles [3, 7]. When the presence of a duplicated spine is considered, the possibility arises that there has been an alteration in the functional anatomy of these extensor muscles. The movements of the vertebral column are liable to be affected. The neurological and vascular systems may be involved, resulting in clinical symptoms. The spinal nerves may be compressed, causing associated neuropathy, although *spina bifida occulta* is frequently asymptomatic. There is also the possibility of the curvature of the vertebral column being altered in the presence of such an anomaly. Admittedly, because the history of the individual was

not available in the present case, it is not possible to comment upon the clinical profile resulting from the anomaly.

There have been past research reports of dorsal dermal sinuses with *spina bifida* and a laminar groove on the upper spinous process [1, 2, 6, 8]. The presence of a duplicated spinous process needs careful clinical investigation to rule out any other associated abnormality. Radiological techniques, such as X-ray, CT and MRI studies, have a key role in diagnosis.

As anatomists, we suggest that in dealing with abnormalities involving the C7 vertebra the possibility of anomalies such as the presence of a duplicated spine should always be considered and the treatment planned accordingly. This, then, may be considered our modest contribution towards creating awareness of this interesting anomaly, which may be important for radiologists, orthopaedic surgeons and neurologists.

## REFERENCES

1. Aydin K, Sencer S, Minareci O (2001) Thoracocervical dorsal dermal sinus associated with multiple vertebral body anomalies. *Neuroradiology*, 43: 1084–1086.
2. Barkovich AJ (1995) Pediatric neuroimaging In: Barkovich AJ (ed.) *Congenital anomalies of the spine*. Raven, New York, pp. 477–540.
3. Duray SM, Morter HB, Smith FJ (1999) Morphological variation in cervical spinous processes: potential applications in the forensic identification of race from the skeleton. *J Forensic Sci*, 44: 937–944.
4. Keats TE, Anderson MW (2001) *Atlas of normal roentgen variants that may simulate disease*. Mosby Inc, St. Louis, p. 270.
5. Shore LR (1931) A report on the spinous processes of the cervical vertebrae in the native races of South Africa. *J Anat*, 65: 482–505.
6. Smoker WRK (1995) Congenital anomalies of the cervical spine. *Neuroimaging Clin N Am*, 5: 427–449.
7. Standring S (2005) *Gray's anatomy*. 39<sup>th</sup> Ed. Elsevier Churchill Livingstone, New York, pp. 742–746.
8. Wright RL (1971) Congenital dermal sinuses. *Prog Neurol Surg*, 4: 175–191.