

An asymmetrical inferior articular process of a lumbar vertebra

S. Das, R. Suri, V. Kapur

Department of Anatomy, Maulana Azad Medical College, New Delhi, India

[Received 5 September 2005; Revised 8 December 2005; Accepted 8 December 2005]

The present case report describes the topographical anatomy and radiological study of an asymmetrical inferior articular process of a lumbar vertebra, which was detected during routine osteology teaching of undergraduate medical students. The inferior articular process of the lumbar vertebra on the left side was rudimentary, while that on the right was normal in size. On the left side an additional bony projection was noted anterior to the rudimentary inferior articular process. The difference in height between the inferior articular processes of the two sides may play an important role in the kinematics of the particular joint. The orientation of the facets of the articular processes of the vertebrae are important for axial weight transmission and anomalies involving these can possibly alter the orientation of movements in that particular segment. An asymmetrical inferior articular process may be related to disc prolapse and may be a cause of back pain. In view of the paucity of research reports of anatomicoradiological study of the inferior articular process of a lumbar vertebra in relation to other parts of the vertebra, we, as anatomists, believe that knowledge of anomalies of the inferior articular process may be relevant for academic, anthropological and clinical purposes.

Key words: anomaly, variations, rudimentary, asymmetry, inferior articular process, lumbar, vertebra

INTRODUCTION

The lower lumbar region has gained special relevance because of the increase in the number of spinal injuries and because of the disc degeneration that occurs in this region [12]. The morphology of the facet joints in the vertebrae may be responsible for causing degenerative spondylolisthesis and instability [2, 6, 8, 13]. It has been observed that compressional, tensional and axial bending forces are responsible for producing the effects of disc failure in the lumbar vertebrae [4, 15, 19]. Interestingly, past experimental studies have shown that by applying a posteriorly directed force to the inferior articular process, fractures resembling spondylolysis can be produced [5, 7].

Studies have been performed on the various parts of the lumbar vertebrae but the superior articular process has received the greatest attention from researchers because it is mounted on a much larger and more massive area formed by the pedicles, partes interarticulares and lateral cephalad parts of the laminae and creating a larger functional unit which guides and limits the movement of a particular segment [18]. The caudal portion of the lamina is the sole buttress for the inferior articular processes and the importance of this in weight transmission cannot be forgotten [18].

The aim of the present study is to report anatomical observations on an anomalous rudimentary inferior articular process of a lumbar vertebra and to discuss its clinical implications.

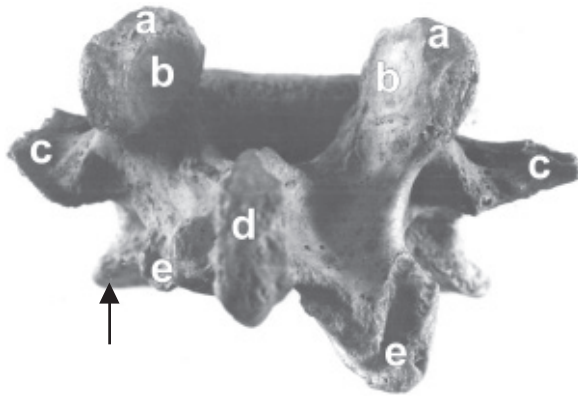


Figure 1. Photograph of lumbar vertebra (posterior view) showing: a — superior articular process on both sides; b — superior articular facets on both sides; c — transverse process on both sides; d — spine; e — inferior articular process on both sides; The rudimentary inferior articular process on the left side is shown with an arrow.

CASE REPORT

During routine osteology teaching in the Department of Anatomy we detected an anomalous lumbar vertebra with a unilateral rudimentary inferior articular process. The bone specimen was studied in detail and the anatomical details were observed. Morphometric observations of various parts of the vertebra were recorded. The specimen was photographed (Figs. 1, 2) and a radiograph was also obtained (Fig. 3).

Observations

Superior articular process. The distance between the anterior ends of the two superior articular processes measured 2.5 cm. The maximum anteroposterior measurement of the superior articular processes was 2 cm on both the left and right sides.

Inferior articular process. The lumbar vertebra had a rudimentary inferior articular process on the left side. The maximum vertical measurements of the inferior articular processes were 0.9 cm and 1.5 cm on the left side and the right side respectively. The inferior articular processes were located at distances of 1.5 cm and 1.9 cm from the spine on the left side and right side respectively. A tubercle measuring 0.6 cm transversely was noted at a distance of 1 cm posterior to the rudimentary inferior articular process on the left side (Fig. 2)

Transverse process. The transverse process was blunt on the left side and pointed on the right. In width it measured 1.4 cm and 1.8 cm on the left side and right side respectively.

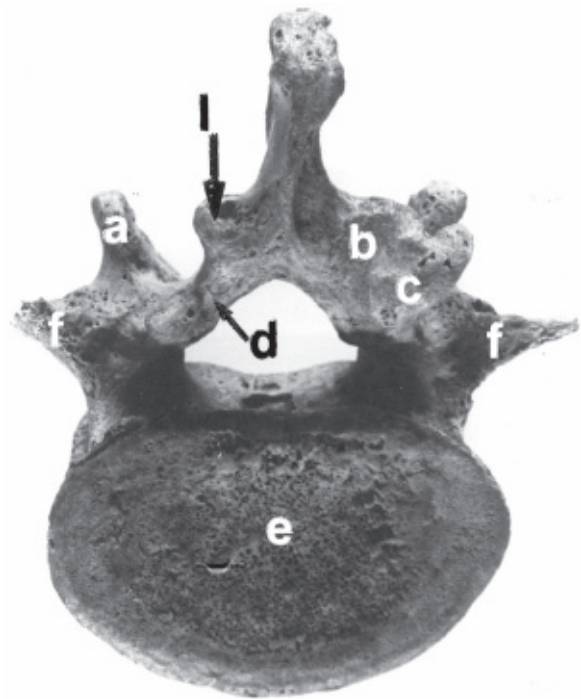


Figure 2. Photograph of lumbar vertebra (inferior view) showing: a — superior articular process on both sides; b — inferior articular process on the right side; c — inferior articular facet on the right side; d — additional tubercle on the left side; e — body of the vertebra; f — transverse process on the both sides; s — spine; l — rudimentary inferior articular process on left side.

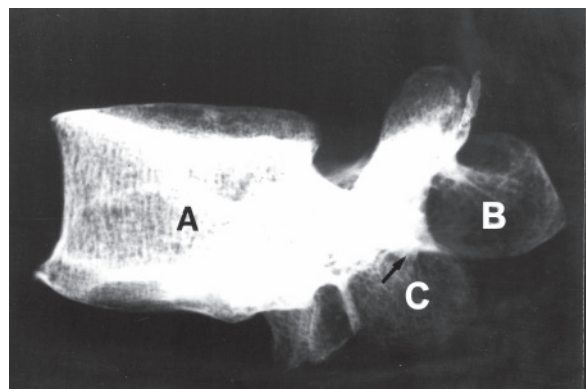


Figure 3. Radiograph of lumbar vertebra showing: A — body of the vertebra; B — spine; C — rudimentary inferior articular process on the left side marked with arrow.

Spine. The spine measured 2 cm vertically. A facet was noticed on the left side of the spine.

No other abnormalities were observed.

DISCUSSION

In the present study the anteroposterior measurement of the superior articular facet, the height of the inferior articular facet and the distance of the

inferior articular process from the spine were found to be significantly smaller on the left side than on the right side of the vertebra. Interestingly, an additional tubercle (Fig. 2) near the inferior articular process was noted only on the left side. These findings clearly suggest the possibility of a developmental defect in the lumbar vertebra. Unfortunately, no clinical history of the patient was available to substantiate these findings. The developmental defect of the inferior articular process in the present case may be related to the neural arch from which this part of the vertebra develops [16]. The radiograph obtained in this case (Fig. 3) did not show any features of injury.

Past research studies have found that the inferior articular processes of a vertebra are attached anterolaterally to the caudal portion of the lamina and that the lamina is the only connection between the inferior articular process and the rest of the vertebra [9]. The inferior articular processes and the caudal portion of the laminae when articulating with the superior articular processes of the lower vertebra form a structural and functional unit and this unit plays an important role in the motion of one particular segment [20]. The caudal portion of the vertebra has been considered to act as a buttress for the inferior articular processes [9]. Any difference in height of the inferior articular processes on the two sides leads to a position of inclination and disability. In the present case the rudimentary inferior articular process on the left side can also be associated with disc herniation.

Lumbar zygapophyseal joints have been found to restrict rotation and excessive flexion [17]. Such movements are likely to be affected in the present scenario, where the inferior articulating surfaces are unequal. As the present study is a case report, further studies are needed to corroborate this important aspect.

It has been reported that there is a significant association between the sagittal orientation of the lumbar facet joint and osteoarthritis [10]. Thus the orientation of the lumbar facet joint has important clinical implications.

The bony facet joints and their capsular soft tissues contribute to spinal stability in the lumbar region [11]. Stability in the region of the anomalous vertebra may have been altered as a result of the asymmetrical inferior articular process, thereby causing discomfort to the individual.

The significance of asymmetrical posterior facets (articular tropism) in the pathogenesis of low back pain and sciatica was first described by Putti in 1927 [14].

In an earlier roentgenogram study of the lumbosacral spine 69% of the lumbosacral facets were symmetrically oriented, 57% were obliquely oriented, 12% were vertically oriented and 31% had asymmetrical orientation [3]. In another study, a variation of 19–87% and 17–90% in the orientation of lumbosacral to the sagittal plane were found on the left and the right sides respectively [1]. A radiographic study of the lumbosacral spine in 200 individuals with back pain reported an overall joint symmetry at each of the lower three lumbar levels in 23% of the patients [8]. A high correlation has been found between the asymmetrical orientation of the facet joints and the degree of disc pathology [8]. Intervertebral joint instability is related to facet orientation [8].

In the region of the inferior articular process the multifidus muscle is attached. The attachment of this muscle may have been altered in the present case, causing resultant symptoms. The attachment of the ligamentum flava may also have been altered, thereby having an effect on extension movement.

The superior articular processes are sometimes said to be “naked” because their inferior facet counterparts are not visible in CT scans. This is termed as the “naked facet sign” [11]. Thus anatomical knowledge of the naked facet sign is important in diagnosing the CT scan of lumbar injuries. As anatomists, we hold the opinion that the inferior articular process has an important role to play in the kinematics of the joint and may be related to disorders of the spine. The present case report is a modest attempt to highlight this and further studies on the inferior articular facets may be beneficial. Anatomical knowledge of anomalies of the inferior articular process of the lumbar vertebrae may be interesting from both an academic and a clinical point of view.

REFERENCES

1. Badgley CE (1941) The articular facets in relation to low back pain and sciatic radiation. *J Bone J Surg*, 23: 481.
2. Boden SD, Riew KD, Yamaguchi K (1996) Orientation of the lumbar facet joints: association with degenerative disc disease. *J Bone J Surg*, 78: 403–411.
3. Brailsford JF (1929) Deformities of the lumbo-sacral region of the spine. *Br J Surg*, 16: 562.
4. Brown T, Hansen RJ, Yorra AJ (1957) Some mechanical tests on the lumbosacral spine with particular reference to the intervertebral discs. *J Bone J Surg Am*, 39A: 1135.
5. Cyron BM, Hutton WC (1978) The fatigue strength of the lumbar neural arch in spondylosis. *J Bone J Surg*, 66: 234–238.
6. Cyron BM, Hutton WC (1980) Articular tropism and stability of the lumbar spine. *Spine*, 5: 168–172.

7. Cyron BM, Hutton WC, Troup JDG (1976) Spondylolytic fractures. *J Bone J Surg Br*, 58: 462–466.
8. Farfan HF, Sullivan JD (1967) The relation of facet orientation to intervertebral disc failure. *Can J Surg*, 10: 179–185.
9. Farfan HF (1973) Mechanical disorders of the low back. Lea & Febiger, Philadelphia, pp. 16–22.
10. Fujiwara A, Tamai K, Howard S, Lim TH, Yoshida H, Kurihashi A, Saotome K (2001) Orientation and osteoarthritis of the lumbar facet joint. *Clin Orthop Rel Res*, 385: 88–94.
11. Harris Mitchel B, Stelly MV, Villarraga ML, Schroeder Ac, Thomas KA (2001) Modeling of the naked facet sign in the thoracolumbar spine. *J Spinal Dis*, 14: 252–258.
12. Holdsworth F (1970) Fractures, dislocations and fracture dislocations of the spine: review article. *J Bone J Surg Am*, 52: 1534–1551.
13. Love TW, Fagan AB, Fraser RD (1999) Degenerative spondylolisthesis: developmental or acquired? *J Bone J Surg*, 81B: 670–674.
14. Putti V (1927) On new conceptions in the pathogenesis of sciatic pain. *Lancet*, 2: 53.
15. Roaf R (1960) A study of the mechanics of spinal injuries. *J Bone J Surg Br*, 42B: 810.
16. Standring S (2005) *Gray's anatomy: the anatomical basis of clinical practice*. 39th Ed. Elsevier Churchill Livingstone, London, pp. 748–749.
17. Taylor JR, Twomey LT (1986) Age changes in lumbar zygapophyseal joints observations on structure and function. *Spine*, 11: 739–745.
18. Van Schaik JPJ, Verbiest H, Van Schaik FDJ (1985) The orientation of laminae and facet joints in the lower lumbar spine. *Spine*, 10: 59–63.
19. Virgin WJ (1951) Experimental investigations into the physical properties of the intervertebral disc. *J Bone J Surg Br*, 33B: 607.
20. White AA, Panjabi MM (1978) The basic kinematics of the human spine. *Spine*, 3: 12.