

An unreported variation of the cervical vagus nerve: anatomical and histological observations

R.S. Tubbs^{1, 2}, M. Loukas^{3, 4}, M.M. Shoja⁵, D. Blevins⁶, R. Humphrey⁶,
G.D. Chua⁶, D.R. Kelly⁶, W.J. Oakes²

¹Department of Cell Biology, University of Alabama at Birmingham, USA

²Section of Pediatric Neurosurgery, University of Alabama at Birmingham, USA

³Department of Anatomical Sciences, St. George's University, Grenada, USA

⁴Department of Education and Development, Harvard University, Boston, Massachusetts, USA

⁵Department of Anatomy and Neurosurgery, Tabriz University, Tabriz, Iran

⁶Department of Pathology and Laboratory Medicine, Children's Hospital, Birmingham, Alabama, USA

[Received 2 January 2007; Accepted 1 March 2007]

Variations involving the cervical portion of the vagus nerve are seemingly very rare. We report an adult male found to harbour a right cervical vagus nerve that crossed anterior to the right common carotid artery to terminate in the lateral aspect of the thyroid gland. A very small continuation of this nerve was found to continue distally into the thorax. Histologically, this part of the vagus nerve did not contain ganglion or other cell bodies. There were no heterologous inclusions (thyroid, parathyroid, thymus, salivary gland or branchial cleft remnants) present. Although grossly there was a connection into the thyroid gland, this was not observed histologically. No signs of trauma were found to the ipsilateral neck region. We hypothesise that this variation is due to entanglement between the thyroid gland and cervical vagus nerve during development. This rare variation might be considered by the clinician who operates in the cervical region or interprets imaging of the neck. To our knowledge, a vagus nerve with the above described morphology has not been described.

Key words: anatomy, neck, nervous system, variation, cranial nerve

INTRODUCTION

Variations of the cervical portion of the vagus nerve are seemingly very rare. Variations include the ansa cervicalis arising from the cervical vagus nerve and this nerve being associated with accessory parathyroid tissue [2]. The left vagus nerve has been found to cross anterior to the common carotid artery and thyroid gland [2]. We now describe a case of an unusual course of the right cervical vagus nerve that, to our knowledge, has not previously been reported.

CASE REPORT

We report a 75-year-old male who died of natural causes. During routine dissection of the right cervical region as part of a gross anatomy course at our university, the right vagus nerve was found to take an unusual course. At the level of the carotid artery bifurcation the vagus nerve was noted to travel anterior to both the common carotid artery and the internal jugular vein. The nerve continued inferomedially to seemingly terminate into the lateral aspect of the thyroid gland. Near this point the nerve

became rather bulbous (Fig. 1). The right thyroid gland was seen to be slightly more superiorly placed compared to the left side (Fig. 1).

A very small continuation of this nerve was found to continue distally into the thorax. Except for a very small right recurrent laryngeal branch,

other branches of the vagus nerve appeared normal. Histologically, the proximal part of the cervical vagus nerve appeared normal. Distally, as the nerve became bulbous, nerve fibres were found to splay out into dense but blandly cellular collagenous tissue (Fig. 2). The perineurium was always

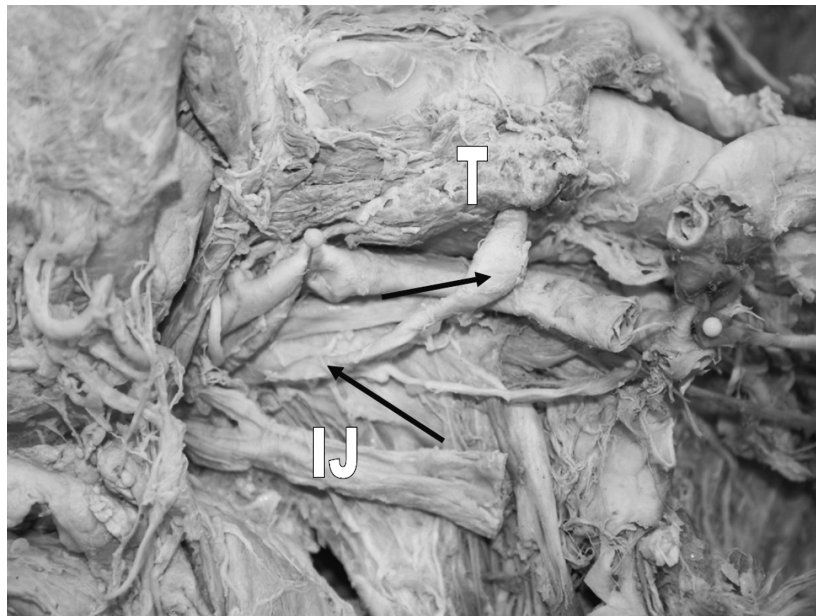


Figure 1. Right cervical region of the cadaver reported (supine and with head to the left) with a variation of the vagus nerve (arrows). For reference, note the common carotid artery (left pin), internal jugular vein (IJ) and thyroid gland (T). The cervical part of the right sympathetic trunk is seen deep to the vagus nerve. Note also that the right thyroid gland is slightly more superiorly placed compared to the left side.

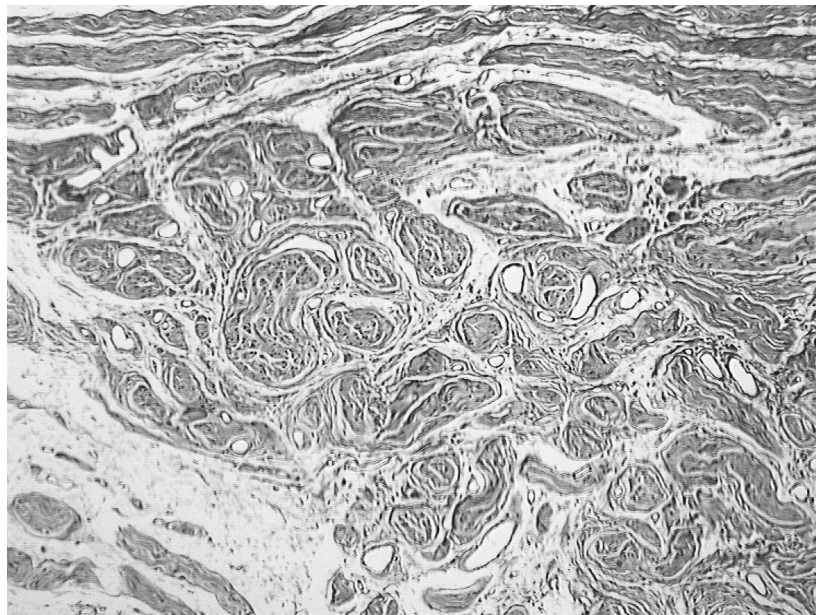

Figure 2. Distal bulbous portion of the vagus nerve variation reported here. At the distal margin of the vagus nerve, as it abuts the connective tissue capsule of the left inferior aspect of the thyroid gland, there are disorganised microfascicles formed by connective tissue stroma ($\times 33$, H&E)

preserved. A few small clusters of lymphocytes with a very patchy distribution were found in and around the nerve. No hemosiderin or calcifications were seen. No ganglion cells were present. Additionally, no heterologous inclusions (thyroid, parathyroid, thymus, salivary gland or branchial cleft remnants) were identified. Other than grossly visible loose connective tissue, there was no apparent connection between the thyroid and the nerve. Abnormal or aberrant peripheral nerve fibres were not found to extend into the thyroid parenchyma. There was no evidence of old trauma or surgery to the neck.

Interestingly, the thyroid gland demonstrated multicentric papillary microcarcinoma, follicular variant. The largest of the five or six tiny round nodules of this pathology measured approximately 2 mm. The gland appeared grossly to be of a normal size and colour.

DISCUSSION

To our knowledge, a vagus nerve with the morphology detailed above has not been described. Gibson [3] has reported bilateral anterior placement of the cervical vagus nerve. This author also reported that this may be more common in foetal life, when the common carotid artery and internal jugular vein are much smaller in diameter than in the adult with a resultant protrusion of the vagus between these vessels. Anson [1] and Schaefer et al. [5] have stated that the vagus nerve may "descend in front of the artery". However no mention

was made of a connection to the thyroid gland, as seen in our case.

The papillary microcarcinoma identified in the adjacent thyroid gland is, at this age, probably of little clinical significance. Perhaps 15–25% of elderly individuals may be found to harbour such microscopic cells within their thyroid gland.

Although we were unable to identify ectopic cells within the vagus nerve, Kameda [4] found evidence to support the theory that neuronal cells from the distal vagal ganglion enter the ultimobranial anlage and give rise to C cells in the chick. Considering the unusual course of the vagus nerve and the slightly elevated right side of the thyroid gland, we hypothesise that this variation is due to entanglement between the thyroid gland and cervical vagus nerve during embryological development.

REFERENCES

1. Anson BJ (1966) *Morris' human anatomy*. 12th ed. The Blakiston Division, McGraw-Hill Book Company, New York.
2. Bergman RA, Afifi AK, Miyauchi R (2006) *Vagus (CN X) Nerve* (<http://www.anatomyatlases.org/AnatomicVariants/NervousSystem/Text/VagusNerve.shtml>).
3. Gibson A (1915) Bilateral abnormal relationship of the vagus nerve in its cervical portion. *J Anat Physiol*, 69: 389–392.
4. Kameda Y (2004) Evidence to support the distal vagal ganglion as the origin of C cells of the ultimobranial gland in the chick. *J Comp Neurol*, 359: 1–14.
5. Schaefer EA, Symington J, Bryce TH (1915) *Quain's anatomy*. 11th ed. Longmans, Green and Co., London.