VIA MEDICA

ORIGINAL ARTICLE

Folia Morphol.
Vol. 66, No. 4, pp. 283–290

ISSN 0015–5659
www.fm.viamedica.pl

The initial zones of the atrioventricular node: really neglected anatomical features of potential clinical significance?

D. Kozłowski[1], M. Kozłowska[2], A. Kosiński[3], P. Woźniak[3], G. Piwko[3], R. Kamiński[1], M. Grzybiak[3], G. Raczak[1]

[1]*Department of Cardiology and Electrotherapy, Second Chair of Cardiology, Medical University, Gdańsk, Poland*
[2]*Department of the Propaedeutics of Medicine and Public Health, Chair of Nursing, Pomeranian University, Słupsk, Poland*
[3]*Department of Clinical Anatomy, Chair of Anatomy, Medical University, Gdańsk, Poland*

[Received 24 August 2007; Accepted 24 October 2007]

The constant evolution of medical knowledge and accompanying development of diagnostic and treatment possibilities for arrhythmias and conduction disturbances has reawakened interest in the structure and function of the conduction system of the human heart, especially in the region of the atrioventricular (AV) junction and within the junction itself. Of the large number of studies dealing with the AV junction few focus on the initial zones of the AV node. These were described for the first time by Tawara in 1906. Similarly, Anderson et al. distinguished two origins of the AV node, the left one running towards the basis of the mitral valve and the right one leading towards the tricuspid valve. The differences in length and scale could be the result of the adoption of different reference points.

The study was carried out on the material of 50 human hearts, of both sexes and ranging in age from 22 to 93, which were fixed in 10% formalin and 98% ethanol solution. The tissue obtained was fixed in the 10% formalin solution and, after being sunk in the paraffin, was cut into layers of about 10 µm thick. According to the age of the hearts, every 10th or 6th section was stained by the Masson-Goldner method. The preparations were examined under a LEICA 2000 and BIOLAR 2 microscope at magnifications of 2× to 400×.

Each of the 50 examined hearts contained the atrioventricular node and its initial parts. We observed that the initial zone of the AV node is created by an assembly of cells typical for a conduction system that can create three groups that are initially independent of each other and are always arranged around the AV nodal artery. In all the hearts examined we found at least two initial parts of the node: the superior and inferior. These two groups were present in 45 hearts (90%). In the last 5 cases (10%) there was also a middle group. No cases were found either with a single initial group or without any initial groups. In the sections examined the superior group appeared to be first in 27 hearts (54%), while in 23 cases (46%) the inferior group was first. The length of each group was measured from its first appearance to its first direct contact with the second part. The length of the superior part varied from 0.15 to 2.91 mm (mean 0.90 ± ± 0.6 mm), the inferior from 0.11 to 2.41 mm (mean 0.88 ± 0.6 mm) and the

Address for correspondence: D. Kozłowski, MD, PhD, Department of Cardiology and Electrotherapy, Medical University of Gdańsk, Dębinki 7, 80–211 Gdańsk, Poland, tel./fax: +48 58 349 39 10, e-mail: dkozl@amedec.amg.gda.pl

middle from 0.67 to 2.21 mm (mean 1.04 ± 0.7 mm). As mentioned above, in all 50 hearts there was a direct connection between the atrial muscle and the upper origin of AV node. Furthermore, in all sections (100%) the same part of the interatrial septal muscle was connected to the compact part of the node. Additionally, in 3 cases (6%) we were able to observe direct connections between the muscle fibres running from the fasciculus limbicus inferior *to the initial zone of the AV node: in 2 cases (4%) with the superior group and in 1 case (2%) with the inferior group. In 8% of the material the atrial muscle of the supra-orificial zone made direct contact with the superior initial group and the compact zone of the node and in 10% there was contact between the suborificial muscle and the inferior group and the compact part of the node. This configuration was not observed in relation to the middle and inferior groups.*

Key words: posterior extensions, initial zones, atrioventricular node, human heart

INTRODUCTION

The constant evolution of medical knowledge and accompanying development of diagnostic and treatment possibilities for arrhythmias and conduction disturbances has reawakened interest in the structure and function of the conduction system of the human heart, especially in the region of the atrioventricular (AV) junction and within the junction itself. The structure referred to is localised within Koch's triangle, which is limited by the attachment of the septal leaflet of the tricuspid valve, the tendon of Todaro and the orifice of the coronary sinus [1, 6, 7]. Knowledge of the mechanism of the re-entry wave arising has created the basis for current clinical electrophysiology. One of the arrhythmias originating from the re-entry wave is atrioventricular nodal re-entry tachycardia (AVNRT). The existence of two AV conduction pathways within the AV node has been confirmed during electrophysiological studies on individuals suffering from this kind of arrhythmia. This was observed for the first time by Moe and Preston in 1956 [3] and confirmed by a microelectrode examination of the conduction system by Mendez and Moe in 1966 [17]. At first the exact location of pathways as the possible substrate for arrhythmia was a very controversial issue. As a result of ablation procedures and in-operation mapping it was possible to determine their topography precisely [3]. It is assumed that these pathways lie within the boundaries of Koch's triangle and not, as believed earlier, within the AV node itself. The fast pathway is located in the vicinity of the AV bundle, while the slow one lies just by the orifice of the coronary sinus. There is also some evidence that the circumferential pathway of conduction does not include the node itself but its environs. Some healthy people without any evidence of AVNRT also have a double conduction pathway through the AV node. Moreover, no significant differences in anatomical structure have been found in patients with a confirmed diagnosis of AVNRT. Of the large number of studies dealing with the AV junction, few have focused on the so-called "posterior extensions" or "initial zones" of the AV junction. In addition, some of the studies fail to confirm our observations, while others are in contradiction to them [1, 8, 11, 19, 20]. Taking this into consideration, we decided to examine the morphology of the initial zones of the node and to find the answer to the question of whether an anatomical substrate for AVNRT exists.

As mentioned above, few studies on the AV junction have so far drawn attention to the initial zones of the AV node. These were first described by Tawara in 1906 [20]. His observations were made on the basis of extremely restricted material, only 5 hearts being studied, and this may have given rise to the diversity of opinions. Similarly, Anderson et al. [1] distinguished two origins of the AV node: the left one running towards the basis of the mitral valve and the right one leading towards the tricuspid valve. We distinguished a third group in addition to these [11], a middle one. The variation in the findings may result from the lack of detailed data on the hearts examined. Inoue and Becker [9] also mentioned the origins of the node; from an examination of 21 sections they founded that the origins of the node fell into three different schemes: in the first both groups, the left and the right, were present (13 hearts); in the second the only group present was the left one (1 heart), and in the third only the right group was observed (7 hearts). These results run completely counter to the earlier observations made by Inoue and Becker [9] in other studies. Their findings are not at all in accordance with our study. These hearts

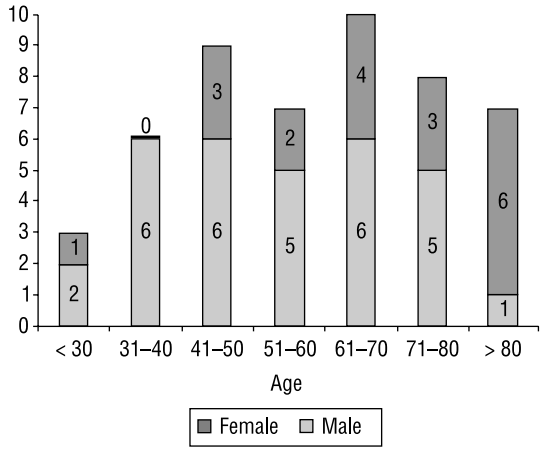

Figure 1. Schedule of material investigated.

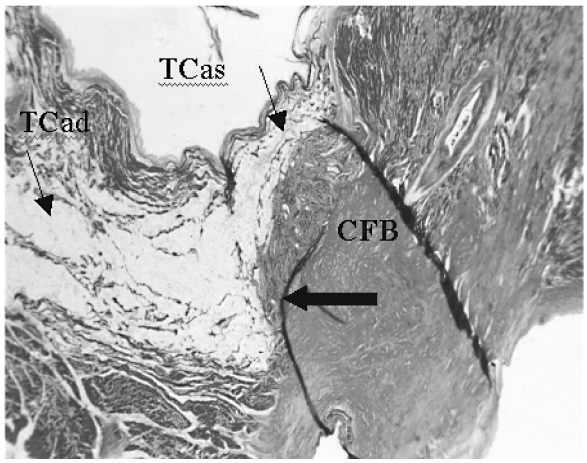

Figure 2. Histological view presenting the AV node with transient cells. TCad — deep; TCas — superficial; CFB — right fibrous body; thick arrow — direct connection of the atrial muscle and the node.

were derived from individuals with serious lesions of the circulatory system and other diseases. The differences in length and scale could be the result of adopting different reference points.

MATERIAL AND METHODS

The study was carried out on the material of 50 human hearts, of both sexes and ranging in age from 22 to 93 years (Fig. 1), which were fixed in 10% formalin and 98% ethanol solution. All the hearts examined were free from macroscopic pathological changes or congenital heart disease and the cause of death was non-cardiac. The heart was opened with two cuts as follows: the first ran from the apex of the right ventricle along its lateral margin and through the posterior leaflet of the tricuspid valve; the second led through the fibrous body of the left AV outlet, the posterior leaflet of the mitral valve and the ventricular wall between the anterior and posterior papillary muscle to the apex of the heart. The part of the right atrium containing Koch's triangle was then excised with the upper subvalvular part of the right chamber so as to obtain the section containing the AV junctional area (the AV node, AV bundle and the branches of AV bundle). Accordingly the cut was begun from the edge of the oval fossa and was then directed down across the outlet of the coronary gulf and the septal leaflet as far as the upper part of the interventricular septum. For this purpose the cut was lead from the oval fossa downwards through the ostium of the coronary sinus and the septal leaflet of the tricuspid valve, and finally it reached the upper part of the interventricular septum. Next, the cut was lead crosswise the interventricular septum reaching the wall of the aorta and the anterior leaflet, i.e. aortal leaflet of the mitral valve. The next cut was lead from the top, cutting the above mentioned leaflet of the mitral valve lengthwise and then the interatrial septum at the level of the oval fossa. The last cut ran through the interatrial septum, and within its anterior segment through the walls of both atria and the aorta localized between them. The excessive amount of fatty tissue was removed from the obtained section and its margins were smoothed. Then the section was divided into two parts: anterior and posterior, along the medial longitudinal axis of the oval fossa. The tissue obtained was fixed in a 10% solution of formalin and, after being sunk in the paraffin, was cut into layers of about 10 μm thick. According to the age of the hearts, every 10th or 6th section was stained by the Masson-Goldner method. The preparations were examined under a LEICA 2000 and BIOLAR 2 microscope at magnifications of 2× to 400×. The length and shape of the examined part of the conduction system were estimated on the basis of the microscopic observations.

RESULTS

Each of the 50 examined hearts contained the atrioventricular node and its initial parts. In all cases the node consisted of two clearly differentiated layers. The first, the outer one, situated subendocardially, was created by cells morphologically transient between the atrial muscle cells and cells typical for the conduction system. With regard to the topography we distinguished two groups of transient cells, namely anterior and posterior, with the border at the level of the completely formed node (Fig. 2). Both

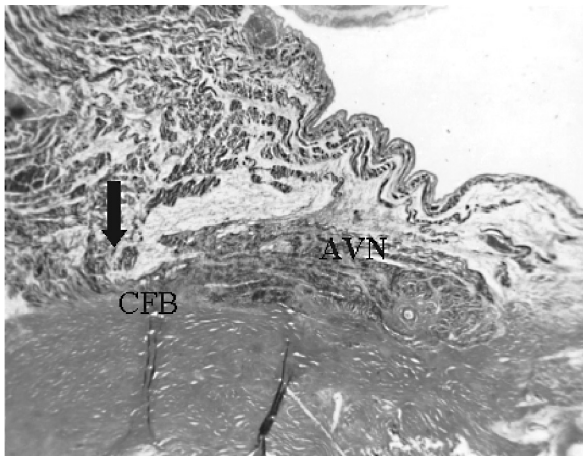

Figure 3. Histological view presenting the compact zone of the AV node and direct connection with the interatrial septum muscle (arrow). CFB — right fibrous body, AVN — atrioventricular node.

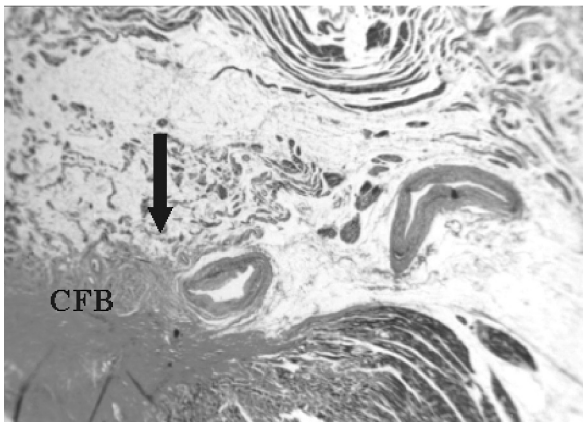

Figure 4. Histological view presenting the initial zone of the AV node in its upper part (supported on the right fibrous body) and direct connections with the muscle of the inferior marginal bundle marked by arrow. CFB — right fibrous body.

groups consisted of two layers, a superficial one and a deep one. In all 50 of the hearts examined we were able to observe the presence of superficial cells in both anterior and posterior groups (100%). Differences in prevalence appeared in the deep layers. Posterior cells of the deep layer were present in 7 hearts (14%), while the anterior group was present in 35 hearts (70%). The transient cells were a constant intermediary element between the atrial muscle and the conduction system. However, they were not the only morphological element in the perinodal area directly connected to the initial zone of the node or the compact AV node itself. Direct connections between the interatrial septum muscle cells (Fig. 3) and both the initial zone of the node (its upper part) and the AV node itself could be found in each of the hearts examined (100%). The presence of such alternative connections can form a gate for the impulse penetrating directly to the AV node.

We observed that the initial zone of the AV node is created by an assembly of cells typical for the conduction system, which can create 3 groups, initially independent of each other, and always arranged around the AV nodal artery (Fig. 4). We divided them into the following groups depending on their relation to the artery: the superior group located above the artery, to the left and supported by right fibrous body, the inferior group located below the artery and supported on the lower part of the attachment of the septal leaflet of the tricuspid valve, and the middle group located below the nodal artery. In all the hearts examined we found at least 2 initial parts of the node, the superior and the inferior (Fig. 5).

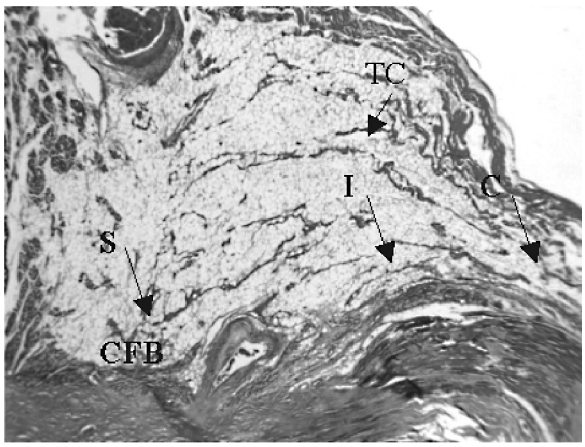

Figure 5. Histological view presenting 2 initial zones of AV node. S — superior group; I — inferior group; CFB — right fibrous body; C — direct connection of the inferior group of the AV node with the suborificial muscle; TC — superficial, transient, anterior cells.

These 2 groups were present in 45 hearts (90%). In the last 5 cases (10%) there was also a middle group. No cases were found either with a single initial group or without any initial groups. In the sections examined the superior group appeared to be first in 27 hearts (54%), while in 23 cases (46%) it was the inferior group. The length of each group was measured from its first appearance to its first direct contact with the second part. The length of the superior part varied from 0.15 to 2.91 mm (mean 0.90 ± 0.6 mm), the inferior from 0.11 to 2.41 mm (mean 0.88 ± ± 0.6 mm) and the middle from 0.67 to 2.21 mm (mean 1.04 ± 0.7 mm) (Table 1). As mentioned above, in all 50 hearts there was a direct connection between the atrial muscle and the upper origin of

Table. 1. Measurement of initial zones of the human heart

Number of specimen	Age	Sex	Superior initial zone [mm]	Inferior initial zone [mm]	Middle initial zone [mm]
1/K266	57	M	1.09	0.79	0.67
2/K254	74	K	2.51	1.91	0.71
3/D31	81	K	0.91	0.81	0.81
4/K271	44	M	1.01	1.11	0.81
5/K267	56	K	2.21	2.41	2.21
6/K272	71	M	0.31	0.11	–
7/D12	55	M	0.35	0.15	–
8/D36	22	K	0.25	0.19	–
9/D39	28	M	0.39	0.19	–
10/K279	45	K	1.01	0.21	–
11/D28	31	M	0.45	0.25	–
12/K261	60	M	0.61	0.25	–
13/D56	19	M	0.63	0.27	–
14/D66	66	M	0.51	0.31	–
15/D35	34	M	0.27	0.33	–
16/D57	71	K	0.51	0.33	–
17/D50	71	M	0.15	0.35	–
18/D46	67	M	0.45	0.39	–
19/D51	50	M	0.57	0.39	–
20/K276	86	K	0.51	0.41	–
21/D67	85	M	0.91	0.41	–
22/K257	97	K	1.11	0.41	–
23/K265	67	K	0.91	0.43	–
24/D34	70	K	0.27	0.51	–
25/K280	42	M	0.81	0.51	–
26/K274	85	K	0.71	0.61	–
27/K273	64	K	0.71	0.61	–
28/K277	73	M	0.81	0.71	–
29/K270	44	M	1.11	0.71	–
30/D61	48	K	0.55	0.75	–
31/D65	84	K	1.45	0.75	–
32/D28	31	M	0.63	0.81	–
33/D30	62	K	0.73	0.85	–
34/D40	44	K	0.57	0.87	–
35/D42	47	M	0.81	0.87	–
36/D49	81	K	0.21	0.9	–
37/K291	60	M	1.01	0.91	–
38/D37	45	M	0.65	1.15	–
39/K278	35	M	1.09	1.15	–
40/D62	62	M	0.85	1.35	–
41/D41	71	M	0.85	1.35	–
42/D27	35	M	1.01	1.41	–
43/K287	76	M	1.21	1.41	–
44/K275	66	M	1.01	1.61	–
45/D63	50	M	2.91	1.61	–
46/K203	38	M	1.41	1.81	–
47/K250	80	M	1.61	1.91	–
48/K259	67	M	2.01	1.91	–
49/D48	58	M	1.81	2.01	–
50/D38	52	K	0.71	2.31	–
		AVG	0.9028	0.8754	1.042
		SD	0.58236338	0.61871892	0.65583535

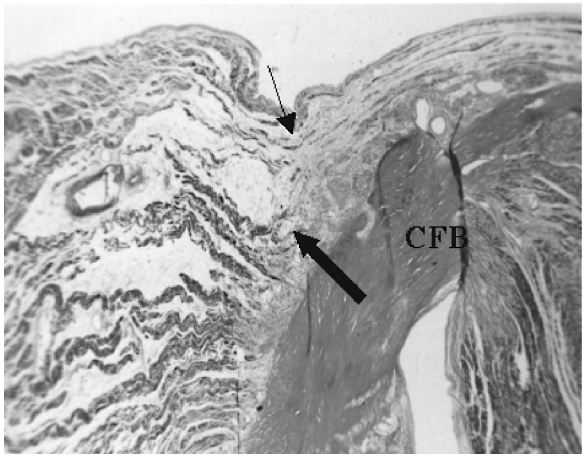

Figure 6. Histological view presenting the AV node. The thin arrow indicates direct connections of the supra-orificial muscle with the node; thick arrow — direct connection of the atrial muscle and the node; CFB — right fibrous body.

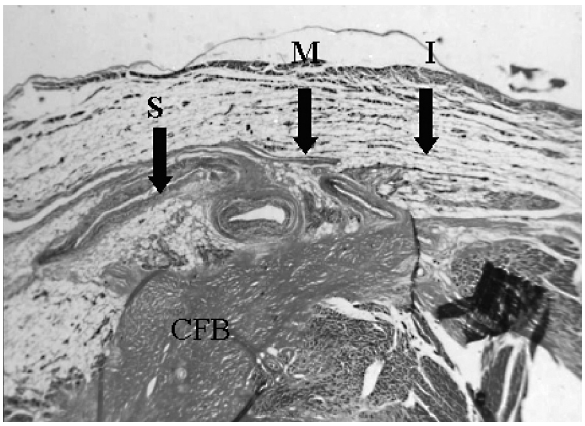

Figure 7. Histological view presenting 3 initial zones of the AV node. S — superior group; M — middle group; I — inferior group; CFB — right fibrous body.

AV node. Furthermore, in all sections (100%) the same part of the interatrial septal muscle connected with the compact part of the node. Additionally, in 3 cases (6%) we were able to observe direct connections between the muscle fibres running from the *fasciculus limbicus inferior* to the initial zone of the AV node: in 2 cases (4%) with the superior group and in 1 case (2%) with the inferior group (Fig. 4). In 8% of the material the atrial muscle of the supra-orificial zone made direct contact with the superior initial group and the compact zone of the node and in 10% there was contact between the suborificial muscle and the inferior group and the compact part of the node (Fig. 6). This configuration was not observed in relation to the middle and inferior groups.

On the basis of our study we were able to conclude that the prevalence of at least two initial zones of the node, the superior and the inferior, was constant and occurred in each of the hearts examined. Our data suggest that the middle group is an additional one that occurs sporadically but that the direct connections between the interatrial septum muscle and the superior group and the compact zone of the node are also constant (Fig. 7).

DISCUSSION

The AV node is physiologically only one of the "bridges" between the atria of the heart and its chambers. It is usually situated in the right atrium, in the region topographically designated as the triangle of Koch, well-known to all electrophysiologists as one of the components of the atrioventricular junctional area. According to physiology, the atrio-ventricular node is the only "bridge" connecting atria and ventricles. Topographically it is localized in the right atrium in the area designated by Koch's triangle. It is a part of the atrio-ventricular junction. This term was introduced to the common use for the first time by Hecht et al. [6]. Nevertheless it was Anderson and the independent group of prominent scientists who in 1975 [1], relying in their own many years' studies, systematized the knowledge of the heart conductive system. Within the junction they distinguished 4 regions: transitional one, the region of the compact atrio-ventricular node, the penetrating bundle and the branching bundle. Although its was discovered almost 100 years ago, the node alone as well as the junction still rise many controversies.

Due to the arrhythmias originating in this region and the development of the invasive methods of therapy, within the last few years it became a subject of the intensive studies. The three-dimensional model of the AV node for the first time was developed by Ho et al. [7]. Considering their results and his own electrophysiological and clinical observations Hecht et al. [6] introduced another scheme. Nevertheless they did not consider the histology of the junction. On the other hand, Denes et al. [4] created a completely new concept of its structure utterly different than the original one. Basing on his observations he stated that the node is uniform structure and, concerning its morphology, shouldn't be divided. He also suggested that transitional cells are the initial part of the node. Considering results of our studies, we can not agree with that. Denes et al. [4] during electrophysiological studies proved that transitional cells area and the beginning of the node do

differ from each other. Additionally he described fibers penetrating into tricuspid valve and afterwards reaching the distal part of the node. Considering our own results we could not confirm those observations. The Anderson's model of the node is the most functional one [1]. He presented the occurrence of two beginnings of the node, where the lower one is longer than the upper. The results of my study differ from the above — the upper beginning occurred to be longer. Moreover in some cases (10% of the hearts) I was able to distinguish a third beginning, which appeared directly behind the artery of the AV node. According to the model recently presented by Becker et al. [9], almost in half of the examined hearts only one (left or right) beginning of the node was observed. It was named the "posterior extension" [9]. None of such cases was found in my study. The length of the "extensions" described by above mentioned authors were also distinctly larger to those that I could find. Different reference points of measurements could be a reason of such a diversity. Unfortunately, the detailed data were not contained in the paper [9]. Moreover those results are not concordant with the previous reports of Anderson and Becker [1] as well as Davies et al. [2]. In his recent papers Anderson did not assume an attitude towards the changes introduced to the model [1]. According to Ionue, the study was carried out on the healthy hearts, but obtained from individuals suffering from disorders that could influence the size, dimensions, and weight of the studied material.

The possibilities given by the electrophysiological examination are significantly helpful in putting the opinions on mechanisms of dysrrhythmia generation in order. The atrio-ventricular nodal reentry tachycardia is the most common supraventricular arrhythmia, where the anatomical structure seems to take an important part. At the very beginning it was supposed that both pathways are localized within the atrio-ventricular node. Through intraoperative mapping currently it is believed that the pathways are localized in the region of the Koch's triangle and the node itself it just one of the links of the loop [1, 4]. During a detailed intraoperative mapping McGuire proved that the region of the slow conduction during AVNRT covers the area of 8 × 3 mm, whereas McGuire presented that size and location on scheme [16]. After morphological analysis of the heart with previous ablation of the slow pathway [5]. Holman et al. [8] coupled the histological and electrophysiological data. However no differences were found in the structure of AV junction between individuals with and without nodal reentry tachycardia. Instead it was suggested that the fast as well as slow pathways are common to everybody, and the pathology originates from too long refraction period of the fast pathway and too short of the slow pathway [5]. The double path of conduction can be documented only in such subjects. Nevertheless, as some of the researchers noticed, the concept of dualism in the AV node does not explain numerous forms of atypical nodal tachycardia, observed in ca. 7.6% of people with AVNRT. Wu et al. [22] introduced a model of a double, 8-shaped loop, consisting of slow, fast and intermediate pathway. If all of them conducted in both directions: descending and ascending, it would give 6 types of tachycardia, and 4 types, if the intermediate pathway conducted only in retrograde direction. There are also concepts of 9-shaped loops with the entrance and circulation within the area of the node [14, 15, 21]. I would like to mention, as I also reported before, that during the studies I have observed a presence of archipelagos of the tongues penetrating the right fibrous ring as well as loop-shaped. Additionally, the proliferation of the fibrous and fatty tissue within the node developed in conjunction with the age, perturbing its homogenous structure. This could be a morphological substrate for the atypical tachycardia occurrence.

Currently a selective ablation of one of the pathways is a radical treatment of the reentry tachycardia. The clinicians argue which of the pathways should be destoyed [4, 8, 15–17, 21]. Each of the methods has some advantages and disadvantages. At the beginning the only being ablated was the fast pathway, most probably consisting of the "last fibers" passing by the node [12] or the atrial fibers directly penetrating either the His' bundle [18] or the node. A short application of the current was efficient. However due to high rate of complications as atrio-ventricular block (5–8%) it was given up. Currently the slow pathway ablation is a method of choice [23]. It is localized close to the outlet of the coronary sinus, distantly from the compact zone of the AV node. The complications are rare (2–3%) and most probably are the effect of AV node artery damage [11, 13]. However the explanation of so called slow pathway potentials and nodal rhythm acceleration during the ablation is still a subject of presumptions. Perhaps the influence on complications of the ablation of the tachycardia in the zone of the slow conduction has an occurrence of initial zones. This unfortunately demands further research and is in hearts with proved and ablated arrhythmia.

REFERENCES

1. Anderson RH, Becker AE, Brechenmacher C, Davies MJ, Rossi L (1975) The human atrioventricular junctional area: a morphological study of the A-V node and bundle. Eur Heart J, 3: 11–25.
2. Davies MJ, Anderson RH, Becker WK, Gas D (1983) The conduction system of the heart. Butterworth & Co., London; 1983.
3. Denes P (1991) Radiofrequency ablation of the A-V node. J Am Coll Cardiol, 18: 1759–1790.
4. Denes P, Wu D, Dhingra R (1973) Demonstration of dual A-V nodal pathways in patients with paroxysmal supraventricular tachycardia. Circulation, 48: 549–555.
5. Haissaguerre M, Gaita F, Fischer B (1991) Elimination of atrioventricular nodal reentrant tachycardia using discrete slow potentials to guide application of radiofrequency energy. Circulation, 85: 2162–2175.
6. Hecht HH, Kossmann ChE, Childers RW, Langendorf R, Lev M, Rosen KM, Pruitt RD, Truex RC, Uhley HN, Watt TB (1973) Atrioventricular and intraventricular conduction. Revised nomenclature and concepts. Am J Cardiol, 31: 232–244.
7. Ho SY, Kilpatric L, Kanall T, Grmroth PG, Thompson RP, Anderson RH (1995) The architecture of the atrioventricular conduction axis in dog compared to man: its significance to ablation of the atrioventricular nodal approaches. J Cardiovasc Electrophysiol, 6: 26–39.
8. Holman WL, Cox JL, Cain ME (1988) Cryosurgical treatment of atrioventricular node reentry: histologic localization of the proximal common pathway. Circulation, 77: 1356–1363.
9. Inoue S, Becker AE (1998) Posterior extensions of the human compact atrioventricular node. A neglected anatomic feature of potential clinical significance. Circulation, 87: 188–193.
10. Kozłowski D, Hreczecha J, Skwarek M, Piwko G, Kosiński A, Gawrysiak M, Grzybiak M (2003) The diameters of the cavo-tricuspid area in relation to type I atrial flutter. Folia Morphol, 62, 133–142.
11. Kozłowski D, Koźluk E, Adamowicz M, Grzybiak M, Walczak F, Walczak E (1998) Histological examination of the topography of the atrioventricular nodal artery within the triangle of Koch. Pacing Clin Electrophysiol, 21: 163–167.
12. Kozłowski D, Koźluk E, Stanke A, Owerczuk A, Grzybiak M, Adamowicz M, Walczak E, Walczak F (1999) Morphology of the anterio-superior approaches in the light of atrioventricular nodal reentry tachycardia fast pathway ablation. Eur Heart J, 20: 583 (abstract).
13. Kozłowski D, Owerczuk A, Piwko G, Kozłowska M, Bigus K, Grzybiak M (2003) The topography of the subthebesian fossa in relation to neighbouring structures within the right atrium. Folia Morphol, 62, 65–70.
14. Koźluk E, Walczak F (1996) Niefarmakologiczne Leczenie zaburzeń rytmu serca — metody. Pol Tyg Lek, 51: 163–167.
15. Koźluk E, Walczak F, Szufladowicz E, Kozłowski D (1998) Ewolucja poglądów na budowę łącza przedsionkowo komorowe jako podłoża szybkich rytmów serca. ESS, 5: 155–162.
16. McGuire MA, Janse MJ, Ross DL (1993) "AV nodal" reentry. Part II: AV nodal, AV junctional or atrionodal reentry? J Cardiovasc Electrophysiol, 4: 573–586.
17. Mendez CSA, Moe GK (1966) Demonstration of a dual A-V nodal conduction system in the isolated rabbit heart. Circ Res, 19: 378–393.
18. Monahan KM, Zebede J, Josephson ME, Schuger CD (1995) Systematic characterization of the reentrant circuit during atrioventricualar nodal reentrant tachycardia. Am J Cardiol, 76: 138–143.
19. Sanchez-Quintana D, Cabrera JA, Farre J, Anderson RH (2001) Topographic anatomy of the inferior pyramidal space: relevance to radiofrequency catheter ablation. J Cardiovasc Electrophysiol, 12: 210–217.
20. Tawara S (1906) Das Reizleitungssustem des Saugetierherzens. Gustav Fisher Verlag, Jena.
21. Walczak F, Szufladowicz E, Jedynak Z, Kępski R, Koźluk E, Łastowiecka E, Popławska W, Stępińska J (1993) Ablacja prądem o wysokiej częstotliwości u chorych z nawrotnym częstoskurczem węzłowym. Kardiol Pol, 33: 199–204.
22. Wu D, Yeh SJ, Wang ChCh, Wen MS, Lin FCh (1994) Double loop figure-of-8 reentry as the mechanism of multiple atrioventricular node reentry tachycardias. Am Heart J, 127: 83–95.
23. Yamane T, Iedaka Y, Goya M, Takahashi A, Fujiwara H, Hiraoka M (1999) Optional target site for slow A-V nodal pathway ablation: possibility of predetermined focal mapping approach using anatomic reference in the Koch's triangle. J Cardiovasc Electrophysiol, 10: 529–537.