

The anatomy of the fundic branches of the stomach: preliminary results

M. Gregorczyk¹, A. Dąbkowska², S. Tarka², B. Ciszek¹

¹Department of Human Anatomy, Warsaw Medical University, Warsaw Poland

²Department of Forensic Medicine, Warsaw Medical University, Warsaw, Poland

[Received 11 February 2008; Accepted 22 April 2008]

The fundic branches of the stomach can be defined as a group of vessels that can arise either directly or indirectly from the following source arteries: the left inferior phrenic artery, the accessory left hepatic artery, the left gastric artery, the left middle suprarenal artery, the main trunk of the splenic artery, the posterior gastric artery, the superior polar artery, the gastrosplenic artery, the left gastroepiploic artery and the splenic artery with its inferior and superior terminal branches. It is worth mentioning that the fundic branches of the left gastroepiploic artery and the superior and inferior terminal branches of the splenic artery, like other vessels arising from these three source arteries and supplying the stomach, are defined as short gastric arteries.

The anatomy of these fundic branches, particularly relevant to some surgical procedures, is not sufficiently described, and the current literature suffers from lack of publications on this particular topic. We therefore decided to explore in detail the arterial vascularisation of the gastric fundus.

The research was carried out on material consisting of 15 human stomach specimens. The anatomical analysis comprised the following: the number of occurrences of fundic branches in each of the source arteries defined above, the distance between the origins of the source artery and its arising fundic branch, the way in which the fundic branches arose, the length, diameter at point of origin and morphology of the fundic branches, as well as the exact point of perforation of each fundic branch on the fundus.

The highest incidence of the direct-branching pattern of fundic branches was in the left middle suprarenal artery, the gastrosplenic artery and the left gastro-splenic artery. The accessory left hepatic artery, the left gastric artery and the main trunk of the splenic artery were the most frequent site of the indirectly arising pattern of fundic branch. The highest median value of fundic branch length was 63.05 mm, found in the accessory left hepatic artery group. The largest median diameter value of the vessel was encountered among those originating in the left middle suprarenal artery and reached 2.17 mm. The posterolateral quadrant of the fundus received the largest number of fundic branches, amounting to 46.5% of all the fundic branches studied. (Folia Morphol 2008; 67: 120–125)

Key words: gastric fundus, arterial vascularisation, accessory left hepatic artery, posterior gastric artery, superior polar artery, gastrosplenic artery

INTRODUCTION

A fundic branch of the stomach can be defined as an artery which, after arising from its source artery, perforates a particular part of the gastric fundus. The aim of the paper is to present the results of a study on the fundic branches of the stomach.

There are several reasons why this particular subject was taken up. Detailed morphometric analysis of the fundic branches leads to precise anatomical description. This has special clinical importance in surgical procedures performed on the stomach and in particular on its fundus [8–10], especially the bariatric procedure applied in pathological obesity, fundoplication carried out in oesophageal hiatus hernia and gastroesophageal reflux, proximal gastrectomy in gastric tumours and oesophageal reconstruction with utilisation of the stomach after oesophagectomy [13, 15, 16]. A precise anatomical description of the arterial supply of the organ operated on can decrease the number of complications due to gastric fundus ischaemia after the above procedures. This results in greater effectiveness of the method applied, while the decrease in the number of complications reduces treatment costs.

MATERIAL AND METHODS

The research was carried out on material consisting of 15 human stomach specimens. First the arterial network of each specimen was injected with dyed gelatine solution and fixed in 10% formaldehyde solution. Then each specimen was dissected with the aid of a standard set of microsurgical instruments and under a surgical microscope with a magnification of 4×40 to measure the fundic branch dimensions and topographical distances.

Each specimen contained a part of the abdominal aorta with the coeliac trunk, the left inferior phrenic artery, the superior mesenteric artery and the proximal portions of the left renal artery. Other anatomical structures included were as follows: part of diaphragm, the abdominal part of the oesophagus, the complete stomach, the bulb of the duodenum, the complete pancreas, the spleen and the left suprarenal gland.

For clear presentation of the results of the analysis only those vessels that were longer than 10 mm were classified as fundic branches. All the others were classified as perforators either of the fundic branch or of the source artery.

A total of 101 fundic branches were studied. The measurements comprised the number of fundic branches arising within groups of source arteries,

the frequency of the direct and indirect patterns of origin and the length, diameter, morphological type and point of perforation on the fundus of each fundic branch.

First the number of occurrences of fundic branches in each of the source arteries defined above and the distance between the origin of the source artery and the fundic branch arising were studied. Next the way in which the fundic branches arose was evaluated. From each previously defined source artery a single artery can arise directly or indirectly. This feature was measured in the material as a whole.

Other measurements that were made concerned the length, diameter at point of origin and the morphology of the fundic branches, as well as the exact point of perforation of each fundic branch on the fundus. For clear presentation of the results of this last measurement the external surface of the fundus was divided into four quadrants: the anteromedial (AMQ), anterolateral (ALQ), posteromedial (PMQ) and posterolateral (PLQ). Each perforation of the fundic branch was referred to the appropriate quadrant.

The results were presented for each source artery group and within a particular quadrant. The following source arteries were evaluated according to the occurrence of their fundic branches (FB): the left inferior phrenic artery (LIPA), the accessory left hepatic artery (ALHA), the left gastric artery (LGA), the left middle suprarenal artery (LMSA), the main trunk of the splenic artery (SA), the posterior gastric artery (PGA), the superior polar artery (SPA), the gastrosplenic artery (GSA), the left gastroepiploic artery (LGEA) and the splenic artery with its inferior and superior terminal branches (SAIB and SASB).

RESULTS

The frequency of occurrence of the fundic branches in the material tested is presented in Table 1. The source arteries in which fundic branches were always present were the SASB, SA, PGA, LMSA and GSA. Source arteries in which fundic branches were seldom present were the LGA and LGEA.

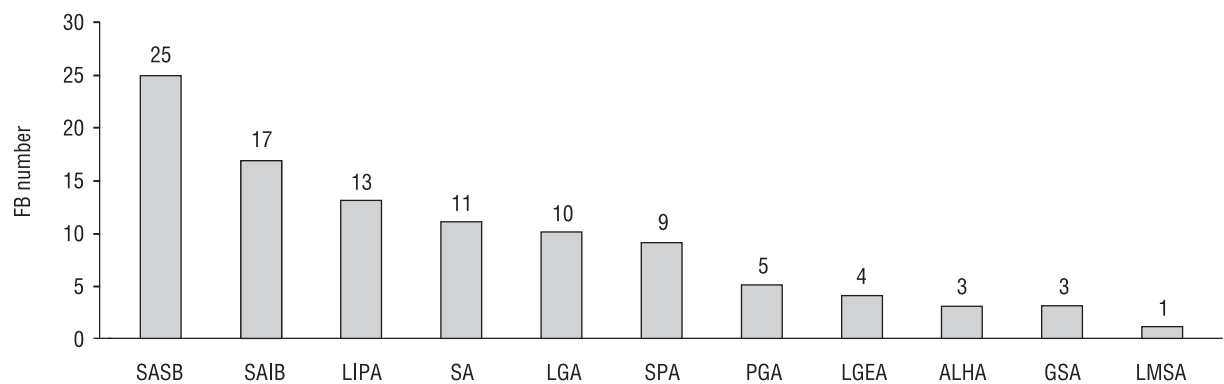
As Figure 1 shows, the total number of fundic branches obtained from any source artery group varied from 1 to 25. The highest median value for the number of fundic branches with a particular type of source artery was in the ALHA and GSA, while the LMSA had the lowest median value of fundic branches, according to the total number of specimens with a LMSA present.

The longest distance between the origin of the source artery and origin of the fundic branch was

Table 1. Participation of source arteries in fundic arterial supply

	SASB	SA	PGA	LMSA	GSA	SAIB	SPA	LIPA	ALHA	LGA	LGEA
No. of specimens arising at least 1 FB	10	5	4	1	1	9	6	9	1	5	2
N	10	5	4	1	1	10	8	15	2	15	15
No. of specimens arising at least 1 FB/total number of occurrences of the following source artery in the studied material	10/10	5/5	4/4	1/1	1/1	9/10	6/8	9/15	1/2	5/15	2/15

FB — fundic branches; SAIB — splenic artery with inferior terminal branches; SASB — splenic artery with superior terminal branches; SA — splenic artery; LGA — left gastric artery; LIPA — left inferior phrenic artery; ALHA — accessory left hepatic artery; SPA — superior polar artery; PGA — posterior gastric artery; LMSA — left middle suprarenal artery; GSA — gastrosplenic artery; LGEA — left gastroepiploic artery

**Figure 1.** Total number of fundic branches (FB) arising from different arterial source groups. For abbreviations see text in Table 1.**Table 2.** Proportion of involvement of the direct and indirect patterns of origin in FBs (1 FB was not evaluated in this study)

	SASB	SAIB	SA	LGA	LIPA	ALHA	SPA	PGA	LMSA	GSA	LGEA	Total
No. of FBs with direct pattern of origin	3	4	1	0	5	0	8	4	1	3	3	32
No. of FBs with indirect pattern of origin	22	13	10	10	8	3	1	1	0	0	0	68

For abbreviations see text in Table 1.

observed in the SA, with an average value of 121.67 mm. The shortest distance was present in the ALHA, with an average value of 15.59 mm.

As far as the type of origin of the fundic branch was concerned, all the fundic branches that originated directly from source artery were recorded as "direct" fundic branches. All the others were defined as "indirect" fundic branches. As shown in Table 2, direct branches were frequently characteristic for the LIPA, SAIB and PGA, whereas indirect

branches were a recognisable feature of the SASB, SAIB and SA.

The longest vessels were present in the LMSA, ALHA and LGEA, and these had a length of 85.57 mm, 63.05 mm and 53.43 mm, respectively. The shortest were found in the SASB (32.02 mm), SPA (20.88 mm) and GSA (18.77 mm).

The widest diameters at point of origin were observed in the LMSA, SAIB and LGA, which had an average width of 2.17 mm, 1.86 mm and 1.54 mm,

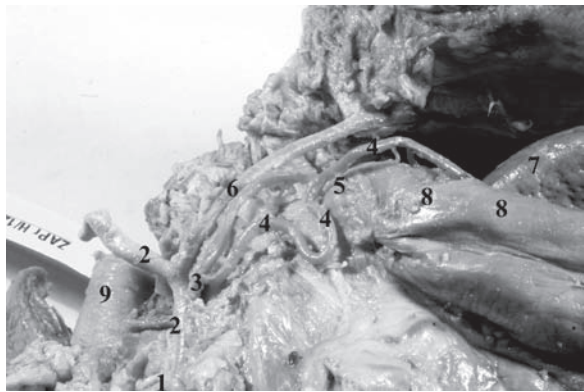


Figure 2. Front right view of the accessory left hepatic artery (ALHA) branching off a type III fundic branch of the stomach: 1 — left gastric artery (LGA), 2 — ALHA, 3 — gastric branch of the ALHA, 4 — fundic branch of the ALHA, 5 — one of the perforators of the fundic branch presented, 6 — phrenic branch, 7 — posterior pole of the spleen, 8 — fundus of the stomach, 9 — abdominal aorta.

respectively. The narrowest diameters were observed in the ALHA (1.09 mm), SPA (0.9 mm) and GSA (0.6 mm).

In terms of their morphology three types of fundic branch were distinguished:

- type I — a straight vessel without any branches, perforating the gastric fundus;
- type II — a bifurcated vessel, which branches off before entering the fundus in two branches without disproportion in their diameters;
- type III — a fundic branch that gives off perforate branches before entering the fundus (Fig. 2).

Type I and type III had a very similar frequency of occurrence, 37% and 41% respectively, whereas type II was present only in 22%. Particular morphological types were characteristic for specific

fundic branch source arteries. Within the material collected type I was characteristic for the GSA, LGA and PGA, type II for the SPA and type III for the LIPA.

Taking the point of perforation of each fundic branch on the fundus into consideration, the majority of fundic branches were received by the medial and lateral posterior quadrants. These accounted for 36.6% and 46.5% of the total number of fundic branches, respectively. The medial posterior quadrant mainly received its fundic branches from the LIPA and SASB (43.3% of the total number of fundic branches perforating this quadrant). The posterolateral quadrant was mostly supplied by fundic branches arising directly from the SASB and SAIB, and these accounted for 66% of the total number of fundic branches found in this quadrant. Figures 3 and 4 present detailed results of the above analysis.

DISCUSSION

The currently published resources do not yet include a comprehensive study of the arterial vascularisation of the fundic branches. There are some publications that partially discuss the topic [1–20]. These contain, for example, a description of the fundic branches deriving from some of the source arteries. The presence of fundic branches arising from the superior terminal branch, the inferior terminal branch, directly from the splenic artery and from the left gastrosplenic artery was described by Brown and Derr [2], Helm [5] and Vandamme and Bonte [20]. Brown and Derr [2] also present results concerning the LGA, finding that it indirectly supplies the fundus via its intramural arterial network. They do not,

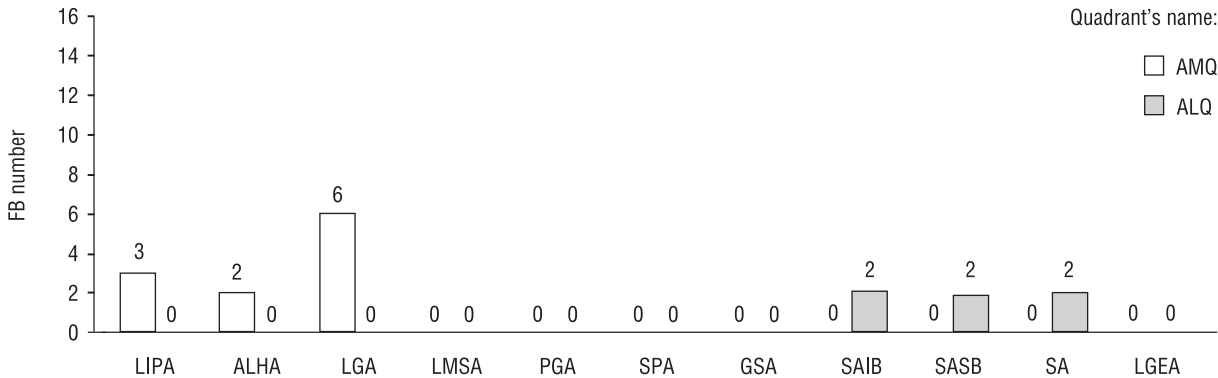


Figure 3. Participation of fundic branches originating from different source arteries in the arterial vascularisation of anterior quadrants of the stomach. For abbreviations see text in Table 1.

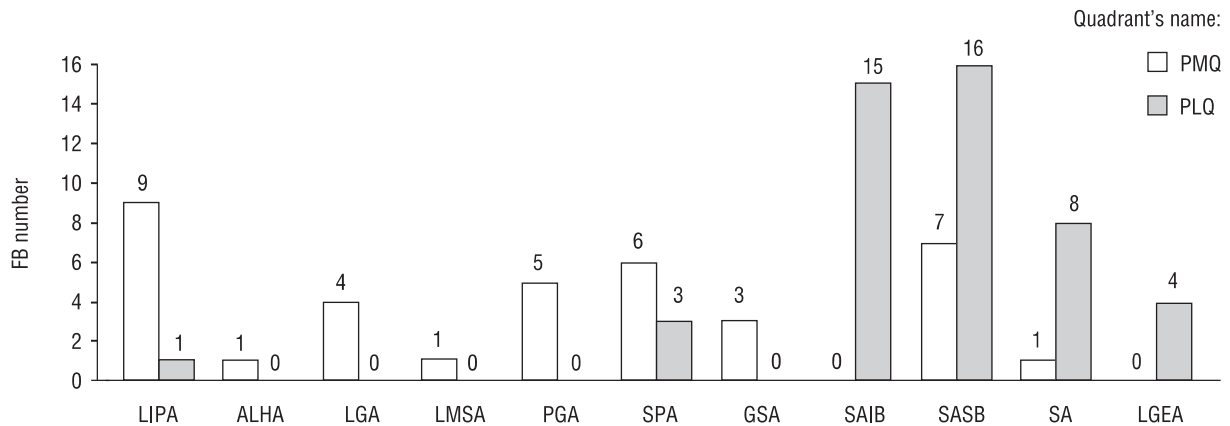


Figure 4. Participation of fundic branches originating from different source arteries in the arterial vascularisation of posterior quadrants of the stomach. For abbreviations see text in Table 1.

however, examine the vessels that build up that network. Other authors, including Berens et al. [1], Kurylcio et al. [7], Trubel et al. [19] and Vandamme and Bonte [20], discuss PGA involvement in the arterial supply of the fundus. Kurylcio et al. [7] also describe the LIPA participation in the arterial vascularisation of the fundus. Within the last few years no new article has been published on this particular topic.

Another point that needs to be mentioned is that our observations do not always confirm the results achieved by other authors. Kurylcio et al. [7], while reporting the involvement of the LIPA's fundic branches, noted that fundic branches arising from this vessel are present in 50%. In our study we obtained 60%.

Berens et al. [1] reported that branches arising from the PGA do not supply the fundus, but the superior part of posterior gastric wall. On the other hand, Kurylcio et al. [7], Trubel et al. [19] and Vandamme and Bonte [20] note that this source-main artery supplies the posterior portion of the fundus. We found that all the PGA fundic branches detected perforate the posteromedial fundic quadrant.

Pitynski et al. [12] found branches originating from the SPA as a source of arterial vascularisation of the posterior quadrants of the fundus. In our study we also observed that all the SPA fundic branches supply posterior fundic quadrants, but two thirds of them participated in perforation of the posteromedial quadrant.

The above discussion concludes that, apart from a lack of comprehensive studies on the arterial vascularisation of the fundic branches, there are differences between the results obtained at our labo-

ratory and investigations carried out elsewhere. Research into the fundic branches should therefore be continued in order to increase knowledge of the anatomy of the fundus. Some additional aspects, such as the relation of the origins of different fundic branches to ligaments presented in this region or some of the morphometric features of the source arteries that form the origin of the branches studied, should also be examined. This could enhance the clinical importance of the results of the research described in this article.

Our study revealed the presence of fundic branches directly perforating the gastric fundus and their crucial morphometric features. This is only one of the sources of the arterial supply of the stomach besides the arterial intraparietal gastric network. The study was also a reminder that fundic branches can arise not only from coeliac trunk and its branches but also from the LIPA and LMSA. Our study showed that fundic branches most often perforate the posterior quadrants of the gastric fundus.

ACKNOWLEDGMENTS

The study was supported by a scholarship for PhD study. I would like to thank especially Mr Pawel Krajewski MD, PhD, Head of the Department of Forensic Medicine of the Medical University of Warsaw, for supervising the progress of the study described.

REFERENCES

1. Berens AS, Aluisio FV, Colborn GL, Gray SW, Skandalakis JE (1991) The incidence and significance of the posterior gastric artery in human anatomy. *J Med Assoc Ga*, 80: 425–428.

2. Brown JR, Derr JW (1952) Arterial blood supply of human stomach. *Ama Arch Surg*, 64: 616–621.
3. DiDio LJ, Christoforidis AJ, Chandnani PC (1980) Posterior gastric artery and its significance as seen in angiograms. *Am J Surg*, 139: 333–337.
4. Hayes N, Waterworth PD, Griffin SM (1994) Avulsion of short gastric arteries caused by vomiting. *Gut*, 35: 1137–1138.
5. Helm HM (1915) The gastric vasa brevia. *Anatom Record*, 9: 637–645.
6. Kimbel KH, Kinzlmeier H, Henning N (1954) Studies on gastric circulation. I. Experiments with radiophosphorus. *Gastroenterologia*, 82: 317–330.
7. Kurylcio L, Metera A, Modrzewski Z, Wilgoszynski A (1970) Arteries of the gastric fundus in man. *Folia Morphol*, 29: 173–179.
8. Levasseur JC, Couinaud C (1968) Study of the arrangement of the gastric arteries. *Surgical problems. Part II. J Chir*, 95: 161–176.
9. Levasseur JC, Couinaud C (1968) Study of the arrangement of the gastric arteries. *Surgical problems. Part I. J Chir*, 95: 57–58.
10. Liu YF (1982) Regional anatomy of the posterior gastric artery and vein and its importance in surgery. *Zhonghua Wai Ke Za Zhi*, 20: 520–522.
11. Lunderquist A (1974) Pharmacangiography on the left gastric artery in oesophageal varices. *Acta Radiol Diagn*, 15: 157–160.
12. Pitynski K, Skawina A, Lipczynski W, Polakiewicz J, Walocha J (1996) The posterior gastric and superior polar arteries in human fetuses. *Folia Morphol*, 55: 43–49.
13. Power C, Maguire D, McAnena OJ (2000) A technique for dealing with the short gastric vessels during gastric surgery. *Eur J Surg Oncol*, 26: 80–81.
14. Sow ML, Diop M, Morin A (1995) The arteries of the stomach. *Bull Assoc Anat*, 79: 33–40.
15. Suzuki K, Prates JC, DiDio LJ (1978) Incidence and surgical importance of the posterior gastric artery. *Ann Surg*, 187: 134–136.
16. Swanstrom LL, Pennings JL (1995) Laparoscopic control of short gastric vessels. *J Am Coll Surg*, 181: 347–351.
17. Takeda Y (1971) Topographic studies on the a. polaris superior of the human spleen. *Nippon Ika Daigaku Zasshi*, 38: 107–116.
18. Trubel W, Rokitansky A, Turkof E, Firbas W (1988) Correlations between posterior gastric artery and superior polar artery in human anatomy. *Anat Anz*, 167: 219–223.
19. Trubel W, Turkof E, Rokitansky A, Firbas W (1985) Incidence, anatomy and territories supplied by the posterior gastric artery. *Acta Anat (Basel)*, 124: 26–30.
20. Vandamme JP, Bonte J (1988) The blood supply of the stomach. *Acta Anat*, 131: 89–96.