

Morphology of root canals in adult premolar teeth

T.K. Różyło¹, M. Miazek¹, I. Różyło-Kalinowska¹, F. Burdan²

¹Department of Dental and Maxillofacial Radiology, Medical University of Lublin, Poland

²Experimental Teratology Unit of the Department of Human Anatomy, Medical University of Lublin, Poland

[Received 18 February 2008; Accepted 13 August 2008]

The aim of the present study was to examine the morphology of root canals in premolar teeth with completely formed root apices. The material consisted of 139 extracted premolar teeth, including 83 first premolars (59.7%) and 56 second premolars (40.3%). Maxillary teeth made up 64% of the material and mandibular teeth 36%. In order to measure the actual root canal length an endodontic instrument was inserted into the root canal (in teeth with a single root canal this was instrument no. 25 and in teeth with two or three root canals no. 20) until its tip was visible in the anatomical foramen. The silicone limit was fixed at a reference point on the dental crown, and after removal of the instrument the real length was read using an endodontic ruler. The results were presented using descriptive statistical measures (mean, maximum, minimum, median value and quartiles). In order to compare mean values of root canal lengths the z test was used. Of the first maxillary premolars, 91% had two root canals and 9% had three root canals. As far as the second upper premolars are concerned, 14.7% were teeth with single root canals while as many as 85.3% were teeth with two root canals. The majority of the first lower premolars (89.3%) had one root canal and 10.7% of these teeth had two root canals. Most of the second lower premolars (68.2%) had a single root canal, while the remaining 31.8% had two root canals. None of the mandibular premolars examined had three root canals. (Folia Morphol 2008; 67: 280–285)

Key words: premolar teeth, root canals, root canal length

INTRODUCTION

Correct diagnosis of root morphology and proper determination of the working length of root canals are of utmost importance in the endodontic treatment of teeth and have a considerable impact on the success of this treatment [1, 3, 4, 15, 18]. All root canals must be tightly sealed in order to eliminate the possibility of bacterial growth in the unfilled spaces, which usually compromises the result of an endodontic procedure and leads to the development of periapical inflammatory lesions [3, 4].

The majority of dental roots have one root canal. Only in mesial roots of the lower molars there are generally two root canals. If during dental development the epithelial sheath of Hertwig is disrupted or folded, supernumerary roots and accessory root canals may be formed. Odontogenesis is overall very sensitive to numerous exogenic and endogenic factors, such as diet and fluoride intake, that may modify tooth-bud growth in maturation, thus resulting in anatomical variations in dental morphology [10–12]. However, there have been many

conflicting observations. For example, according to Glenn et al. [8], the development of enamel organ and dental papilla was more advanced in human foetuses whose pregnant mothers took fluoride tablets than in controls. On the other hand Appleton [2] stated that a fluoridated diet in weaning rats caused a high degree of irregularity in the predentine and unmineralised spaces in the dentine. On the other hand Maciejewska and Adamowicz-Klepalska [10, 11] observed no disturbances in the predentine as a result of a high concentration of sodium fluoride in drinking water.

The deposition of secondary dentine may lead to changes in root canals after the end of their development. The shape and dimensions of already formed root canals may change; the pulp cavity is then reduced, pulp horns recede and root canals become narrowed. On the other hand the superposition of cementum on the dental apex leads to narrowing of the apical foramen as well as of the anatomical foramen [4, 17].

According to Weine et al. [18] there are different configurations of canals in a single dental root:

- type I: a single root canal ending with an apical foramen;
- type II: two root canals ending with a single apical foramen;
- type III: two root canals ending with two separate apical foramina;
- type IV: one root canal, which after furcation, ends with two apical foramina.

Yoshioka et al. [19] supplemented this classification with type V to describe a root with more than two root canals.

Apart from the main root canal (ending with an anatomical foramen) lateral and accessory canals are also encountered. The lateral canals originate from the main root canal and terminate in dentine with a dead end or with an accessory foramen in the periodontal membrane. Accessory canals stem from

Table 1. The distribution of the examined teeth according to localisation

Quadrant		Number of teeth		Percentage (%)	
1	Maxilla	42	89	30.2	64.0
2		47		33.8	
3	Mandible	25	50	18.0	36.0
4		25		18.0	
Total		139		100.0	

Quadrant 1 — upper right; Quadrant 2 — upper left; Quadrant 3 — lower left; Quadrant 4 — lower right

the pulp chamber and terminate in an accessory foramen in the periodontal membrane at different levels of the root [3, 4, 19]. The appearance of supernumerary root canals following deposition of secondary dentine is observed mostly in root canals that are tapered in the midline, and their shapes resemble a “biscuit” (with an isthmus in the middle). Deposits of dentine located in the area of the isthmus may partially or totally divide a single root canal into two separate canals, ending in a common apical foramen or two different apical foramina [4].

The aim of the present study was to examine the morphology of root canals in premolar teeth with completely formed root apices.

MATERIAL AND METHODS

The material consisted of 139 extracted premolar teeth, including 83 first premolars (59.7%) and 56 second premolars (40.3%). All the teeth studied were collected from Polish patients of Caucasian origin. Maxillary teeth made up 64% of the material and mandibular teeth 36%. The distribution of the teeth studied according to their localisation in quadrants is presented in Table 1, while the distribution, with the localisation and the number of the teeth taken into account, is shown in Table 2.

After the extraction, tooth number, the age and gender of the patient and the indications for extraction

Table 2. The distribution of the examined teeth according to the localisation in the dental arch and tooth type

Quadrant		Tooth type				Total	
		First premolars		Second premolars			
1	Maxilla	31	55	11	34	42	89
2		24		23		47	
3	Mandible	15	28	10	22	25	50
4		13		12		25	
Total		83		56		139	

Quadrant 1 — upper right; Quadrant 2 — upper left; Quadrant 3 — lower left; Quadrant 4 — lower right

Table 3. The distribution of the examined teeth according to tooth type and the number of root canals

Tooth type	No. of root canals			Total
	1	2	3	
First premolar	25	53	5	83
Second premolar	20	36	0	56
Total	45	89	5	139

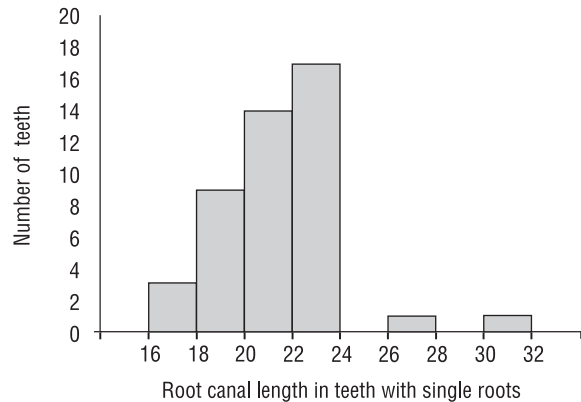
were noted for each tooth. The majority of the teeth were extracted because of orthodontic indications and only some were extracted because of disease of the pulp, periodontal disease or for prosthetic reasons. After extraction the teeth were stored in a physiological saline solution. All the teeth qualified for the present study had a preserved clinical crown and completely formed apices.

In order to measure the actual root canal length an endodontic instrument was inserted into the root canal until its tip was visible in the anatomical foramen. In teeth with a single root canal this was instrument no. 25 and in teeth with two or three root canals it was no. 20. The silicone limit was fixed on a reference point on the dental crown, and after removal of the instrument the real length was read using an endodontic ruler.

The results were presented using descriptive statistical measures (mean, maximum, minimum, median value and quartiles). In order to compare the mean values of root canal lengths the z test was used.

RESULTS

Of the teeth examined a majority, 89 (64.0%), were teeth with two root canals. There were 45 teeth with a single root canal (32.4%). In contrast, only 5 teeth (3%) had three root canals (Table 3).

**Figure 1.** Histogram of root canal length of teeth with single root canals.

The prevalence of two root canals was high in both the first premolars (53 teeth, 38.1%) and the second premolars (36 teeth, 25.9%). Three root canals were detected only in first premolars (3.6 teeth, 5%) (Table 3).

Teeth with two root canals were more frequent in the maxilla (the upper left quadrant (41 teeth, 29.5%) and the upper right quadrant (38 teeth, 27.3%). In the mandible premolars with a single root canal were more common. All the teeth with three root canals were located in the maxilla (Table 4).

Mean root canal length in teeth with single roots was 21.22 ± 2.29 mm (Fig. 1); in buccal canals of teeth with two root canals it amounted to 20.96 ± 1.62 mm (Fig. 2) and the palatal/lingual canals measured on average 19.95 ± 1.8 mm (Fig. 3). Similarly, minimum, median and maximum values were also the highest for the root canals of teeth with single roots and the lowest for palatal/lingual canals of teeth with two or three root canals. A detailed distribution of root canal lengths is presented in Table 5. There was no statistically significant difference between root canal lengths of teeth

Table 4. The distribution of the examined teeth according to localisation in the dental arch and the number of root canals

Quadrant		Number of root canals						Total	
		1		2		3			
1	Maxilla	2		38		2		42	89
2		3	5	41	79	3	5	47	
3	Mandible	19		6		0		25	50
4		21	40	4	10	0	0	25	
Total		45		89		5		139	

Quadrant 1 — upper right; Quadrant 2 — upper left; Quadrant 3 — lower left; Quadrant 4 — lower right

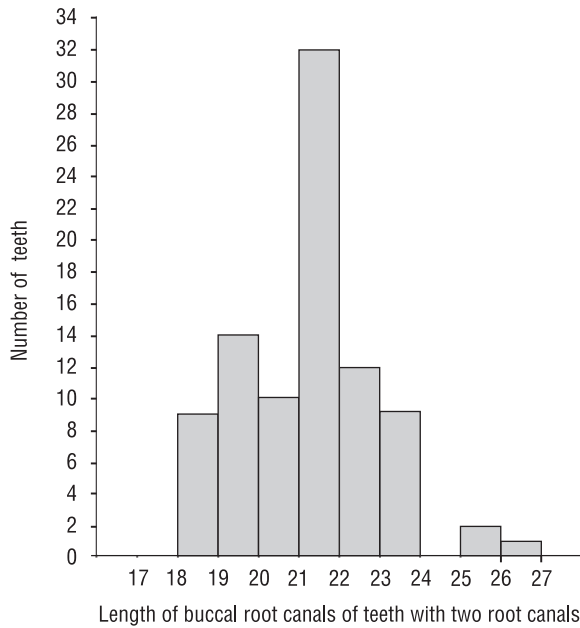


Figure 2. Histogram of lengths of buccal root canals of teeth with two root canals.

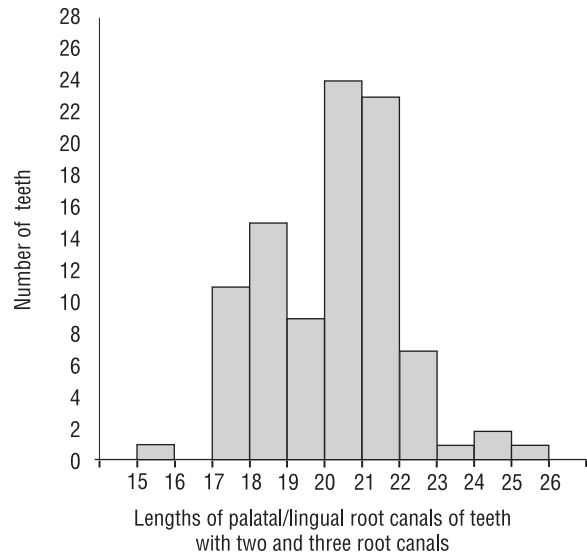


Figure 3. Histogram of lengths of palatal/lingual root canals of teeth with two and three root canals.

Table 5. Basic characteristics of the measurements of root canal lengths

Characteristics	Type of root canal		
	Root canals of teeth with single root canals	Buccal canals of teeth with two root canals	Palatal/lingual canals of teeth with two or three root canals
Number of teeth	45	89	94
Mean depth	21.22	20.96	19.95
Standard deviation	2.29	1.62	1.80
Minimum	17.00	18.00	15.00
Lower quartile (25%)	19.80	19.80	18.50
Median value (50%)	21.50	21.00	20.00
Upper quartile (75%)	22.50	22.00	21.00
Maximum	30.00	26.00	25.00

with single root canals and buccal canals of teeth with two root canals ($p = 0.4486 > 0.05$). Palatal/lingual root canals were shorter than root canals of single teeth and buccal canals of teeth with two root canals. These differences were statistically significant: $p = 0.0005 < 0.05$ and $p = 0.0001 < 0.05$, respectively.

DISCUSSION

The results of recent studies testify to the fact that numerous deviations from the generally accepted anatomical norms frequently occur [13]. Apart

from the main root canal, dental roots may possess supernumerary root canals. There may be furcation of the main root canal and root canals that occur separately or even appear after the end of dental development as a result of the deposition of secondary dentine [4]. If a supernumerary tooth is not diagnosed, it may result in pain, inflammatory peri-apical lesions or other complications [15].

Authors have differed in their assessment of the prevalence of supernumerary roots in different types of teeth. In the literature discrepancies related to

the lower incisors and molars are mainly described [16]. Our own observations have led to the expectation of supernumerary root canals if the root canal aperture is not located centrally in the pulp cavity.

The lower incisors are commonly believed to be teeth with a single root canal. In fact 75% have a single root canal and 24% two root canals [4]. According to Bardelli et al. [5] two root canals occur in 29% of central incisors. According to Japanese endodontists, about 12.5% of these teeth have two root canals [13].

The roots of the lateral incisors are usually flattened in the mesiodistal direction, which results in the pulp chamber being oval in shape. This anatomy often determines an increase in the number of root canals, and about 60% of these teeth have one canal with the remaining 40% having two canals, labial and lingual [3, 4]. According to Ahlstrand [1] two root canals occur in only 20% of cases.

The first upper molar normally has three root canals (mesial buccal, distal buccal and palatal). An accessory root canal is usually found in the mesial buccal root. According to the literature, the prevalence of this root canal varies from 5 to 56% [3, 4, 16].

The first and second lower molars are teeth with three root canals (two mesial canals — a buccal and a lingual one — as well as a distal one). The supernumerary canals in general occur in a distal root [3]. Four root canals may be found in the first lower molar in 25–29% of cases [4]. The discrepancies are higher for the second lower molar, as the prevalence of four root canals is estimated to range from 7% to 42% of cases [4]. The cross-sections of the root canals of molars can be divided into one round canal, one oval canal, one elongated canal and one elongated canal with an isthmus [7].

The third molars are often retained and impacted, while their morphology and localisation are very variable [14]. Supernumerary molars may also assume different shapes, from normal morphology to teeth that are rudimentary in shape and smaller in size [6].

The crown and pulp cavity of maxillary premolars is flattened in the mesiodistal direction. The tooth has two cusps (palatal and buccal) and two corresponding pulp horns, the buccal horn being located higher than the palatal. The pulp cavity has a narrowing in the middle part, which results in a shape similar to a biscuit on the transversal cross-section. In 80% of cases the first maxillary premolars have two roots, while in about 18% they have only one root. Most often (95%) even in one root they have two root canals, a palatal and a buccal,

the latter being generally thinner and more curved. In 2% of cases the tooth has three roots and three root canals, two buccal (mesial and distal) and one palatal [3, 4]. The second maxillary premolar usually has one root (85%) and one root canal. The shape of the pulp cavity transversal cross-section is then oval and the root canal aperture is located centrally. In about 14% of cases the tooth has two roots and two root canals (buccal and palatal) and if so, the cross-section of the crown resembles a biscuit, as in the first premolar. In about 1% of cases the tooth has three roots and three root canals, buccal mesial, buccal distal and palatal [3, 4].

The shape of the crown of the mandibular premolars is more circular. In almost 75% of cases the first mandibular premolar has a single root with a single root canal. However, furcation of the root canal quite frequently occurs in the periapical area. In about 25% of cases the first premolar has two root canals (lingual and buccal), while in just 1% of these teeth three canals may be found [3, 4].

The second mandibular premolar usually contains two pulp horns, the buccal one located higher than the lingual one. In the majority of cases (98%) a single root with a single root canal (89%) is detected. About 10% of these teeth have two canals, buccal and lingual [3, 4].

In our own material, consisting of 139 premolars, extracted mainly for orthodontic reasons (so that the teeth were generally sound and all had intact clinical crowns), the results were as follows:

- 91% of the first upper premolars had two root canals and 9% had three root canals;
- of the second upper premolars, 14.7% were teeth with single root canals; while as many as 85.3% were teeth with two root canals;
- the majority of the first lower premolars (89.3%) had a single root canal and 10.7% of these teeth had two root canals;
- most of the second lower premolars had one root canal (68.2%), while the remaining 31.8% had two root canals.

In comparison with generally accepted anatomical norms [9], there was a much higher prevalence in this material of two root canals in the second upper premolars. In addition, the percentage of second lower premolars with two root canals was greater than usually assumed. The differences observed are probably secondary to the high degree of anatomical variation between the populations examined.

Yoshioka et al. [19] also demonstrated the existence of considerable variety in the number and

configuration of root canals of the first lower premolars. According to this study 15.1% of these teeth have two root canals and 4.3% more than two root canals. In our own material there were no lower premolars with three root canals. According to Duda et al. [7] there is more than one root canal in about 30.7% of the first lower premolars.

CONCLUSIONS

1. Of the first maxillary premolars 91% had two root canals and 9% three root canals.
2. As far as the second upper premolars are concerned, 14.7% were teeth with single root canals and as many as 85.3% teeth with two root canals.
3. The majority of the first lower premolars (89.3%) had one root canal, and 10.7% of these teeth had two root canals.
4. Most of the second lower premolars had a single root canal (68.2%), while the remaining 31.8% had two root canals.
5. None of the mandibular premolars examined had three root canals.

REFERENCES

1. Ahlstrand W (1998) Rozmyślenia nad „trudnym” kanałem. *Mag Stomat*, 4: 52–55.
2. Appleton J (1994) Formation and structure of dentin in the rat incisor after chronic exposure to sodium fluoride. *Scan Microsc*, 8: 711–719.
3. Arabska-Przedpeńska B (1996) Endodoncja. Med Tour Press, Warszawa.
4. Barańska-Gachowska M (2004) Endodoncja wieku rozwojowego i dojrzałego. Wyd. Czelej, Lublin.
5. Bardelli M, Bruno E, Rossi G (1990) Anatomy of lower incisor root canals. *G Ital Endod*, 4: 34–37.
6. Das S, Suri RK, Kapur V (2005) A supernumerary maxillary tooth: its topographical anatomy and its clinical implications. *Folia Morphol*, 63: 507–509.
7. Duda M, Skoczek A, Kowal B, Komorek A (2004) Morphology of root canal cross-sections of resected roots of first and second lower molars. *Ann Univ Mariae Curie Sklodowska Med (Sectio D)*, 54: 54–60.
8. Glenn FB, Glenn WD, Burdi AR (1997) Prenatal fluoride for growth and development: Part X. *J Dent for Children*, 64: 317–321.
9. Lombart B, Michonneau JC (2005) Classification of premolars as a function of root anatomy and statistics. *Rev Belge Med Dent*, 60: 310–321.
10. Maciejewska I, Adamowicz-Klepalska B (2000) Effects of diet and fluoride on early phases of odontogenesis in rats. *Folia Morphol*, 59: 37–42.
11. Maciejewska I, Adamowicz-Klepalska B (2000) Influence of low and high doses of fluoride on tooth germ development in rats. *Folia Morphol*, 59: 307–310.
12. Maciejewska I, Spodnik JH, Domaradzka-Pytel B, Sidor-Kaczmarek J, Bereznowski Z (2006) Fluoride alters type I collagen expression in early stages of odontogenesis. *Folia Morphol*, 65: 359–366.
13. Miyashita M, Kasahara E, Yasuda E, Yamamoto A, Sekizawa T (1997) Root canal system of the mandibular incisor. *J Endod*, 23: 479–484.
14. Różyło-Kalinowska I, Budan F, Marchut T (2003) Morphology of third molar teeth with incompletely formed apices on the basis of panoramic radiographs. *Folia Morphol*, 62: 113–118.
15. Różyło-Kalinowska I, Jurkiewicz-Mazurek M, Niedzielska A, Jaroszewicz E (2005) Najczęstsze błędy jatrogenne popełniane podczas leczenia endodontycznego w materiale własnym. *Twój Przegląd Stomat*, 9: 52–55.
16. Seidberg BH, Altan H, Guttuso J, Suson M (1973) Frequency of two mesiobuccal root canals in maxillary permanent first molars. *J Am Dent Assoc*, 87: 852–856.
17. Stein TJ, Corcoran JF (1990) Anatomy of the root apex and its histological changes with age. *Oral Surg Oral Med Oral Pathol*, 69: 238–242.
18. Weine FS, Healey HJ, Gerstein H, Evanson L (1969) Canal configuration in the mesiobuccal root of the maxillary first molar and its endodontic significance. *Oral Surg Oral Med Oral Pathol*, 28: 419–425.
19. Yoshioka T, Villegas JC, Kobayashi C, Suda H (2004) Radiographic evaluation of root canal multiplicity in mandibular first premolars. *J Endod*, 30: 73–74.