

The anatomy of the human thyroid veins and its surgical application

N. Wafae, K. Hirose, C. Franco, G.C. Wafae, C.R. Ruiz, L. Daher, O.C. Person

Departments of Morphology of the Universidade de Taubaté, Centro Universitário São Camilo and of the Universidade Federal de São Paulo, Brazil

[Received 10 April 2008; Accepted 8 August 2008]

The present study was motivated by the importance of the thyroid veins in surgery in the anterolateral cervical region, particularly in tracheostomies, the need for information on modern diagnostic imaging techniques and the lack of specific publications on the subject. The research was performed on 30 adult human specimens by means of dissection and measurement. The superior thyroid vein was constant, single on both sides (83.3%), with its termination (87.1%) at the internal jugular vein (97.2%), either isolated (29.4%) or with other veins, mostly the lingual vein (52.1%), and was located between 1.0 and 2.5 cm below a plane that passes the upper margin of the hyoid bone. The medial thyroid vein, when present, was not constant (43.3%), was single (96.1%), terminated in the internal jugular vein and was located between 2.0 and 4.0 cm from the mid-sagittal line (84.6%). The inferior thyroid vein was constant (96.7%) and varied in number, with one (62.1%), two (27.6%) or even five occurring, and was formed by the confluence of two primary branches (78.6%) as a result of the abundance of anastomoses coming from the lower and medial parts of the gland. The number of terminations corresponded to the number of veins, at the level of the 5th to 8th rings in 36.9%, of the 9th to 10th rings in 34.8% and of the 11th to 14th rings in 28.3%, and occurred in the right brachiocephalic vein (26.1%), in the left brachiocephalic vein (60.9%) or in both veins (13.0%). (Folia Morphol 2008; 67: 221–225)

Key words: anatomy, thyroid veins, morphology, venous system

INTRODUCTION

Knowledge of the anatomy of the veins in the anterolateral cervical region, particularly the thyroid veins, is important because of its application in thyroid [5], parathyroid and laryngeal surgery, in the transposition of myocutaneous flaps for reconstructions [13] and, particularly, in tracheostomies [2, 4, 9].

The frequency of indications for tracheostomy in emergency rooms and intensive care units is increasing and thus the occurrence of haemorrhagic events is increasing likewise. Krausen [4] reports that many surgeons have been dismayed at the occur-

rence of massive haemorrhages caused by accidental section of the inferior thyroid vein during emergency or even routine tracheostomies. Buguet-Brown et al. [2] report the case of cataclysmic acute haemorrhage caused by lesion of the inferior thyroid vein in percutaneous tracheostomy. Muhammad et al. [8] report 4.8% unsuccessful tracheostomies where haemorrhages were caused by vascular lesions and recommend the use of ultrasonography to assess anatomical variations of these vessels.

Krausen [4] found the pattern given in treatises for the anatomy of the thyroid veins in only three

out of ten dissections, and reports confirm the surgical accidents caused by variations [5, 9]. The present research finds its justification in the lack of specific publications on variations in the anatomy of these veins, the paucity of knowledge of significant anatomical facts [6], the need for descriptions to assist diagnostic imaging [1, 7] and the importance of the subject for surgical applications.

MATERIAL AND METHODS

The present research was conducted using 30 adult human specimens between 30 and 55 years of age, 24 male and 6 female. These were all from the laboratories of Human Anatomy of the University of Taubate and the Federal University of São Paulo (Brazil) and were fixed in 10% formalin solution.

The specimens were placed for dissection in dorsal recumbency with the head lengthwise. The skin, the subcutaneous tissue, the platysma and the cervical fascia were incised longitudinally from the centre of the mental region to the centre of the jugular incision of the sternum and laterally in the inner margin of the mandible up to the ear and along the clavicle up to the acromion. When the thyroid gland was exposed, identification was initiated and dissection of the thyroid veins was performed up to their terminations in veins with a larger diameter. For complete dissection of the inferior thyroid veins, the sternum, the upper ribs and the clavicle were reduced.

Measurements were performed with a flexible ruler using the following references:

- the vertical distance between the termination of the superior thyroid vein and the transverse plane passing the upper margin of the hyoid bone;
- the horizontal distance between the sagittal plane passing the termination of the medial thyroid vein and its intersection with the mid-sagittal line;
- a count of the tracheal ribs from the junction of the trachea with the cricoid cartilage.

The χ^2 test was used in the statistical analysis in order to assess the correlation of the variables.

RESULTS

Superior thyroid vein

The superior thyroid vein was present in all samples and on both sides (100%) and was single (83.3%) or double (16.7%) (Fig. 1). It was formed by the confluence of two branches, termed primary branches, in 80.1% of samples or more than two branches, termed secondary branches, in 19.9%.

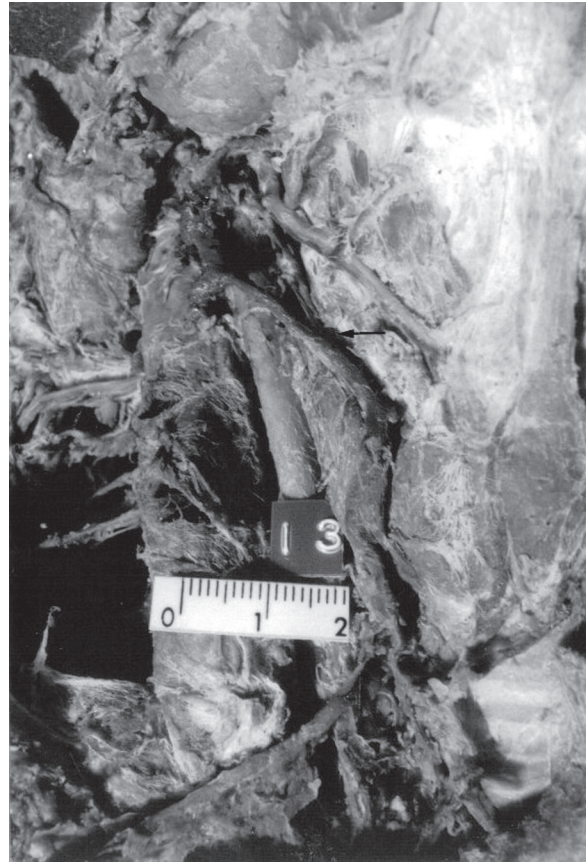

Figure 1. Superior thyroid vein, single, with a double termination in the internal jugular vein.

Using only macroscopic dissection, we noticed that the original branches came only from the upper part of the gland in 75%, from the upper and medial parts in 18.3% and the upper, medial and lower parts in 6.7%.

Its termination in another vein could be single (87.1%) or by more branches (12.9%), and in relation to a plane passing the upper margin of the hyoid bone it occurred below in 85.7% and above in 14.3%. In this case there was a significant difference in relation to the side ($X^2 = 5.3$). By performing the measurement of this distance we noticed that it could occur up to 2 cm (64.9%) or even 2 cm (35.1%). The termination occurred at the internal jugular vein (97.2%) and could be single when it ended isolated (29.4%) or multiple when combined with other veins (70.6%).

Before its termination in the internal jugular vein the superior thyroid was united with the lingual vein in 35.4%, with the retromandibular vein in 6.2%, with the retromandibular and facial veins in 4.2% and with the facial vein in 2.1%.



Figure 2. Medial thyroid vein, double, with a direct termination in the internal jugular vein.

Medial thyroid vein

The medial thyroid vein, located laterally to the thyroid gland just above the inferior thyroid artery, was present in only 43.3% of the dissected sides. It was present bilaterally in 7 cases (23.3%), on the right side while absent on the left in 7 cases (23.3%) and absent on the right side while present on the left in 5 cases (16.7%). It was formed by the confluence of primary branches (88.9%) or secondary branches (11.1%). It drained the medial part of the gland (70.4%), the medial and lower parts (22.2%) or the upper, medial and lower parts (7.4%).

The termination of the internal jugular vein was single and the distance in relation to the medial sagittal plane was within 3 cm in 44.4% and more than 3 cm away in 55.6%, on the right in 81.5% or associated with other veins in 18.5% (Fig. 2).

On its way the vein crossed the recurrent laryngeal nerve (96.1%) and the common carotid artery (100%).

Inferior thyroid vein

The inferior thyroid vein was present in 96.7% of the samples. The number of independent veins varied: one (62.1%), two (27.6%), three (3.4%), four

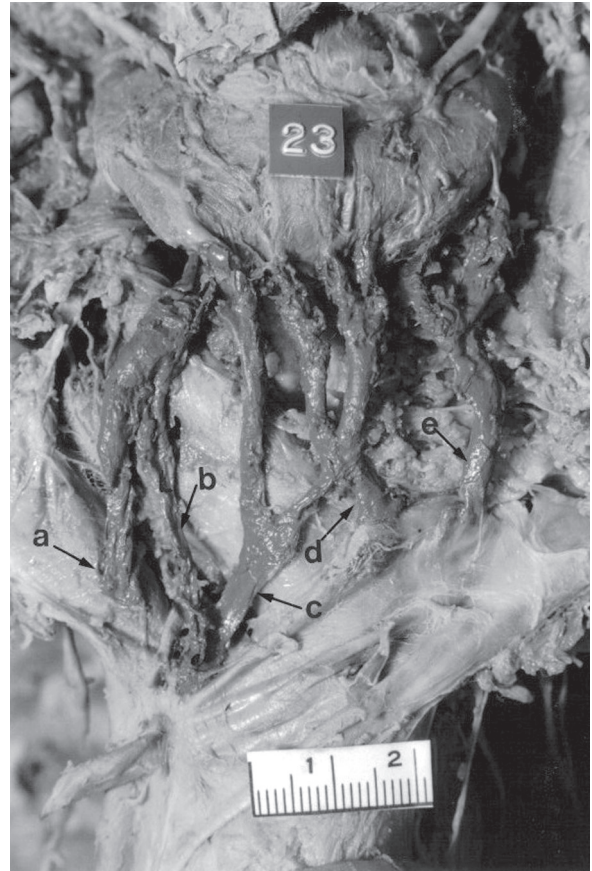


Figure 3. Inferior thyroid vein, five; direct termination in the right brachiocephalic vein (a), in the confluence of the right and left brachiocephalic vein (b, c), in the left brachiocephalic vein (d, e).

(3.4%) or five (3.4%) (Fig. 3). These were formed by the confluence of two primary branches in 78.6% of samples or more than two secondary branches in 21.4%. We noted that the originating branches came only from the lower part of the gland in 34.1%, from the upper and medial parts in 58.7% or from the medial part 6.9%.

The number of terminations corresponds to the number of veins, and in relation to the tracheal rings we noticed that it occurs at the level of the 5th to 8th rings in 36.9%, of the 9th to 10th rings in 34.8% and of the 11th to 14th rings in 28.3%. The terminations occur in the right brachiocephalic vein (26.1%), in the left brachiocephalic vein (60.9%) or both (13.0%) (Fig. 3, 4).

DISCUSSION

Superior thyroid vein

The superior thyroid vein was found in all samples and on both sides, confirming the references



Figure 4. Inferior thyroid vein, double, with a termination in the right brachiocephalic vein (a) and in the left brachiocephalic vein (b).

cited in the literature studied [3, 12]. Chevrel et al. [3] report cases of two terminations but do not state whether the veins are independent; Remmert et al. [12] report that in 20% of cases this vein is not single. In our study we found two independent veins in their origin, path and termination in 16.7%. Dissection only gave us access to the macroscopically visible drainage surface, which we confirmed to be the upper part of the gland. However, by means of anastomoses it is possible to drain the medial part (25.0%) and the lower part (6.7%).

Through analysis of the termination we found the greatest number of variations both in the medical literature and in our dissections. Chevrel et al. [3] mentioned the possibility of two terminations, and in our study we found two or three terminations at different points (12.9%).

We believe it would be interesting for surgeons to examine the location of this termination, using as a reference point a plane that passes the upper margin of the hyoid bone. We found that the termination occurs more often below this plane (85.7%), at a distance of between 10 and 25 mm. For Chevrel et al. [3] the termination may occur directly in the internal jugular vein (10%), or through the linguofacial trunk (56%) or even in both (33%). For Remmert et al. [12] the vein joins the facial vein in 43% of cases and in other cases goes directly to the internal jugular vein. Oszukowski and Kosinski [11] report the junction with the lingual and facial veins in 44% and Shima et al. [13] found an association of the three veins in 46.6% and a combination with the facial vein in 6.9%.

In our study we noticed two types of termination: directly in the internal jugular vein (29.4%) and in association with other veins (70.6%): with the

lingual vein (52.1%), with the linguofacial trunk (35.4%) and with the facial vein (2.1%). In two cases the superior thyroid vein deepens toward the vertebral column to join the vertebral vein.

Medial thyroid vein

Chevrel et al. [3] report its presence in 29%, while for Shima et al. [13] the frequency is 55.2%. Our research demonstrated its presence in 43.3% of the sides, which was half-way between the findings of Chevrel et al. [3] and those of Shima et al. [13]. This vein, when present, is single. In one case we found two veins on the same side.

Drainage of the medial part of the thyroid gland is performed by this vein, but the upper and lower lateral parts also participate in the process. We tried to establish points of reference for the location of its termination in relation to the mid-sagittal line located at a distance of between 2 and 4 cm. This termination occurs directly in the internal jugular vein, but in 18.5% of cases it occurs in association with another vein in the region. Oszukowski and Kosinski [10] found this termination in one case (1.7%) at the vertebral vein. Surgeons should keep in mind that the vein crosses the common carotid artery and the recurrent laryngeal nerve. However, in one case it passed behind the recurrent laryngeal nerve.

Inferior thyroid vein

The inferior thyroid vein was always present for Krausen [4], Lazaro da Silva et al. [5] and Moriggl and Pomaroli [6]. Using computerised tomography, Belli et al. [1] found this artery in 90% of cases. In our study this vein was present in 96.7%. Chevrel et al. [3] do not mention any absences, so we conclude that they found it in all cases.

There were differences in the number of veins found by these authors:

- Krausen [4] — one (10%), two (10%), three (40%), four (20%), five (20%);
- Lazaro da Silva et al. [5] — one (81.5%) and two (18.5%);
- Belli et al. [1] — one (38%), two (33%), three (16%), four (3%);
- Moriggl and Pomaroli [6] — one (60.7%), two (30.3%), three (8.4%), four (0.6%).

Our findings were similar to those of Moriggl and Pomaroli [6] and were as follows: one vein (62.1%), two veins (27.6%), three veins (3.4%), four veins (3.4%) and five veins (3.4%). Chevrel et al. [3] distinguished between the inferior thyroid vein and the medial thyroid vein, which made it difficult to compare results.

Like Lazaro da Silva et al. [5], we also studied the number and types of branches that were the sources of the vein, obtaining similar results. Concerning the surface of drainage we noticed the prevalence of the medial and lower parts on both sides.

We found no comparison parameters to locate the level of termination of this vein. We therefore established a relationship with the tracheal rings, the most frequent location occurring between the 7th and 12th rings (80.4%).

The points of termination of this vein, considered of great importance by Moriggl and Pomaroli [6], were classified into three groups:

- a) exclusive drainage in the brachiocephalic vein (right: 6%, left: 47%, junction: 20.2%);
- b) combination of the possibilities cases in the brachiocephalic veins (right and left: 10.7%, left and junction: 9.5%, right and junction: 1.8%, right, left and junction: 3%);
- c) special cases with supernumerous drainage to other veins of mediastinum [1, 8].

Krausen [4] reports that termination in the left brachiocephalic vein was found in 7 out of 10 dissections, and in one case there was draining into the right brachiocephalic vein. For Chevrel et al. [3] the terminations occur in both the right and the left brachiocephalic veins. For Lazaro da Silva et al. [5] the terminations occur only in the brachiocephalic veins: right, left and junction. Belli et al. [1] confirmed that the termination is varied, but can be summarised as two types: the veins flow in the lower part and form two veins that unite and end in the proximal part of the brachiocephalic vein (60%), or else they do not unite and end respectively in the left brachiocephalic vein and in the junction of the right brachiocephalic vein with the superior vena cava. In our research the terminations occurred in the right brachiocephalic vein (26.1%), in the left brachiocephalic vein (60.9%) or in both (13.0%).

Treatises on anatomy were consulted, but since they did not contain detailed information on this subject, they are not referred to here.

In conclusion, the superior thyroid vein is constant, single, predominantly drains the upper part of the thyroid gland and ends in the internal jugular vein, 1 to 2.5 cm below the plane that passes the upper margin of the hyoid bone, usually together with other veins, mostly the lingual.

The medial thyroid vein is not constant, drains predominantly the medial part of the gland and ends

in the internal jugular vein between 2 and 4 cm from the mid-sagittal line, crossing the recurrent laryngeal nerve and the common carotid artery.

The inferior thyroid vein is constant, varies in number, drains the lower and medial parts of the gland and its termination in the brachiocephalic veins occurs predominantly on the levels between the 7th and the 12th tracheal rings.

REFERENCES

1. Belli AM, Ingram CE, Heron CW, Husband JE (1988) The appearance of the inferior thyroid veins on computed tomography. *Br J Radiol*, 61: 125–127.
2. Buguet-Brown ML, Favier JC, Da Conceição M, Pitti R (2001) Acute severe hemorrhage by a wound of the inferior thyroid vein during percutaneous tracheostomy. *Ann Fr Anesth Reanim*, 20: 304–305.
3. Chevrel JP, Hidden G, Lassau JH, Alexandre JH, Hureau J (1965) Le drainage veineux et lymphatique du corps thyroïde. *J Chir (Paris)*, 90: 445–464.
4. Krausen AS (1976) The inferior thyroid veins. The ultimate guardians of the trachea. *Laryngoscope*, 86: 1849–1855.
5. Lázaro da Silva A, Delorenzo S, Pelaquim AF, Freire MTG, Rezende Neto JB (1989) Anatomia das veias tireóideas inferiores: aplicação cirúrgica. *Arq Bras Med*, 63: 243–246.
6. Moriggl B, Pomaroli A (1992) Das Mündungsverhalten der vena (e) thyroidea (e) inferior (es). *Ann Anat*, 176: 389–393.
7. Muhammad JK, Patton DW, Evans RM, Major E (1999) Percutaneous dilatational tracheostomy under ultrasound guidance. *Br J Oral Maxillofac Surg*, 37: 309–311.
8. Muhammad JK, Major E, Woods A, Patton DW (2000) Percutaneous dilatational tracheostomy: haemorrhagic complications and the vascular anatomy of the anterior neck. A review based on 497 cases. *Int J Oral Maxillofac Surg*, 29: 217–222.
9. Muhammad JK, Major E, Patton DW (2000) Evaluating the neck for percutaneous dilatational tracheostomy. *J Craniomaxillofac Surg*, 28: 336–342.
10. Oszukowski P, Kosinski H (1996) Opening of the middle thyroid vein into vertebral vein in the fetus. *Przegl Lek*, 53: 634–635.
11. Oszukowski P, Kosinski H (1998) The orifice of superior thyroid vein to the internal jugular vein in human fetuses. *Folia Morphol*, 57: 229–232.
12. Remmert S, Majocco A, Gehrking E (1995) Der neurovaskuläre infra-hyoideale muskelfaszienlappen: anatomisch-topographische untersuchung der innervation und gefäßversorgung. *HNO*, 43: 182–187.
13. Shima H, Von Luedinghausen M, Ohno K, Michi K (1998) Anatomy of microvascular anastomosis in the neck. *Plast Reconstr Surg*, 101: 33–41.