

A rare case of bilateral supernumerary heads of sternocleidomastoid muscle and its clinical impact

K. Natsis¹, I. Asouchidou², M. Vasileiou¹, E. Papathanasiou¹,
G. Noussios¹, G. Paraskevas¹

¹Department of Anatomy, Medical School, Aristotle University of Thessaloniki, Greece

²Department of Anesthesiology, G. Papanikolaou Hospital, Exohi, Thessaloniki, Greece

[Received 3 September 2008; Accepted 4 November 2008]

The sternocleidomastoid muscle (SCM) functions as a landmark for physicians such as anatomists, orthopaedic surgeons, neurosurgeons, and anaesthesiologists, who intervene in the minor supraclavicular fossa located at the base of the neck. The variability of SCM anatomy may cause complications while trying to access the vital elements that are located in the minor supraclavicular fossa. This study aims to present a case of supernumerary heads of the sternocleidomastoid muscle and to discuss its clinical significance.

The cervical region of an elderly male cadaver was dissected and the findings were recorded and photographed.

On both sides, the SCM muscle had an additional sternal head, and simultaneously there were three additional clavicular heads, four in total. These additional heads, the sternal and the clavicular, reduced the interval between them causing significant stenosis of the minor supraclavicular fossa.

Sternocleidomastoid muscle variations with regard to the number of its heads are very rare in the literature, but this variation may cause severe complications. The minor supraclavicular fossa is important for anaesthesiologists because of the anterior central venous catheterization approach. Physicians should be aware of this anatomical variation in order to prevent complications. (Folia Morphol 2009; 68, 1: 52–54)

Key words: sternocleidomastoid muscle, heads, supernumerary

INTRODUCTION

The sternocleidomastoid muscle (SCM) is one of the most complex muscles of the body. It is responsible for the mechanical action for the majority of the movements of the head and it is considered to be an accessory muscle for respiration [6]. Normally the SCM arises with two heads: the sternal head, which arises from the upper part of the anterior surface of the manubrium sterni, and the clavicular head, which arises from the superior border and anterior surface

of the medial third of the clavicle. The two heads are both directed upward, separated at their origins by a triangular interval, but gradually they blend into a thick muscle which is inserted into the lateral surface of the mastoid process [11, 14]. The SCM is the most prominent muscle of the anterior and posterior regions of the neck. The two heads of the SCM form, with the clavicle, the minor supraclavicular fossa. The posterior border of the SCM also participates in the formation of the posterior cervical triangle.

Address for correspondence: K. Natsis, Orthopaedic Surgeon, Associate Professor of Anatomy, Department of Anatomy, Medical School, Aristotle University of Thessaloniki, P.O. Box: 300, 54124 Thessaloniki, Greece, tel./fax: +30 2310 999681, e-mail: natsis@med.auth.gr

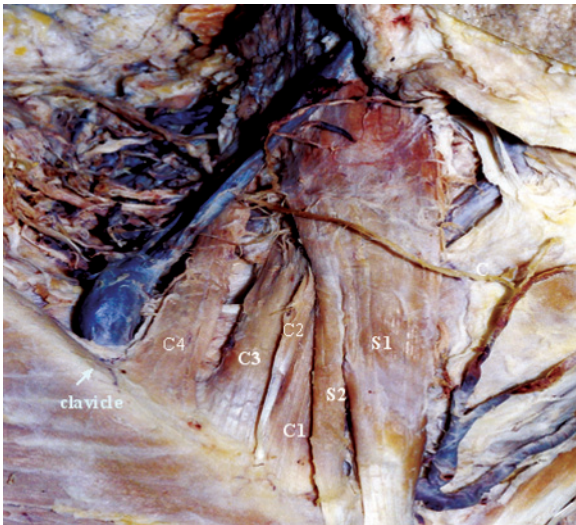


Figure 1. Dissection demonstrating the right side of the neck, showing the sternocleidomastoid muscle; S — sternal head; C — clavicular head; numbers 1–4 indicate the heads.

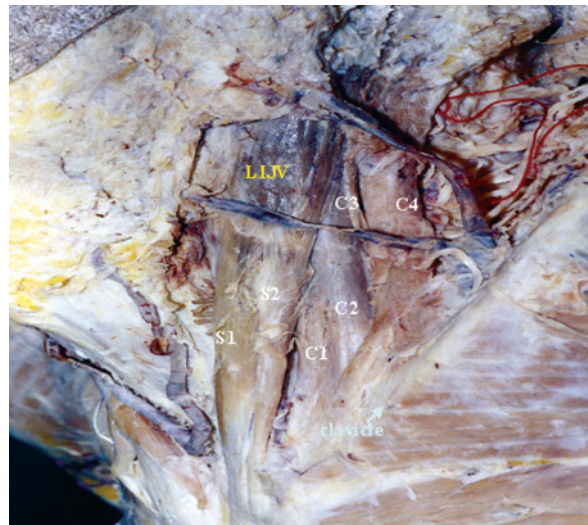


Figure 2. Dissection demonstrating the left side of the neck; S — sternal head; C — clavicular head; numbers 1–4 indicate the heads; LIJV — left internal jugular vein.

The SCM functions as a landmark for physicians such as orthopaedic surgeons, neurosurgeons and anaesthesiologists, who intervene in the minor supraclavicular fossa located at the base of the neck. The minor supraclavicular fossa is formed by the separation of the two heads of the sternocleidomastoid muscle [4, 5, 12]. Variability of SCM anatomy may cause complications while trying to access the vital elements that are located in the minor supraclavicular fossa. For example, damage can be caused to the spinal accessory nerve, and unsuccessful cannulation of the internal jugular vein may also occur. It is of great importance for physicians to have a clear understanding of the anatomy of the SCM and its possible variations in order to avoid inadvertent complications. This study aims to present a case of supernumerary heads of the sternocleidomastoid muscle and to discuss its clinical significance.

MATERIAL AND METHODS

A 72-year-old male cadaver was dissected at the Department of Anatomy of the Medical School of the Aristotle University in Thessaloniki. During the routine anatomy dissection of the cervical region, the skin, the platysma muscle, the lamina of the cervical fascia, the veins, and the superficial nerves were removed in order to reveal the sternocleidomastoid muscle. The findings were recorded and photographed.

RESULTS

During the cadaveric dissection of the head and neck region of a 72-year-old male cadaver we noticed bilateral supernumerary heads of the SCM. On both sides, the

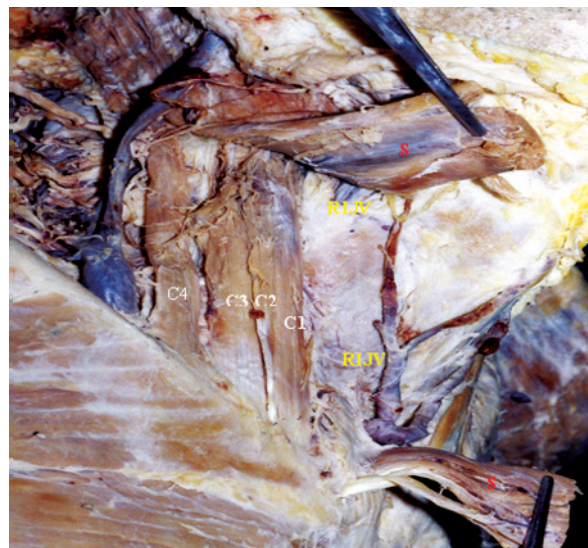


Figure 3. Dissection demonstrating the right side of the neck. The two sternal heads (S) were cut and reflected taken away in order to reveal the right internal jugular vein (RIJV).

SCM muscle had an additional sternal head arising from the manubrium sterni. Simultaneously, there were three additional clavicular heads, four in total, arising from the clavicle. The additional sternal head was lateral to the main sternal head and fused with it close to its insertion to the mastoid process. The additional clavicular heads were located lateral to the main clavicular head. Similar observations were made on both sides (Figs. 1, 2). These additional heads, the sternal and the clavicular, reduced the interval between them causing significant stenosis of the minor supraclavicular fossa (Figs. 2, 3).

DISCUSSION

Sternocleidomastoid muscle variations with regard to the number of its heads are very rare in the literature. There are only a few reports about supernumerary heads of SCM, but all of them present cases of either additional sternal [9, 10] or clavicular heads [3, 10]. Nayak et al. [9] reported the presence of a bilateral additional sternal head of the SCM that was found during the dissection of a 60-year-old male cadaver. Ramesh et al. [10] observed, during the dissection of a cadaver, an additional clavicular head bilaterally. However, the sternal heads were normal on both sides [10]. During the dissection of a nine-month-old infant, Boaro et al. [3] also observed the presence of three clavicular heads, while the sternal head was normal. In our study, the additional heads were observed in the sternal as well as in the clavicular head, bilaterally.

Our findings also revealed that the minor supraclavicular fossa was so narrow that it would be extremely difficult, or even impossible, to locate the internal jugular vein (IJV) and cannulate it. Repeated efforts to cannulate the IJV may result in the formation of a local haematoma [1] or even in severe and life-threatening complications [2, 7, 13]. The minor supraclavicular fossa is important for anaesthesiologists because the anterior central venous catheterisation approach is an anatomically accurate technique [4, 8]. A number of techniques have been described to locate the needle insertion point for the IJV cannulation. However, the anterior central venous catheterisation approach for IJV cannulation is often preferred as it is associated with a lower rate of pneumothorax.

Surgeons, anaesthesiologists, orthopaedics, neurosurgeons, and head and neck surgeons should be aware of this anatomical variation in order to prevent complications. It is furthermore important to realize that during any invasive procedure, a thorough anatomical knowledge of the region is necessary.

REFERENCES

1. Asouhidou I, Natsis K, Asteri T, Sountoulides P, Vlasis K, Tsikaras P (2008) Anatomical variation of left internal jugular vein: clinical significance for an anaesthesiologist. *Eur J Anaesthesiol*, 25: 314–318.
2. Asteri T, Tsagaropoulou I, Vasiliadis K, Fessatidis I, Papavasiliou E, Spyrou P (2002) Beware Swan-Ganz complications. Perioperative management. *J Cardiovasc Surg*, 43: 467–470.
3. Boaro SN, Fragoso Neto R (2003) A topographic variation of the sternocleidomastoid muscle in a just been born children. *Int J Morphol*, 21: 261–264.
4. Botha R, van Schoor AN, Boon JM, Becker JH, Meiring JH (2006) Anatomical considerations of the anterior approach for central venous catheter placement. *Clin Anat*, 19: 101–105.
5. Bruneau M, Cornelius JF, George B (2005) Anterolateral approach to the V2 segment of the vertebral artery. *Neurosurgery*, 57: 262–267.
6. Costa D, Vitti M, de Oliveira Tosello D, Costa RP (1994) Participation of the sternocleidomastoid muscle on deep inspiration in man. An electromyographic study. *Electromyogr Clin Neurophysiol*, 34: 315–320.
7. Kua JS, Tan IK (1997) Airway obstruction following internal jugular vein cannulation. *Anaesthesia*, 52: 776–780.
8. Marino PL (2007) *The ICU Book*. Lippincott Williams & Wilkins, NY, pp: 119–121.
9. Nayak SR, Krishnamurthy A, Sj MK, Pai MM, Prabhu LV, Jetti R (2006) A rare case of bilateral sternocleidomastoid muscle variation. *Morphologie*, 90: 203–204.
10. Ramesh RT, Vishnumaya G, Prakashchandra S, Suresh R (2007) Variation in the origin of sternocleidomastoid muscle. A Case Report. *Int J Morphol*, 25: 621–623.
11. Standring S, Berkovitz BKB, Hackney CM, Ruskell IGL (2005) *Gray's anatomy. The anatomical basis of clinical practice*. 39th Ed. Churchill & Livingstone, Edinburg, pp. 536.
12. Symes A, Ellis H (2005) Variations in the surface anatomy of the spinal accessory nerve in the posterior triangle. *Surg Radiol Anat*, 27: 404–408.
13. Sznajder JI, Zveibil FR, Bitterman H, Weiner P, Bursztein S (1986) Central vein catheterization: failure and complication rates by three percutaneous approaches. *Arch Intern Med*, 146: 259–261.
14. Williams PL, Bannister LH, Berry M eds. (1995) *Gray's anatomy*. 38th Ed. Churchill & Livingstone, Edinburg, pp. 804–805.