

The first appearance of sympathetic ganglia in human embryos at stage 13

W. Woźniak, M. Grzymińska, J. Łupicka

Department of Anatomy, Poznań University of Medical Sciences, Poznań, Poland

[Received 14 July 2009; Accepted 30 September 2009]

The primordia of the sympathetic trunk ganglia were traced on serial sections of 10 embryos at stage 13 (32 postovulatory days). It was found that in all embryos, these primordia were present in the thoracic level T4 to T9 and they appeared as scattered aggregates of cells lying dorsally and laterally to the dorsal aortae. (Folia Morphol 2009; 68, 4: 215–217)

Key words: human neuroembryology, autonomic nervous system, sympathetic ganglia

INTRODUCTION

The development of the sympathetic nervous system can be divided into three overlapping stages [6]. First, the precursors of sympathetic neurons arise from neural crest cells that migrate ventrally, aggregate adjacent to the dorsal aorta, and ultimately differentiate into catecholaminergic neurons. Second, the cell number is refined when neurotrophic factors determine the number of neurons. The final stage of the sympathetic development is the establishment and maturation of sympathetic connections.

The primordia of the sympathetic ganglia appear before the fibres of the communicating rami can be traced into them and before formation of the sympathetic trunk [13]. According to Mitchell [16], aggregation of cells, representing the primordia of the future ganglia of the sympathetic trunk, are first evident in the lower thoracic and upper lumbar regions, and they are located on the posterolateral aspects of the aorta. Such aggregations of primordial cells are arranged initially in an ill-defined column, and in embryos at the 15 mm stage, they are present in all except the cervical region.

Kuntz [12] stated that aggregates of cells may be observed from the caudal cervical to the sacral region in human embryos 6 mm in length.

Pearson and Eckhard [19] found white communicating rami in embryos 6.0–6.5 mm in length.

It has to be pointed out that the embryonic age should be expressed in developmental stages which are based on the morphological status of development. Embryos of 6.0 mm in length may belong to different stages [17, 18].

The aim of the present study is to trace the early formation of the sympathetic ganglia in human embryos at stage 13.

MATERIAL AND METHODS

Serial sections of 10 embryos at stage 13 (32 postovulatory days) from the Collection of the Department of Anatomy, Poznań University of Medical Sciences were studied (Table 1).

Coronal, sagittal, and horizontal sections stained with haematoxylin and eosin, cresyl violet, according to the Mallory method, and impregnated with silver were examined microscopically. The roots of the spinal cord and the spinal nerves were carefully traced and the positions of the sympathetic ganglia were evaluated.

RESULTS

In all investigated embryos, the division of sclerotomes into loose superior and dense inferior zones

Table 1. CR length, developmental stage, and postovulatory days of investigated embryos

| Catalogue number | CR length [mm] | Developmental stage | Age [days] | Plane of section |
|------------------|----------------|---------------------|------------|------------------|
| B171 | 5.0 | 13 | 32 | Horizontal |
| B174 | 4.5 | 13 | 32 | Horizontal |
| B194 | 6.0 | 13 | 32 | Horizontal |
| B202 | 4.5 | 13 | 32 | Horizontal |
| B206 | 5.5 | 13 | 32 | Horizontal |
| B207 | 6.0 | 13 | 32 | Frontal |
| B208 | 5.5 | 13 | 32 | Frontal |
| B209 | 5.0 | 13 | 32 | Horizontal |
| B218 | 5.5 | 13 | 32 | Horizontal |
| I | 5.5 | 13 | 32 | Sagittal |

is observed (Fig. 1). The spinal ganglia are not yet segregated and the spinal neural crest extends on the dorsolateral surface of the spinal cord. The spinal nerves are already formed and the thick anterior branch of these nerves is evident (Fig. 2).

The primordia of the sympathetic ganglia are composed of scattered cells which are larger than cells of the mesenchyme, and show more intense staining reaction (Figs. 1, 2). Such aggregates of cells are found in the thoracic levels T4–T9. They lie along the dorsolateral aspects of dorsal aortae. Cells in these primordia are identical to cells of the spinal ganglia. At this stage of development, there are no communicating rami.

DISCUSSION

Postganglionic sympathetic neurons arise from the neural crest, which migrate ventrally from the dorsal surface of the neural tube. Neural crest cells develop at the interface between the non-neural ectoderm (presumptive epidermis/ surface ectoderm) and the dorsal region of the neural plate, a region commonly referred to as the neural plate border [3].

The sympathetic primordia are near the dorsal aortae [7]. Several factors play a role in early development of the sympathetic ganglia [1, 2, 4, 8–11, 20].

The sympathetic trunk and plexuses are made up of cells that originate from the entire length of the neural crest located behind the level of the fifth somite [14, 15, 18].

According to Anderson [1], both catecholaminergic neural crest derivatives: adrenal chromaffin cells and sympathetic neurons, derive from a common sympathoadrenal progenitor.

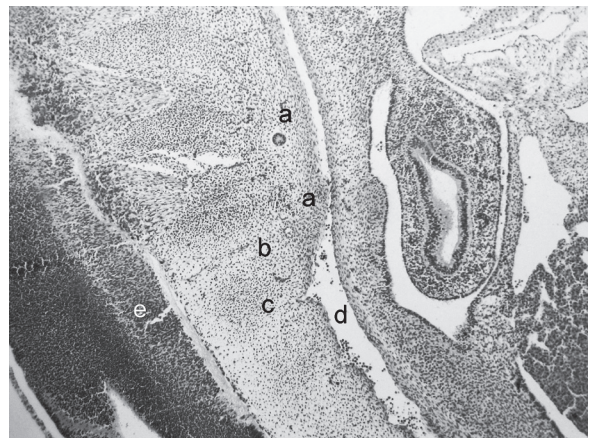


Figure 1. Sagittal section of embryo. Impregnation with Bodian's protargol, $\times 100$; a — sympathetic ganglia, b — loose zone of sclerotome, c — dense zone of sclerotome, d — dorsal aorta, e — spinal cord.

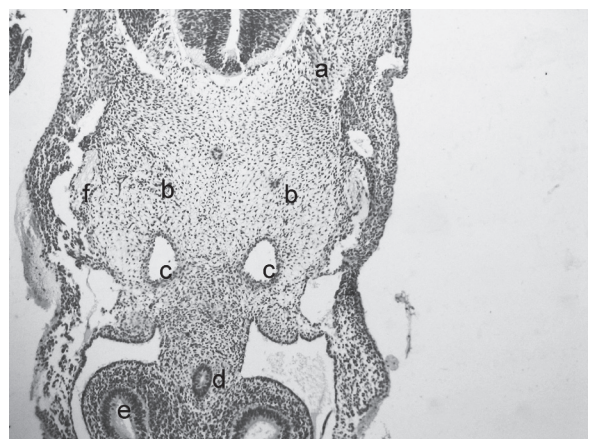


Figure 2. Horizontal section of embryo at the level of the main bronchi. Stained with cresyl violet, $\times 40$; a — spinal nerve, b — sympathetic ganglia, c — dorsal aortae, d — oesophagus, e — main bronchus, f — anterior ramus of the spinal nerve.

The dorsal aorta and notochord regulate the commitment to and expression of cell fate by the neural crest that settle there. Dorsal aorta and neural tubes induce noradrenergic traits in neural crest cultures, and adrenergic properties are not expressed in the sympathetic ganglia of notochord-ablated chicken embryos [5].

The dorsal aorta-derived factor involves one or more of the members of the BMP family, which increase TH expression in migrating neural crest cells [6].

The present study revealed that the primordia of the sympathetic ganglia appear very early in the thoracic part of the sympathetic trunk. They precede the formation of the communicating rami. The sympathetic ganglia are related to the dorsal aortae and sclerotomes surrounding the notochord.

Our results are not in accordance with the findings of Kuntz [12], who observed such primordia in the lower thoracic and upper lumbar region. According to Kuntz [12], the primordia of the sympathetic trunks grow cranially from the lower cervical region, both by displacement of cells along the dorsal aspect of the aortae and by local cell division.

Streeter [21], investigating nervous system in the human embryo at the end of the first month (10 mm), found that the neural crest cells destined to become sympathetic ganglion cells fused together on each side of the body to form a longitudinal column situated lateral to the aorta and in front of the developing vertebral bodies.

Such an appearance of the sympathetic trunks is observed in the later stages of development during the second month.

REFERENCES

1. Anderson DJ (2000) Genes, lineages and the neural crest: a speculative review. *Philos Trans R Soc London B Biol Sci*, 355: 953–964.
2. Coughlin MD, Dibner MD, Boyer DM, Black JB (1978) Factors regulating development of an embryonic mouse sympathetic ganglion. *Dev Biol*, 66: 513–528.
3. Crane JF, Trainor PA (2006) Neural crest stem and progenitor cells. *Annu Rev Cell Dev Biol*, 22: 267–286.
4. Ernsberger U (2001) The development of postganglionic sympathetic neurons: coordinating neuronal differentiation and diversification. *Auton Neurosci*, 94: 1–13.
5. Ernsberger U, Roher H (1996) The development of the noradrenergic transmitter phenotype in postganglionic sympathetic neurons. *Neurochem Res*, 21: 823–829.
6. Francis NJ, Landis SC (1999) Cellular and molecular determinants of sympathetic neuron development. *Annu Rev Neurosci*, 22: 541–566.
7. Glebova NO, Ginty DD (2005) Growth and survival signals controlling sympathetic nervous system development. *Annu Rev Neurosci*, 28: 191–222.
8. Groves AK, George KM, Tissier-Seta J-P, Engel JD, Brunet J-F, Anderson DJ (1995) Differential regulation of transcription factor gene expression and phenotypic markers in developing sympathetic neurons. *Development*, 121: 887–901.
9. Hall AK, MacPhedran SE (1995) Multiple mechanisms regulate sympathetic neuronal phenotype. *Development*, 121: 2361–2371.
10. Howard MJ (2005) Mechanisms and perspectives on differentiation of autonomic neurons. *Dev Biol*, 277: 271–286.
11. Huang EJ, Reichardt LF (2001) Neurotrophins: roles in neuronal development and function. *Annu Rev Neurosci*, 24: 677–736.
12. Kuntz A (1920) The development of the sympathetic nervous system in man. *J Comp Neurol*, 32: 173–229.
13. Kuntz A (1953) The autonomic nervous system. Lea and Febiger, Philadelphia.
14. Le Douarin NM, Smith J (1988) Development of the peripheral nervous system from the neural crest. *Annu Rev Cell Biol*, 4: 375–404.
15. Markman JA, Vaughn JE (1991) Patterns of sympathetic preganglionic neuronal migration in spinal cord of embryonic rats. *Soc Neurosci*, 17: 206.
16. Mitchell GAG (1953) Anatomy of the autonomic nervous system. Livingstone LTD, Edinburgh, London.
17. O'Rahilly R, Müller F (2003) Somites, spinal ganglia, and centra. *Cells Tissues Organs*, 173: 75–92.
18. O'Rahilly R, Müller F (2007) The development of the neural crest in the human. *J Anat*, 211: 335–351.
19. Pearson AA, Eckhard AL (1960) Observations on the gray and white rami communicantes in human embryos. *Anat Rec*, 138: 115–127.
20. Sommer L, Shah N, Rao M, Anderson DJ (1995) The cellular function of MASH1 in autonomic neurogenesis. *Neuron*, 15: 1245–1258.
21. Streeter GL (1908) The peripheral nervous system in the human embryo at the end of the first month (10 mm). *Amer J Anat*, 8: 285–301.