

# A giant aneurysm of the internal carotid artery, which caused dysphagia: case study and short review of literature

I. Vasileiadis, S. Kapetanakis, A. Fiska, D. Vasileiadis, T. Dimitriou

Department of Anatomy, Medical School of Alexandroupolis, Democritus University of Thrace, Greece

[Received 26 August 2010; Accepted 29 September 2010]

*The retropharyngeal space is a virtual space behind the pharynx, which extends from the skull base to the level of the fourth thoracic vertebra. Many retropharyngeal masses can cause dysphagia or airway obstruction. We report the case of a 69 year-old woman with a much enlarged aneurysm in the extracranial portion of the left internal carotid, causing dysphagia, and a short review of the relevant literature. (Folia Morphol 2010; 69, 4: 267–270)*

**Key words:** aneurysm, extracranial, fusiform, internal carotid

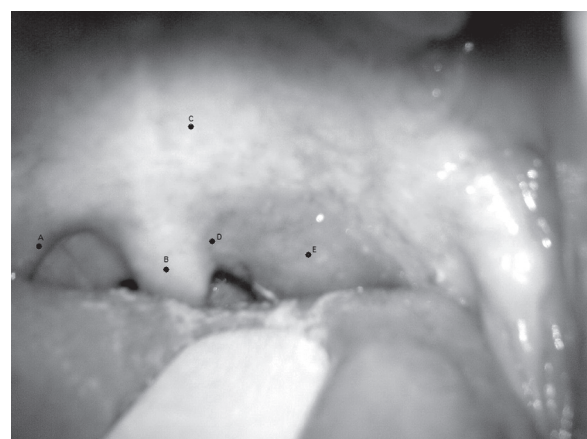## INTRODUCTION

Pseudotumors of retropharyngeal space are mentioned as anatomical variants of the carotid artery or internal jugular vein, degenerative alterations or anatomical variations of regional bone structures, and damage of muscle such as hypertrophy of the levator scapulae muscle and fibrosis of sternocleidomastoid muscle [5, 16]. We present a case of an elderly patient with pseudotumour of the retropharyngeal space, which caused dysphagia for solid foods. Oral examination revealed a bulge in the posterior pharyngeal wall without mucosa lesions. A spiral computed tomography (CT) of patient's neck revealed a pseudomass of the retropharyngeal space, which was a much enlarged aneurysm in the extracranial portion of left internal carotid.

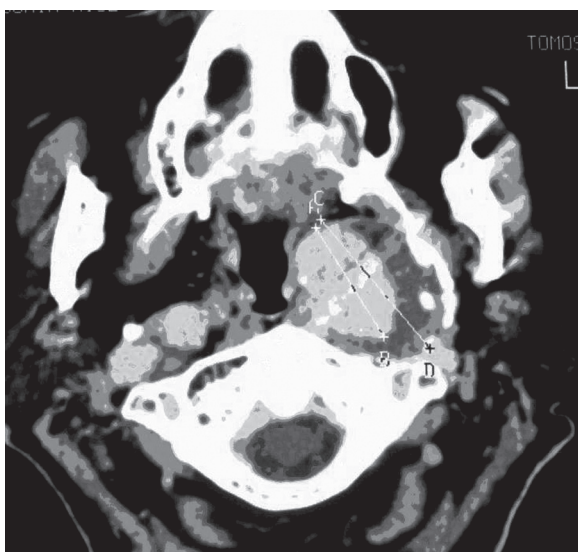
## CASE REPORT

A 69 year-old woman who complained of dysphagia and foreign body sensation in the posterior pharynx for three months was referred to our ENT department. The patient's medical history was hypertension, without known coronary artery or cerebrovascular disease. Physical examination found a nonpulsatile oropharyngeal mass displacing the

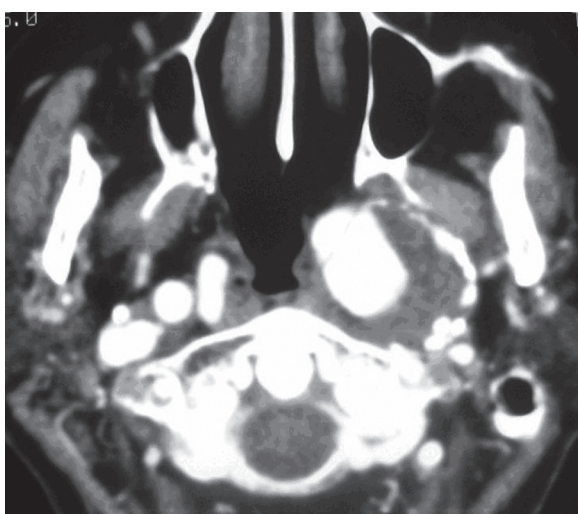
left tonsil and lateral pharyngeal wall into the midline (Fig. 1). Endoscopic examination revealed a bulge in the posterior and in the left lateral pharyngeal wall without mucosa lesions. There were no signs of infection or tenderness around the neck. Auscultation evidenced no pathological carotid bruit. Under the impression of left parapharyngeal tumour,



**Figure 1.** Anatomy of retropharyngeal space and the aneurysm of the extracranial portion of left internal carotid; A — palatoglossal arch; B — uvula; C — soft palate; D — palatine tonsil; E — suspicious mass.



**Figure 2.** Spiral computed tomography revealed a giant aneurysm of the extracranial portion of the left internal carotid artery with parietal thrombosis and a maximal transverse diameter of 38 mm (C, D) and a lumen of 31 mm (A, B).



**Figure 3.** Spiral computed tomography after intravenous contrast agent administration revealed the lumen of the fusiform aneurysm of the extracranial portion of the left internal carotid artery.

contrast-enhancing spiral CT of the patient's neck was obtained prior to biopsy. It revealed a giant fusiform aneurysm of the extracranial portion of the left internal carotid artery with parietal thrombosis and a maximal transverse diameter of 38 mm (Figs. 2, 3). Cranial CT was also performed in order to discover any possible previous thrombo-embolic events, which also revealed an aneurysm of the right middle cerebral artery. In this case, CT exam prior to

intervention offered a concise diagnosis, thereby avoiding a clinical catastrophe.

## DISCUSSION

The retropharyngeal space, which is bounded posteriorly by the prevertebral fascia and anteriorly by the buccopharyngeal fascia, extends from the skull base to about the level of the sixth thoracic vertebral body. Here the retropharyngeal space is closed by fibrous tissue around the tracheal bifurcation. Many other spaces border the retropharyngeal space. The pharyngeal mucosal space of the nasopharynx, oropharynx, and hypopharynx is located anteriorly. Lateral to the retropharyngeal space is the carotid space, which contains the common carotid artery, the internal jugular vein, and the lower four cranial nerves as well as most of the external carotid artery branches [16]. Two other potential spaces (the danger space and prevertebral space) are in close proximity to the retropharyngeal space. The danger space is formed anteriorly by the alar fascia and posteriorly by the prevertebral fascia. The prevertebral space is bound anteriorly by the prevertebral fascia and posteriorly by the longus colli muscles of the spine. The danger space extends down the mediastinum to the level of the diaphragm, whereas the prevertebral space continues to the insertion of the psoas muscles [5, 16].

The extracranial portion of internal carotid is relatively superficial as it starts, is contained in the carotid triangle of the neck, and lies behind and lateral to the external carotid, overlapped by the sternocleidomastoid muscle, covered by the deep fascia, the platysma, and integument. It then passes beneath the parotid gland, being crossed by the hypoglossal nerve, the digastric muscle and the stylohyoid muscle, the occipital artery, and the posterior auricular artery. Higher up, it is separated from the external carotid by the styloglossus and stylopharyngeus muscles, the tip of the styloid process and the stylohyoid ligament, the glosopharyngeal nerve, and the pharyngeal branch of the vagus nerve. It is in relation, behind, with the longus capitis, the superior cervical ganglion of the sympathetic trunk, and the superior laryngeal nerve; laterally, with the internal jugular vein and vagus nerve, the nerve lying on a plane posterior to the artery; and medially, with the pharynx, superior laryngeal nerve, and ascending pharyngeal artery. At the base of the skull the glosopharyngeal, vagus, accessory, and hypoglossal

nerves lie between the artery and the internal jugular vein.

Sometimes there are benign lesions that during clinical examination give the impression of a tumour at the posterior retropharyngeal space, but a careful radiological evaluation provides important information about their kind and justifies the accurate diagnosis. These lesions are mentioned as pseudotumours. The carotid artery may show pronounced tortuosity and extend into the retropharyngeal space, and clinically this may appear as a submucosal mass lesion. Other pseudotumours of the retropharyngeal space are anatomical variants of the internal jugular vein (thrombosis), degenerative alterations or anatomical variations of regional bone structures (osteophytes of cervical vertebrae), and damage of muscle such as hypertrophy of the levator scapulae muscle and fibrosis of the sternocleidomastoid muscle [5].

The main complaint of patient reported in our case was dysphagia due to pressure on the pharyngeal constrictor muscles, pharyngeal dysfunction because of pressure on mucous membranes, and glossopharyngeal nerve and ear pain radiating to the occipital area [6, 7, 12]. Presentation with an isolated mass in the oropharyngeal wall without extension to the outside has been reported infrequently [3, 12]. Spiral CT revealed a giant aneurysm of the extracranial portion of the left internal carotid artery with parietal thrombosis and a maximal transverse diameter of 38 mm. Only a few cases have been reported in English literature [3, 12] of the extracranial portion of the internal carotid causing dysphagia, and none of these cases was of this size.

Anatomical variants of the carotid artery have been reported with a large variability of degree and pattern. Among these variants, an anomalous retropharyngeal course of the internal carotid artery can mimic parapharyngeal neoplasm and pose a risk of vascular injury during a pharyngeal intervention such as biopsy or surgery. Tortuous or medially deviated carotid arteries are relatively rare causes of retropharyngeal soft tissue widening [6, 8, 10, 16]. Aneurysms of the extracranial internal carotid arteries are extremely rare [6, 10, 11]. These aneurysms are estimated at 0.1% to 2% of all carotid procedures.

The clinical manifestation requires the participation of the high cervical segments with primary enlargement into the tonsillar fossa. These aneurysms can cause dysphagia, airway obstruction, prevent

correct swallowing, palpate asymmetric pulses, or can appear thrombosed, as in our case [1, 4, 8, 9, 17]. It is especially dangerous when the aneurysm comes into contact with the tonsillar fossa or the posterior pharyngeal wall. A precise and early diagnosis of a bulge in the posterior pharyngeal wall is critical and may prevent an eventual catastrophic outcome. One of the principal dangers is that it can be mistaken clinically for a tumour or an abscess and subsequently be injured during an attempted biopsy or surgical extension [8].

The most common aetiological factor for extracranial true carotid artery aneurysm is atherosclerosis, with an incidence of 34 to 70% in different series. They are typically fusiform in shape although saccular aneurysm is also seen [2]. In physical examination, a pulsatile mass around the neck region is found in 90% of cases. Aneurysms are seen twice as commonly in males, and the mean age of patients is in the sixties at the time of diagnosis. Most of the aneurysms are asymptomatic. In 38–100% of cases the first finding is of neurological origin. The main aetiology for neurologic accidents is embolisation from the aneurismal contents [1, 2, 7, 12].

Cystic hygroma, neuroblastoma, haemangioma, neurofibroma, schwannoma, foreign body, ectopic goitrous thyroid tissue, myxoedema of hypothyroidism, thymus, traumatic instrumentation and oedema or haematoma from cervical spine injury, retropharyngeal cellulitis or abscess, lymphoma, leukaemia, infectious mononucleosis, and tuberculosis are some of the retropharyngeal masses that may lead to dysphagia or airway obstruction [2, 8, 13, 14].

Radiological evaluation includes imaging of the neck, and the brain and its vasculature. The initial coloured Doppler ultrasonography can determine the size and the extension of the aneurysm, but it is not sufficient in defining the relation with its neighbouring structures. In contrast, spiral CT imaging of the lumen and wall of the aneurysm show identical contrasting as vessels. The possibility of misdiagnosis disappears when ultrasound and contrast spiral CT are evaluated together. CT angiography and magnetic resonance imaging (MRI) angiography are non-invasive methods that can show the course, calibre, and contour of the vessels. The advantage of contrast-enhancing multislice CT is that it simultaneously offers CT angiography and clear multiplanar images, and it is the definitive diagnostic procedure for these lesions [3, 7, 15]. In our hospital we did not have the option of MRI. A contrast-enhancing spiral CT

of the neck was obtained, which revealed the giant fusiform aneurysm.

Conservative treatment may be indicated for most asymptomatic cases, based on anticoagulant and antiplatelet medication. In patients with symptoms, the objective of surgical treatment is the prevention of thromboembolic stroke and the restoration of the blood supply. Open surgery remains the gold standard to treat extracranial internal carotid artery aneurysms; endovascular procedure may be used in appropriate cases as an alternative surgical therapy [3, 6, 11]. In our case, the patient was treated with open surgery and she is free of symptoms after two years of follow up.

### CONCLUSIONS

In conclusion, many lesions can cause dysphagia. A giant aneurysm, such as in our case, should always be a part of the differential diagnosis in a patient with dysphagia, especially when surgical intervention is planned for the diagnosis or the treatment of a tumour to the posterior pharyngeal space. Consequently, these anomalies must be recognised in time by the surgeons and radiologists in order to avoid mistakes during the clinical diagnosis.

### REFERENCES

- Atallah PC, Atallah P, Kashyap V (2010) Internal carotid artery aneurysm discovered by palpation of asymmetric pulses. *Am J Med*, 123: e1–e2.
- Baba S, Fukuda Y, Mizota S, Hayashi K, Suyama K, Nagata I (2010) Fusiform aneurysm associated with fenestration of the posterior communicating artery. *Neurol Med Chir*, 50: 568–570.
- Biazzi L, Azzarone M, De Troia A, Salcuni P, Tecchio T (2008) Extracranial internal carotid artery aneurysms: case report of a saccular wide-necked aneurysm and review of literature. *Acta Biomedica*, 79: 217–222.
- Chen G, Leng B, Song D, Wang Q (2010) Multiple aneurysms of external and internal carotid arteries. *Acta Neurol Belg*, 110: 120–121.
- Davis WL, Harnsberger HR, Smoker WRK, Watanabe AS. (1990) Retropharyngeal space: evaluation of normal anatomy and diseases with CT and MR imaging. *Radiology*, 174: 59–64
- El Sabrout R, Cooley DA (2000) Extracranial carotid artery aneurysms: Texas Heart Institute experience. *J Vasc Surg*, 31: 702–712.
- Fix TJ, Daffner RH, Deeb ZL (1996) Carotid transposition: another case of wide retropharyngeal soft tissues. *Am J Roentgenol*, 167: 1305–1307.
- Galletti B, Bucolo S, Abbate G, Calabrese G, Romano G, Quattrocchi C, Freni F (2002) Internal carotid artery transposition as risk factor in pharyngeal surgery. *Laryngoscope*, 112:1846–1847.
- Kubis N, Haguenu M, Woimant f, Von Langsdorff D, Mikol J, Delfiner B (2000) A giant carotid aneurism preventing correct swallowing. *J Neurol Neurosurg Psychiatry*, 68: 678.
- McCullum CH, Wheler WG, Noon GP, De Bakey ME (1979) Aneurysms of the extracranial carotid artery. Twenty-one years' experience. *Am J Surg*, 137: 196–200.
- Moreau P, Albat B, Thevenet A (1994) Surgical treatment of internal carotid artery aneurysm. *Ann Vasc Surg*, 8: 409–416.
- Oruckaptan H, Ozcan O (2001) Giant extracranial internal carotid artery aneurysm: a rare presentation with an oropharyngeal mass. *Otolaryngology, Head Neck Surg*, 125: 571–573.
- Sergi B, Alberti V, Paludetti G, Snider F (2006) Extracranial Internal Carotid artery aneurysm presenting as pharyngeal mass with dysphagia. *J Laryngol Otol*, 120: e4.
- Siablis D, Karnabatidis D, Katsanos K, Mastronikolis N, Zabakis P, Kraniotis P (2004) Extracranial internal carotid artery aneurysms: report of a ruptured case and review of the literature. *Cardiovasc Intervent Radiol*, 27: 397–401.
- Weissman JL, Johnson JT, Synderman CH, Seed DL (1994) Thrombosed aneurysm of the cervical carotid artery: avoiding a retrospective diagnosis. *Radiology*, 190: 869–871.
- Wong YK, Novotny GM (1978) Retropharyngeal space: a review of anatomy, pathology and clinical presentation. *J Otolaryngol*, 153: 149–156.
- Xie T, Zhang XB, Li QP, Zhu W, Zhou H, Gu Y (2010) Hemifacial spasm patient with ipsilateral total absence of common carotid artery, vertebral artery and aneurysm of the contralateral internal carotid artery. *Surg Radiol Anat*, 32: 707–710.