

Anomalous origin of the left vertebral artery from the arch of the aorta: review of the literature and a case report

V. Jayanthi, Prakash, M. Nirmala Devi, B.S. Geethanjali, T. Rajini

Department of Anatomy, Vydehi Institute of Medical Sciences and Research Centre, Whitefield, Bangalore, Karnataka, India

[Received 24 June 2010; Accepted 16 July 2010]

The present report describes an anomalous case of the left vertebral artery arising from the aortic arch between the left common carotid artery and the left subclavian artery in a male cadaver during dissection in an anatomical laboratory. Aortic origin of the vertebral artery is a rare anatomic variant. Detailed knowledge of anomalous origin is important for patients who undergo four-vessel angiography. Normally, the vertebral artery arises from the first part of the subclavian artery on both sides. We also review the anomalous origin of the vertebral artery in the literature and discuss its clinical significance. (Folia Morphol 2010; 69, 4: 258–260)

Key words: anatomy, cadaver, review, dissection

INTRODUCTION

The anomalies of branches arising from the aortic arch are due to variations in the extent of the fusion process and absorption of some of the aortic arches into the aortic sac. Increases and decreases in the number of the branches arising from the arch depend on such processes. The great arteries of the thoracic region are well known for their variations, the aortic arch being one of them [14]. The variations of branches arising from the aortic arch are well known and have been documented regarding different races by several authors such as Barry [3], Barwell [4], and Birmingham [7].

Detailed knowledge of the anomalous origin of supra aortic arteries is also important for patients who have to undergo four-vessel angiography in an emergency [10].

In angiographic and anatomic postmortem examinations, abnormal vertebral artery origins are incidental findings because, in most cases, they are

clinically asymptomatic; nonetheless, these abnormalities are of diagnostic importance either prior to vascular surgery in the neck region or in cases of intra vascular disease such as arteriovenous malformations or cerebral aneurysms [10].

Anatomic and morphological variations of the vertebral artery are of immense importance in surgery, angiography, and all non-invasive procedures [11]. The vertebral arteries arise from the superolateral aspect of the first part of the subclavian artery. The vessel takes a vertical posterior course to enter the foramen transversarium of the sixth cervical vertebra. In our study, the left vertebral artery (LVA) originates directly from the arch of aorta.

MATERIAL AND METHODS

During routine dissection of a cadaver in the Department of Anatomy, an unusual origin of a pre-vertebral segment of LVA from the arch of aorta was observed in a male body aged about 60 years.

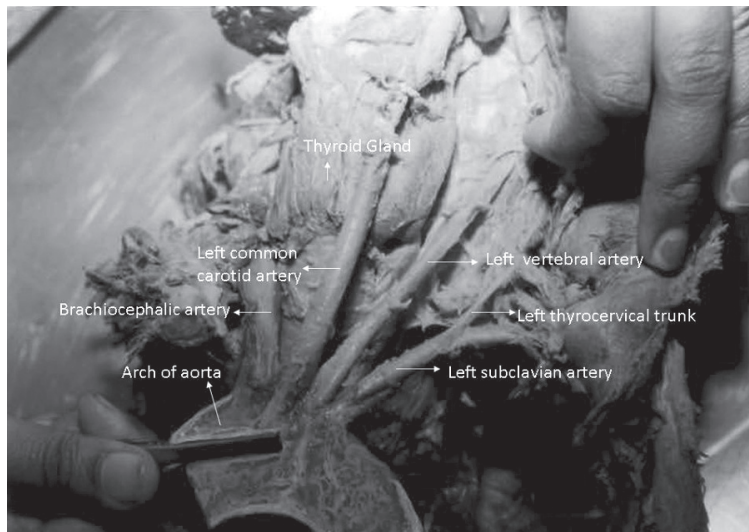


Figure 1. The origin of left vertebral artery from arch of aorta between left subclavian and left common carotid artery.

OBSERVATION

The origins of the right and left vertebral arteries were studied on both sides. The right vertebral artery (RVA) originated normally from the subclavian artery and the LVA originated directly from the arch of aorta between the left common carotid and left subclavian artery (Fig. 1).

DISCUSSION

The course and variability in origin of the LVA [16], its surgical importance [5] in cerebral disorders [20], and the importance of the vertebral artery in head and neck surgery has been described [9]. In our study we found an abnormal origin of the LVA in one out of 20 cadavers (5%). The frequency of origin of the LVA from the aortic arch is in the approximate range of 1–3% of cases [8].

The LVA arose directly from the aortic arch, and the order was as follows: right brachiocephalic, left common carotid, left subclavian, and LVA [19]. Aortic arch anomalies are also associated with chromosomal 22q deletion [13]. Normal three-branched arrangements of the aortic arch are reported in 64.9% [2] of cases. The true value of detecting anomalous origins is of diagnostic importance before vascular surgeries of supra-aortic arteries as variations of the branches of the aortic arch are likely to occur as a result of the altered development of certain branchial arch arteries during the embryonic period of gestation [6]. Anatomical and morphological variations of the vertebral artery are of great importance in surgery,

angiography, and all non-invasive procedures [17]. Abnormal origin of the vertebral artery may favour cerebral disorders due to alterations in cerebral haemodynamics [20].

Anomalous vertebral artery origins do not result in clinical symptoms [22]. In rare cases patients complained of dizziness, which was thought to have no connection to the anomalous origin of the vertebral artery [15]. Some authors hypothesize that anomalous origins and distributions of the large aortic arch vessels can cause changes in cerebral haemodynamics and may lead to cerebral abnormalities [5]. The LVA originated from the aortic arch between the common carotid artery and left subclavian artery [23]. An unusual case of duplicated origin of the LVA from the aorta is reported [18]. A case of bilateral anomalous origin of the vertebral artery from the aortic arch is also reported [1].

EMBRYOLOGICAL DEVELOPMENT

Congenital abnormalities of the aortic arch, which take many forms, result from the aberrant development of one or more components of the embryonic pharyngeal arch system and represent < 1% of all congenital cardiac defects [12]. The various forms of this anomaly occur very early in embryonic development. They result from abnormal or incomplete regression of one of the six embryonic branchial arches. Evidence from human genetic models and animal models suggest that chromosome 22q deletion may be an important cause of anomalous development of the aortic arch [12]. The vertebral artery arises from the post-costal longitudinal anastomosis between

the c and c7 intercostal arteries and the cervical intercostal obliteration zone [10].

Embryologically, the aberrant origin of the LVA directly from the aortic arch is due to the persistence of the eighth intersegmental artery [1]. Vorster et al. [21] noted that vertebral arteries arose from the aortic arch in 5% of cadavers.

CONCLUSIONS

Anomalies in the origin of the LVA from the aortic arch have been documented worldwide. The course and variability in the origin of the LVA is important in head and neck surgery, angiography, and non-invasive procedures of the neck. These anomalous origins can cause changes in cerebral haemodynamics leading to cerebral abnormalities.

REFERENCES

- Albayram S, Gailloud P, Wasserman BA (2002) Bilateral arch origin of the vertebral arteries. *Am J Neuroradiol*, 23: 455–458.
- Anson BV, Mcvay CB (1971) *Surgical anatomy*. 5th Ed. WB Saunders, Philadelphia.
- Barry A (1951) The aortic arch derivatives in the human adult. *Anat Rec*, 111: 221–238.
- Barwell (1867) Abnormal origin of arteries from the aortic arch. *Trans Pathol Soc Lond*, 18: 68.
- Bernardi L, Deton P (1975) Angiographic study of a rare anomalous origin of the vertebral artery. *Neuroradiology*, 9: 43–47.
- Bhatia K, Ghabriel MN, Henneberg M (2005) Anatomical variations in the branches of the human aortic arch: a recent study of a South Australian population. *Folia Morphol*, 64: 217–223.
- Birmingham A (1893) Extreme anomaly of the heart and great vessels. *J Anat Physiol*, 27: 139–150.
- Dasler EH, Anson BJ (1959) surgical anatomy of the subclavian artery and its branches. *Surg Gynecol Obstetrics*, 108: 149–174.
- Komiyama M, Morikawa T, Nakajiman H, Nishikawa M, Yasui T (2001) High incidence of arterial dissection associated with left vertebral artery of aortic origin. *Neurol Med Chir*, 41: 8–11.
- Lemke AJ, Benndorf G, Liebig T, Felix R (1999) Anomalous origin of the right vertebral artery: review of the literature and case report of right vertebral artery: origin distal to the left subclavian artery. *Am J Neuroradiol*, 20: 1318–1321.
- Matula C, Trattling S, Tschabitscher M, Day JD, Kaos WT (1997) The course of the prevertebral segment of the vertebral artery: anomaly and clinical significance. *Surg Neurol*, 48: 125–131.
- McElhinney DB, Goldmuntz E (2004) Abnormalities of the aortic arch. *Orphanet Encyclopedia*, <http://www.orpha.net/data/patho/GB/uk-aortic-arch.pdf>.
- Mumma K, Matsuoka R, Takao A (1999) Aortic arch anomalies associated with chromosome 22q11 deletion (CATCH 22). *Pediatr Cardiol*, 20: 97–102.
- Nayak SR, Pai MM, Prabhu LV, D'Costa S, Shetty P (2006) Anatomical organization of aortic arch variations in India: embryological basis and review. *J Vasc Bras*, 5: 95–100.
- Nishijima M, Harada J, Nogami K, Endo S, Takaku A (1989) Operative correction of kinking and coiling at the origin of vertebral artery and Stellate ganglionectomy in patients with severe vertigo and dizziness. *No Shinkei Geka*, 17: 255–261.
- Nizanowski C, Noozynski E, Sunder E (1982) Variability of origin of ramifications of the subclavian artery in human. *Folia Morphol*, 41: 281–294.
- Paniker HK, Tarnekar A, Dhawana V, Ghosh SK (2002) Anomalous origin of left vertebral artery: embryological basis and applied aspects. *J Anat Soc India*, 51: 234–235.
- Shhadeh A, Sair HI, Kanamalia US (2007) Bifid direct aortic arch origin of left vertebral artery: a unique vascular variant. *J Vasc Interv Radio*, 18: 1051–1053.
- Son JS, Hong KB, Chung DCW (2008) Pseudocoarctation of the aorta associated with the anomalous origin of the left vertebral artery. *Korean J Radiol*, 9: 283–285.
- Vicko G, Goran I, Damjan M, Sanja P (1999) Anomalous origin of both vertebral arteries. *Clin Anat*, 12: 281–284.
- Vorster W, du Plooy PT, Meiring JH (1998) Abnormal origin of internal thoracic and vertebral arteries. *Clin Anat*, 11: 33–37.
- Wasserman BA, Mikulis DJ, Manzione JV (1992) Origin of the right vertebral artery from the left side of the aortic arch proximal to the origin of the left subclavian artery. *Am J Neuroradiol*, 13: 355–358.
- Yamaki K, Saga T, Hirata T, Sakaino M, Nohno M, Kobavashi S, Hirao T (2006) Anatomical study of the vertebral artery in Japanese adults. *Anat Sci Int*, 81: 100–106.