

Curcumin exerts protective effects on the thyroid gland in propylthiouracil-treated rats

Monika A. Papież 

Department of Cytobiology, Pharmaceutical Faculty, Jagiellonian University Medical College, Kraków, Poland

Abstract

Introduction. Among the plant ingredients, some compounds interfere with the functions of the thyroid gland. However, there is limited research on the effect of curcumin (CMN) on the functions of this gland. The aim of this study was to analyze the effect of CMN on morphology, histochemical reactivity of cytochrome c oxidase (CCO) and secretion functions of the thyroid gland under conditions of hypothyroidism induced by propylthiouracil (PTU).

Material and methods. The rats were treated for 30 days by gavage with CMN (100 mg/kg b.w.) and/or PTU (1 mg/kg b.w.). Control rats received vehicle only. Histomorphometric tests were performed on the thyroid glands, cytochrome c oxidase activity was visualized using the histochemical method, and the levels of thyroid hormones were measured using the radioimmunoassay method.

Results. Rats receiving PTU showed compensatory changes in their thyroid glands, including a significant increase in thyroid epithelium height, a decrease in colloid volume density, a decrease in the percentage of small follicles, an increase in medium-sized follicles compared to the control group, as well as a significant increase in CCO histochemical reactivity in the columnar epithelium and a decrease in FT4 serum level compared to the control group. The administration of CMN reversed these adverse changes caused by PTU. The PTU + CMN group exhibited a significant decrease in the height of the thyroid follicle epithelium compared to the PTU group. The percentage of small and medium-sized follicles in the CMN + PTU group did not differ from the control group. Furthermore, CCO reactivity in the cubic epithelium and serum FT4 levels increased compared to the PTU group. Administration of CMN alone resulted in a significant increase in FT4 levels compared to the control group.

Conclusions. The administration of CMN to rats with induced hypothyroidism resulted in a reduction of hyperplasia, hypertrophy, and an increase in secretory activity of the thyroid gland. These findings suggest the protective effect of CMN against induced hypothyroidism. (*Folia Histochemica et Cytobiologica* 2023, Vol. 61, No. 3, 143–152)

Keywords: rat; thyroid; propylthiouracil; curcumin; histomorphometry; cytochrome c oxidase; histochemistry

Introduction

Curcumin (CMN), a yellow polyphenol, can be isolated from the rhizomes of *Curcuma longa L.*, which belongs to the Zingiberaceae family. This perennial plant is native to Southeast Asia [1]. CMN falls under the category of phenolic acids and is a dimeric derivative of ferulic acid. It is commonly found in curry

spice and is also used in medications for biliary tract disorders [1].

Numerous studies have demonstrated various protective effects of CMN, including its cholesterol-lowering, anti-inflammatory, antioxidant, anticancer, hypotensive, antiviral, and antibacterial effects [2, 3]. Animal studies have indicated that CMN is a compound with low toxicity, and doses up to 5 g/kg b.w. are safe without causing side effects. However, long-term use of an organic extract from turmeric rhizomes, which is primarily composed of CMN, has been associated with hyperplasia of the thyroid follicle epithelium [4].

Multiple environmental factors can contribute to the onset of hypothyroidism. These factors primarily

Correspondence address:

Monika Papież, PhD
Department of Cytobiology, Pharmaceutical Faculty,
Jagiellonian University Medical College
Medyczna 9 St., 30–688 Kraków, Poland
e-mail: monika.papiez@uj.edu.pl

include iodine deficiency in the diet. Additionally, humans can be exposed to several antithyroid factors found in a plant-based diets containing, *e.g.*, cruciferous vegetables. The antithyroid plant compounds encompass cyanogenic glycosides, thioglycosides, and some polyphenols [5]. Plant polyphenols, specifically flavonoids, isoflavonoids, and phenolic acids, have the potential to reduce the activity of thyroid peroxidase (TPO, thyroperoxidase) — a key enzyme involved in the synthesis of thyroid hormones [6]. Moreover, they might also impact iodine uptake, intrathyroidal transport, or inhibit thyroid gland function at the gene expression level [7]. The antithyroid effects of plant polyphenols in humans become apparent under conditions of iodine deficiency, a low-protein diet [8, 9], or in synergy with environmental goitrogens like polybrominated (PBB) and polychlorinated (PCB) biphenyls or perchlorate [10]. Furthermore, antithyroid dietary components or environmental contaminants can interact with specific medications, such as amiodarone, traditional anticonvulsants, and sulfonamides, leading to hypothyroidism or goiter [11–14]. The obtained results are concerning, given that the antithyroid effect of certain polyphenols has been confirmed in both *in vitro* and *in vivo* studies [5, 15].

In earlier studies, we have previously demonstrated that polyphenol CMN has a weak stimulating effect on the secretory function of the thyroid gland in young rats. However, in older rats, it did not improve thyroid function and may even lead to a decrease in FT3 levels [16]. Conversely, published research results showed the protective effect of CMN on the thyroid gland, acting as an antioxidant and safeguarding the gland against degenerative changes induced by lithium carbonate and sodium fluoride [17–19]. Moreover, *in silico* studies have proven the stimulating effect of ferulic acid on TPO activity [20]. Nevertheless, research on the impact of CMN on thyroid gland function remains limited.

Cytochrome c oxidase (CCO) plays an important role in the formation of ATP in cells as the last element of the mitochondrial electron transport chain (ETC). In turn, ATP contributes to an increase in the level of free intracellular Ca²⁺, which as a central second messenger may affect the expression of genes regulating thyrocyte function [21]. In addition, ATP is the source for the synthesis of cAMP, an important second messenger in the cells [22]. Numerous studies have shown that one of the links in the signaling pathway leading from the TSH receptor to the synthesis of thyroid hormones is cAMP, which is activated by the G_{α_s} subunit [23]. Moreover, it has been shown that curcumin may increase cAMP levels in skeletal muscle [24] and pancreatic beta-cells [25].

The aim of this study was to evaluate the effect of CMN in rats receiving propylthiouracil (PTU), a classic inhibitor of thyroid hormone synthesis. Thus, the evaluation of CMN impact on the thyroid gland was conducted under conditions of hypothyroidism in rats by applying histomorphometric, histochemical and radioimmunoassay methods.

Material and methods

Animals. The three-month-old inbred male Wistar rats (WAG/Krf) weighted 215.6 ± 22.2 g (mean and SD) — 246.4 ± 22.9 g. The animals were kept under standard conditions at the temperature of 22°C and 50–60% humidity, on a 12-h light-dark cycle. The rats were fed on a commercial pellets diet and given drinking water *ad libitum*. The animals were divided into four groups. The rats were treated daily for 30 days by gavage: control group (K) — with 1 mL of corn oil (5 rats); group D1 — with curcumin (Sigma-Aldrich, Saint Louis, MI, USA), 100 mg/kg b.w. (5 rats); group D2 — with propylthiouracil (PTU, Sigma-Aldrich) 1 mg/kg b.w. (6 rats); group D3 — with propylthiouracil (1 mg/kg b.w.) and curcumin, 100 mg/kg b.w. (6 rats); curcumin and PTU were administered in 1 mL of corn oil. The dose of PTU was based on toxicity studies of this compound published in the enhanced report of the Organization for Economic Cooperation and Development (OECD) (Enhanced OECD Test Guideline no. 407), developed to establish guidelines for screening potential endocrine disruptors [26]. However, the dose of CMN used in this study exerted a protective effect against cyclophosphamide in rats, which was shown in the studies of Shukla *et al.* [27].

Blood was collected from the tail vein to a tube with heparin, and after centrifugation at 230 g for 5 min, plasma was obtained and frozen at –20°C until further analyses. The animals were killed by cervical dislocation under Vetbutal anesthesia. The experiments were carried out with the consent of the Local Ethics Committee at the Jagiellonian University, Kraków, Poland.

Histological examination of the thyroid gland. The thyroid lobes were excised and fixed using a 4% formaldehyde in the phosphate buffer (pH = 7.4). Then they were subjected to the procedure of dehydration in a graded ethanol series and embedding in Paraplast (Leica). Tissue sections, 5 μM-thick, were used to visualize cross-sections through the thyroid lobes. Serial sections were stained with periodic acid Schiff (PAS) and hematoxylin for a histological analysis.

Histomorphometric evaluation. A random spatial orientation of the organs was assumed to obtain surface cross-sections at a random position. Then, histomorphometric measurements of the height of the secretory epithelium of the thyroid gland and the diameter of the follicles were performed on 30 randomly selected follicles at 400-fold magnification. The criteria established by Low [28] were used in the morphometric measurements of the thyroid follicles. According to them, the

measurement area included tissue not adjacent to the border of the thyroid, but adjacent to the parathyroid glands. The criteria adopted in this way made it possible to avoid inclusion in the measurements of follicles lying on the margins of the thyroid gland, which are less active than those lying in the depths of the gland.

Measurements were taken in 3 cross sections of 5 μm thickness from each thyroid gland. The distance between sets of sections was 50 μm . A computer-assisted image analyzer with Multi Scan v. 11.06 software (CSS Ltd. Warsaw, Poland) was used for the measurements. The system was calibrated using a stage micrometer with a scale divided into 0.01-mm units. Measurements were made in the entire cross-section of the thyroid lobe, both at the edges and in the middle part [29]. The short and long diameters of the thyroid follicles were measured. The measurement of the longer diameter was defined as the length of the longest straight line marked on the base of the basal part of the cells and running through the center of the thyroid follicle. The shorter diameter was the length of the shortest line connecting the two extreme points (at the base of the basal part of the cells) and passing through the center of the follicle. The height of the thyroid follicle epithelium was determined by measuring a straight line running perpendicular to the base of the epithelium and connecting the base of the thyrocyte with the end of the apical part of the cell. Four opposite lines were measured [28]. Three size classes were distinguished based on the diameter of the thyroid follicles [16].

Volume density (V_v) was assessed in 5 non-overlapping thyroid cross-sectional areas by using a morphometric grid, containing 256 nodes [26]. The studies were performed at 25 \times magnification using point-counting methods. We counted hit points, that is places where net nodes were intersected with the colloid. Then the volume density of the colloid in the thyroid gland of individual rats was determined using the formula: $V_v = \frac{P_i}{P_t}$, where V_v is the volume density (the volume (V) of the colloid of thyroid follicles vs. the structure under study (v), P_i is the number of hit points (P) in the colloid (i) and P_t is the number of hit points (P) in all the follicles (t) of the organ under study. V_v was expressed as a percent ($V_v \%$) [29].

Histochemical analysis of cytochrome c oxidase reactivity in thyroid follicular epithelium. Tissue cryosections at a thickness of 8 μm were stained with Burstone's method [30]. In short, the cryosections were incubated in a solution that contained 5 mg variamine blue, and 5 mg para-aminodiphenylamine dissolved in 96% ethanol. This solution was added to a Tris buffer, pH = 7.4. The number of granules being the product of the histochemical reaction was an indicator of the relative degree of cytochrome c oxidase reactivity. Measurements of the intensity of the histochemical reaction were performed using a computer microscopy image analyzer consisting of a CH-2 light microscope (Olympus, Tokyo, Japan) connected to a camera CCD-FS-2012P (Mischke, Germany) and the Multi Scan 11.06 program, which distinguishes 256 gray levels. Gray levels have been replaced by integrated optical density (IOD). The results of quantitative measurements of the histochemical reaction products were expressed in degrees of optical density.

Radioimmunological analysis. Concentrations of free triiodothyronine (FT3) and free thyroxine (FT4) in serum were measured by radioimmunoassay competitive methods [31, 32]. The level of FT3 was determined using a mouse monoclonal anti-T3 antibody labeled with ^{125}I ; specific activity was < 225 kBq *per* vial. The concentration of FT4 was determined using a ^{125}I anti-T4 antibody; specific activity was < 150 kBq *per* vial.

Statistical analysis. A one-way analysis of variance (Statistica, StatSoft, Poland) was used to determine significant differences between individual groups. In the absence of the homogeneity of variance, the non-parametric Kruskal-Wallis test was used. Significance was set at $P < 0.05$.

Results

General health status and thyroid weight of rats after PTU and CMN treatment

No significant differences in body weight gain of rats were observed between control and experimental groups (Table 1). Rats receiving PTU had a slightly rougher coat compared to the other groups. They also showed a significant increase in the mean thyroid

Table 1. The body and thyroid weight of the rats treated with curcumin (CMN, 100 mg/kg b.w) and/or propylthiouracil (PTU, 1 mg/kg b.w.) for 30 days

Group	Mean body weight of the rats (g)		Mean weight of thyroid gland (mg)	Relative thyroid weight (%)
	0 day of experiment	30 days of experiment		
Control	246.4 \pm 22.9	283.4 \pm 24.9	10.6 \pm 0.9	3.7 \pm 0.5
CMN	227.8 \pm 19.3	262.0 \pm 18.4	11.3 \pm 2.0	4.3 \pm 0.6
PTU	215.6 \pm 2.2	259.5 \pm 14.6	14.0 \pm 2.2*	5.4 \pm 0.8*, ^, &
CMN + PTU	236.1 \pm 2.4	286.3 \pm 9.8	12.1 \pm 2.6	4.2 \pm 0.9

Values are means \pm SD. One-way analysis of variance with the Newman-Keuls post hoc test was used to determine significant differences between groups. * $P < 0.05$ vs. control; ^ $P < 0.05$ vs. CMN; & $P < 0.05$ vs. CMN + PTU. Relative thyroid weight = (thyroid weight/body weight) \times 100.

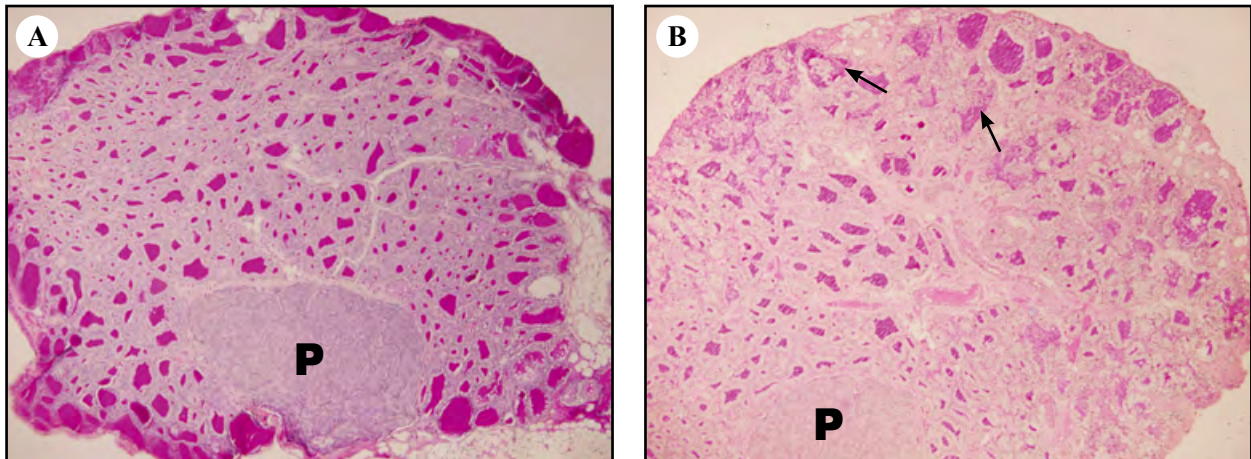


Figure 1. Cross sections through the thyroid lobes adjacent to the parathyroid gland (P) of rats treated with curcumin (CMN, 100 mg/kg b.w.) or propylthiouracil (PTU, 1 mg/kg b.w.) for 30 days. PAS-hematoxylin staining. **A.** Control rat: thyroid follicles are filled with intensely colored colloid and surrounded by secretory epithelium. **B.** PTU-treated rat: focal hyperplasia of the secretory epithelium is seen in thyroid follicles, characterized by the presence of multiple layers of thyrocytes protruding into the lumen (arrows). Total magnification: 100 \times .

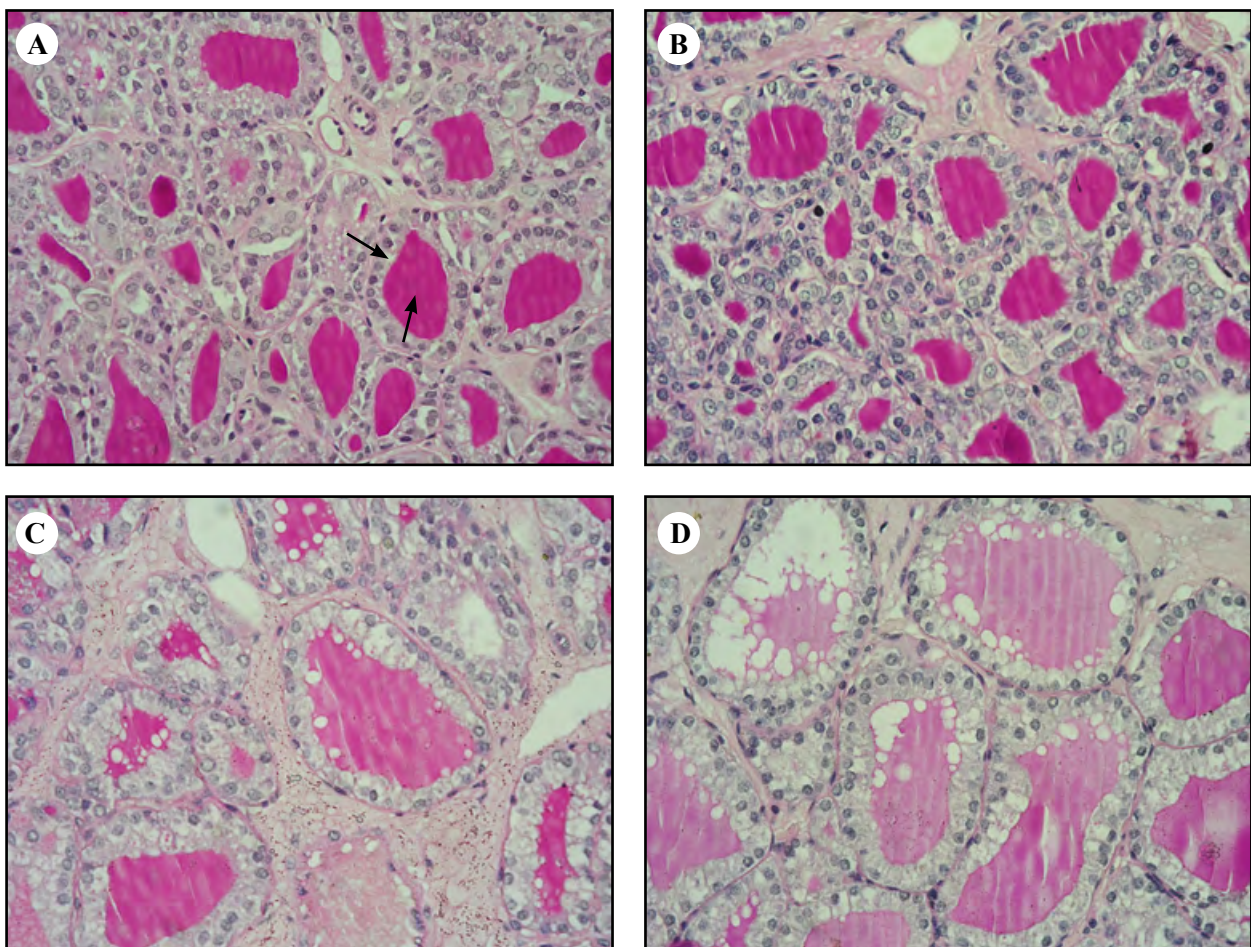


Figure 2. Cross sections through the middle part of the thyroid lobes of rats treated with curcumin (CMN, 100 mg/kg b.w.) and/or propylthiouracil (PTU, 1 mg/kg b.w.) for 30 days. PAS-hematoxylin staining. **A.** Control rat: thyroid follicles are mainly surrounded by cubic epithelium (arrow) and filled with colloid (arrow). **B.** CMN-treated rat: the histology of the thyroid gland is similar to the thyroid of the control rats. **C.** PTU-treated rat: the vacuolated colloid is surrounded by cylindrical epithelium. **D.** PTU- and CMN-treated rat: a very strongly vacuolated colloid is visible in the follicles. Magnification: 400 \times .

weight in comparison to the control group. The use of CMN in combination with PTU led to a significant decrease in relative thyroid gland weight compared to rats receiving PTU (Table 1).

Morphology of the thyroid gland in rats administered PTU and CMN

The morphological analysis of the thyroid gland of control rats revealed that the central part of the thyroid lobes showed a prevalence of small follicles surrounded by cubic or columnar epithelium and rarely medium-sized follicles with cubic epithelium. In contrast, the peripheral part of the thyroid lobes exhibited medium-sized follicles with cubic epithelium or large follicles with cubic or squamous epithelium. All follicles contained colloids with few vacuoles (Fig. 1A, 2A).

No morphological differences were observed in the structure of thyroid glands between the rats treated with CMN (D1 group) and the control group. Thyroids of both the control and CMN-treated animals displayed a predominance of vacuolated colloid in follicles with cubic epithelium (Fig. 2A, B). Rats treated with PTU (D2 group) exhibited symptoms of hypothyroidism, such as hyperplasia of the follicular epithelium and more pronounced colloid vacuolation in the vicinity of the epithelium compared to the control group (Fig. 1B, 2C). The D2 group also had a higher frequency of epithelial ingrowths into the follicular lumen and significantly more PAS-positive vacuoles in thyrocytes compared to the control group (Fig. 1B, 2C). The thyroid of rats in the D3 group, which received a combination of PTU and CMN, showed strong colloid vacuolization and a reduction in colloid volume compared to the control group. The colloid in the D3 group showed the least intense staining in the PAS reaction compared to the other groups (Fig. 2D).

Histomorphometric evaluation

In control rats, three size classes of thyroid follicles were observed: small follicles with a diameter of 18–50 μm , medium-sized follicles ranging from 51 to 90 μm , and large follicles exceeding 90 μm in diameter (Fig. 3).

There was no significant difference in follicle size between the control group and rats treated with CMN. However, in rats treated with PTU (D2 group), there was a statistically significant decrease in the number of small follicles and an increase in medium-sized follicles compared to the control group (Fig. 3B). In the rats that received both CMN and PTU (D3 group), there was a significant increase in the percentage of small follicles and a decrease in medium-sized follicles compared to the rats treated with PTU alone. However, the difference in the number of small and medium

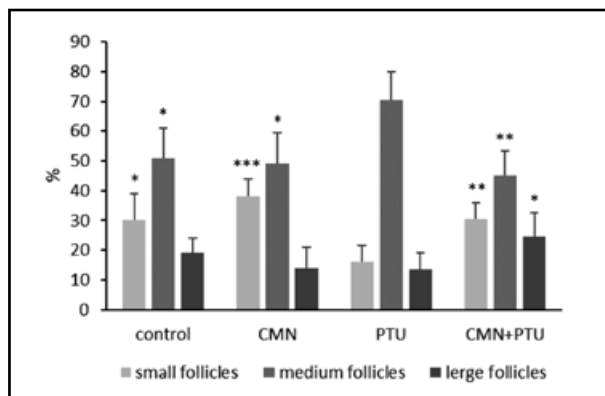


Figure 3. The influence of curcumin (CMN) and/or propylthiouracil (PTU) treatment on the percentage of size classes of the thyroid follicles. The rats were treated as described in the legend in Fig. 1. Size classes were defined as described in Methods. Values are means \pm SD, * $P < 0.05$, ** $P < 0.01$, *** $P < 0.001$ vs. PTU. Number of animals *per* group: control — 5, CMN — 5, PTU — 6, PTU + CMN — 6.

follicles between the D3 group and the control group was not statistically significant. Notably, the number of large follicles in the D3 group increased significantly compared to the PTU group (Fig. 3).

The morphometric analysis of the follicular epithelium showed a significant increase in epithelial height in the D2 group compared to both the D1 and control groups (Fig. 4A). Furthermore, there was a significant increase in epithelial height in the D3 group of rats compared to the D1 and K groups. Interestingly, when CMN was administered along together PTU to rats in the D3 group, there was a decrease in the height of the secretory epithelium of the thyroid follicles compared to the group that received only PTU (D2).

The volume density of the colloid showed a significant decrease in both the D2 and D3 groups compared to the control and D1 groups (Fig. 4B). However, the administration of CMN did not significantly affect the reduction in colloid volume caused by the simultaneous administration of PTU compared to PTU treatment alone.

Histochemical analysis of cytochrome c oxidase reactivity in thyroid follicular epithelium

There was no significant difference in the intensity of histochemical reaction indicating the activity of cytochrome c oxidase between the control and CMN-treated rats. However, in the groups treated with PTU or PTU and CMN, the intensity of the histochemical reaction was usually stronger in comparison to the control or CMN-treated rats (Table 2).

In the columnar epithelium, a significantly higher CCO reactivity was observed in the groups of rats receiving PTU or PTU and CMN compared to the control

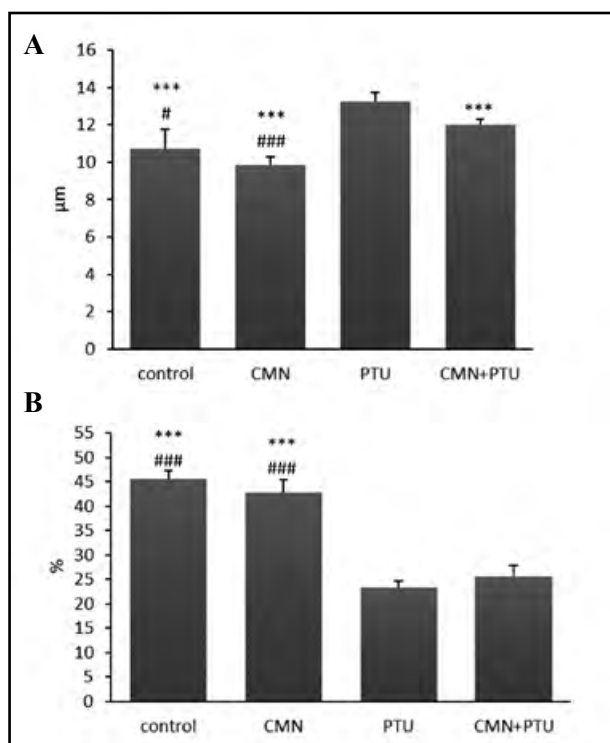


Figure 4. The influence of curcumin (CMN) and/or propylthiouracil (PTU) treatment on histomorphometric parameters of rat thyroid follicles. **A.** The height of follicular epithelium. **B.** The volume density of the colloid. The rats were treated as described in the legend in Fig. 1. Values are means \pm SD, *** $P < 0.001$ vs. PTU; # $P < 0.05$, ### $P < 0.001$ vs. CMN + PTU. Number of animals *per* group as in the legend in Fig. 3.

and the group treated with CMN alone (Table 2). Less variability in the intensity of histochemical reaction detecting CCO was noted in the cubic epithelium of the thyroid follicles. A significant increase in the intensity of the histochemical reaction in the cubic epithelium, compared to the control and the group treated with CMN alone, was noted only in rats receiving both PTU and CMN (Table 2).

Concentrations of free triiodothyronine and free thyroxine in rat serum

The serum level of FT3 did not show a significant change in the experimental D2 group (PTU-treated rats) compared to the control group. The difference in FT3 levels between D3 and the control group was statistically not significant (Table 2).

The serum concentration of FT4 significantly decreased in rats treated with PTU compared to the control group. However, when CMN and PTU were administered together, there was a significant increase in FT4 levels compared to the group that received only PTU (D2) (Table 2). Interestingly, the level of FT4 increased significantly after the administration of CMN alone (D1) compared to the control group (Table 2).

Discussion

Thyroid hormones play a crucial role in various important processes in the body, including cell proliferation and differentiation, as well as regulation of metabolism in various organs. Therefore, any inhibition in the synthesis and secretion of thyroid hormones can lead to numerous health issues. Our research has demonstrated that CMN, a polyphenol found in turmeric and a component of curry spice, has a stimulating effect on the thyroid gland in rats [16]. To investigate whether CMN can modify thyroid function under hypothyroid conditions, we induced weak hypothyroidism in rats using PTU, an established experimental model, and conducted histomorphometric, histochemical and hormonal analyses.

Our studies have shown that CMN can alleviate PTU-induced hypothyroidism at a dosage of 1 mg/kg b.w. Disturbances in the thyroid gland's secretory function after PTU administration, indicated by a significant decrease in FT4 levels, correlated with morphological changes in the thyroid gland. The administration of PTU resulted in hypertrophy and

Table 2. The influence of curcumin (CMN) and/or propylthiouracil (PTU) treatment on the relative levels of cytochrome c oxidase (CCO) histochemical reactivity in the thyroid secretory epithelium and the serum levels of FT3 and FT4

Group	The reactivity of cytochrome c oxidase in various types of epithelium (OD)		Serum concentration of thyroid hormones (pmol/L)	
	Cubic epithelium	Columnar epithelium	FT3	FT4
Control	80.6 \pm 7.2	79.9 \pm 4.8	6.3 \pm 0.6	23.9 \pm 1.4
CMN	82.2 \pm 5.1	81.9 \pm 4.3	6.2 \pm 1.1	26.0 \pm 0.9*
PTU	85.3 \pm 4.7	87.7 \pm 3.6*	6.4 \pm 1.2	21.7 \pm 1.4*. [^]
CMN + PTU	88.8 \pm 3.4*	89.0 \pm 4.4*	7.5 \pm 0.8	24.0 \pm 1.6 [#]

The rats were treated with CMN (100 mg/kg b.w.) and/or PTU — propylthiouracil (1 mg/kg b.w.) for 30 days. Relative CCO activity is expressed as degrees of optical density (OD) as described in Methods. Values are means \pm SD. One-way analysis of variance with the Newman-Keuls *post hoc* test was used to determine significant differences between groups * $P < 0.05$ vs. control; # $P < 0.05$ vs. PTU; [^] $P < 0.001$ vs. CMN.

hyperplasia of the secretory epithelium, along with an increase in the proportion of medium-sized follicles at the expense of small ones. A strong vacuolization of the thyrocyte cytoplasm after treatment with PTU was visible, which indicates the stimulation of their resorption activity [33]. The observed morphological changes are consistent with the findings of Yamasaki *et al.* who showed enlargement of the thyroid glands, an increase in their mass and hypertrophy of the follicular epithelium in Sprague-Dawley rats after treatment with PTU at a dose of 1 mg/kg b.w. for 28 days [26]. A significant decrease in the level of thyroid hormones was also demonstrated [26]. Similar changes in rat thyroid morphology, manifested by hypertrophy and hyperplasia of the follicular epithelium and a reduction in the amount of colloid, were observed after the use of bromide in rats. [34].

The observed increase in the reactivity of CCO in the thyrocytes of rats receiving PTU may indicate the presence of compensatory mechanisms in conditions of hypothyroidism. It should be noted that thyroid hormones interact with mitochondrial CCO and can influence its activity. *In vitro* studies have shown that T3 inhibits CCO activity with a K_i of 200 μM , while T4 has a K_i of approximately 100 μM [35]. Additionally, it is known from other studies that oxidative metabolism in thyrocytes is enhanced by the action of TSH [36]. In addition, ATP is required to enhance synthetic thyroid function by TSH [23]. Although we were not able to measure rat TSH serum concentration it should be noted that Yi *et al.* observed similar morphological changes in the thyroid gland of rats under the influence of PTU, which were attributed to an increase in TSH secretion due to reduced biosynthetic function of the thyroid gland [37]. The lack of significant differences in the level of FT3 between the PTU-treated group and the control group, despite a significant decrease in the level of FT4, along with the observed morphological and histochemical changes in the thyroid follicles, may indicate compensatory changes that occurred in the group treated with a low dose of PTU.

It can be assumed that PTU did not sufficiently inhibit the activity of iodothyronine deiodinases at a concentration of 1 mg/kg b.w. In rats, 60% of T3 is produced by extra-thyroidal deiodinases in peripheral tissues, the activity of which is stimulated by thyroid hormones [38, 39]. Due to the decrease in T4 level, a greater role in the production of T3 may have been played by thyroid deiodinase which is activated by TSH-stimulated cAMP production [40]. The mentioned mechanism could contribute to maintaining FT3 secretion at the control level in the rats treated with a relatively low dose of the PTU. Moreover, CCO reactivity increased in the thyroid of PTU-tre-

ated group, which may have provided ATP for cAMP production.

Similar changes manifested by a decrease in total T4 and FT4 levels and no effect on the level of total T3 in blood serum were observed by other authors after the administration of low doses of PTU to rats, below 1 mg/kg b.w. [41]. However, in other studies, a 50% greater decrease in the level of FT4 in the blood serum was observed compared to FT3 in the rats treated with PTU at a dose of 1 mg/kg b.w. [42].

The modifying effect of CMN on thyroid function in the presence of hypothyroidism is supported by a significant increase in FT4 secretion in the group treated with both CMN and PTU, compared to the group receiving PTU alone. Additionally, the co-administration of CMN resulted in the restoration of normal, found in control rats, proportion of small and medium-sized follicles and a decrease in the height of the secretory epithelium of the thyroid gland, in contrast to the group treated with PTU only. These findings suggest that CMN stimulated the activity of thyrocytes and enhanced the process of biosynthesis and colloid resorption in hypothyroid conditions, as evidenced by the large colloid vacuolation observed in the PTU + CMN group in this study. Consequently, the level of FT4 in rats receiving both compounds returned to control values and showed a significant increase compared to the group treated solely with PTU.

The observed effect of CMN can be further supported by a significant increase in CCO reactivity in the secretory epithelium, which was highest in the group treated with both PTU and CMN. Other studies have suggested that CMN may increase the expression of proteins involved in oxidative phosphorylation in the liver of mice on a high-fructose diet [43]. Our previous study indicated that CMN did not improve thyroid function in aged male rats (18-month-old) with reduced production of thyroid hormones in comparison to 3-month-old ones [16]. This suggests that the effectiveness of CMN in enhancing thyroid function may be compromised in older individuals due to age-related metabolic slowdown [44]. Mitochondrial oxygen utilization decreases with age, leading to disruptions in ATP synthesis, which is essential for the function of the Na/K pump driving the transport of iodide ions into the thyrocytes [45]. However, in young rats with PTU-induced hypothyroidism, CMN may stimulate basal metabolism in thyrocytes and increase the biosynthetic activity and consumption of accumulated colloid. The *in silico* study showed that ferulic acid interacts with the allosteric site of TPO, increasing its activity [20]. In addition, in thyroid cancer cells, curcumin enhanced the expression of TPO and sodium iodide symporter (NIS). This polyphenol

increased glycosylation and membrane trafficking of NIS by inhibiting the PI3K-AKT-mTOR pathway [46]. Curcumin also significantly increased the expression of NIS mRNA and thyroglobulin production inhibited by hyaluronan oligosaccharide treatment in primary human thyrocytes [47]. Other studies have also supported the findings by demonstrating that CMN, when administered to rats at a dose of 60 mg/kg body weight for 6 weeks, significantly increased the serum levels of FT4, which had been lowered by the administration of lithium carbonate [48]. Additionally, CMN exhibited antioxidant and anti-inflammatory effects and restored the normal morphology of the thyroid gland, which had been altered by the action of lithium carbonate [48]. In other studies, it was shown that the administration of CMN to rats after gas explosion-induced traumatic brain injury significantly increased the level of FT3 and FT4 to control values [49]. Interestingly, consumption of turmeric rich in CMN in goiter-prone areas in Pakistan reduces the risk of developing this disease [50].

CMN may also exert an antiproliferative effect on the thyroid gland, leading to a reduction in the hyperplasia of the follicular epithelium and a decrease in thyroid weight in the rats treated with PTU together with CMN compared to the group receiving only PTU [17].

The results of the study provide evidence for the protective effect of CMN against hypothyroidism in conditions of weak antithyroid effects of PTU. This protective effect is indicated by the stimulation of CCO reactivity, which provides ATP necessary for thyroid biosynthetic process, increased colloid resorption and enhanced FT4 secretion. Thus, it can be speculated that CMN activity may protect the thyroid gland against the effects of environmental goitrogens.

Article information

Data availability statement

The results of my own research are presented.

Ethics statement

The experiments were carried out with the consent of the Local Ethics Committee at the Jagiellonian University (no. 64/OP/2004).

Author contributions

M. Papież is the author of the idea, the contractor of the laboratory part, the contractor of statistical and graphical studies of the results, and the author of the text.

Funding

The study was partially supported by the Jagiellonian University Program nr WŁ/349/P/F.

Acknowledgments

The author thanks the staff of Prof. Krystyna Sztefko from the Department of Clinical Biochemistry, Institute of Pediatrics, Jagiellonian University Medical College, Kraków, Poland, for the analysis of the FT3 and FT4 using the radioimmunological method and Mr. M. Kaja for technical assistance.

Conflict of interest

The author declares that there is no conflict of interest.

References

- Nelson KM, Dahlin JL, Bisson J, et al. The essential medicinal chemistry of curcumin. *J Med Chem.* 2017; 60(5): 1620–1637, doi: [10.1021/acs.jmedchem.6b00975](https://doi.org/10.1021/acs.jmedchem.6b00975), indexed in Pubmed: [28074653](https://pubmed.ncbi.nlm.nih.gov/28074653/).
- Papież MA. The influence of curcumin and (-)-epicatechin on the genotoxicity and myelosuppression induced by etoposide in bone marrow cells of male rats. *Drug Chem Toxicol.* 2013; 36(1): 93–101, doi: [10.3109/01480545.2012.726626](https://doi.org/10.3109/01480545.2012.726626), indexed in Pubmed: [23078406](https://pubmed.ncbi.nlm.nih.gov/23078406/).
- Fuloria S, Mehta J, Chandel A, et al. A comprehensive review on the therapeutic potential of linn. in relation to its major active constituent curcumin. *Front Pharmacol.* 2022; 13: 820806, doi: [10.3389/fphar.2022.820806](https://doi.org/10.3389/fphar.2022.820806), indexed in Pubmed: [35401176](https://pubmed.ncbi.nlm.nih.gov/35401176/).
- National Toxicology Program. NTP Toxicology and Carcinogenesis Studies of Turmeric Oleoresin (CAS No. 8024-37-1) (Major Component 79%-85% Curcumin, CAS No. 458-37-7) in F344/N Rats and B6C3F1 Mice (Feed Studies). *Natl Toxicol Program Tech Rep Ser.* 1993; 427: 1–275, indexed in Pubmed: [12616304](https://pubmed.ncbi.nlm.nih.gov/12616304/).
- Doerge DR, Sheehan DM. Goitrogenic and estrogenic activity of soy isoflavones. *Environ Health Perspect.* 2002; 110 Suppl 3(Suppl 3): 349–353, doi: [10.1289/ehp.02110s3349](https://doi.org/10.1289/ehp.02110s3349), indexed in Pubmed: [12060828](https://pubmed.ncbi.nlm.nih.gov/12060828/).
- de Carvalho DP, Rego KG, Rosenthal D. Thyroid peroxidase in dysmorphogenetic goiters with organification and thyroglobulin defects. *Thyroid.* 1994; 4(4): 421–426, doi: [10.1089/thy.1994.4.421](https://doi.org/10.1089/thy.1994.4.421), indexed in Pubmed: [7711505](https://pubmed.ncbi.nlm.nih.gov/7711505/).
- Gonçalves CF, Santos MC, Ginabreda MG, et al. Flavonoid rutin increases thyroid iodide uptake in rats. *PLoS One.* 2013; 8(9): e73908, doi: [10.1371/journal.pone.0073908](https://doi.org/10.1371/journal.pone.0073908), indexed in Pubmed: [24023911](https://pubmed.ncbi.nlm.nih.gov/24023911/).
- Paunkov A, Chartoumpakis DV, Ziros PG, et al. Impact of antioxidant natural compounds on the thyroid gland and implication of the keap1/nrf2 signaling pathway. *Curr Pharm Des.* 2019; 25(16): 1828–1846, doi: [10.2174/1381612825666190701165821](https://doi.org/10.2174/1381612825666190701165821), indexed in Pubmed: [31267862](https://pubmed.ncbi.nlm.nih.gov/31267862/).
- Sartelet H, Serghat S, Lobstein A, et al. Flavonoids extracted from fonio millet (*Digitaria exilis*) reveal potent antithyroid properties. *Nutrition.* 1996; 12(2): 100–106, doi: [10.1016/0899-9007\(96\)90707-8](https://doi.org/10.1016/0899-9007(96)90707-8), indexed in Pubmed: [8724380](https://pubmed.ncbi.nlm.nih.gov/8724380/).
- The Latest Research and Development of Minerals in Human Nutrition. *Advances in Food and Nutrition Research.* 2021, doi: [10.1016/s1043-4526\(21\)x0003-4](https://doi.org/10.1016/s1043-4526(21)x0003-4).
- Loh KC. Amiodarone-induced thyroid disorders: a clinical review. *Postgrad Med J.* 2000; 76(893): 133–140, doi: [10.1136/pmj.76.893.133](https://doi.org/10.1136/pmj.76.893.133), indexed in Pubmed: [10684321](https://pubmed.ncbi.nlm.nih.gov/10684321/).

12. Morariu ID, Avasilcai L, Cioanca O, et al. The effects of honey sulfonamides on immunological and hematological parameters in wistar rats. *Medicina (Kaunas)*. 2022; 58(11), doi: [10.3390/medicina58111558](https://doi.org/10.3390/medicina58111558), indexed in Pubmed: [36363515](https://pubmed.ncbi.nlm.nih.gov/36363515/).
13. Elshorbagy HH, Barseem NF, Suliman HA, et al. The impact of antiepileptic drugs on thyroid function in children with epilepsy: new versus old. *Iran J Child Neurol*. 2020; 14(1): 31–41, indexed in Pubmed: [32021626](https://pubmed.ncbi.nlm.nih.gov/32021626/).
14. Singh S, Panda V, S S, et al. Protective effect of a polyherbal bioactive fraction in propylthiouracil-induced thyroid toxicity in rats by modulation of the hypothalamic-pituitary-thyroid and hypothalamic-pituitary-adrenal axes. *Toxicol Rep*. 2020; 7: 730–742, doi: [10.1016/j.toxrep.2020.06.002](https://doi.org/10.1016/j.toxrep.2020.06.002), indexed in Pubmed: [32579134](https://pubmed.ncbi.nlm.nih.gov/32579134/).
15. Di Dalmazi G, Giuliani C. Plant constituents and thyroid: A revision of the main phytochemicals that interfere with thyroid function. *Food Chem Toxicol*. 2021; 152: 112158, doi: [10.1016/j.fct.2021.112158](https://doi.org/10.1016/j.fct.2021.112158), indexed in Pubmed: [33789121](https://pubmed.ncbi.nlm.nih.gov/33789121/).
16. Papiiez MA, Kaja M, Gebarowska A. Age-dependent different action of curcumin in thyroid of rat. *Folia Histochem Cytobiol*. 2008; 46(2): 205–211, doi: [10.2478/v10042-008-0031-6](https://doi.org/10.2478/v10042-008-0031-6), indexed in Pubmed: [18519239](https://pubmed.ncbi.nlm.nih.gov/18519239/).
17. Abdelaleem MM, El-Tahawy NF, Abozaid SM, et al. Possible protective effect of curcumin on the thyroid gland changes induced by sodium fluoride in albino rats: light and electron microscopic study. *Endocr Regul*. 2018; 52(2): 59–68, doi: [10.2478/enr-2018-0007](https://doi.org/10.2478/enr-2018-0007), indexed in Pubmed: [29715188](https://pubmed.ncbi.nlm.nih.gov/29715188/).
18. Abd El-Twab SM, Abdul-Hamid M. Curcumin mitigates lithium-induced thyroid dysfunction by modulating antioxidant status, apoptosis and inflammatory cytokines. *The Journal of Basic & Applied Zoology*. 2016; 76: 7–19, doi: [10.1016/j.jobaz.2016.10.001](https://doi.org/10.1016/j.jobaz.2016.10.001).
19. Mishra P, Paital B, Jena S, et al. Possible activation of NRF2 by Vitamin E/Curcumin against altered thyroid hormone induced oxidative stress via NFκB/AKT/mTOR/KEAP1 signalling in rat heart. *Sci Rep*. 2019; 9(1): 7408, doi: [10.1038/s41598-019-43320-5](https://doi.org/10.1038/s41598-019-43320-5), indexed in Pubmed: [31092832](https://pubmed.ncbi.nlm.nih.gov/31092832/).
20. Habza-Kowalska E, Kaczor AA, Bartuzi D, et al. Some dietary phenolic compounds can activate thyroid peroxidase and inhibit lipoxygenase-preliminary study in the model systems. *Int J Mol Sci*. 2021; 22(10), doi: [10.3390/ijms22105108](https://doi.org/10.3390/ijms22105108), indexed in Pubmed: [34065957](https://pubmed.ncbi.nlm.nih.gov/34065957/).
21. Asghar MY, Lassila T, Törnquist K. Calcium signaling in the thyroid: friend and foe. *Cancers (Basel)*. 2021; 13(9), doi: [10.3390/cancers13091994](https://doi.org/10.3390/cancers13091994), indexed in Pubmed: [33919125](https://pubmed.ncbi.nlm.nih.gov/33919125/).
22. Grigorenko B, Polyakov I, Nemukhin A. Mechanisms of ATP to cAMP conversion catalyzed by the mammalian adenylyl cyclase: a role of magnesium coordination shells and proton wires. *J Phys Chem B*. 2020; 124(3): 451–460, doi: [10.1021/acs.jpcc.9b07349](https://doi.org/10.1021/acs.jpcc.9b07349), indexed in Pubmed: [31881811](https://pubmed.ncbi.nlm.nih.gov/31881811/).
23. Jing Li, Zhang Q. Intrathyroidal feedforward and feedback network regulating thyroid hormone synthesis and secretion. *Front Endocrinol (Lausanne)*. 2022; 13: 992883, doi: [10.3389/fendo.2022.992883](https://doi.org/10.3389/fendo.2022.992883), indexed in Pubmed: [36187113](https://pubmed.ncbi.nlm.nih.gov/36187113/).
24. Hamidie RDR, Shibaguchi T, Yamada T, et al. Curcumin induces mitochondrial biogenesis by increasing cyclic AMP levels via phosphodiesterase 4A inhibition in skeletal muscle. *Br J Nutr*. 2021; 126(11): 1642–1650, doi: [10.1017/S0007114521000490](https://doi.org/10.1017/S0007114521000490), indexed in Pubmed: [33551001](https://pubmed.ncbi.nlm.nih.gov/33551001/).
25. Rouse M, Younès A, Egan JM. Resveratrol and curcumin enhance pancreatic β-cell function by inhibiting phosphodiesterase activity. *J Endocrinol*. 2014; 223(2): 107–117, doi: [10.1530/JOE-14-0335](https://doi.org/10.1530/JOE-14-0335), indexed in Pubmed: [25297556](https://pubmed.ncbi.nlm.nih.gov/25297556/).
26. Yamasaki K, Tago Y, Nagai K, et al. Comparison of toxicity studies based on the draft protocol for the ‘Enhanced OECD Test Guideline no. 407’ and the research protocol of ‘Pubertal Development and Thyroid Function in Immature Male Rats’ with 6-n-propyl-2-thiouracil. *Arch Toxicol*. 2002; 76(9): 495–501, doi: [10.1007/s00204-002-0371-5](https://doi.org/10.1007/s00204-002-0371-5), indexed in Pubmed: [12242606](https://pubmed.ncbi.nlm.nih.gov/12242606/).
27. Shukla Y, Arora A, Taneja P. Antimutagenic potential of curcumin on chromosomal aberrations in Wistar rats. *Mutat Res*. 2002; 515(1-2): 197–202, doi: [10.1016/s1383-5718\(02\)00016-5](https://doi.org/10.1016/s1383-5718(02)00016-5), indexed in Pubmed: [11909768](https://pubmed.ncbi.nlm.nih.gov/11909768/).
28. Löw O. Studies on quantitative morphology. VI. Morphometry of colloid and epithelium in the thyroid gland. *Exp Pathol*. 1982; 22(1): 43–58, indexed in Pubmed: [7128722](https://pubmed.ncbi.nlm.nih.gov/7128722/).
29. Zieliński KW, Strzelecki M. Komputerowa analiza obrazu biomedycznego. Wydawnictwo Naukowe PWN, Warszawa 2002.
30. Pearse AGE. Histochemistry. Theoretical and Applied. Volume one: Preparative and optical technology, 4th ed. Churchill-Livingstone, London 1980.
31. Paczkowska K, Otlewska A, Loska O, et al. Laboratory interference in the thyroid function test. *Endokrynol Pol*. 2020; 71(6): 551–560, doi: [10.5603/EP.a2020.0079](https://doi.org/10.5603/EP.a2020.0079), indexed in Pubmed: [33378071](https://pubmed.ncbi.nlm.nih.gov/33378071/).
32. Henning Y, Vole C, Begall S, et al. Unusual ratio between free thyroxine and free triiodothyronine in a long-lived mole-rat species with bimodal ageing. *PLoS One*. 2014; 9(11): e113698, doi: [10.1371/journal.pone.0113698](https://doi.org/10.1371/journal.pone.0113698), indexed in Pubmed: [25409169](https://pubmed.ncbi.nlm.nih.gov/25409169/).
33. Rajkovic V, Matavulj M, Johansson O. Light and electron microscopic study of the thyroid gland in rats exposed to power-frequency electromagnetic fields. *J Exp Biol*. 2006; 209(Pt 17): 3322–3328, doi: [10.1242/jeb.02375](https://doi.org/10.1242/jeb.02375), indexed in Pubmed: [16916968](https://pubmed.ncbi.nlm.nih.gov/16916968/).
34. Velický J, Titlbach M, Lojda Z, et al. Long-term action of potassium bromide on the rat thyroid gland. *Acta Histochem*. 1998; 100(1): 11–23, doi: [10.1016/S0065-1281\(98\)80003-2](https://doi.org/10.1016/S0065-1281(98)80003-2), indexed in Pubmed: [9542578](https://pubmed.ncbi.nlm.nih.gov/9542578/).
35. Oleynikov IP, Sudakov RV, Azarkina NV, et al. Direct interaction of mitochondrial cytochrome c oxidase with thyroid hormones: evidence for two binding sites. *Cells*. 2022; 11(5), doi: [10.3390/cells11050908](https://doi.org/10.3390/cells11050908), indexed in Pubmed: [35269529](https://pubmed.ncbi.nlm.nih.gov/35269529/).
36. Hood A, Liu YP, Gattone VH, et al. Sensitivity of thyroid gland growth to thyroid stimulating hormone (TSH) in rats treated with antithyroid drugs. *Toxicol Sci*. 1999; 49(2): 263–271, doi: [10.1093/toxsci/49.2.263](https://doi.org/10.1093/toxsci/49.2.263), indexed in Pubmed: [10416271](https://pubmed.ncbi.nlm.nih.gov/10416271/).
37. Yi X, Yamamoto K, Shu Lu, et al. Effects of propylthiouracil (PTU) administration on the synthesis and secretion of thyroglobulin in the rat thyroid gland: a quantitative immuno-electron microscopic study using immunogold technique. *Endocr Pathol*. 1997; 8(4): 315–325, doi: [10.1007/BF02739934](https://doi.org/10.1007/BF02739934), indexed in Pubmed: [12114793](https://pubmed.ncbi.nlm.nih.gov/12114793/).
38. Chanoine JP, Braverman LE, Farwell AP, et al. The thyroid gland is a major source of circulating T3 in the rat. *J Clin Invest*. 1993; 91(6): 2709–2713, doi: [10.1172/JCI116510](https://doi.org/10.1172/JCI116510), indexed in Pubmed: [8514878](https://pubmed.ncbi.nlm.nih.gov/8514878/).
39. Bruinstroop E, van der Spek A, Boelen A. Role of hepatic deiodinases in thyroid hormone homeostasis and liver metabolism, inflammation and fibrosis. *Eur Thyroid J*. 2023 [Epub ahead of print]; 12(3), doi: [10.1530/ETJ-22-0211](https://doi.org/10.1530/ETJ-22-0211), indexed in Pubmed: [36892852](https://pubmed.ncbi.nlm.nih.gov/36892852/).
40. Lavado-Autric R, Calvo RM, de Mena RM, et al. Deiodinase activities in thyroids and tissues of iodine-deficient female rats. *Endocrinology*. 2013; 154(1): 529–536, doi: [10.1210/en.2012-1727](https://doi.org/10.1210/en.2012-1727), indexed in Pubmed: [23142811](https://pubmed.ncbi.nlm.nih.gov/23142811/).
41. Bansal R, Tighe D, Danai A, et al. Polybrominated diphenyl ether (DE-71) interferes with thyroid hormone action independent of effects on circulating levels of thyroid hormone in male rats. *Endocrinology*. 2014; 155(10): 4104–4112, doi: [10.1210/en.2014-1154](https://doi.org/10.1210/en.2014-1154), indexed in Pubmed: [25060363](https://pubmed.ncbi.nlm.nih.gov/25060363/).
42. Nambiar PR, Palanisamy GS, Okerberg C, et al. Toxicities associated with 1-month treatment with propylthiouracil (PTU)

- and methimazole (MMI) in male rats. *Toxicol Pathol.* 2014; 42(6): 970–983, doi: [10.1177/0192623313502708](https://doi.org/10.1177/0192623313502708), indexed in Pubmed: [24067673](https://pubmed.ncbi.nlm.nih.gov/24067673/).
43. Silva-Gaona OG, Hernández-Ortiz M, Vargas-Ortiz K, et al. Curcumin prevents proteins expression changes of oxidative phosphorylation, cellular stress response, and lipid metabolism proteins in liver of mice fed a high-fructose diet. *J Proteomics.* 2022; 263: 104595, doi: [10.1016/j.jprot.2022.104595](https://doi.org/10.1016/j.jprot.2022.104595), indexed in Pubmed: [35490921](https://pubmed.ncbi.nlm.nih.gov/35490921/).
44. Lima T, Li TY, Mottis A, et al. Pleiotropic effects of mitochondria in aging. *Nat Aging.* 2022; 2(3): 199–213, doi: [10.1038/s43587-022-00191-2](https://doi.org/10.1038/s43587-022-00191-2), indexed in Pubmed: [37118378](https://pubmed.ncbi.nlm.nih.gov/37118378/).
45. Carvalho DP, Dupuy C. Thyroid hormone biosynthesis and release. *Mol Cell Endocrinol.* 2017; 458: 6–15, doi: [10.1016/j.mce.2017.01.038](https://doi.org/10.1016/j.mce.2017.01.038), indexed in Pubmed: [28153798](https://pubmed.ncbi.nlm.nih.gov/28153798/).
46. Zhang Li, Xu S, Cheng X, et al. Curcumin enhances the membrane trafficking of the sodium iodide symporter and augments radioiodine uptake in dedifferentiated thyroid cancer cells suppression of the PI3K-AKT signaling pathway. *Food Funct.* 2021; 12(18): 8260–8273, doi: [10.1039/d1fo01073e](https://doi.org/10.1039/d1fo01073e), indexed in Pubmed: [34323243](https://pubmed.ncbi.nlm.nih.gov/34323243/).
47. Ruggeri R, Minuti A, Aliquo F, et al. Curcumin attenuates the pro-inflammatory response induced by hyaluronan oligosaccharides in human thyroid fibroblasts and thyrocytes. *Endocrine Abstracts.* 2022, doi: [10.1530/endoabs.81.p742](https://doi.org/10.1530/endoabs.81.p742).
48. Abd El-Twab SM, Abdul-Hamid M. Curcumin mitigates lithium-induced thyroid dysfunction by modulating antioxidant status, apoptosis and inflammatory cytokines. *The Journal of Basic & Applied Zoology.* 2016; 76: 7–19, doi: [10.1016/j.jobaz.2016.10.001](https://doi.org/10.1016/j.jobaz.2016.10.001).
49. Dong X, Deng L, Yao S, et al. Protective effects of curcumin against thyroid hormone imbalance after gas explosion-induced traumatic brain injury via activation of the hypothalamic-pituitary-thyroid axis in male rats. *Environ Sci Pollut Res Int.* 2022; 29(49): 74619–74631, doi: [10.1007/s11356-022-20943-2](https://doi.org/10.1007/s11356-022-20943-2), indexed in Pubmed: [35641736](https://pubmed.ncbi.nlm.nih.gov/35641736/).
50. Jawa A, Jawad A, Riaz SH, et al. Turmeric use is associated with reduced goitrogenesis: Thyroid disorder prevalence in Pakistan (THYPAK) study. *Indian J Endocrinol Metab.* 2015; 19(3): 347–350, doi: [10.4103/2230-8210.152768](https://doi.org/10.4103/2230-8210.152768), indexed in Pubmed: [25932388](https://pubmed.ncbi.nlm.nih.gov/25932388/).

Submitted: 13 July, 2023

Accepted after reviews: 4 September, 2023

Available as AoP: 14 September, 2023