

Effect of human papillomavirus on cell cycle-related proteins p16INK4A, p21waf1/cip1, p53 and cyclin D1 in sinonasal inverted papilloma and laryngeal carcinoma. An *in situ* hybridization study

Olga Stasikowska-Kanicka, Małgorzata Wągrowka-Danilewicz, Marian Danilewicz

Department of Nephropathology, Medical University of Lodz, Poland

Abstract: Human papillomavirus (HPV) infection is implicated as an important risk factor in the development of head and neck cancers. Many studies focusing on the relationships between HPV infection and cell cycle proteins immunoeexpression in laryngeal lesions have provided contradictory results. The aim of this study was to evaluate the relationships between HPV DNA presence and p16INK4a, p21waf1/cip1, p53 and cyclin D1 immunoeexpression in heterogenous HPV-positive and HPV-negative groups of laryngeal cancers and inverted papillomas. The HPV DNA expression was detected using an *in situ* hybridization method and immunoeexpression of p16INK4a, p21waf1/cip1, p53 and cyclin D1 using immunohistochemistry. The immunoeexpression of p21waf1/cip1 and p53 proteins was lower in the HPV-positive group compared to the HPV-negative group, although only the difference of p53 staining was statistically significant. The immunoeexpression of p16INK4a and cyclin D1 was significantly increased in the HPV-positive group compared to the HPV-negative group. The increased immunoeexpression of p16INK4a and cyclin D1, and the lower immunoeexpression of p21waf1/cip1 and p53 in the HPV-positive group compared to the HPV-negative group, supports the hypothesis that HPV may play an important role in cell cycle dysregulation. (*Folia Histochemica et Cytobiologica* 2011; Vol. 49, No. 1, pp. 34–40)

Key words: HPV, p16, p21, p53, cyclin D1

Introduction

Head and neck squamous cell carcinoma (HNSCC) is the sixth commonest cancer, with an annual incidence of approximately 400,000 worldwide. Although the principal risk factors for head and neck cancer remain tobacco and alcohol abuse, human papillomavirus (HPV) has recently been found to be etiologically associated with 15–35% of cases of HNSCC [1, 2]. Inverted papillomas are relatively rare epithelial tumors which are of considerable interest because they have a tendency to recur and to malignant trans-

formation. The nature and pathogenesis of inverted papillomas are debated. Viral infections are one of the potential etiological factors [3–8]. It is well known that HPVs are the etiological agents responsible for a number of pathologies affecting the stratified epithelia of the skin and anogenital and oropharyngeal sites [9–11].

Multiple molecular studies have reported that HPV-mediated tumorigenesis is mainly due to the activities of two viral oncoproteins: E6 and E7. HPV E6 is able to induce the degradation of p53 by direct binding to the ubiquitin ligase E6AP, inhibiting p53-dependent signaling upon stress stimuli, and contributing to tumorigenesis [12–14]. p53 is a well-known cellular tumor suppressor involved in processes such as cell cycle progression, DNA repair, chromatin remodeling, differentiation, apoptosis and senescence. Neutralization of the p53 tu-

Correspondence address: O. Stasikowska-Kanicka,
Department of Nephropathology, Medical University of Lodz,
Czechoslowacka Str. 8/10, 92–216 Lodz, Poland;
tel.: (+ 48 42) 675 76 33;
e-mail: olgast@op.pl

mor suppressor pathways by increased expression of HPV E6 and E7 oncogenes can cause disturbances in fundamental cell-cycle proteins [13, 14]. The expression of E6 and E7 alone is insufficient for cellular transformation [15], but the additional genetic alterations necessary for malignant progression in the setting of virus-induced genomic instability are unknown.

The cell cycle is controlled by a family of cyclins, cyclin dependent kinases (CDK) and their inhibitors (CDKI) through activating and inactivating phosphorylation events. Attention has been focused on the expression of G1 cyclins and cyclin dependent kinases, because the major regulatory events leading to cell proliferation and differentiation occur within the G1 phase of the cell cycle. Cyclin D1 is a G1 cyclin that regulates the transition from G1 to S phase, reaching maximum levels of expression and forming functional kinase complexes with CDK4 or CDK6, during the mid-G1 phase. Active CDK/cyclin complex could be regulated by binding to CDK-inhibitors p16INK4a and p21waf1/cip1, and inhibit cell cycle progression from G1 to S phase [16]. The p16INK4a functions also as a cyclin-dependent kinase inhibitor by inhibiting the CDK-induced phosphorylation of the retinoblastoma protein (pRb) [17, 18]. The phosphorylation of pRb induces the release of a transcription factor E2F from the bound form of E2F and pRb. The release of E2F results in G1-S transition [19]. Similarly as p16 protein, HPV induces the release of E2F through the binding of E7 to pRb. The released E2F stimulates the expression of genes which are involved in G1-S transition [20]. The inactivation of pRb by HPV E7 causes p16 overexpression, because p16 is regulated by negative feedback of pRb [20–23].

Protein p21waf1/cip1 exists in normal cells in complexes with cyclins, CDKs, and proliferating cell nuclear antigen. The induction of p21waf1/cip1 is associated with terminal differentiation, senescence, and apoptosis in several tissues. Furthermore, p21waf1/cip1 acts as a mediator of wild-type p53 protein, suppressing DNA replication under genomic stress [17, 21, 22]. Although p21waf1/cip1 functions as a putative tumor suppressor, mutations of the waf1/cip1 gene have been detected only rarely in human malignancies [24], but dysregulation of p16INK4A and p21waf1/cip1 have recently been reported in various human tumors.

Therefore, the aim of our study was to evaluate an immunoexpression of p16INK4a, p21waf1/cip1, p53 and cyclin D1 in HPV DNA positive and HPV DNA negative groups of squamous cells carcinoma of the larynx and sinonasal inverted papillomas.

Material and methods

Patients

A total of 23 formalin-fixed, paraffin-embedded tissue specimens of squamous cell carcinoma of the larynx, and ten sinonasal inverted papillomas, were retrieved from archival material (Chair of Pathomorphology, Medical University of Lodz). The age range for sinonasal inverted papillomas was 29 to 78 years (mean 54.19), and for squamous cell carcinomas of the larynx it was 47 to 82 years (mean 64.54). Paraffin tissue sections were stained with hematoxylin and eosin and the histological diagnoses were established according to WHO classification [25]. All examined cases of squamous cell carcinoma of the larynx and sinonasal inverted papillomas showed histological signs of HPV infections (koilocytosis, binucleated squamous cells and increased mitotic activity).

In situ hybridization

The ten sinonasal inverted papillomas and 23 squamous cell carcinomas of the larynx were analyzed using commercially available HPV DNA probes (Dako, Carpinteria, California, USA). Initially, a wide spectrum biotinylated probe for common HPV subtypes was used, according to the manufacturer's suggested protocol. The wide spectrum probe targets the genomic DNA of HPV types 6, 11, 16, 18, 31, 33, 35, 39, 45, 51 and 52. Further subtyping was carried out in the same way, using specific probes for HPV low risk — LR-HPV (HPV 6 and 11) and HPV high risk — HR-HPV (HPV 16, 18, 31, 33, 35, 39, 45, 51, 52, 56, 58, 59, 68). Afterwards, a catalyzed signal amplification system (prepared according to the instructions of the manufacturer) was used (GenPoint, CSA System for *in situ* hybridization; Dako).

Immunohistochemistry

Paraffin-embedded tissue sections were mounted onto SuperFrost slides, deparaffinized, then treated in a microwave oven in a solution of TRS (Target Retrieval Solution, pH 8.0, Dako) for 30 minutes (2 × 6 minutes 360W, 2 × 5 180W, 2 × 4 minutes 90W) and transferred to distilled water. Endogenous peroxidase activity was blocked by 0.3% hydrogen peroxide in distilled water for 30 minutes, and then sections were rinsed with tris-buffered saline (TBS, Dako, Denmark) and incubated for 30 minutes with primary mouse monoclonal antibody against: p16INK4a (Santa Cruz; clone F-12, dilution 1:100); p21waf1/cip1 (Dako; clone SX118, dilution 1:50); p53 (Dako; clone DO-7, dilution 1:50); and cy-

clin D1 (Dako; clone DCS-6, dilution 1:40). Immunoreactive proteins were visualized using EnVision-horse-radish peroxidase kit (Dako, Carpinteria, California, USA) according to the instructions of the manufacturer. Visualization was performed by incubating the sections in a solution of 3,3'-diaminobenzidine (DakoCytomation, Denmark). After washing, the sections were counter-stained with hematoxylin and coverslipped. For each antibody, and for each sample, a negative control was processed. Negative controls were carried out by incubation in the absence of the primary antibody and always yielded negative results.

Morphometry

The p16INK4a, p21waf1/cip1, p53 and cyclin D1 immunoreexpression was assessed by means of an image analysis system consisting of a PC equipped with a Pentagram graphical tablet, Indeo Fast card (frame grabber, true-color, real-time) produced by Indeo (Taiwan), and a color TV camera (Panasonic, Japan) coupled with a Carl Zeiss microscope (Germany). This system was programmed (MultiScan 8.08 software, produced by Computer Scanning System, Poland) to calculate the number of objects (automatic function with manual correction).

Statistical methods

Differences between groups were tested using unpaired Student's *t*-test preceded by evaluation of normality and Levene's test. The Mann-Whitney U test was used where appropriate. Results were deemed statistically significant if $p < 0.05$.

Results

Of the ten cases of sinonasal inverted papillomas, one was positive for HPV DNA using the wide spectrum probe and for HPV DNA subtypes 6 and 11. In addition, one case was positive for the HPV wide spectrum probe and for high risk HPV probe (Figure 1). Seven out of the 23 cases of squamous cell carcinoma were positive for HPV. Of the seven positive cases, five were positive for both HPV DNA probes: wide spectrum probe and HPV high risk probe (Figure 2). In addition, positive reactions for HPV DNA using high risk probe were noted in two examined cases of squamous cell carcinomas. All cases of squamous cell carcinomas and inverted papillomas positive for any HPV DNA probes were deemed to constitute the HPV-positive group, and all cases negative for HPV DNA were deemed to constitute the HPV-negative group. For statistical purposes, the patients were also

divided into a sinonasal inverted papillomas group (IP) and a laryngeal cancer group (Ca).

The p21waf1/cip1, p53 and cyclin D1 protein immunoreexpression was exclusively nuclear, whereas brown staining of cell nuclei and sometimes cytoplasm was interpreted as positive staining of the p16INK4a protein. The immunoreexpression of examined proteins was on a similar level in all cases of HPV-positive and HPV-negative inverted papillomas and carcinomas (Table 1). The morphometric data of immunoreexpression of p21waf1/cip1, p16INK4a, p53 and cyclin D1 in the HPV-positive and the HPV-negative group are shown in Table 2. The immunoreexpression of p21waf1/cip1 and p53 proteins was lower in the HPV-positive group compared to the HPV-negative group (Figures 3, 4), although only the difference of p53 immunostaining was statistically significant ($p < 0.03$). The immunoreexpression of p16INK4a and cyclin D1 was significantly increased in the HPV-positive group compared to the HPV-negative group ($p < 0.005$ and $p < 0.03$, respectively) (Figures 5, 6).

Discussion

HPV infection is an important risk factor in the development of head and neck cancers. At the molecular level, several differences are linked to HPV status, but studies focusing on relationships between HPV infection and the immunoreexpression of cell cycle proteins in laryngeal lesions have provided contradictory results.

Dysfunction of the TP53 tumor suppressor gene seems to be an early event in carcinogenesis and is associated with disease progression. It is well known that inactivation of p53 by HPV E6 plays a crucial role in cervical tumorigenesis [15]. So far, the impairment of p53 protein function and its impact on cellular proliferation has not been studied precisely in HPV-positive head and neck lesions. In our study, the immunoreexpression of p53 was significantly lower in the HPV-positive group compared to the HPV-negative group. Altavilla et al. [26] and Katori et al. [27] also showed decreased or no p53 immunoreexpression in the HPV-positive group compared to the HPV-negative group of inverted papillomas. Our results support the idea of neutralization of the p53 gene suppressor pathways by HPV proteins. In contrast to our results, p53 protein overexpression has been demonstrated in many preneoplastic and neoplastic lesions of the larynx [28–35].

The lower immunoreexpression of p21waf1/cip1 in the HPV-positive group compared to the HPV-negative group found in our study is similar to that seen in other studies. For instance, Katori et al. [27] described a significant decrease of immunoreexpression of

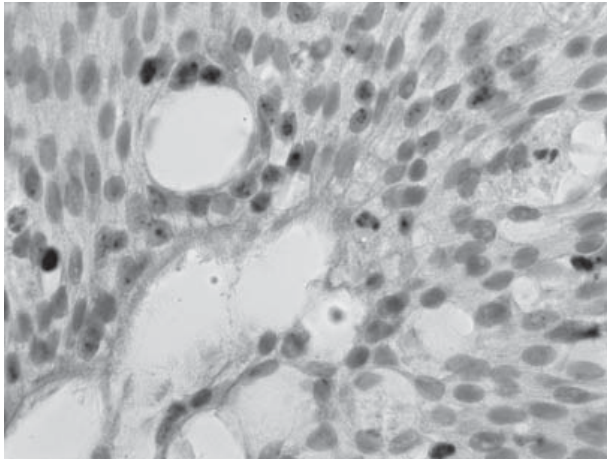


Figure 1. Positive DNA expression for high risk HPVs probe in sinonasal inverted papillomas. *In situ* hybridization (magnification $\times 200$)

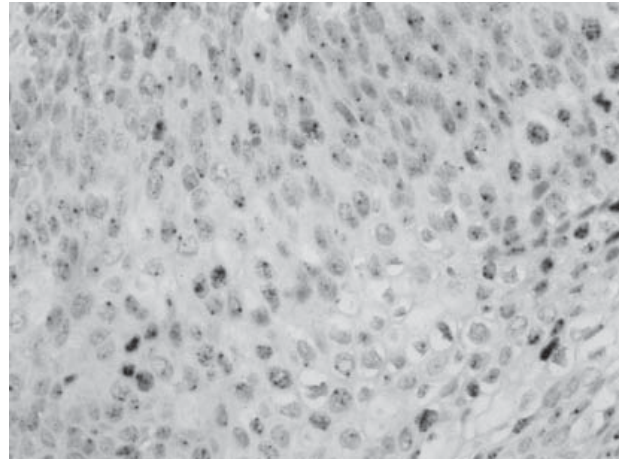


Figure 2. Positive DNA expression for high risk HPVs probe in squamous cell carcinoma of the larynx. *In situ* hybridization (magnification $\times 200$)

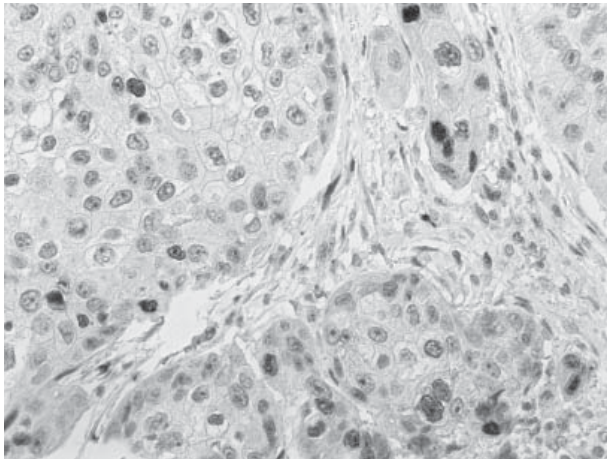


Figure 3. Decreased immunoreactivity of p53 in HPV-positive group. Immunohistochemistry (magnification $\times 200$)

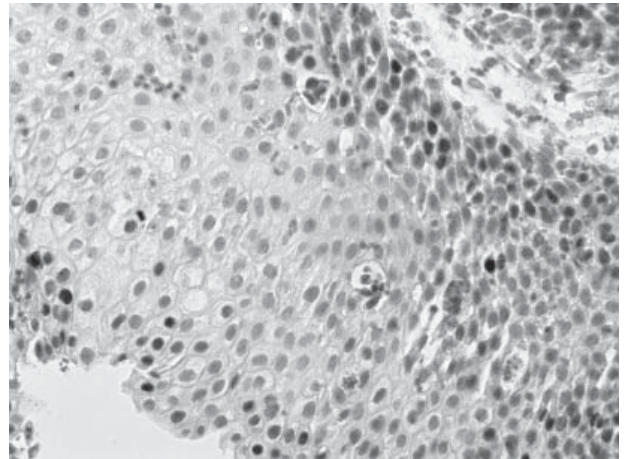


Figure 4. Decreased immunoreactivity of p21waf1/cip1 in HPV-positive group. Immunohistochemistry (magnification $\times 200$)

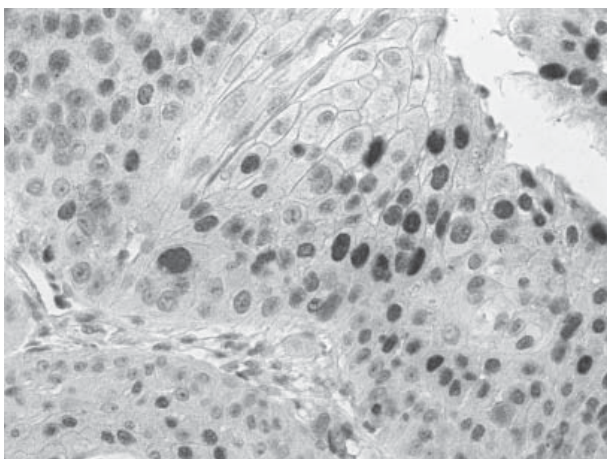


Figure 5. Increased immunoreactivity of p16INK4a in HPV-positive group. Immunohistochemistry (magnification $\times 200$)

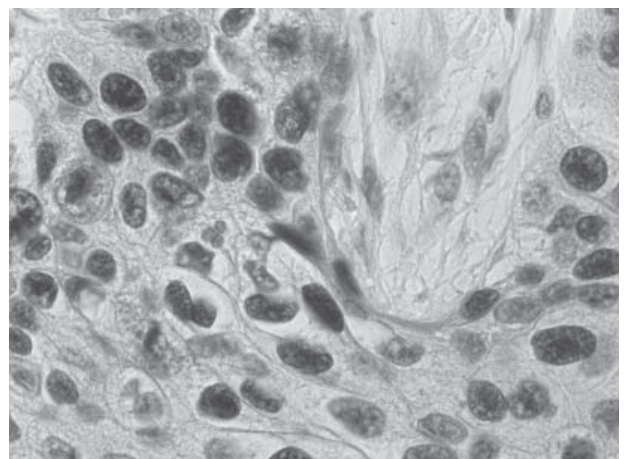


Figure 6. Increased immunoreactivity of cyclin D1 in HPV-positive group. Immunohistochemistry (magnification $\times 400$)

Table 1. Morphometric data of immunoexpression of p16, p21, p53 and cyclin D1 in IP and Ca groups

Groups		p16	p21	p53	Cyclin D1
IP n = 10	HPV (+) n = 2 HPV (-) n = 8	11.6 ± 7.6	34.7 ± 19.9	33.5 ± 16.1	8.9 ± 5.4
Ca n = 23	HPV (+) n = 7 HPV (-) n = 16	16.0 ± 9.8	27.9 ± 17.1	25.3 ± 9.7	12.1 ± 7.6
p		= 0.22 (NS)	= 0.32 (NS)	= 0.08 (NS)	= 0.23 (NS)

Ca — squamous cell carcinoma of the larynx; IP — sinonasal inverted papilloma; HPV — human papillomavirus; NS — not significant

Table 2. Summary of the morphometric data of the immunoexpression of p16, p21, p53 and cyclin D1 and results of *in situ* hybridization for HPV-positive (+) and HPV-negative (-) groups

Groups		HPV WSS	HPV 6/11	HPV high risk	p16	p21	p53	Cyclin D1
HPV (+)	IP n = 2	+	+	-	18.8 ± 11.2	27.4 ± 17.6	23.2 ± 11.4	13.2 ± 8.6
		+	-	+				
	Ca n = 7	+	-	+				
		+	-	+				
		+	-	+				
		+	-	+				
		-	-	+				
		-	-	+				
HPV (-)	IP n = 8	-	-	-	8.8 ± 6.4	35.2 ± 19.4	35.6 ± 14.4	7.8 ± 4.4
	Ca n = 16	-	-	-				
p					< 0.005	= 0.3 (NS)	< 0.03	< 0.03

WSP — wide spectrum probe; IP — sinonasal inverted papilloma; Ca — squamous cell carcinoma of the larynx; HPV — papillomavirus; NS — not significant

p21waf1/cip1 in the HPV 16/18 positive group compared to the HPV 16/18 negative group of inverted papillomas.

Moreover, Malanchi et al. [36, 37] clearly demonstrated that HPV E6 may strongly down-regulate p21waf1/cip1. In contrast to our results, Altavilla et al. [26] showed stronger p21waf1/cip1 immunoexpression in HPV-positive sinonasal inverted papillomas, and Hafkamp et al. [38] demonstrated that HPV positivity was strongly correlated with p21waf1/cip1 overexpression in tonsillar squamous cell carcinomas.

Our results indicated that down-regulation of p21waf1/cip1 and p53 was associated with the HPV-positive group of patients. It is well established that the prominent function of HPV E6 is inactivation of p53 and pro-apoptotic proteins, which results in resistance to apoptosis and increased chromosomal

instability [39, 40]. Overexpression of p21waf1/cip1 decreases E6-induced proliferation, indicating that the observed down-regulation of p21waf1/cip1 in HPV-positive cells is an important mechanism for cell cycle dysregulation. Lower immunoexpression of p21waf1/cip1 and p53 proteins in the HPV-positive group strongly suggests that HPV expression could be involved in p53 inactivation. It must be taken into consideration that all described divergences concerning p21waf1/cip1 and p53 immunoexpression may be connected with an independent way of p53 inactivation. Possible explanations for part of these discordant results are differences in the number of HPV-positive cases, and methodological issues. But it is also possible that HPV-induced oncogenesis and TP53 malfunction due to genetic abnormalities may be independent events during the tumorigenesis.

In our study, the immunoexpression of the p16INK4a protein and cyclin D1 was significantly increased in the HPV-positive group compared to the HPV-negative group of patients. The literature data suggests that overexpression of p16INK4a and cyclin D1 is strongly related to the presence of HPV16/18. According to Malanchi et al. [36, 37], HPV16 E6 could induce accumulation of p16 and cellular proliferation. König et al. [41] demonstrated a statistically significant relationship between the presence of HPV16/18 DNA and increased immunoexpression of p16INK4a in head and neck squamous cell cancers, but the HPV 6/11 presence was also significantly correlated with p16INK4a immunoactivity. Altavilla et al. [26] showed strong p16INK4A and cyclin D1 immunoexpression in HPV-positive sinonasal inverted papillomas, whereas Lako et al. [42] observed strong immunoexpression of p16INK4a in 18 out of 21 cases of HPV-positive laryngeal papillomas. In contrast to our results, Marsit et al. [43] showed that positive immunohistochemical D1 staining was inversely related to HPV 16 presence in 698 head and neck cancers. Also Hafkamp et al. [38], looking at tonsillar squamous cell carcinomas, described a strong correlation between HPV presence and down-regulation of cyclin D1. However, most researchers agree that high p16 immunoexpression might serve as a marker of HPV infection, and is a more cost-effective alternative to ISH and PCR.

HPV-positive tumors differ from HPV-negative tumors in many regards, including histological appearance, differentiation and prognosis. To the best of our knowledge, data concerning a correlation between the immunoexpression of cell cycle proteins and clinical parameters is scarce. It would be interesting to correlate our results with clinical parameters which are unavailable for current study (development of local recurrences in the papilloma group; staging parameters and survival data in the laryngeal cancer group). For this reason, further studies are necessary.

To sum up, our results support the hypothesis of involvement of HPV in the process of dysregulation of the cell cycle. Multiple discrepancies concerning immunoexpression of cell cycle proteins and HPV presence can indicate that various pathways of multistep tumorigenesis do exist. Further studies are needed to better understand the molecular basis of tumorigenesis and the role of HPV infection in this process.

Acknowledgments

This study was supported by the research project of Medical University of Lodz, grant 502-16-822.

References

1. Neufcoeur PE, Arafa M, Delvenne P, Saussez S. Involvement of human papillomavirus in upper aero-digestive tract cancers. *Bull Cancer*. 2009;96:941-950.
2. Slebos RJ, Yi Y, Ely K et al. Gene expression differences associated with human papillomavirus status in head and neck squamous cell carcinoma. *Clin Cancer Res*. 2006;12:701-709.
3. Brandwein M, Steinberg B, Thung S, Biller H, Dilorenzo T, Galli R. Human papillomavirus 6/11 and 16/18 in Schneiderian inverted papillomas. In situ hybridization with human papillomaviruses RNA probes. *Cancer*. 1989;63:1708-1713.
4. Kashima HK, Kessis T, Hruban RH, Wu TC, Zinreich SJ, Shah KV. Human papillomavirus in sinonasal papillomas and squamous cell carcinoma. *Laryngoscope*. 1992;102:973-976.
5. Major T, Szarka K, Sziklai I, Gergely L, Czegledy J. The characteristics of human papillomavirus DNA in head and neck cancer and papillomas. *J Clin Pathol* 2005;58:51-55.
6. Syrjänen KJ. HPV infection in benign and malignant sinonasal lesions. *J Clin Pathol*. 2003;56:174-181.
7. Wang D, Li Y, Sun K. Nasal inverted papilloma and human papilloma virus. *Lin Chuang Er Bi Yan Hou Ke Za Zhi*. 1998;12:118-119 (Abstract).
8. Zhou Y, Hu M, Li Z. Human papillomavirus (HPV) and DNA test in inverted papillomas of the nasal cavities and paranasal sinuses. *Zhonghua Er Bi Yan Hou Ke Za Zhi*. 1997;32:345-347 (Abstract).
9. Mork J, Lie AK, Glattre E et al. Human papillomavirus infection as a risk factor for squamous-cell carcinoma of the head and neck. *N Engl J Med*. 2001;344:1125-1131.
10. Shen J, Tate JE, Crum CP, Goodman ML. Prevalence of human papillomavirus (HPV) in benign and malignant tumors of the upper respiratory tract. *Mod Pathol*. 1996;9:15-20.
11. Bosch FX, Lorincz A, Muñoz N, Meijer CJ, Shah KV. The casual relation between human papillomavirus and cervical cancer. *J Clin Pathol*. 2002;55:244-265.
12. Scheffner M, Huibregtse JM, Vierstra RD, Howley PM. The HPV-16 E6 and E6-AP complex functions as an ubiquitin-protein ligase in the ubiquitination of p53. *Cell*. 1993;75:495-505.
13. Scheffner M, Werness BA, Huibregtse JM, Levine AJ, Howley PM. The E6 oncoprotein encoded by human papillomavirus types 16 and 18 promotes the degradation of p53. *Cell*. 1990;63:1129-1136.
14. Werness BA, Levine AJ, Howley PM. Association of human papillomavirus types 16 and 18 E6 proteins with p53. *Science*. 1990;248:76-79.
15. Chung CH, Gillison ML. Human papillomavirus in head and neck cancer: its role in pathogenesis and clinical implications. *Clin Cancer Res*. 2009;15:6758-6762.
16. Motoyama S, Ladines-llave CA, Villaneueva SL, Maruo T. The role of human papilloma virus in the molecular biology of cervical varcinogenesis. *Kobe J Med Sci*. 2004;50:9-19.
17. Nam EJ, Kim YT. Alteration of cell-cycle regulation in epithelial ovarian cancer. *Int J Gynecol Cancer*. 2008;18:1169-1182.
18. Nam EJ, Kim HY, Kim SW et al. Relationship between p16INK4a, pRb and high risk HPV infection and recurrence. *Korean J Obstet Gynecol*. 2006;49:1437-1445.
19. Chellappan SP, Hiebert S, Mudryj M, Horowitz JM, Nevins JR. The E2F transcription factor is a cellular target for the RB protein. *Cell*. 1991;65:1053-1061.
20. Dyson N, Howley PM, Munger K, Harlow E. The human papilloma virus-16 E7 oncoprotein is able to bind to the retinoblastoma gene product. *Science*. 1989;243:934-937.

21. Kamb A, Gruis NA, Weaver-Feldhaus J et al. A cell cycle regulator potentially involved in genesis of many tumor types. *Science*. 1994;264:436–440.
22. Sherr CJ. Cancer cell cycles. *Science*. 1996;274:1672–1677.
23. Nam EJ, Kim JW, Kim SW et al. The expressions of the Rb pathway in cervical intraepithelial neoplasia: predictive and prognostic significance. *Gynecol Oncol*. 2007;104:207–211.
24. Skomedal H, Kristensen GB, Lie AK, Holm R. Aberrant expression of the cell cycle associated proteins TP53, MDM-2, P21, P27, cdK4, cyclin D1, RB, and EGFR in cervical carcinomas. *Gynecol Oncol*. 1999;73:223–228.
25. Barnes L, Everson JW, Reichart P, Sidransky D. *World Health Organization Classification of Tumors. Pathology and Genetics Head and Neck Tumors*. Lyon: IARC Press 2005;26–32, 118–121.
26. Altavilla G, Staffieri A, Busatto G, Canesso A, Giacomelli L, Marioni G. Expression of p53, p16INK4A, pRb, p21WAF1/CIP1, p27KIP1, cyclin D1, Ki-67 and HPV DNA in sinonasal endophytic Schneiderian (inverted) papilloma. *Acta Otolaryngol*. 2009;129:1242–1249.
27. Katori H, Nozawat A, Tsukuda M. Relationship between p21 and p53 expression, human papilloma virus infection and malignant transformation in sinonasal-inverted papilloma. *Clin Oncol (R Coll Radiol)*. 2006;18:300–305.
28. Jin YT, Kayser S, Kemp BL et al. The prognostic significance of the biomarkers p21WAF1/CIP1, p53, and bcl-2 in laryngeal squamous cell carcinoma. *Cancer*. 1998;82:2159–2165.
29. Boyle JO, Hakim J, Koch W et al. The incidence of p53 mutations increases with progression of head and neck cancer. *Cancer Res*. 1993;53:4477–4480.
30. Olshan AF, Weissler MC, Pei H, Conway K. p53 mutations in head and neck cancer: new data and evaluation of mutational spectra. *Cancer Epidemiol Biomarkers Prev*. 1997;6:499–504.
31. Somers KD, Merrick MA, Lopez ME, Incognito LS, Schechter GL, Casey G. Frequent p53 mutations in head and neck cancer. *Cancer Res*. 1992;52:5997–6000.
32. Gale N, Zidar N, Kambic V, Poljak M, Cör A. Epidermal growth factor receptor, c-erbB-2 and p53 overexpressions in epithelial hyperplastic lesions of the larynx. *Acta Otolaryngol Suppl*. 1997;527:105–110.
33. Lavieille JP, Brambilla E, Riva-Lavieille C, Rey E, Charachon R, Brambilla C. Immunohistochemical detection of p53 protein in preneoplastic lesions and squamous cell carcinoma of the head and neck. *Acta Otolaryngol*. 1995;115:334–339.
34. Narayana A, Vaughan AT, Gunaratne S, Kathuria S, Walter SA, Reddy SP. Is p53 an independent prognostic factor in patients with laryngeal carcinoma? *Cancer*. 1998;82:286–291.
35. Jacob SE, Sreevidya S, Chacko E, Pillai MR. Cellular manifestations of human papillomavirus infection in laryngeal tissues. *J Surg Oncol*. 2002; 79: 142–150.
36. Malanchi I, Caldeira S, Krützfeldt M, Giarre M, Alunni-Fabroni M, Tommasino M. Identification of a novel activity of human papillomavirus type 16 E6 protein in deregulating the G1/S transition. *Oncogene*. 2002;21:5665–5672.
37. Malanchi I, Accardi R, Diehl F et al. Human papillomavirus type 16 E6 promotes retinoblastoma protein phosphorylation and cell cycle progression. *J Virol*. 2004; 78: 13769–13778.
38. Hafkamp HC, Mooren JJ, Claessen SM, et al. P21 Cip1/WAF1 expression is strongly associated with HPV-positive tonsillar carcinoma and a favorable prognosis. *Mod Pathol*. 2009; 22:686–698.
39. Pett MR, Alazawi WO, Roberts I et al. Acquisition of high-level chromosomal instability is associated with integration of human papillomavirus type 16 in cervical keratinocytes. *Cancer Res*. 2004;64:1359–1368.
40. Plug-DeMaggio AW, Sundsvold T, Wurscher MA, Koop JJ, Klingelutz AJ, McDougall JK. Telomere erosion and chromosomal instability in cells expressing the HPV oncogene 16E6. *Oncogene*. 2004;23:3561–3571.
41. König F, Krekeler G, Hönig JF, Cordon-Cardo C, Fischer G, Korabiowska M. Relation between human papillomavirus positivity and p16 expression in head and neck carcinomas: a tissue microarray study. *Anticancer Res*. 2007;27:283–288.
42. Laco J, Slaninka I, Jirásek M, Celakovský P, Vosmiková H, Ryska A. High-risk human papillomavirus infection and p16INK4a protein expression in laryngeal lesions. *Pathol Res Pract*. 2008;204:545–552.
43. Marsit CJ, Black CC, Posner MR, Kelsey KT. A genotype-phenotype examination of cyclin D1 on risk and outcome of squamous cell carcinoma of the head and neck. *Clin Cancer Res*. 2008;14:2371–2377.

Submitted: 29 January, 2010

Accepted after reviews: 30 January, 2011