

Assessment of S100 protein expression in the epididymis of juvenile and adult European bison

Elżbieta Czykier¹, Maciej Zabel^{2,3}, Joanna Surdyk-Zasada², Agnieszka Lebel⁴, Beata Klim⁴

¹Department of Histology and Embryology, Medical University of Białystok, Białystok

²Department of Histology and Embryology, Medical University, Poznań

³Department of Histology and Embryology, Medical Academy, Wrocław

⁴Department of Human Anatomy, Medical University of Białystok, Białystok

Abstract: In our study, we decided to compare S100 protein expression in the material obtained from the epididymes of 5- and 12-month-old calves, and adult European bison, and to detect any differences in S100 expression according to the animal age and size of the organ examined. We used the epididymes obtained from 6 adult European bison aged 6-12 years, from 6 at the age of 12 months and 6 calves aged 5 months. Immunocytochemical reactions were performed using the avidin-biotinylated-peroxidase (ABC) technique according to HSU. Specific polyclonal rabbit antiserum against bovine S100 protein (Bio Genex Laboratories) at a dilution at 1:400 was applied. We found the expression of S100 protein in endothelial cells of arteries, veins and lymphatic vessels in all the study animals. At the same time, we found no differences in the expression of S100 protein in vascular endothelial cells. Our observations seem to indicate that S100 expression in endothelial cells of European bison epididymis is not correlated with age or maturity of the organ tested. We found S100 protein in smooth muscle cells of arteries and veins in all European bison specimens examined. Interestingly in the current study, in young 5-month-old sexually immature European bison specimens we observed weaker expression of S100 protein in smooth muscle cells of small vessels as compared to the same cell type both in large vessels in these animals and in small vessels in adult specimens.

Key words: S100 protein expression, epididymis, European bison

Introduction

The S100 protein family covers the largest group of "calcium-binding proteins" in living organisms. The S100 is an acidic calcium binding protein. Structurally, S100 is a dimer with a subunit composition of aa, ab and bb, and with solubility in a saturated solution of ammonium sulfate. Members of this group are characterized by high molecular weight and the presence of two calcium binding sites of the EF-hand type (helix-loop-helix calcium-binding domains). According to Hsieh [1], "most S100 proteins are small acidic proteins with calcium binding domains – the EF hands. It is thought that this group of proteins carry out their cellular functions by interacting with specific target proteins, an interaction that is mainly dependent on

exposure of hydrophobic patches, which result from calcium binding".

Most of the S100 protein genes are located in gene cluster on human chromosome 1q21, which is structurally conserved in evolution [2]. The respective members of the S100 family show varied degree of interspecies gene homology, which suggests that the divergence between these two genes occurred earlier in evolution. For instance, the homology between human and mouse S100 cDNAs is in the range of 85-95%.

S100 proteins can be found in physiological conditions in such cells and organs as nerve fibers, amnion, trophoblast, decidual cells of fetal membranes, in Sertoli cells, Leydig cells, peritubular cells of the seminiferous tubules, epithelial cells of the transitional segment of the seminiferous tubules, thyroid gland parathyroid gland, hair cuticle cells, myeloid cells, lung, kidney, liver, cardiac and skeletal muscle [2-14]. The hybridization method in situ has detected the expression of S100 mRNA in skeletal muscle, heart, kidney, pancreas, ovary, spleen and small intestine [13].

Correspondence: E. Czykier, Dept. of Histology and Embryology, Medical University of Białystok, Kilińskiego Str. 1, 15-230 Białystok, Poland; tel./fax.: (+4885) 7485455, e-mail: czykier@umwb.edu.pl

S100 protein expression has been also observed in a number of pathological conditions in humans: rheumatoid arthritis, acute inflammatory lesions, cystic fibrosis, acute myocardial ischemia, Leydig cell tumors of the testis, melanoma and breast cancer [7,15-18].

The involvement of S100A8 and S100A9 has also been found in the initiation and development of inflammatory processes, e.g. in secretory epithelium in inflamed tissue [19, 20]. As stated by Robinson [20] "in inflamed tissues, the S100A8 and S100A9 complex is deposited into the endothelium of venules associated with extravasating leukocytes". On the other hand, Eue [19] has demonstrated in progressing inflammatory processes that "S100A8, S100A9 and S100A8/9 heterodimeric complex bind to human dermal microvascular endothelial cell line [HMEC]-1 with an increasing binding capacity progressing from S100A8 S100A9 S100A8/A9".

Our earlier research showed the expression of S100 protein in the endothelial cells of arteries, veins, capillaries and lymphatic sinusoids of the testis and epididymis of adult European bison and in smooth muscle cells of arteries and veins in both testis and epididymis [21]. Therefore, we decided to compare S100 protein expression in the material obtained from the epididymes of 5- and 12-month-old calves, and adult European bison, and to detect any differences in S100 expression according to the animal age and size of the organ examined. We used the material from such young calves, since animals at this age are not sexually mature. Active spermiogenesis in European bison begins at the age of 4 years, sporadically at the age of 3 years [22,23].

Materials and methods

Tissue collection. We used the epididymes obtained from 6 adult European bison aged 6-12 years, from 6 at the age of 12 months and 6 calves aged 5 months. The animals (living in the Białowieża Forest reserve and in a free-ranging herd in the Białowieża Forest) were shot in the autumn-winter season to reduce the herd. The fragments of the epididymes were collected, fixed in Bouin's solution for 24 h and embedded in paraffin. Five- μ m sections were stained with hematoxylin and eosin (H+E).

Immunocytochemical procedures. Immunocytochemical reactions were performed using the avidin-biotinylated-peroxidase (ABC) technique according to HSU [24]. Specific polyclonal rabbit antiserum against bovine S100 protein (Bio Genex Laboratories) at a dilution of 1:400 was applied. In brief, the following steps were carried out:

- inhibition of endogenous peroxidase activity with 1% H₂O₂ in distilled water for 30 min,
- blocking of non-specific binding of antibodies by incubation with normal goat serum (DAKO X 0907) in PBS, diluted 1:20,
- incubation with antiserum against bovine S100 protein, diluted 1:400 for 24 hours at 4°C, then for 60 min at room temperature,
- incubation with biotinylated anti-rabbit IgG (DAKO LSAB 2 Kit),
- incubation with ABC complex (DAKO LSAB 2 Kit),

- peroxidase detection using DAB,
- wash in tap water for 10 min, dehydration.

Between the successive steps, sections were washed in PBS (3 \times 3 min). The slides were mounted in a balsam (Permount). In negative controls, we omitted the primary antibody and used normal rabbit antiserum, the remaining stages being unchanged.

Results

Adult European bison

We found S100 protein expression in vascular endothelial cells and smooth muscle cells in the epididymes of adult European bison specimens (Fig. 1). The expression was very strong in endothelial cells of medium-size vessels (Fig. 1). In most endothelial cells, the reaction was very strong and evenly distributed within the cytoplasm, being slightly weaker in some.

In smooth muscle cells of medium-size vessels, the reaction for S100 was slightly weaker than in endothelial cells of these vessels (Fig. 1). The reaction intensity varied among these cells, being stronger or weaker, but it was always evenly distributed in the cytoplasm.

Staining intensity in endothelial cells of small vessels varied, but the reaction was regularly distributed in the cytoplasm. In some cells it was comparable to the intensity observed in medium-size vessels, in others it was markedly weaker. Strong staining for S100, but evenly distributed, was found in smooth muscle cells of the small vessels of the epididymis (Fig. 2) as compared to the same type of cells in the medium-size vessels.

Positive S100 expression was also noted in endothelial cells of the lymphatic vessels. The reaction was strong and evenly distributed within the cytoplasm, its intensity being comparable to the staining noted in endothelial cells of medium-size arteries and veins. We found a positive reaction for S100 protein in cells of the stromal connective tissue (Fig. 1).

One-year-old calves

In one-year-old calves, staining of endothelial cells for S100 protein in medium-size vessels was varied (Fig. 2). In some cells, the reaction was very strong, in others it was weak, and the reaction product was regularly distributed within the cytoplasm. The reaction for S100 protein in smooth muscle cells of the medium size vessels varied in intensity and was evenly distributed within the cytoplasm (Fig. 2). In some cells, the reaction was strong, in others slightly weaker, but in both cases it was comparable to the intensity observed in smooth muscle cells of the same-size vessels in adult bison (Figs. 1, 2).

In endothelial cells of small vessels, the intensity of reaction for S100 protein was comparable to that

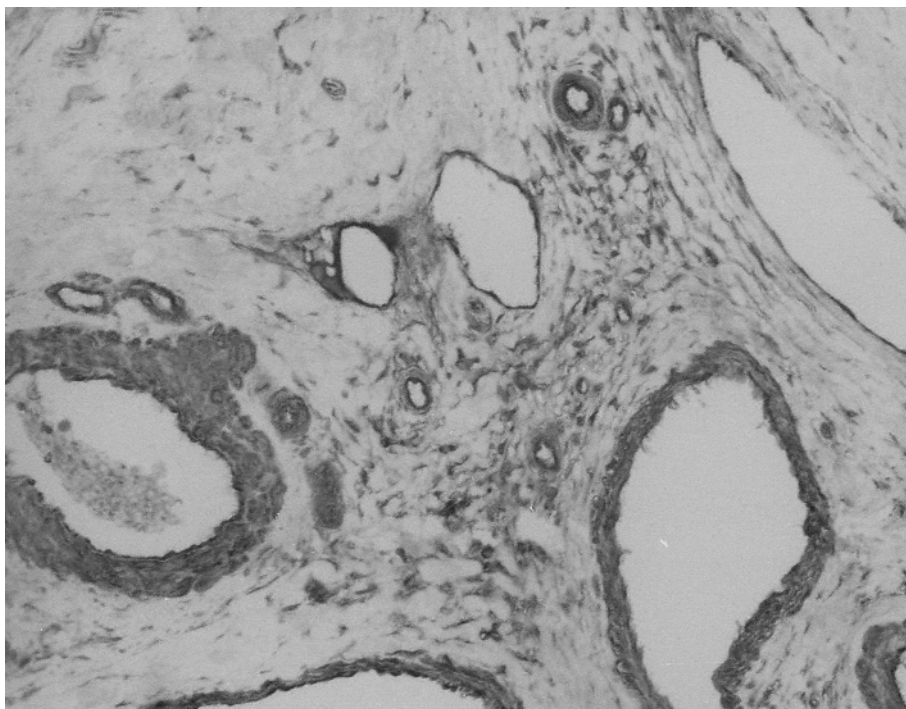


Fig. 1. Epididymis of adult bison. Medium-size artery, vein and lymphatic vessels. In endothelial cells of the artery, the reaction for S100 protein varies from very strong to strong. Endothelial cells of vein and lymphatic vessels exhibit variable immunostaining from very strong to weak, as compared to endothelial cells of the medium-size artery. The strong reaction for S100 protein in vascular smooth muscle cells of medium artery and vein. Endothelium of small arteries and veins exhibits very strong reaction for S100 protein as compared to endothelial cells of the medium-size vessels. Strong reaction for S100 protein in smooth muscle cells of the small artery and vein. A positive reaction for S100 protein in the cells of the stromal connective tissue (original magnification $\times 200$).

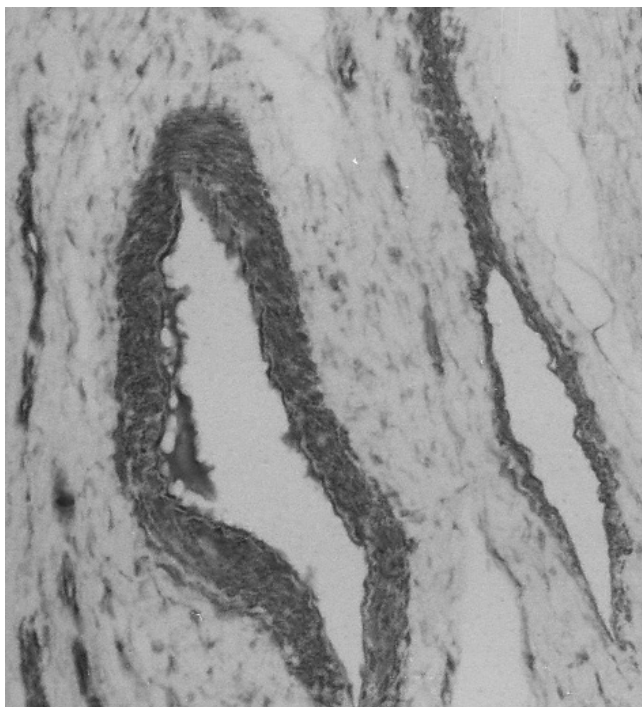


Fig. 2. Epididymis of 12-month-old calf. Medium-size artery and vein. Very strong and strong reactions for S100 protein in endothelial cells of the artery. Strong expression for S100 protein in smooth muscle cells of medium artery. Longitudinal section of medium-size vein shows varied intensity of reaction for S100 protein in endothelial cells, from very strong to weak. In small vessels, there is a strong reaction for S100 protein in endothelial cells, whereas strong or weaker in smooth muscle cells. A positive reaction for S100 protein in the cells of the stromal connective tissue (original magnification $\times 200$).

observed in endothelial cells of medium-size vessels in these animals. The reaction was evenly distributed within the cytoplasm. In smooth muscle cells of small vessels the reaction for S100 protein was weaker (Fig. 2) than in smooth muscle cells of medium-size arteries and veins, and was regularly distributed in the cytoplasm.

We observed high S100 protein expression in endothelial cells of lymphatic vessels, comparable in intensity to that noted in endothelial cells of medium-size vessels. The reaction showed regular distribution in the cytoplasm (Fig. 3). We found a positive reaction for S100 protein in the cells of the stromal connective tissue (Figs. 2, 3).

5-month-old calves

We found diverse intensity of reaction for S100 protein in endothelial cells of medium-size vessels in the epididymis of 5-month-old calves (Fig. 4). In some cells, the reaction was very strong, in others weak, but showed even distribution in the cytoplasm. The reaction was weaker in smooth muscle cells of these vessels as compared to one-year-old and adult bull specimens (Figs. 1, 2, 4), and was regularly distributed within the cytoplasm. In small vessels of the epididymis, endothelial cells showed weak reaction for S100 protein, being evenly distributed within the cytoplasm (Fig. 4). Staining of smooth muscle cells for S100 protein in small vessels was trace (Fig. 4). We found a positive reaction for S100 protein in cells of the stromal connective tissue (Fig. 4).

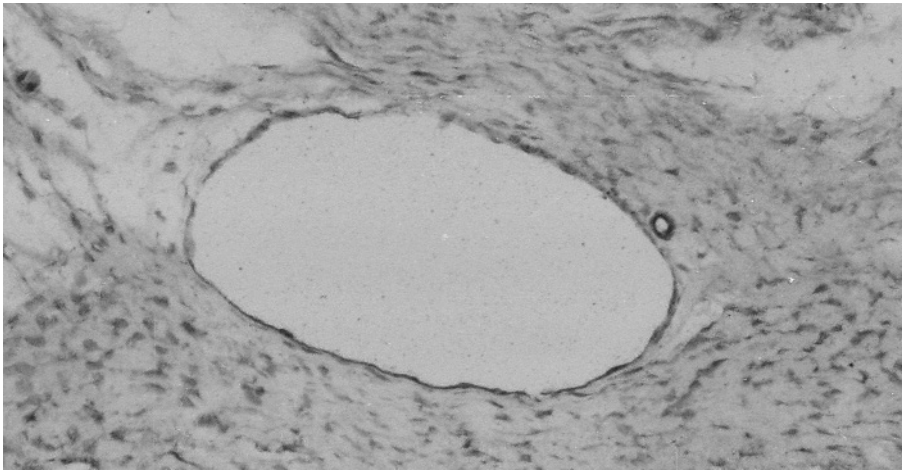


Fig. 3. Epididymis of 12-month-old calf. Medium-size lymphatic vessels. Endothelial cells of lymphatic vessel show diverse intensity of reaction for S100 protein from very strong to weak or very weak. Very strong S100 protein expression is noted in endothelial cells of small vessels, slightly weaker in smooth muscle cells of small vessels. A positive reaction for S100 protein in the cells of the stromal connective tissue (original magnification $\times 200$).

Discussion

We found the expression of S100 protein in endothelial cells of arteries, veins and lymphatic vessels in all the study animals. Our findings concerning the expression of S100 protein in lymphatic endothelial cells correspond to localization described in the testis in humans, rats, pine vole, European bison, pigs and ruminants [21,25-27]. Our results referring to localization of S100 protein in endothelial cells of veins and lymphatic vessels of the epididymis are consistent with those reported in boars and ruminants, as well as in the testis of water buffalo [5,25]. A positive reaction to S100 protein in arterial endothelia was described in pig ovary, whereas in the endothelial cells of arteries and veins in pig and cattle [28,29]. Other authors found the expression of S100 protein in human umbilical vein-derived endothelial cell line [1,30]. Still others, in the electron microscopic picture, observed a positive reaction for S100 protein in continuous type capillary endothelia in rat testis, while negative in fenestrated type endothelium [31]. Moreover, Carpentier [32] observed an increased amount of S100 protein positive vesicles in endothelial cells of adjacent capillaries during lipolysis. Since one of the major roles of endothelial cells is to transport bioactive substances from blood into the perivascular space, Iwanaga [28] suggested that S100 protein in the continuous type capillary endothelium may be involved in the transport of fatty acids and/or other substances. Moreover, a study by Hsieh [30] showed that S100 protein undergoes "translocation in response to extracellular S100 protein in human endothelial cells". According to this author, "different S100 proteins utilize distinct translocation pathways in endothelial cells, which might lead them to certain subcellular compartments in order to perform their physiological tasks in the same cellular environment".

In our opinion, S100 protein plays a similar role in endothelial cells of arteries, veins and lymphatic vessels

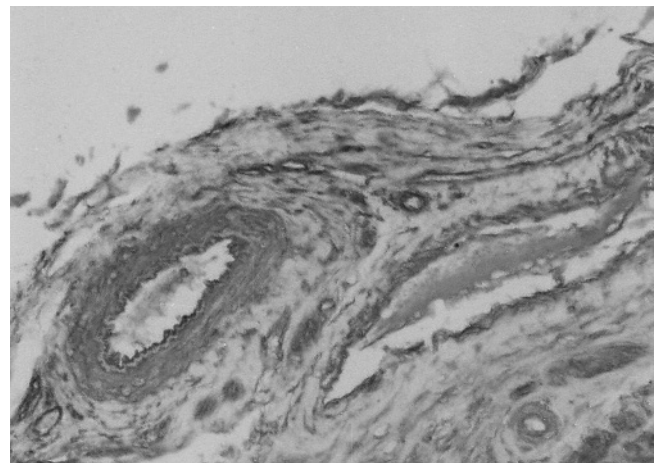


Fig. 4. Epididymis of 5-month-old calf. Medium-size artery and vein. Very strong S100 protein expression in endothelial cells of the artery. Weak reaction for S100 protein in smooth muscle cells of medium artery. Endothelial cells and smooth muscle cells of vein exhibit variable immunostaining – from strong to weak. Small artery endothelium shows a strong reaction for S100 protein. In smooth muscle cells of small vessels, staining for S100 protein is weak. A positive reaction for S100 protein in the cells of the stromal connective tissue (original magnification $\times 200$).

in European bison epididymis. At the same time, we found no differences in the expression of S100 protein in vascular endothelial cells in all study animals. Our observations seem to indicate that S100 expression in endothelial cells of European bison epididymis is not correlated with age or maturity of the organ tested.

We found S100 protein in smooth muscle cells of arteries and veins in all European bison specimens examined. Our current results concerning the expression of S100 protein in smooth muscle cells of arteries and veins in the epididymis are consistent with the findings reported by Daub [33], who found the expression of S100A4 and S100A6 in the smooth muscle of the aorta and in cultured smooth muscle cells. Similar results were obtained by other authors, who found pos-

itive reaction for S100 protein in rat vascular smooth muscle cells [34,35], human and guinea pig smooth muscle cells from the aorta [33,36,37] and porcine isolated coronary artery smooth muscle cells [36,38-41].

According to Daub [13], S100 protein "could be potentially involved in the regulation of cytoplasmic Ca^{2+} -concentration and/or in signal transduction in smooth muscle cells". Chang [39] forwards the hypothesis that the "increase in cytosolic free $[Ca^{2+}]$ leads to formation of the complex of S100A11 and annexin A6, which forms a physical connection between the plasma membrane and the cytoskeleton, or plays a role in the formation of signaling complexes at the level of the sarcolemma". On the other hand, Brisset [36] claims that S100A4 is "a marker of porcine rhomboid smooth muscle cells and it is also a marker of a large population of human atherosclerosis and restenotic smooth muscle cells". We think that S100 protein in vascular smooth muscle cells in the epididymis of European bison plays a similar role.

Interestingly in the current study, in young 5-month-old sexually immature European bison specimens we observed weaker expression of S100 protein in smooth muscle cells of small vessels as compared to the same cell type both in large vessels in these animals and in small vessels in adult specimens. The cause of weaker expression of S100 protein in vascular smooth muscle cells in sexually immature epididymis of young 5-month-old European bison is difficult to explain.

References

- [1] Hsieh H-L, Schäfer BW, Cox JA, Heizmann CW. S100A13 and S100A6 exhibit distinct translocation pathways in endothelial cells. *J Cell Sci.* 2002;115:3149-3158.
- [2] Ridinger K, Schafer BW, Durussels I, Cox JA, Heizmann CW. S100 A13. Biochemical characterization and subcellular localization in different cell lines. *J Biol Chem.* 2000;275: 8686-8694.
- [3] Arcuri C, Giambanco I, Bianchi R, Donato R. Subcellular localization of S100A11 (S100C, calgizzarin) in developing and adult avian skeletal muscles. *Biochim Biophys Acta.* 2002;1600:84-89.
- [4] Boni R, Burg G, Doguoglu A, Ilg EC, Schafer BW, Muller, Heizmann CW. Immunohistochemical localization of the Ca^{2+} binding S100 proteins in normal human skin and melanocytic lesions. *Br J Dermatol.* 1997;137:39-43.
- [5] Cruzana BC, Hondo E, Kitamura N, Matsuzuki S, Nakagawa M, Yamada J. Differential localization of immunoreactive alpha-and beta-subunits of S-100 protein in feline testis. *Anat Histol Embryol: Veterinary Medicine Series.* 2000;29:83-86.
- [6] Glenney JR Jr, Kindy MS, Zokas L. Isolation of a new member of the S100 protein family: amino acid sequence, tissue, and subcellular distribution. *J Cell Biol.* 1989;108:569-578.
- [7] Ilg EC, Schafer BW, Heizmann CW. Expression pattern of S100 calcium binding proteins in human tumors. *Int J Cancer.* 1996;68:325-332.
- [8] Kizawa K, Uchiwa H, Murakami U. Highly-expressed S100A3, a calcium-binding protein, in human hair cuticle. *Biochim Biophys Acta.* 1996;1312:94-98.
- [9] Marinoni E, Di Iorio R, Gazzolo D, Lucchini C, Michetti F, Corvino V, Cosmi EV. Ontogenic localization and distribution of S-100 beta protein in human placental tissues. *Obster Gynecol.* 2002;99:1093-1099.
- [10] Paulsen F, Hallmann U, Paulsen J, Thahr A. Innervation of the cavernous body of the human efferent tear ducts and function in tear outflow mechanism. *J Anat.* 2000;197:177-187.
- [11] Tanaka Y, Carney J A, Ijiri R, Kato K, Miyake T, Nakatami Y, Misugi K. Utility of immunostaining for s-100 protein subunit in gonadal sex cord-stromal tumors, with emphasis on the large-cell calcifying Sertoli cell tumor of the testis. *Hum Pathol.* 2002;33:285-289.
- [12] Vogl T, Propper C, Hartmann M, Strey A, Strupat K, van den Bos C, Sorg C, Roth J. S100A12 is expressed exclusively by granulocytes and acts independently from MRP8 and MRP14. *J Biol Chem.* 1999;274:2591-2596.
- [13] Wicki R, Schafer BW, Erne P, Heizmann CW. Characterization of the human and mouse cDNAs coding for S100A13, a new member of the S100 protein family. *Biochem Biophys Res Commun.* 1996;227:594-599.
- [14] Zabel M, Surdyk J, Biela-Jacek I. Immunocytochemical study of the distribution of S-100 protein in the parathyroid gland of rats and guinea pigs. *Histochemistry.* 1986;86:97-99.
- [15] Donato R. S100: a multigenic family of calcium-modulated protein of the EF-hand type with intracellular and extracellular functional roles. *Int J Biochem Cell Biol.* 2001;33:637-668.
- [16] Heizman CW, Fritz G, Schäfer BW. S100 proteins: structure, functions and pathology. *Frontiers Biosci.* 2002;7:D1356-D1368.
- [17] Ulbright TM, SRigley JR, Hatzianastassiou DK, Young RH. Leydig cells tumors of the testis with unusual features: adipose differentiation, calcification with ossification, and spindle-shaped tumor cells. *Am J Surg Pathol.* 2002;26:1424-1433.
- [18] Wetermann MA, Stoopen GM, van Muijen GN, Kuznicki J, Ruiter DJ, Bloemers HP. Expression of calyculin in human melanoma cell lines correlates with metastatic behavior in nude mice. *Cancer Res.* 1992;52:1291-1296.
- [19] Eue I, König S, Pior J, Sorg C. S100A8, S100A9 and the S100A8/A9 heterodimer complex specifically bind to human endothelial cells: identification and characterization of ligands for the myeloid-related proteins S100A9 and S100A8/A9 on human dermal microvascular endothelial cell line-1 cells. *Int Immunol.* 2002;14:287-297.
- [20] Robinson MJ, Tessier P, Poulson R, Hogg N. The S100 family heterodimer, MRP-8/14, binds with high affinity to heparin and heparin sulfate glycosaminoglycans on endothelial cells. *J Biol Chem.* 2002;277:3658-3665.
- [21] Czykier E, Sawicki B, Zabel M. Immunocytochemical localization of S-100 protein in the European bison testis and epididymis. *Folia Histochem Cytobiol.* 1999;37:83-84.
- [22] Czykier E, Sawicki B, Krasieńska M. Postnatal development of the European bison spermatogenesis. *Acta Theriol.* 1999; 44:77-90.
- [23] Czykier E, Krasieńska M. Cases of spermiogenesis in young European bison. *Acta Theriol.* 2004;49:543-554.
- [24] Hsu Su-Ming, Raine L, Fanger H. Use of avidin-biotin-peroxidase complex (ABC) in immunoperoxidase techniques: a comparison between ABC and unlabeled antibody (PAP) procedures. *J Histochem Cytochem.* 1981;29:577-580.
- [25] Amselgruber WM, Sinowatz F, Erhard M. Differential distribution of immunoreactive S-100 protein in mammalian testis. *Histochemistry.* 1994;102:241-245.
- [26] Czykier E, Sawicki B, Zabel M. S-100 protein immunoreactivity in mammalian testis and epididymis. *Folia Histochem Cytobiol.* 2000;38:163-166.
- [27] Michetti F, Lauriola L, Rende M, Stolfi VM, Battaglia F, Cocchia D. S-100 protein in the testis. An immunohistochemical and

- immunohistochemical study. *Cell Tissue Res.* 1985;240:37-142.
- [28] Iwanaga T, Fujita T, Takahashi Y, Isobe T. Immunohistochemical demonstration of S-100 protein in the endothelial cells of blood vessels in the pig and cattle. *Biomed Res.* 1987;8:329-334.
- [29] Mirecka J, Brinck U, Korabiowska M, Schauer A. Localization of S-100 protein in pig ovarian structures. *Folia Histochem Cytochem.* 1994;32:177-180.
- [30] Hsieh H-L, Schäfer BW, Weigle B, Heizmann CW. S100 protein translocation in response to extracellular S100 is mediated by receptor for advanced glycation endproducts in human endothelial cells. *Biochem Biophys Res Commun.* 2004;316:949-959.
- [31] Holash JA, Harik SI, Perry G, Stewart PA. Barrier properties of testis microvessels. *Cell Biol.* 1993;90:11069-11073.
- [32] Carpentier JL, Perrelet A, Orci L. Morphological changes of the adipose cell plasma membrane during lipolysis. *J Cell Biol.* 1977;72:104-117.
- [33] Daub B, Schroeder M, Pfitzer G, Ganitkevich V. Expression of members of the S100 Ca²⁺-binding protein family in guinea-pig smooth muscle. *Cell Calcium.* 2003;33:1-10.
- [34] Lefranc F, Decaestecker C, Brotchi J, Heizmann CW, Dewitte O, Kiss R, Mijatovic T. Co-expression/co-location of S100 proteins (S100B, S100A1 and S100A2) and protein kinase C (PKC- α , - η and - ξ) in rat model of cerebral basilar artery vasospasm. *Neuropath Appl Neurobiol.* 2005;31:649-660.
- [35] Shaw SS, Schmidt AM, Banes AK, Wang X, Stern DM, Marrero MB. S100B-RAGE-mediated augmnetin of angiotensin II-induced activation of JAK2 in vascular smooth muscle cells is dependent on PLD2. *Diabetes.* 2003;52:2381-2388.
- [36] Brisset AC, Hao H, Camenzid E, Bacchetta M, Geinoz A, Sanchez JCh, Chaponnier CH, Gabbiani G, Bochaton-piallat ML. Intimal smooth muscle cells of porcine and human coronary artery express S100Ar, a marker of the rhomboid phenotype in vitro. *Circ Res [serial online]* 2007;100:1055-1062. Available at: <http://circres.ahajournals.org> DOI: 10.1161/01.RES.0000262654.84810.6c
- [37] Inaba H, Hokamura K, Nakano K, Nomura R, Katayama K, Nakajima A, Yoshioka H, Taniguchi K, Kamisaki Y, Takashi O, Umemura K, Murad F, Wada K, Amano A. Upregulation of S100 calcium-binding protein A9 is required for induction of smooth muscle cell proliferation by a periodontal pathogen *FEBS Lett.* 2009;583:128-134.
- [38] Chadjichritos CE, Morel S, Derouette JP, Sutter E, Roth I, Brisset AC, Bochaton-Piallat ML, Kwak BR. Targeting connexin 43 prevents platelet-derived growth factor-BB-induced phenotypic change in porcine coronary artery smooth muscle cells. *Circ Res.* 2008;102:653-660.
- [39] Chang N, Sutherland C, Hesse E, Winkfein R, Wichler WB, Pho M, Veillette C, Li S, Wilson DP, Kiss E, Walsh MP. Identification of a novel interaction between the Ca²⁺-binding protein S100A11 and the Ca²⁺- and phospholipid-binding protein annexin A6. *Am J Physiol Cell Physiol.* 2007;292:C1417-C1430.
- [40] Prunotto M, Bacchetta M, Jayaraman S, Galloni M, Van Eys G, Gabbiani G, Bochaton-Piallat ML. Cytostatic drugs differentially affect phenotypic features of porcine coronary artery smooth muscle cell populations. *FEBS Lett.* 2007;581:5847-5851.
- [41] Reddy MA, Li SI, Sahar S, Kim Y-S, Xu Z-G, Lanting L. Key role of Src kinase in S100B-induced activation of the receptor for advanced glycation end products in vascular smooth muscle cells. *J Biol Chem.* 2006;281:13685-13693.

Submitted: 4 August, 2010

Accepted after reviews: 24 April, 2010