

‘A blessing in disguise’: the severe course of perioperative takotsubo syndrome associated with favourable long-term outcome

„Złe dobrego początku” – ciężki przebieg okołoperacyjnego zespołu takotsubo powiązany z dobrymi wynikami odległymi

Konrad Stępień, Karol Nowak, Paweł Rostoff, Barbara Szłószarczyk,
Adam Stępień, Jadwiga Nessler, Jarosław Zalewski

Department of Coronary Artery Disease and Heart Failure, Jagiellonian University Medical College, Krakow, Poland

Abstract

In the current article, the case report of perioperative takotsubo syndrome in a 59-year-old woman with hypertension, paroxysmal atrial fibrillation and toxic nodular goitre was presented. During the induction of general anaesthesia before scheduled thyroidectomy, the cardiac arrest in the mechanism of asystole was diagnosed. As a result of cardiopulmonary resuscitation, the spontaneous circulation returned. The cardiogenic shock requiring catecholamines administration was noted. In the urgent coronarography, the marked slow flow phenomenon was observed in coronary arteries. The bedside echocardiogram revealed left ventricular ejection fraction (LVEF) deterioration to 20% with the akinesia of apical segments. The diagnosis of takotsubo syndrome was made. In the control examinations, the rapid clinical improvement with the increase of LVEF to 40% on the second day of hospitalization was observed. Due to the good general condition, the patient was discharged on the tenth day of hospitalization. Currently, the patient remains in cardiological out-patient care without any signs of takotsubo syndrome relapse. After 3.5 years of observation, the LVEF equalled 60% without significant disturbances in regional contractility.

Key words: takotsubo syndrome, thyroidectomy, cardiac arrest, cardiogenic shock

Folia Cardiologica 2020; 15, 6: 419–422

Introduction

The takotsubo syndrome (TTS) is a rare medical condition that closely mimics acute myocardial infarction. According to the available registries, it consists of 1–3% of ST-elevation myocardial infarctions [1]. Despite numerous studies conducted in recent years, the pathophysiology and aetiology of this entity remain incompletely elucidated. In the literature, the TTS is traditionally associated with severe emotional and physical stress [1, 2]. However, the lack of

identifiable preceding stressful event is stated in about one-third of TTS patients [1].

Case report

A 59-years-old obese woman with the history of paroxysmal atrial fibrillation, hypertension and nodular goitre was admitted to the hospital after cardiac arrest in the mechanism of asystole with subsequent return of spontaneous circulation (after administration of 1.5 mg of adrenaline)

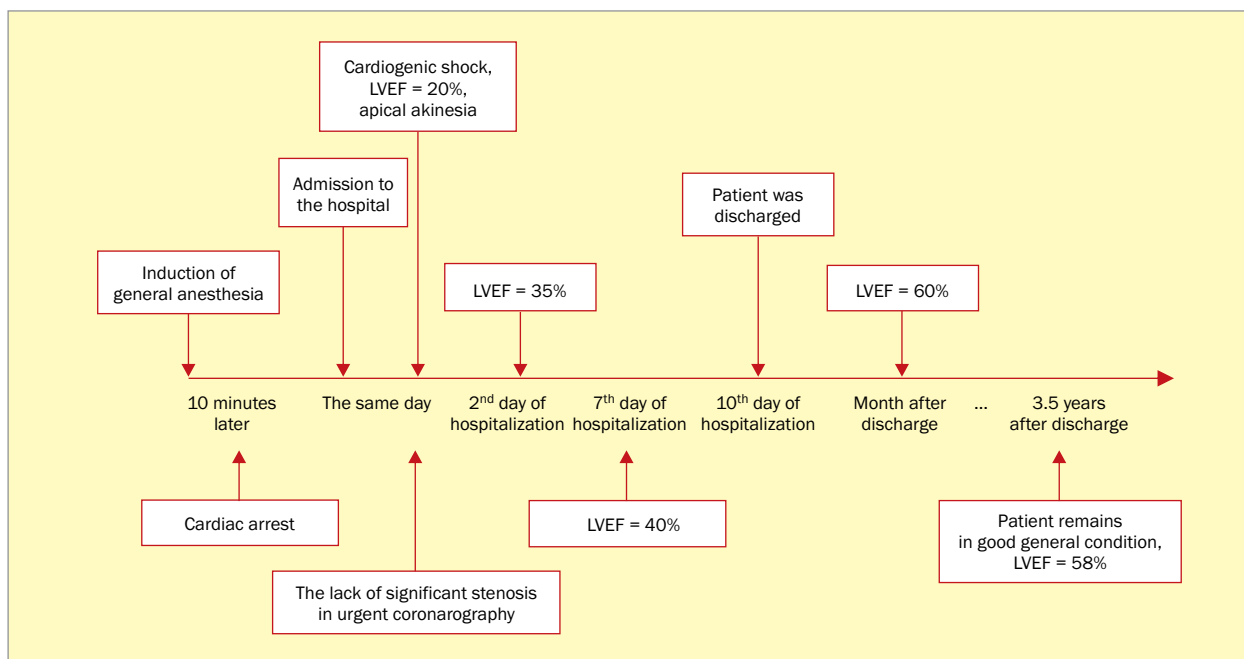


Figure 1. The timeline of subsequent diagnostic and therapeutic stages; LVEF – left ventricular ejection fraction

that occurred ten minutes after induction of general anesthesia before total thyroidectomy (Figure 1).

On admission, she had symptoms of cardiogenic shock requiring catecholamine infusions. In electrocardiogram (ECG) recorded immediately after cardiac arrest transient ST-segment elevations in inferior leads have been documented. The urgent angiography revealed almost normal epicardial segments of coronary arteries with the slow flow in the left anterior descending artery and first marginal branch (Supplementary File 1, see on the journal website). In the transthoracic echocardiography (TTE) the typical presentation of TTS has been shown with the ballooning of apical segments of the left ventricle and reduced left ventricular ejection fraction (LVEF) to 20% (Supplementary File 2A, see on the journal website).

The patient was transferred to the intensive care unit where intracranial haemorrhage and cerebral ischemia were excluded with computed tomography and magnetic resonance imaging. Blood tests were negative for thyrotoxicosis and myocarditis with elevated high sensitivity troponin T but normal level of isoenzyme myocardial bound (MB) of creatine kinase. On the second day, she was successfully extubated. TTE performed after extubation has shown a substantial improvement of global (LVEF up to 35%) and segmental contractility (Figure 1, Supplementary File 2B, see on the journal website). On the tenth day, the patient was discharged in a good general condition. Her prescribed treatment included dabigatran, perindopril, metoprolol and eplerenone.

One month later, during an outpatient visit, further improvement of LVEF up to 60% with the remaining slightly hypokinetic apex has been found. Within over 3.5-year follow-up the patient regularly visited in outpatient clinic remained in good general condition without recurrence of TTS and with well-preserved left ventricular contractility (Supplementary Files 2C and 3, see on the journal website). Currently, the patient, permanently disqualified from surgical thyroidectomy, is prepared to the third attempt of radioiodine therapy and subsequent catheter ablation for atrial fibrillation.

Discussion

Up to now more than one hundred cases of perioperative TTS have been described, however, most of them were diagnosed postoperatively and proceeded mildly [3]. Stiermaier et al. [4] described higher 28-day, 1-year and long-term mortality after 3.6 years than in TTS survivors without cardiogenic shock, respectively. Additionally, in the latest publication based on the InterTAK Registry Gili et al. reported that 8.1% of included TTS patients received cardiopulmonary resuscitation which was associated with higher 60-day and 5-year overall mortality [5].

Due to the lack of significant lesions, the working diagnosis of myocardial infarction with nonobstructive coronary arteries (MINOCA) was initially made following current guidelines [6, 7]. However, based on subsequent characteristic echocardiography image the diagnosis was verified

in the light of the latest TTS semantic controversies [8]. Another observation with proven prognostic significance was the slow-flow phenomenon in the left coronary system suggesting impaired myocardial perfusion. In the latest paper, Montone et al. [9] reported a higher prevalence of in-hospital complications, including cardiogenic shock, and a higher rate of major adverse cardiovascular events and overall mortality mainly due to non-cardiac causes during long-term follow-up in TTS patients with coronary slow flow. This observation complies with previous research regarding the poorer long-term prognosis of myocardial infarction patients with slow-flow phenomenon [10]. In myocardial infarction, the impaired coronary circulation is often derived by distal embolization or ischemic injury [10]. In turn, the frequently observed slow-flow phenomenon in TTS patients is probably related to severe catecholamines ejection and microvascular circulation constriction that provide a characteristic image of ballooning apex [1, 2].

Conclusions

In the presented high-risk TTS patient, the meticulous step-by-step risk stratification which indicated a poor prognosis has not been confirmed in the long-term follow-up. A brisk reaction of an anaesthesiologist who cautiously assessed the circumstances of cardiac arrest and transferred the patient to the cath lab together with subsequent comprehensive differential diagnosis allowed to save the health and life of the patient.

Acknowledgements

None.

Conflict of interest

The authors declared no conflict of interest.

Streszczenie

W niniejszym artykule przedstawiono opis okołooperacyjnego zespołu takotsubo u 59-letniej kobiety z nadciśnieniem tętniczym, napadowym migotaniem przedsionków i nadczynnym wolem guzkowym tarczycy. W trakcie indukcji znieczulenia ogólnego przed planowym zabiegiem tyroidektomii doszło do nagłego zatrzymania krążenia w mechanizmie asystolii. W wyniku podjętej resuscytacji przywrócono pracę serca. Stwierdzono wstrząs kardiogeny wymagający podaży amin presyjnych. W wykonanej w trybie pilnym koronarografii zaobserwowano cechy zwolnionego przepływu środka kontrastowego w tętnicach wieńcowych przy braku istotnych hemodynamicznie zwężeń. W przyłóżkowym badaniu echokardiograficznym uwidoczono obniżoną do 20% frakcję wyrzutową lewej komory (LVEF) oraz akinezę segmentów koniuszkowych. Rozpoznano zespół takotsubo. W badaniach kontrolnych wykonanych w trakcie hospitalizacji stwierdzono szybką poprawę kliniczną ze wzrostem LVEF do 40% już 2. dnia hospitalizacji. W związku z dobrym stanem ogólnym chorą wypisano do domu 10. dnia hospitalizacji. Pacjentka pozostają pod regularną kontrolą kardiologiczną, bez cech nawrotu zespołu takotsubo. Po 3,5-letnim okresie obserwacji odnotowano LVEF wynoszącą 60% bez istotnych zaburzeń kurczliwości regionalnej.

Słowa kluczowe: zespół takotsubo, tyroidektomia, nagłe zatrzymanie krążenia, wstrząs kardiogeny

Folia Cardiologica 2020; 15, 6: 419–422

References

- Ghadri JR, Wittstein IS, Prasad A, et al. International Expert Consensus Document on Takotsubo Syndrome (part I): clinical characteristics, diagnostic criteria, and pathophysiology. *Eur Heart J*. 2018; 39(22): 2032–2046, doi: [10.1093/eurheartj/ehy076](https://doi.org/10.1093/eurheartj/ehy076), indexed in Pubmed: [29850871](https://pubmed.ncbi.nlm.nih.gov/29850871/).
- Stępień K, Nowak K, Pasięka P, et al. Typical variant of takotsubo cardiomyopathy in oncological patients. Two case reports and review of the literature. *Folia Med Cracov*. 2020; 60(1): 45–54, doi: [10.24425/fmc.2020.133485](https://doi.org/10.24425/fmc.2020.133485), indexed in Pubmed: [32658211](https://pubmed.ncbi.nlm.nih.gov/32658211/).
- Agarwal S, Bean MG, Hata JS, et al. Perioperative takotsubo cardiomyopathy: a systematic review of published cases. *Semin Cardiothorac Vasc Anesth*. 2017; 21(4): 277–290, doi: [10.1177/1089253217700511](https://doi.org/10.1177/1089253217700511), indexed in Pubmed: [29098955](https://pubmed.ncbi.nlm.nih.gov/29098955/).
- Stiermaier T, Eitel C, Desch S, et al. Incidence, determinants and prognostic relevance of cardiogenic shock in patients with takotsubo cardiomyopathy. *Eur Heart J Acute Cardiovasc Care*. 2016; 5(6): 489–496, doi: [10.1177/2048872615612456](https://doi.org/10.1177/2048872615612456), indexed in Pubmed: [26474843](https://pubmed.ncbi.nlm.nih.gov/26474843/).
- Gili S, Cammann VL, Schlossbauer SA, et al. Cardiac arrest in takotsubo syndrome: results from the InterTAK Registry. *Eur Heart J*. 2019; 40(26): 2142–2151, doi: [10.1093/eurheartj/ehz170](https://doi.org/10.1093/eurheartj/ehz170), indexed in Pubmed: [31098611](https://pubmed.ncbi.nlm.nih.gov/31098611/).

6. Stepien K, Nowak K, Wypasek E, et al. High prevalence of inherited thrombophilia and antiphospholipid syndrome in myocardial infarction with non-obstructive coronary arteries: Comparison with cryptogenic stroke. *Int J Cardiol.* 2019; 290: 1–6, doi: [10.1016/j.ijcard.2019.05.037](https://doi.org/10.1016/j.ijcard.2019.05.037), indexed in Pubmed: [31133433](https://pubmed.ncbi.nlm.nih.gov/31133433/).
7. Stepien K, Nowak K, Nessler J, et al. Worse long-term prognosis in myocardial infarction occurring at weekends or public holidays with insight into myocardial infarction with nonobstructive coronary arteries. *Pol Arch Intern Med.* 2020; 130(11): 942–952, doi: [10.20452/pamw.15615](https://doi.org/10.20452/pamw.15615), indexed in Pubmed: [32969634](https://pubmed.ncbi.nlm.nih.gov/32969634/).
8. Marafioti V, Turri G, Monaco S. Important distinction between acute coronary syndromes and takotsubo syndrome. *Nat Rev Cardiol.* 2020; 17(4): 258, doi: [10.1038/s41569-020-0342-7](https://doi.org/10.1038/s41569-020-0342-7), indexed in Pubmed: [31996799](https://pubmed.ncbi.nlm.nih.gov/31996799/).
9. Montone RA, Galiuto L, Meucci MC, et al. Coronary slow flow is associated with a worse clinical outcome in patients with takotsubo syndrome. *Heart.* 2020; 106(12): 923–930, doi: [10.1136/heartjnl-2019-315909](https://doi.org/10.1136/heartjnl-2019-315909), indexed in Pubmed: [31924712](https://pubmed.ncbi.nlm.nih.gov/31924712/).
10. Krawczyk K, Stepien K, Nowak K, et al. ST-segment re-elevation following primary angioplasty in acute myocardial infarction with patent infarct-related artery: impact on left ventricular function recovery and remodeling. *Post Kardiol Interw.* 2019; 15(4): 412–421, doi: [10.5114/aic.2019.90215](https://doi.org/10.5114/aic.2019.90215), indexed in Pubmed: [31933657](https://pubmed.ncbi.nlm.nih.gov/31933657/).

Commentary



Monika Budnik MD, PhD

1st Department of Cardiology, Medical University of Warsaw, Warszawa, Poland

Although takotsubo syndrome (TTS) has been known since 1990, it remains largely a mystery. The pathophysiology of this condition and causal treatment are not fully elucidated. According to the InterTAK classification, depending on the type of causative agent, TTS can be distinguished into four classes – related to an emotional or physical factor (here, we distinguish TTS secondary to physical exertion, comorbidities, procedures and neurological disorders) and without particular causes [1]. An especially difficult group of patients are those treated in intensive care units (ICU) and after sudden cardiac arrest. It is estimated that TTS may involve approximately 5% of patients hospitalised in the ICU undergoing echocardiographic examination [2] due to hemodynamic instability.

The authors present an interesting case of TTS, which occurred after induction of anesthesia before thyroidectomy. The first sign of the disease was sudden cardiac arrest due to asystole, followed by effective resuscitation and development of cardiogenic shock. Bradycardia and asystole are rare complications of TTS, occurring in approximately 2–5% of patients [3, 4] is transient or permanent complete AV block [5]. The incidence of sudden cardiac arrest in TTS is not known. According to the InterTAK registry, approximately 8% of patients with TTS required cardiopulmonary resuscitation [6]. In the Japanese population, 19.8% of patients who suffered from sudden cardiac death were diagnosed with stress-induced cardiac dysfunction post-mortem [7]. Establishing the diagnosis of TTS in a patient after a sudden cardiac arrest may be incredibly difficult. Contractility abnormalities can result from cardiac arrest and hypoxia alone. A relatively small increase in markers of myocardial necrosis may be due to the development of TTS, but also cardiac arrest and cardiopulmonary resuscitation. A thorough case-by-case analysis based on laboratory tests and imaging, in a context of clinical findings is necessary. Differential diagnosis should primarily rule out acute coronary syndrome, pulmonary embolism, myocarditis, or left ventricular dysfunction in the course of sepsis. Every patient with suspected TTS should undergo mandatory laboratory testing, including troponin, N-terminal pro-B-type natriuretic peptide (NT-proBNP), creatine kinase-myocardial band (CK-MB), inflammatory markers, and D-dimer levels [8]. Examination of coronary arteries should always be performed if clinical condition allows. Echocardiography is of key importance in the diagnostics and monitoring, which allows the diagnosis of TTS once contractility abnormalities are resolved.

In the described case, full differential diagnosis was performed, and most importantly, the presence of significant coronary artery stenosis was excluded. Moreover, intracranial bleeding was ruled out. Subsequent echocardiographic examinations confirmed rapid improvement of left ventricular contractility, confirming the diagnosis of type IIa TTS.

Response to stress associated with surgery begins already during the induction of anesthesia, lasts 3–4 days after surgery and involves activation of the sympathetic nervous system. Moreover, surgery itself is associated with a mental and emotional burden. All these factors may promote development of TTS in the perioperative period. The effects of anaesthetics cannot be ruled out. Due to the presence of TTS in only 0.08% of the general population treated in hospital [2], a huge number of surgeries performed every day all over the world and only a negligible incidence of TTS in this group of patients, our experience is based on individual cases only. Meanwhile, intra-hospital mortality of patients with TTS treated in the ICU is high at 32% vs. 20% in the general population treated in the ICU [9] and, according to some reports, can be as high as 37% [10].

Therefore, reports based on data from national TTS registers are extremely valuable. A multicenter, nationwide register of patients with TTS (acronym Pol-tako; www.pol-tako.pl), encompassing all cathlabs is conducted in Poland. Registry data can help develop more effective diagnostic and treatment methods for each type of TTS. I hope that thanks to the obtained data, TTS will no longer remain a mystery.