






Patient out of control: diagnostic and treatment dilemmas in Loeys-Dietz syndrome

Pacjent poza kontrolą – trudności diagnostyczne i lecznicze
w zespole Loeysa-Dietza

Anna Danel¹, Alicja Szczerba¹, Radosław Kowalski¹,
Joanna Śliwka², Szymon Pawlak³

¹Faculty of Medical Sciences in Zabrze, Medical University of Silesia, Katowice, Poland

²Department of Cardiac Surgery, Transplantology and Mechanical Circulatory Support in Children, Silesian Center
for Heart Diseases, Zabrze, Poland

³Department of Cardiac, Vascular and Endovascular Surgery and Transplantology, Silesian Center for Heart Disease, Zabrze,
Medical University of Silesia, Katowice, Poland

Abstract

Loeys-Dietz syndrome (LDS) first identified in 2005 is an aggressive congenital disorder of connective tissue characterized by multisystemic involvement (hypertelorism, and bifid/broad uvula or cleft palate). The most common features are vascular manifestations such as widespread arterial aneurysms and dissection at a young age. The diagnosis is confirmed by a molecular test and computed tomography but no specific diagnostic criteria exist. The similarity of clinical manifestations to other connective tissue disorders may be associated with poor recognition of LDS. The patient is a 20-month-old boy who was admitted to our clinic presenting circulatory failure. Tests revealed dilated ascending aorta and aortic valve regurgitation, because of which ascending aorta and aortic valve replacement was performed. Seven years later his health state deteriorated significantly. Computed tomography angiography revealed a massive aneurysm of the aortic arch (8 cm), multiple thoracic aortic aneurysms and vascular tortuosity. Based on significant clinical image LDS was diagnosed. Due to the multiplicity of aneurysms, the patient was disqualified from any further surgical treatment. LDS is characterized by an aggressive vascular course. Early diagnosis, prophylactic surgery of the aorta and pharmacological treatment are recommended in these patients as the only possibility to prolong their lives.

Key words: Loeys-Dietz syndrome, connective tissue diseases, aortic aneurysm, cardiovascular abnormalities, aortic dissection

Folia Cardiologica 2022; 17, 6: 363–366

Address for correspondence: Anna Danel MD, Department of Cardiac Surgery, Transplantology and Mechanical Circulatory Support in Children, Faculty of Medical Sciences in Zabrze, Medical University of Silesia, Katowice, Poland, e-mail: aniadan24@gmail.com

This article is available in open access under Creative Common Attribution-Non-Commercial-No Derivatives 4.0 International (CC BY-NC-ND 4.0) license, allowing to download articles and share them with others as long as they credit the authors and the publisher, but without permission to change them in any way or use them commercially.

Introduction

Loeys-Dietz syndrome (LDS) is a rare connective tissue disorder (CTD) with autosomal dominant inheritance. 75% of cases result from de novo mutation [1]. The exact prevalence is unknown. LDS has multisystemic manifestations, considering a mainly cardiovascular system.

Case report

A 20-month-old boy was admitted to a hospital in severe general condition with the blood flow centralization. Echocardiography revealed left ventricular hypertrophy with a left ventricular ejection fraction (LVEF) of 14%. Computed tomography angiography (CTA) presented ascending aorta diameter enlarged to 3.5 cm (Figure 1), aortic arch diameter to 1.8 cm. Diagnostic cardiac catheterization revealed massive aortic valve regurgitation. Cardiac surgeons performed aortic valve replacement and supracoronary ascending aorta replacement which improved the patient's condition significantly (LVEF improved to 40%). On the 18th day after surgery, the boy was discharged with an antihypertensive drug regimen. Due to parental non-compliance, the patient did not follow treatment directions. Seven years later the boy was admitted to our clinic with features of upper respiratory tract inflammation, progressive dyspnoea and exercise intolerance. The X-ray image was inconclusive. Inflammation parameters were moderately elevated, blood culture result was negative. Empiric antibiotic therapy was initiated. Echocardiography did not show any vegetations.

CTA revealed: an aortic arch aneurysm (8 cm), multiple thoracic aortic aneurysms, dilated brachiocephalic trunk (3.25 cm) (Figure 2A) and common carotid arteries, aneurysm of the right middle cerebral artery (Figure 2B). Moreover, the patient presented optic neuropathy, papilledema, dissection of a retina, intraocular inflammation and scoliosis. Based on clinical manifestation the LDS was diagnosed by two independent units. Due to the multiplicity of aneurysms Heart Team disqualified the patient from any surgical treatment. Tracheobronchial compression with atelectasis occurred as a consequence of an aortic arch aneurysm. Because of recurrent respiratory disorders demanding mechanical ventilation and repeated intubations tracheostomy was performed. Unfortunately, the patient died due to spontaneous pulmonary haemorrhage and cardiac arrest.

Due to the overlapping symptoms among Marfan-like syndromes, establishing the diagnosis of LDS may be challenging in clinical practice. Abnormal twists and turns of arteries have been considered hallmarks of LDS. However, studies have proven that tortuosity is present in many other genetically mediated arteriopathies [2]. Nevertheless, the development of quantitative methods describing arterial tortuosity such as the tortuosity index (TI) creates new possibilities to differentiate between CTD. Spinardi et al. [3] found the vertebrobasilar system (VBS) TI to be the strongest independent predictor of LDS in patients with CTD. Increased vertebral TI links with more severe dilatation of the aortic root, higher probability of cardiac surgery intervention, earlier dissection and death [4]. Another valuable tool is the newly described chalice sign, which is

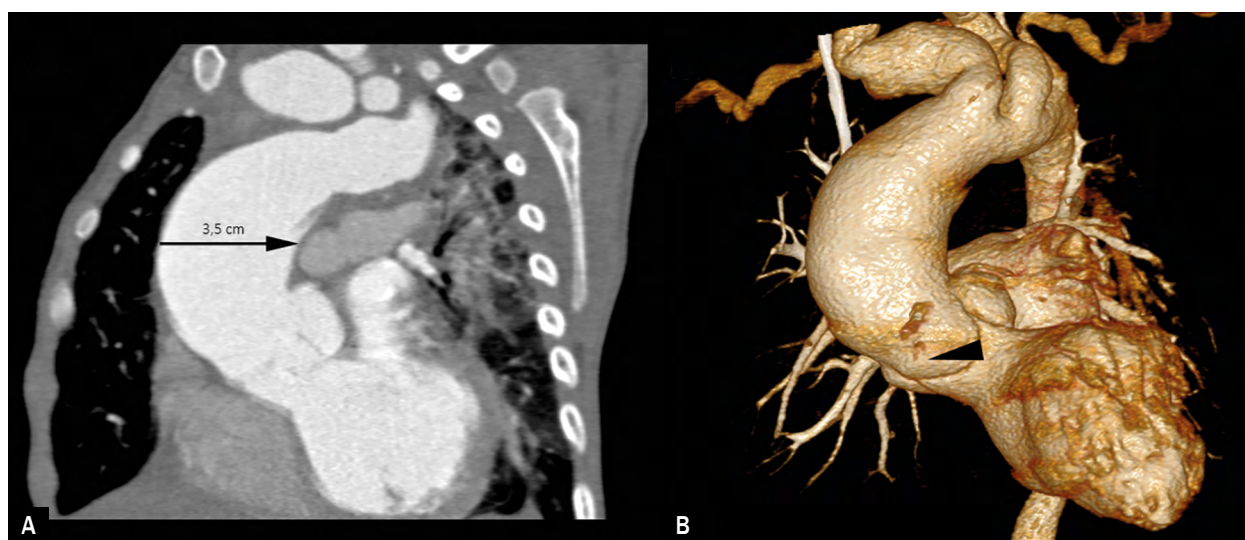


Figure 1. Multislice CT angiography of an aortic arch aneurysm in a 20-month-old boy with suspected Marfan syndrome; **A.** Sagittal CT angiogram; **B.** 3D volume rendering image show ascending aorta with a maximum diameter of 3.5 cm (arrow), a significant enlargement of the aortic root and moderately dilated three sinuses of Valsalva (arrowhead) with severe aortic regurgitation; CT – computed tomography

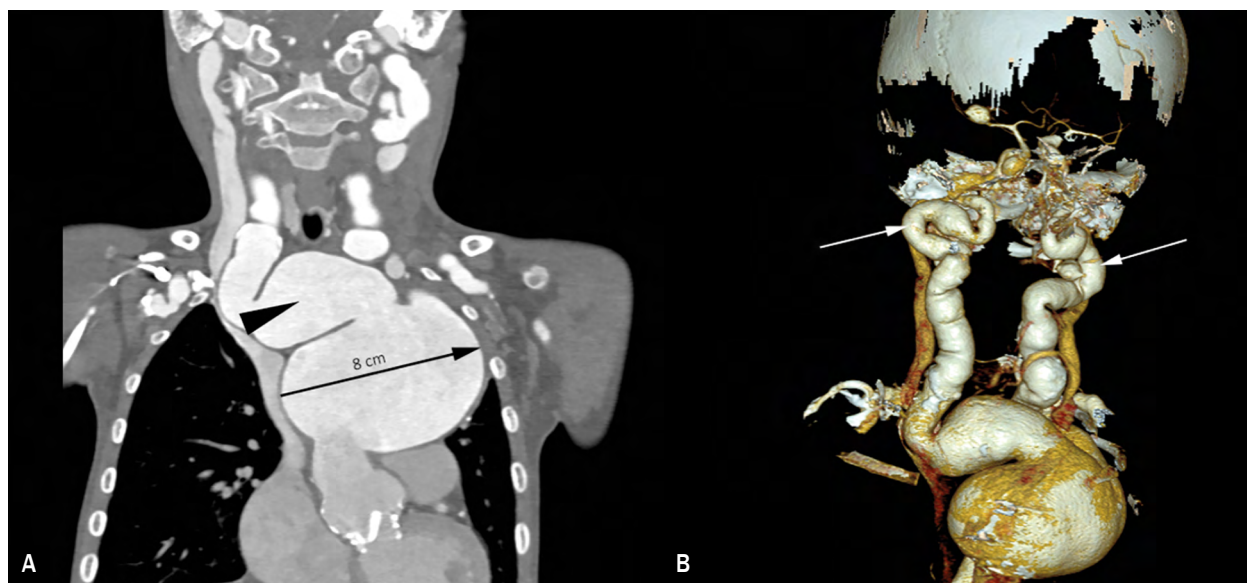

Figure 2. Multislice CT angiography of an 8-year-old boy with radiological diagnosis of Loey-Dietz syndrome; **A.** Coronal CT angiogram shows an 8 cm aortic arch aneurysm (arrow) and dilated brachiocephalic trunk with a maximal diameter of 3.25 cm (arrowhead); **B.** 3D volume rendering image reveals markedly tortuous left and right common carotid arteries (arrows). Additional CT finding includes an aneurysm of the right middle cerebral artery (arrowhead); CT – computed tomography

defined as a carotid bifurcation angle of $\geq 80^\circ$, highly specific for LDS especially when bilateral [5].

The average life expectancy in patients with LDS is 37 years while those with vascular Ehlers–Danlos syndrome (EDS) are expected to live 48 years and patients diagnosed with Marfan syndrome and properly treated have an average lifespan of 70 years [6]. Differences are related to the known propensity toward rupture and dissection at a younger age and smaller aortic diameter in LDS [7]. The major source of early mortality is thoracic aortic dissection (67%), abdominal aortic dissection (22%) and cerebral hemorrhage (7%) [6]. A noteworthy correlation between cerebral aneurysms and extracranial arterial dissection was reported. Cerebral aneurysm found in the brain imaging screening may point out the need for careful investigation due to the higher risk of severe extracranial vascular events [8]. Conservative medication involves strict control of hypertension and reducing hemodynamic stress [9]. Most of the patients require surgical interventions. In comparison to the EDS, the fatal complication rate post-surgery is 1.7% in LDS versus 45% in EDS. All patients with LDS require

annual echocardiography to control especially the aortic root. Moreover, the whole arterial tree should be assessed over aneurysms and tortuosity in magnetic resonance angiography or CTA.

Conclusion

As the LDS is characterized by the most aggressive vascular course among CTD, early diagnosis and prompt pharmacological and surgical interventions are crucial in avoiding dreadful consequences. Despite the exact criteria for diagnosing LDS are not established, we need to consider the disease when we find any LDS-related mutation in genes combined with characteristic clinical presentation: multiple arterial aneurysms, dissection or family history of the disease [10]. Future research might bring personalized gene-based management strategies.

Conflict of interest

The authors declare no conflict of interest.

Streszczenie

Zespół Loeysa-Dietza (LDS) opisany po raz pierwszy w 2005 roku jest wrodzoną wieloukładową chorobą tkanki łącznej o agresywnym przebiegu. Najczęstsze są objawy naczyniowe, takie jak rozległe tętniaki i rozwarstwienia tętnic, do których dochodzi w młodym wieku. Diagnoza stawiana jest na podstawie wyników badań molekularnych i tomografii komputerowej, jednak nadal nie istnieją specyficzne kryteria diagnostyczne. Podobieństwo objawów klinicznych do innych zaburzeń tkanki łącznej skutkuje zbyt małą rozpoznawalnością LDS. Praca przedstawia historię 20-miesięcznego chłopca przyjętego do kliniki z powodu niewydolności krążenia. Przeprowadzone badania wykazały poszerzenie aorty wstępującej i niedomykalność zastawki aortalnej, z powodu których podjęto decyzje o wymianie aorty wstępującej i zastawki aortalnej. Siedem lat po zabiegu stan zdrowia chłopca uległ znacznemu pogorszeniu. W angiografii tomografii komputerowej rozpoznano masywnego tętniaka łuku aorty (8 cm), liczne tętniaki aorty piersiowej i stwierdzono krętość naczyń. Na podstawie charakterystycznego obrazu klinicznego rozpoznano LDS. Ze względu na mnogość tętniaków pacjent został zdyskwalifikowany z dalszego leczenia operacyjnego. LDS charakteryzuje się agresywnym przebiegiem naczyniowym, więc u chorych kluczowe znaczenie mają wczesna diagnostyka, profilaktyczna operacja aorty i leczenie farmakologiczne dające jedyną możliwość przedłużenia życia.

Słowa kluczowe: zespół Loeysa-Dietza, choroby tkanki łącznej, tętniak aorty, anomalie naczyniowe, rozwarstwienie aorty

Folia Cardiologica 2022; 17, 6: 363–366

References

- Loeys BL, Dietz HC. Loey-Dietz syndrome. In: Adam MP, Ardinger HH, Pagon RA. ed. GeneReviews®. University of Washington, Seattle (WA) : 1993–2021.
- Morris SA. Arterial tortuosity in genetic arteriopathies. *Curr Opin Cardiol.* 2015; 30(6): 587–593, doi: [10.1097/HCO.0000000000000218](https://doi.org/10.1097/HCO.0000000000000218), indexed in Pubmed: [26398550](https://pubmed.ncbi.nlm.nih.gov/26398550/).
- Spinardi L, Vornetti G, De Martino S, et al. Intracranial arterial tortuosity in marfan syndrome and loeys-dietz syndrome: tortuosity index evaluation is useful in the differential diagnosis. *AJNR Am J Neuroradiol.* 2020; 41(10): 1916–1922, doi: [10.3174/ajnr.A6732](https://doi.org/10.3174/ajnr.A6732), indexed in Pubmed: [32819908](https://pubmed.ncbi.nlm.nih.gov/32819908/).
- Morris SA, Orbach DB, Geva T, et al. Increased vertebral artery tortuosity index is associated with adverse outcomes in children and young adults with connective tissue disorders. *Circulation.* 2011; 124(4): 388–396, doi: [10.1161/CIRCULATIONAHA.110.990549](https://doi.org/10.1161/CIRCULATIONAHA.110.990549), indexed in Pubmed: [21730308](https://pubmed.ncbi.nlm.nih.gov/21730308/).
- Benson JC, Brinjikji W. The Chalice sign: characteristic morphology of the cervical carotid bifurcation in patients with Loey-Dietz syndrome. *Clin Neuroradiol.* 2020; 30(4): 713–720, doi: [10.1007/s00062-019-00838-5](https://doi.org/10.1007/s00062-019-00838-5), indexed in Pubmed: [31552453](https://pubmed.ncbi.nlm.nih.gov/31552453/).
- Loeys BL, Schwarze U, Holm T, et al. Aneurysm syndromes caused by mutations in the TGF-beta receptor. *N Engl J Med.* 2006; 355(8): 788–798, doi: [10.1056/NEJMoa055695](https://doi.org/10.1056/NEJMoa055695), indexed in Pubmed: [16928994](https://pubmed.ncbi.nlm.nih.gov/16928994/).
- Williams JA, Loeys BL, Nwakanma LU, et al. Early surgical experience with Loey-Dietz: a new syndrome of aggressive thoracic aortic aneurysm disease. *Ann Thorac Surg.* 2007; 83(2): S757–S763; discussion S785, doi: [10.1016/j.athoracsur.2006.10.091](https://doi.org/10.1016/j.athoracsur.2006.10.091), indexed in Pubmed: [17257922](https://pubmed.ncbi.nlm.nih.gov/17257922/).
- Spinardi L, Mariucci E, Vornetti G, et al. High prevalence of arterial dissection in patients with Loey-Dietz syndrome and cerebral aneurysm. *Vasc Med.* 2020; 25(3): 218–220, doi: [10.1177/1358863X19900923](https://doi.org/10.1177/1358863X19900923), indexed in Pubmed: [32129152](https://pubmed.ncbi.nlm.nih.gov/32129152/).
- Patel ND, Crawford T, Magruder JT, et al. Cardiovascular operations for Loey-Dietz syndrome: Intermediate-term results. *J Thorac Cardiovasc Surg.* 2017; 153(2): 406–412, doi: [10.1016/j.jtcvs.2016.10.088](https://doi.org/10.1016/j.jtcvs.2016.10.088), indexed in Pubmed: [27955909](https://pubmed.ncbi.nlm.nih.gov/27955909/).
- MacCarrick G, Black JH, Bowdin S, et al. Loey-Dietz syndrome: a primer for diagnosis and management. *Genet Med.* 2014; 16(8): 576–587, doi: [10.1038/gim.2014.11](https://doi.org/10.1038/gim.2014.11), indexed in Pubmed: [24577266](https://pubmed.ncbi.nlm.nih.gov/24577266/).