

# Electrocardiography for the diagnosis of left ventricular hypertrophy in end-stage renal disease treated with haemodialysis

Elektrokardiografia w diagnostyce przerostu mięśnia lewej komory u pacjentów ze schyłkową niewydolnością nerek leczonych powtarzanymi zabiegami hemodializ

Agnieszka Szramowska<sup>1</sup>, Katarzyna Kurnicka<sup>1</sup>, Marek Roik<sup>1</sup>, Marcin Koć<sup>1</sup>, Andrzej Łabyk<sup>1</sup>,  
Olga Zdończyk<sup>1</sup>, Maksymilian Bielecki<sup>2</sup>, Piotr Bienias<sup>1</sup>, Aisha Ou-Pokrzewińska<sup>1</sup>,  
Mirosław Grzeszczyk<sup>3</sup>, Marek Cacko<sup>4</sup>, Piotr Pruszczyk<sup>1</sup>

<sup>1</sup>Department of Internal Medicine and Cardiology, Medical University of Warsaw, Poland

<sup>2</sup>Department of Psychology, SWPS University of Social Sciences and Humanities, Poland

<sup>3</sup>Department of Internal Medicine, Nephrology and Transplantology, Medical University of Warsaw, Poland

<sup>4</sup>Department of Nuclear Medicine, Medical University of Warsaw, Poland



Lekarz Agnieszka Szramowska jest absolwentką I Wydziału Lekarskiego Warszawskiego Uniwersytetu Medycznego. Zakończyła szkolenie specjalizacyjne w zakresie chorób wewnętrznych w Klinice Chorób Wewnętrznych i Kardiologii Szpitala Klinicznego Dzieciątka Jezus w Warszawie pod kierownictwem prof. Piotra Pruszczyka. Obecnie realizuje tam rozprawę doktorską, której promotorem jest dr hab. n. med. Marek Roik. Rozprawa dotyczy oceny stężenia sercowej troponiny T w osoczu w przewidywaniu powikłań kardiologicznych u pacjentów przewlekle hemodializowanych, kwalifikowanych do zabiegu przeszczepienia nerki. Zainteresowania medyczne skupia na diagnostyce nieinwazyjnej chorób układu sercowo-naczyniowego.

Wolny czas poświęca literaturze obcej oraz podróżom po Warmii i Mazurach.

## Abstract

**Introduction.** Left ventricular hypertrophy (LVH) is one of the most common cardiovascular risk factors in patients undergoing haemodialysis (HD). Although standard ECG can help to identify patients at greater risk of LVH, its prognostic value in haemodialysed patients is uncertain. This study aimed to evaluate currently used ECG criteria for LVH in patients on renal replacement therapy.

**Material and methods.** A group of 90 patients, who were undergoing qualification to renal transplantation, were included in the study. Every patient underwent 12-lead ECG and transthoracic echocardiography. Patients with any conduction disorders were excluded from the study. Finally, the study group consisted of 76 patients (21 women, mean age  $53.1 \pm 14.4$  years).

**Results.** LVH was diagnosed by echocardiography in 39 patients (51%, 27 men and 12 women). Only three out of six tested criteria showed satisfactory performance for LVH diagnosis in HD patients: the sum of S V3 and R aVL > 28 mm in men, and > 20 mm in women (area under curve [AUC] 68%, 95% confidence interval [CI] 56–80); the sum of S V1 and R V5 or V6 > 35 mm (AUC 63%, 95%CI 50–76); and the sum of SV2 and RV5 or V6 > 45 mm (AUC 63%; 95%CI 50–75).

**Conclusions.** The present ECG diagnostic criteria for LVH are of very limited value in patients undergoing HD. Further studies should be performed to establish new ECG criteria for this group of patients. In the meantime, echocardiography should be recommended as the most precise diagnostic routine test to evaluate HD patients for LVH.

Key words: left ventricular hypertrophy, electrocardiography, end-stage renal disease, haemodialysis, renal replacement therapy

Folia Cardiologica 2019; 14, 1: 24–29

## Introduction

Cardiovascular complications are the leading cause of mortality and morbidity in patients with end-stage renal disease (ESRD). It is well known, that the prevalence of cardiovascular disease (CVD) is very high already at the beginning of renal replacement therapy (RRT) even begins [1]. Apart from the traditional risk factors for CVD, there is growing evidence that these patients are at increased risk as a result of potential specific uraemic risk factors that are responsible for the presence and progression of CVD. These include volume overload, hypertension, anaemia, abnormal calcium-phosphate metabolism, accumulation of uraemic toxins, and the chronic inflammatory process [2].

LVH, which is present in 50% to 70% of patients undergoing HD [3], is an independent risk factor of CVD and sudden cardiac death (SCD). Standard electrocardiography is a widely used screening method for diagnosing LVH [4]. However, data on the diagnostic value of ECG in haemodialysed patients is limited [5, 6]. This study aimed to assess the diagnostic value of currently used electrocardiographic (ECG) criteria for LVH diagnosis in patients with ESRD undergoing HD.

## Material and methods

A group of 90 consecutive patients (21 women, 69 men, mean age  $53.7 \pm 14.3$  years) with ESRD, who were undergoing HD, and who were hospitalised in the cardiology department for a cardiovascular assessment prior to renal transplantation, were included in the study. All of them underwent a detailed clinical evaluation *i.e.* standard 12-lead ECG, transthoracic echocardiography focused on left ventricular morphology and function, exercise ECG test when possible, and exercise perfusion heart scintigraphy (SPECT). Subsequently, all subjects with LV wall motion abnormalities at echocardiography or abnormal exercise tests underwent coronary angiography. Patients with QRS

**Table 1.** Clinical characteristics of 76 patients with end-stage renal disease (ESRD) treated with haemodialysis

Parameter	Total N = 76
Aetiology of ESRD, N [%]:	
• glomerulonephritis	27 (35.5)
• diabetes mellitus	20 (26.3)
• polycystic kidney disease	12 (15.8)
• other	17 (22.4)
Time of HD, median (months)	24 (2–228)
Coronary artery disease, N [%]	33 (43)
Hypertension, N [%]	71 (96)
Heart failure (HF), nN [%]:	
• HF-PEF	8
• HF-MEF	8
• HF-REF	2
Diabetes mellitus, N [%]:	
• type 1	7
• type 2	17

HD – haemodialysis; HF-PEF – heart failure with preserved ejection fraction; HF-MEF – heart failure with midrange ejection fraction; HF-REF – heart failure with reduced ejection fraction

duration  $\geq 120$  ms (due to right or left bundle branch block, interventricular conduction delay or after pacemaker implantation) were excluded from further analysis. Thus, the final study group consisted of 76 patients (21 female, 55 male, mean age  $53.1 \pm 14.4$  years), as set out in Table 1. This study was approved by our Institutional Review Board. All patients provided written informed consent to participate in this study.

## Electrocardiography

All patients underwent a standard rest 12-lead ECG. Examinations were performed with a Spacelabs Cardio Express

**Table 2.** Current diagnostic electrocardiographic criteria of left ventricular hypertrophy

Criterion
R aVL > 1.1 mV (11 mm)
R I + S in III > 2.5 mV (25 mm)
R V5 or V6 > 2.6 mV (26 mm)
S V1 + R V5 or V6 > 3.5 mV (35 mm)
S V2 + R V5 or V6 > 4.5 mV (45 mm)
S V3 + R aVL > 2.8 mV (28 mm) men; S V3 + R aVL > 2.0 mV (20 mm) (women)

SL6 device. The ECGs were recorded at speed of 25 mm/s and a standardised calibration of 1 mV/cm. 29 patients underwent the ECG on the day of the HD, just before the procedure, while 47 patients underwent the ECG on the day after the HD. Patients with RBBB, LBBB, IVCD or patients after pacemaker implantation were not included in the current analysis. Standard 12-lead ECG tracings were analysed by the same investigator for LVH using electrocardiographic LVH criteria according to European Society of Cardiology (ESC) and Polish Society of Cardiology guidelines [7], as set out in Table 2. The QRS amplitude was measured by the same investigator, manually.

### Echocardiography

iE 33 and EPIQ 7 Philips (Andover, Md., USA) systems with a sector transducer with bandwidths of 2.5–3.5 MHz were used for transthoracic echocardiographic examinations. Patients were placed in the left-lateral decubitus position, with continuous monitoring of a single ECG lead. Echocardiographic images were interpreted by an experienced physician according to the recommendations of the guidelines of the European Association of Cardiovascular Imaging [8]. Interventricular septum (IVS) and posterior wall (PW) thickness were measured at late diastole with two-dimensional imaging in the long parasternal axis view. Left ventricle dimensions were recorded by placing the ultrasound beam perpendicularly to its long axis. Measurements were performed in 2D visualisation and in M-Mode presentation. Left ventricular mass (LVM) was calculated according to the formula proposed by Devereux [9]:  $LVM [g] = 1.04 [(IVS [cm] + LVDd [cm])^3 - LVDd^3] - 13.6$ . The LVM index (LVMI) was calculated as LVM divided by body surface area (BSA). We diagnosed LVH when the LVMI exceeded 109 g/m<sup>2</sup> in women and 132 g/m<sup>2</sup> in men [8]. Echocardiographic examinations were performed in 31 patients just before the HD, and in 45 patients the day after the HD.

### Statistical analysis

Descriptive statistics for quantitative data were presented as means ± standard deviations or medians with ranges, when appropriate. Qualitative data were shown as counts and percentages. Between-group comparisons for qualitative data were performed using Chi-square test or Fisher's exact test, depending on the expected counts. For quantitative variables, *t*-test with Welch correction or Mann-Whitney tests were used, depending on the group size and normality of distributions. Receiver operating curves (ROC) were used to assess the performance of ECG indices for the diagnosis of LVH. For significant predictors of LVH, we assessed sensitivity and specificity based on currently accepted ECG criteria. All reported results are based on two-sided statistical tests. Effects were considered significant at a *p*-value of less than 0.05. Statistical analyses were performed using R software (R Core Team, 2017 version 3.4.2).

### Results

The clinical characteristics of the final study group with ESRD undergoing HD are set out in Table 1. The mean age was 53.1 ± 14.4 years and 27.6% were women. ESRD had resulted from glomerulonephritis in 35.5% of subjects, from diabetes mellitus in 26.3% of subjects, and from polycystic kidney disease in 15.8% of subjects. Hypertension requiring medical therapy was present in 71 patients (96%), and 33 patients (43%) suffered from coronary artery disease. LVH was diagnosed by echocardiography in 39 patients (51.3%), 27 men (69.2%) and 12 (30.8%) women. The clinical characteristics based on LVH presence are set out in Table 3. Statistically significant differences were BMI which was lower in the group of patients with LVH, and the mean time of HD which was shorter in the LVH group.

### ECG for the diagnosis of left ventricular hypertrophy

Table 4 shows ROC analysis of six electrocardiographic criteria proposed by ESC for LVH diagnosis. Only three out of six tested criteria showed satisfactory performance for LVH diagnosis in HD patients, with a lower limit of AUC confidence interval exceeding 50% (Table 5, Figure 1). The sum of the amplitude of R wave in aVL with the amplitude of S wave in V3 showed the highest significant predictive power (AUC 68%, 95% CI 56–80).

Three criteria: 1) the amplitude of R in aVL (AUC 61%; 95% CI 48–74); 2) the sum of the amplitude of R wave in lead I and amplitude of S wave in lead III (AUC 57%; 95%CI: 43–70); and 3) the amplitude of R wave in lead V5 or lead V6 (AUC 59%; 95% CI: 46–72) were found to be not statistically significant for LVH diagnosis. Eventually, using current

**Table 3.** Clinical characteristics of patients according to left ventricular hypertrophy

Parameter	LVH (+) N = 39 (51.3)	LVH (-) N = 37 (48.7)	p value
Sex M/F, n(%)	27 (69.2)/12(30.8)	28 (75.7)/9(24.3)	NS <sup>a</sup>
Age, years	51.4 ± 13.2	54.8 ± 15.5	NS
BMI [kg/m <sup>2</sup> ]	23.7 (17.2–35.5)	25.3 (18.6–33.6)	0.026 <sup>b</sup>
Time of HD, median [months]	18 (2–228)	31 (2–204)	0.017
CAD, N [%]	15 (38.5)	18 (48.6)	NS <sup>a</sup>
Hypertension, N [%]	39 (100.0)	32 (86.4)	NS <sup>c</sup>
Aetiology of ESRD N [%]:			0.014 <sup>a</sup>
• glomerulonephritis	10 (25.6)	15 (40.5)	
• diabetes mellitus	11 (28.2)	9 (24.3)	
• polycystic kidney disease	3 (7.7)	9 (24.3)	
• other	15 (38.5)	4 (10.9)	
LVM [g]	289.4 ± 69.5	195.5 ± 42.0	< 0.0001
LVM [g]:			
• M	318.0 ± 58.0	210.4 ± 33.9	< 0.0001
• F	223.5 (169.4–345.0)	165.4 (105.6–177.2)	< 0.0001 <sup>b</sup>
LVMI [g/m <sup>2</sup> ]	146.7 (112.2–235.5)	105.1 (66.7–129.2)	< 0.0001 <sup>b</sup>
LVMI [g/m <sup>2</sup> ):			
• M	155.6 (132.2–235.5)	112.1 (71.5–129.2)	< 0.0001 <sup>b</sup>
• F	129.7 (112.2–213.5)	83.8 (66.7–107.9)	< 0.0001 <sup>b</sup>

<sup>a</sup>Chi-square test, <sup>b</sup>Mann-Whitney test, <sup>c</sup>Fisher's exact test; all remaining comparisons were conducted using t-tests with Welch correction, LVH – left ventricular hypertrophy; M – male; F – female; NS – not significant; BMI – body mass index; N – number of patients; HD – haemodialysis; CAD – coronary artery disease; ESRD – end-stage renal disease; LVM – left ventricular mass; LVMI – left ventricular mass index

ECG criteria, LVH was diagnosed in only 12 of 39 subjects with echocardiographically detected LVH.

## Discussion

In this study, we assessed the effectiveness of ECG as a clinical tool reflecting LVH. Kidney Disease Outcomes Quality Initiative (K/DOQI) guidelines recommend the recording of an ECG in every patient at the initiation of RRT, and annually thereafter [9]. In ESRD patients, LVH detected by ECG or echocardiography is the most common manifestation of cardiovascular disease and strongly predicts cardiovascular morbidity and mortality [6].

Therefore, ECG is the common tool which can be used to select patients with an increased cardiovascular risk. However, there is very limited data regarding the diagnostic value of standard ECG criteria in patients with ESRD undergoing HD [5, 6]. It is well known that fluid overload and electrolyte imbalance can affect QRS voltage, and thus the interpretation of standard ECG. In our study, LVH was diagnosed in 39 patients (51%). Only 12 (30.8%) patients in this group had diagnosed LVH in ECG. Three out of six

**Table 4.** Receiver operating curves analysis of electrocardiographic (ECG) criteria in the diagnosis of left ventricular hypertrophy in patients with end-stage renal disease

ECG criterion	AUC [%]	95% CI	p
R aVL	61	48–74	NS
R I + S III	57	43–70	NS
R V5 or V6	59	46–72	NS
S V1 + R V5 or V6	63	50–76	0.047
S V2 + R V5 or V6	63	50–75	0.036
S V3 + R aVL	68	56–80	0,003

NS – not significant; AUC – area under curve; CI – confidence interval

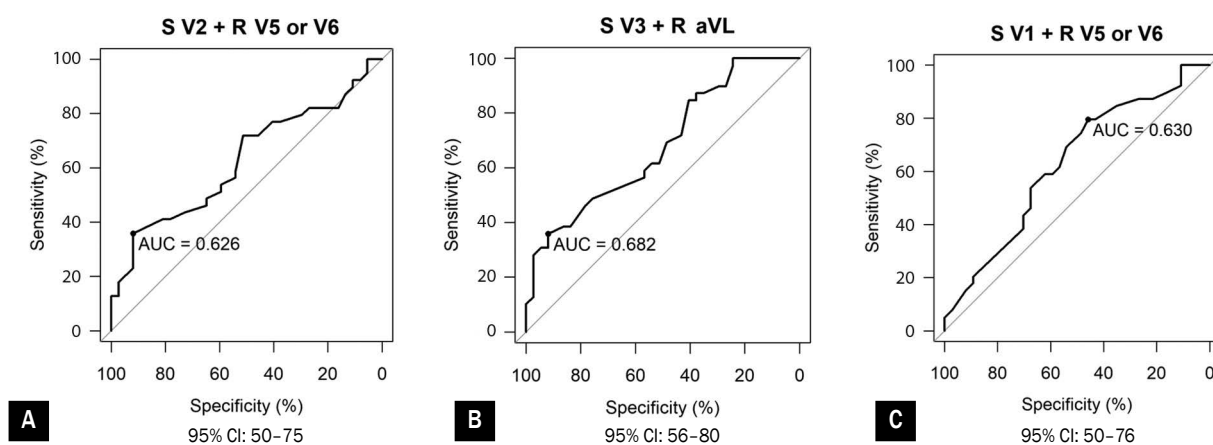
proposed ECG criteria were found to have a significant predictive power in ROC analysis. Of these three, the most useful for LHV diagnosis in HD patients (AUC 68% 95 CI 56–80), was found to be the sum of sV3 with RaVL. Importantly, current cut-off values of ECG criteria were found to be suboptimal.

Our study had several limitations. Because the number of patients was relatively small, the clinical outcomes

**Table 5.** Diagnostic value of current electrocardiographic criteria in the diagnosis of left ventricular hypertrophy in patients with end-stage renal disease

Criterion	Value [mm]	Current cut-off			
		Sensitivity [%]	Specificity [%]	PPV [%]	NPV [%]
S V1 + R V5 or V6 [mm]	35	8	97	75	53
S V2 + RV5 or V6 [mm]	45	8	100	100	53
S V3 + aVL	M > 28 F > 20	14	97	83	54

PPV – positive predictive value; NPV – negative predictive value



**Figure 1A-C.** Receiver operating curves for all statistically significant electrocardiographic parameters in the diagnosis of left ventricular hypertrophy in patients with end-stage renal disease; AUC – area under curve; CI – confidence interval

may not be generalisable to the whole population. Some authors have suggested that ECG should be interpreted in the context of the recording time, in relation to the HD treatment, fluid overload and electrolyte status, because these changes have been shown to affect ECG wave amplitude, which can determine the diagnosis of LVH [10].

In our study, 29 patients underwent the ECG just before the HD, while 47 patients underwent the ECG the day after the HD. Also, echocardiographic examinations were performed in 31 patients just before the HD, and in 45 patients the day after the HD. Therefore, we did not find any statistically significant difference in diagnosing LVH in both groups.

## Conclusions

The present ECG criteria for LVH are of very limited value in the group of patients undergoing HD. A further study on a large group of patients should be performed to establish new cut-off points for ECG criteria for patients requiring HD.

In the meantime, it appears that echocardiography should be recommended as the most precise routine diagnostic method to evaluate for the presence of LVH.

## Conflict(s) of interest

The authors have no conflict of interest to declare.

**Streszczenie**

**Wstęp.** Przerost mięśnia lewej komory (LVH) jest głównym czynnikiem ryzyka powikłań sercowo-naczyniowych u pacjentów leczonych powtarzanymi zabiegami hemodializ (HD). Choć rutynowo wykonywany zapis elektrokardiograficzny (EKG) może pomóc w identyfikacji chorych z LVH, to jego wartość diagnostyczna wśród pacjentów poddawanych zabiegom HD pozostaje niepewna. Celem badania była weryfikacja przydatności diagnostycznej stosowanych obecnie kryteriów elektrokardiograficznych LVH w grupie pacjentów leczonych nerkozastępczo.

**Materiał i metody.** Do badania włączono 90 chorych kwalifikowanych do zabiegu przeszczepienia nerki. U każdego pacjenta wykonano 12-odprowadzeniowy zapis EKG oraz przekłatkowe badanie echokardiograficzne. Z badania wykluczono chorych z zaburzeniami przewodzenia śródkomorowego rozpoznawanymi w badaniu EKG. Ostatecznie do badania włączono 76 pacjentów (21 kobiet, średni wiek  $53,1 \pm 14,4$  roku).

**Wyniki.** W badaniu echokardiograficznym LVH rozpoznano u 39 chorych (51%, 27 mężczyzn i 12 kobiet). Tylko 3 z 6 ocenianych kryteriów okazały się istotne statystycznie w diagnostyce LVH u hemodializowanych chorych. Były to: suma załamka S w odprowadzeniu V3 oraz załamka R w odprowadzeniu aVL przekraczająca 28 mm u mężczyzn i 20 mm u kobiet (pole pod krzywą [AUC] 68%, 95-proc. przedział ufności [CI] 56–80), suma załamka S w odprowadzeniu V1 oraz załamka R w odprowadzeniu V5 lub V6 przekraczająca 35 mm (AUC 63%, 95%CI 50–76), a także suma załamka S w odprowadzeniu V2 i załamka R w odprowadzeniu V5 lub V6 przekraczająca 45 mm (AUC 63%; 95%CI 50–75).

**Wnioski.** Stosowane obecnie kryteria elektrokardiograficzne LVH mają niską wartość diagnostyczną w grupie chorych hemodializowanych. Należy przeprowadzić dalsze badania w celu ustalenia nowych kryteriów elektrokardiograficznych LVH w tej grupie chorych. Wydaje się, że badanie echokardiograficzne jest najbardziej dokładne w wykrywaniu LVH i to ono powinno być obecnie wykorzystywane do diagnostyki LVH w grupie chorych poddawanych HD.

Słowa kluczowe: przerost mięśnia lewej komory, elektrokardiografia, schyłkowa niewydolność nerek, hemodializy, terapia nerkozastępcza

Folia Cardiologica 2019; 14, 1: 24–29

**References**

1. Locatelli F. Effect of anaemia on left ventricular hypertrophy in end-stage renal disease. *Eur J Heart Failure Suppl.* 2003; 2(2): 207–212, doi: [10.1016/s1567-4215\(03\)80004-8](https://doi.org/10.1016/s1567-4215(03)80004-8).
2. Cafka M, Rroji M, Seferi S, et al. Inflammation, left ventricular hypertrophy, and mortality in end-stage renal disease. *Iran J Kidney Dis.* 2016; 10(4): 217–223, indexed in Pubmed: [27514769](https://pubmed.ncbi.nlm.nih.gov/27514769/).
3. Kiciński P, Kołodziejczyk B, Jaroszyński A, et al. Przydatność wybranych wskaźników elektrokardiograficznych w diagnostyce przerostu mięśnia lewej komory serca u pacjentów hemodializowanych. *Nefrol Dial Pol.* 2010; 14: 55–58.
4. Levy D, Garrison RJ, Savage DD, et al. Prognostic implications of echocardiographically determined left ventricular mass in the Framingham Heart Study. *N Engl J Med.* 1990; 322(22): 1561–1566, doi: [10.1056/NEJM199005313222203](https://doi.org/10.1056/NEJM199005313222203), indexed in Pubmed: [2139921](https://pubmed.ncbi.nlm.nih.gov/2139921/).
5. Cordeiro AC, Lindholm B, Sousa MG, et al. Reliability of electrocardiographic surrogates of left ventricular mass in patients with chronic kidney disease. *J Hypertens.* 2014; 32(2): 439–445, doi: [10.1097/HJH.000000000000026](https://doi.org/10.1097/HJH.000000000000026), indexed in Pubmed: [24317549](https://pubmed.ncbi.nlm.nih.gov/24317549/).
6. Kim SJ, Oh HJ, Yoo DE, et al. Electrocardiographic left ventricular hypertrophy and outcome in hemodialysis patients. *PLoS One.* 2012; 7(4): e35534, doi: [10.1371/journal.pone.0035534](https://doi.org/10.1371/journal.pone.0035534), indexed in Pubmed: [22530043](https://pubmed.ncbi.nlm.nih.gov/22530043/).
7. Baranowski R, Wojciechowski D, Maciejewska M. Recommendation for electrocardiographic diagnosis. *Kardiol Pol.* 2010; 68(Suppl IV).
8. Lang RM, Badano LP, Mor-Avi V, et al. Recommendations for cardiac chamber quantification by echocardiography in adults: an update from the American Society of Echocardiography and the European Association of Cardiovascular Imaging. *Eur Heart J Cardiovasc Imaging.* 2015; 16(3): 233–270, doi: [10.1093/ehjci/jev014](https://doi.org/10.1093/ehjci/jev014), indexed in Pubmed: [25712077](https://pubmed.ncbi.nlm.nih.gov/25712077/).
9. Devereux RB, Alonso D, Lutas E, et al. Echocardiographic assessment of left ventricular hypertrophy: comparison to necropsy findings. *Am J Cardiol.* 1986; 57(6): 450–458, indexed in Pubmed: [2936235](https://pubmed.ncbi.nlm.nih.gov/2936235/).
10. Krane V, Heinrich F, Meesmann M, et al. German Diabetes and Dialysis Study Investigators. Electrocardiography and outcome in patients with diabetes mellitus on maintenance hemodialysis. *Clin J Am Soc Nephrol.* 2009; 4(2): 394–400, doi: [10.2215/CJN.02020408](https://doi.org/10.2215/CJN.02020408), indexed in Pubmed: [19158371](https://pubmed.ncbi.nlm.nih.gov/19158371/).