

Constrictive pericarditis mimicking severe mitral restenosis in a post-operative patient of rheumatic heart disease

Zaciskające zapalenie osierdza imitujące ciężką restenozę zastawki mitralnej u chorego po leczeniu chirurgicznym choroby reumatycznej serca

Biswajit Majumder, Sandip Ghosh, Praveen Shukla, Pritam Kumar Chatterjee, Sudeep K.N.

R. G. Kar Medical College and Hospital, Kolkata, Indie

Abstract

Pericardial constriction is a rare, but well documented complication following cardiac surgery. It has been reported following coronary artery bypass grafting (CABG), cardiac surgery for congenital heart diseases and very rarely following closed mitral commissurotomy. We hereby report a case of chronic constrictive pericarditis following closed mitral commissurotomy mimicking mitral restenosis with refractory heart failure.

Key words: constrictive pericarditis, mitral restenosis, post cardiac surgery, refractory heart failure

Folia Cardiologica 2018; 13, 4: 347–349

Introduction

Chronic constrictive pericarditis (CCP) rarely develops as a midterm or late complication of cardiac surgery. It often poses major diagnostic issues as its clinical picture at presentation may be nonspecific. The disease may develop at any time of follow-up. Diagnosing this disorder requires a high level of suspicion. We hereby report a case of constrictive pericarditis following closed mitral commissurotomy to remind about this complication all surgeons and physicians involved in the long-term care of cardiac surgery patients.

Case report

A 50-year-old female presented to the cardiology department with progressive shortness of breath for the last six months. She was diagnosed with mitral stenosis twenty four years back and underwent closed mitral commissurotomy twice – twenty two years and ten years from the day of presentation respectively. At presentation she was

orthopnic (NYHA class IV) with gross bipedal oedema, and a raised jugular venous pressure (JVP) with prominent v waves and rapid y descent. Her pulse was 98/min, irregular low volume, blood pressure 100/70 mm of Hg with respiratory rate of 28/min. Systemic examination revealed left lateral thoracotomy scar and prominent precordial and epigastric pulsation. On palpation the apex was not well palpable. Auscultation revealed a variably loud first heart sound at the apex along with a pansystolic murmur and a mid-diastolic murmur. There was a pansystolic murmur in the right lower parasternal region and loud pulmonary component of second heart sound with narrow split along with a mid-systolic murmur in the pulmonary area. There were bibasilar rales, tender hepatomegaly and the presence of free fluid in the abdomen. The patient was put on intravenous loop diuretics, spironolactone, and digitalis and oral vitamin K antagonist. Echocardiography revealed severe calcified mitral stenosis (Mitral valve area [MVA] 1.2 cm²) with moderate mitral regurgitation, and moderate tricuspid regurgitation with moderate pulmonary arterial hypertension (Figure 1). There was left atrial enlargement

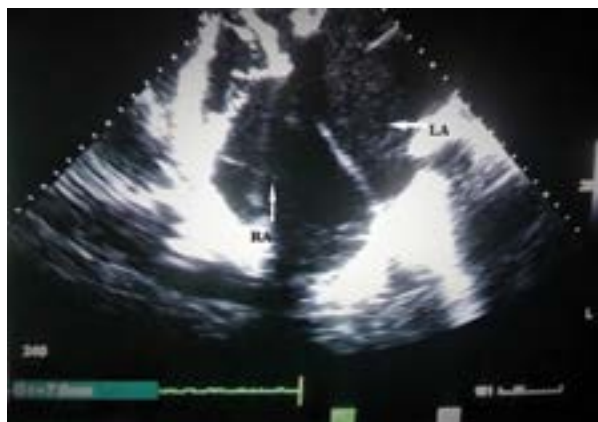


Figure 1. Transthoracic echocardiography apical 4 chamber view showing biatrial enlargement with valvular mitral stenosis

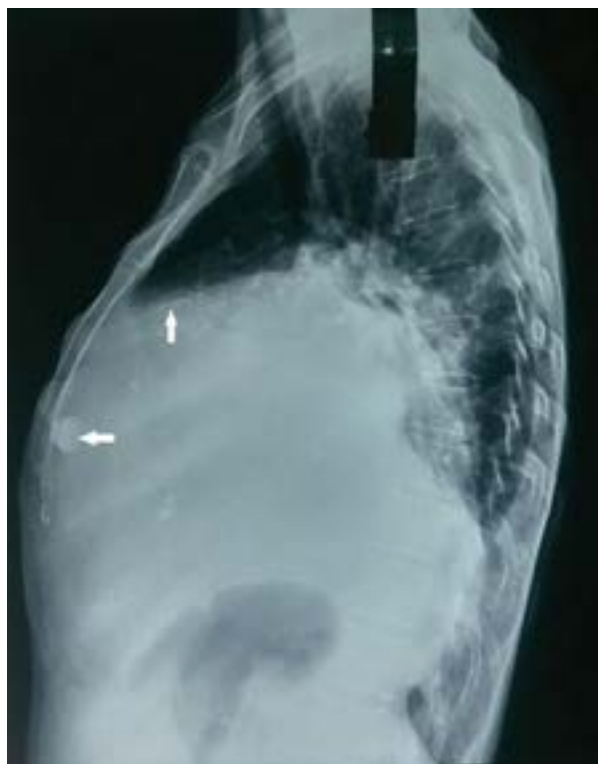

Figure 2. X-Ray chest lateral view showing pericardial calcification (arrows)

with hugely dilated right atrium disproportional to the degree of tricuspid regurgitation and pulmonary arterial hypertension. The pericardium was thickened (8 mm) with dilated inferior vena cava (IVC) (24 mm) with loss of respiratory variation of diameter.

In spite of multiple diuretic therapy, the right sided congestive symptoms did not improve. A chest X-Ray (CXR) was ordered, which showed pericardial calcification with cardiomegaly (Figure 2). Computed tomography (CT) of the

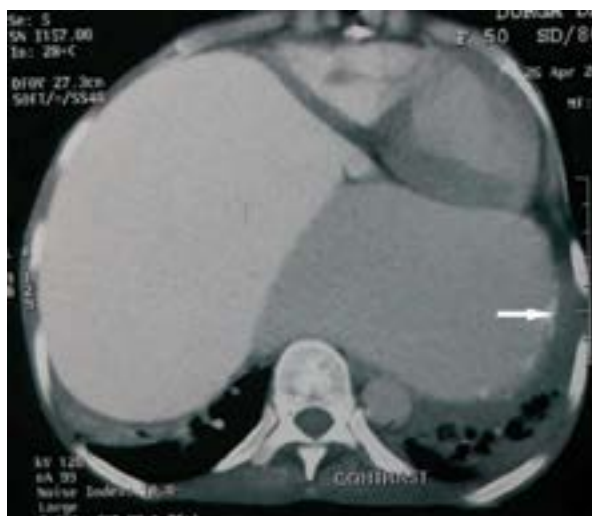

Figure 3. Contrast enhanced computed tomography of the thorax showing pericardial calcification (arrow) with bi-atrial enlargement

thorax showed thickened pericardium with calcification with biatrial enlargement (Figure 3).

Discussion

There are many causes of heart failure in a post-operative case of rheumatic heart disease (RHD). These include development of regurgitant lesions, restenosis, arrhythmias, coronary artery disease, infective endocarditis and rarely CCP.

Constrictive pericarditis is an unusual complication of cardiac surgery; its actual incidence is not well ascertained, although it may approach 2% to 3%. While the clinical signs, echocardiography and computed tomographic scan may raise the suspicion of CCP, the gold-standard diagnostic mean remains the left- and right-heart catheterisation. ¹Constrictive pericarditis as a complication of CABG was first reported by Kendall et al. in 1972 [2–4].

CCP is often difficult to diagnose and high degree of clinical suspicion is needed, especially in a patient with past history of cardiac surgery.

From the clinical history of the patient we suspected that he may be suffering from mitral restenosis with mitral regurgitation with pulmonary artery hypertension (PAH) and right sided heart failure. But in spite of use of multiple diuretics in high doses, the patient's congestive symptoms did not improve. This, along with two cardiac surgeries in the past, prompted us to think of associated constrictive pericarditis. From the echo, disproportionate right atrium enlargement compared to the degree of PAH and a thickened pericardium also supported a diagnosis of constrictive pericarditis. In the X-Ray chest and the CT-Thorax the presence of pericardial calcification and thickening also favoured the diagnosis of constrictive pericarditis.

Cardiac catheterisation was not done, because the patient was not stable and the presence of MS and PAH would interfere with the haemodynamic data classical of constrictive pericarditis. The patient was advised mitral valve replacement along with pericardiectomy. The operative findings were consistent with CCP. The patient is now doing well after MVR and pericardiectomy and is currently on regular follow-up.

Conclusions

In case of any patient, who has a history of multiple past cardiac surgeries and refractory heart failure like our case, constrictive pericarditis should be considered as a potential cause of heart failure even in a patient of pre-existing structural heart disease like mitral stenosis.

Streszczenie

Zaciskanie osierdzia jest rzadkim, lecz dobrze udokumentowanym powikłaniem zabiegów kardiochirurgicznych. Opisano wystąpienie tego powikłania po pomostowaniu aortalno wieńcowym (*coronary artery bypass grafting*, CABG), zabiegach korekcyjnych u osób z wadami wrodzonymi serca i bardzo rzadko po komisurotomii mitralnej metodą zamkniętą. W niniejszej pracy przedstawiono przypadek przewlekłego zaciskającego zapalenia osierdzia po zabiegu komisurotomii metodą zamkniętą imitującego restenozę zastawki mitralnej z niewydolnością serca oporną na leczenie.

Słowa kluczowe: zaciskające zapalenie osierdzia, restenoza zastawki mitralnej, stan po zabiegu kardiochirurgicznym, niewydolność serca oporna na leczenie

Folia Cardiologica 2018; 13, 4: 342–349

References

1. Gaudino M, Anselmi A, Pavone N, et al. Constrictive pericarditis after cardiac surgery. *Ann Thorac Surg.* 2013; 95(2): 731–736, doi: 10.1016/j.athoracsur.2012.08.059, indexed in Pubmed: 23266135.
2. Kendall ME, Rhodes GR, Wolfe W. Cardiac constriction following aorta-to-coronary bypass surgery. *J Thorac Cardiovasc Surg.* 1972; 64(1): 142–153, indexed in Pubmed: 4538270.
3. Kundu A, Yadava OmP, Prakash A. Constrictive pericarditis following coronary artery bypass grafting. *Indian Heart J.* 2013; 65(2): 198–200, doi: 10.1016/j.ihj.2013.02.004, indexed in Pubmed: 23647902.
4. Huque A, Khan O, Aftabuddin Md, et al. Mitral Valve Replacement After 10 Years of Closed Mitral Commissurotomy: A Case Report. *Medicine Today.* 2015; 26(2): 111, doi: 10.3329/medtoday.v26i2.24233.