

Successful percutaneous coronary intervention in aorto-ostial lesions with chronic total occlusion of right coronary artery using Szabo technique

Zakończona powodzeniem przezskórna interwencja wieńcowa z zastosowaniem techniki Szabo w przypadku zmian aortalno-ostialnych z przewlekłym całkowitym zamknięciem prawej tętnicy wieńcowej

Santosh Kumar Sinha¹, Mukesh Jitendra Jha², Vikas Mishra², Mahmadula Razi¹, Anupam Mahrotra¹, Nasar Abdali², Vikas Chaturvedi², Lokendra Rekwai², Anupam Kumar Singh²

¹Faculty, Department of Cardiology LPS Institute of Cardiology, G.S.V.M. Medical College, Kanpur, Uttar Pradesh, India

²Senior Registrar, Department of Cardiology LPS Institute of Cardiology, G.S.V.M. Medical College, Kanpur, Uttar Pradesh, India

Abstract

Percutaneous coronary intervention (PCI) in aorto-ostial lesions with chronic total occlusion is one of the most challenging scenarios, because geographic miss may lead to a higher rate of immediate and late adverse events when comparing with non-ostial lesions. Here we report a case, where aorto-ostial chronic total occlusion of right coronary artery in a 39-year-old male was successfully recanalised and perfectly stented using the Szabo technique.

Key words: aorto-ostial lesion, chronic total occlusion, percutaneous coronary intervention, Szabo technique

Folia Cardiologica 2018; 13, 4: 342–346

Introduction

Coronary ostial lesions are described as stenosis located within 3 mm of its origin, which is different from the lesion located elsewhere due to the peculiar distribution of the muscle layer of the vessel in the aorto-ostial regions and ostia of major coronary vessels [1]. They have predisposition for both immediate and delayed increased elastic recoil after balloon dilation, which may enlarge the chances of procedural failure and coronary restenosis compared with non-ostial lesions [1]. Stents are effective in neutralising the elastic recoil of vessel, but percutaneous coronary intervention (PCI) on aorto-ostial lesions is technically a different ball game, because it requires precise stent placement in ostium to avoid any geographic miss [2]. In

order to circumvent such problem, the Szabo technique has been proposed and used. This technique consists of side branch wiring through most proximal stent strut as well as main branch wiring through stent lumen. The side branch wire or anchor wire prevents stent advancement beyond ostial segment and makes possible the accurate stent implantation in ostium [3].

Case report

A 39-year-old male presented with exertional angina, Canadian Cardiovascular Society (CCS) class III, despite guideline-directed medical treatment. His treadmill test was strongly positive for reversible ischaemia. His past history included inferior wall myocardial infarction one

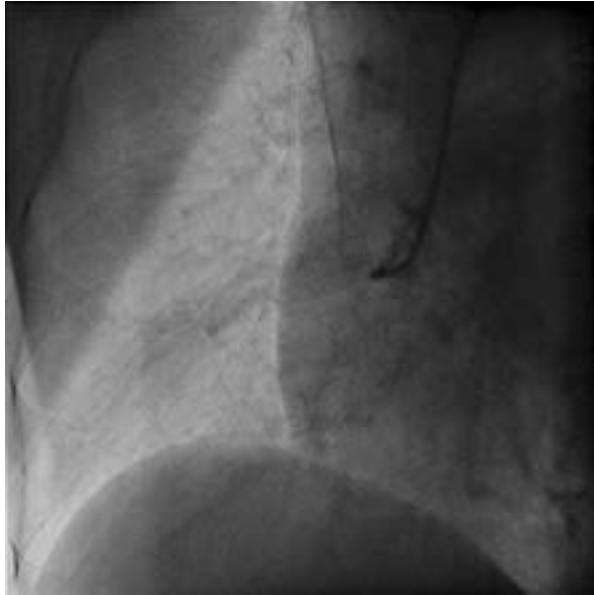

Figure 1. Right coronary artery (RCA) showed aorto-ostial chronic total occlusion

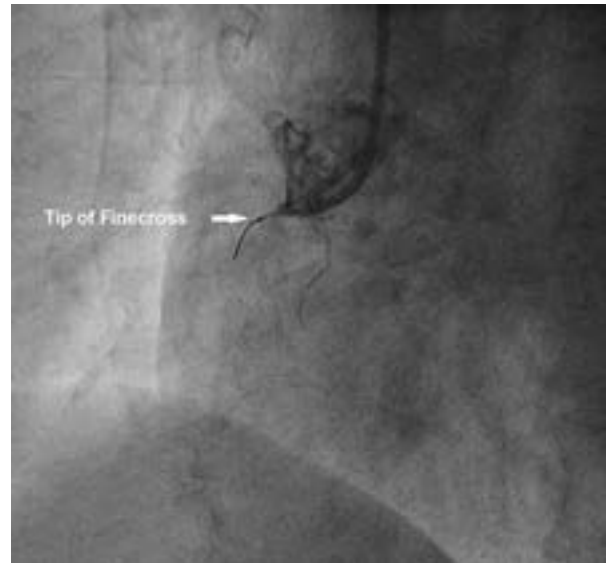


Figure 2. RCA was cannulated with 6 F Judkins right catheter. CTO being probed with Fielder FC wire over finecross microcatheter (white arrow)

year back, hypertension and diabetes for past three years. His physical examinations and biochemistry were all unremarkable. Electrocardiogram revealed q-wave in II, III, and aVF. Echocardiography revealed mild hypokinesia in right coronary artery territory with ejection fraction of 48%. Coronary angiogram was performed through transfemoral route after proper consent and revealed normal left main, left anterior descending artery (LAD) and left circumflex artery. Right coronary artery (RCA) showed chronic total occlusion from ostia with Grade II Grantham collaterals from LAD (Figure 1). Percutaneous coronary intervention through antegrade approach was planned. A total of 6,000 U of unfractionated heparin was further administered. RCA was cannulated with 6 F Judkins right (JR) catheter (Figure 2). We probed the micro channel with help of Fielder FC (Asahi, Japan) wire over finecross microcatheter (Terumo, Japan) (Figure 2). Once the proximal cap was penetrated, it was parked distally. We were unable to move the finecross catheter beyond the proximal cap; therefore finecross microcatheter was removed and predilated with 1 x 8 mm sapphire balloon (OrbusNeich, China). Once the passage was visible, we exchanged the fielder FC wire with runthrough NS 0.014", 190 cm guidewires (Terumo, Japan) (Figure 3) and sequential predilatation performed with 2 x 10, 2.5 x 10 and 3 x 10 mm sapphire balloon (OrbusNeich, China). Considering the ostial lesion, we planned the Szabo technique for stenting of RCA. Another runthrough 0.014", 190 cm guidewire was parked in aortic sinus, which acted as anchor wire (Figure 4). The 3.5 x 38 mm Xience Prime stent (Everolimus drug eluting stent, Abbott, USA) was mounted over the workhorse wire while proximal end of

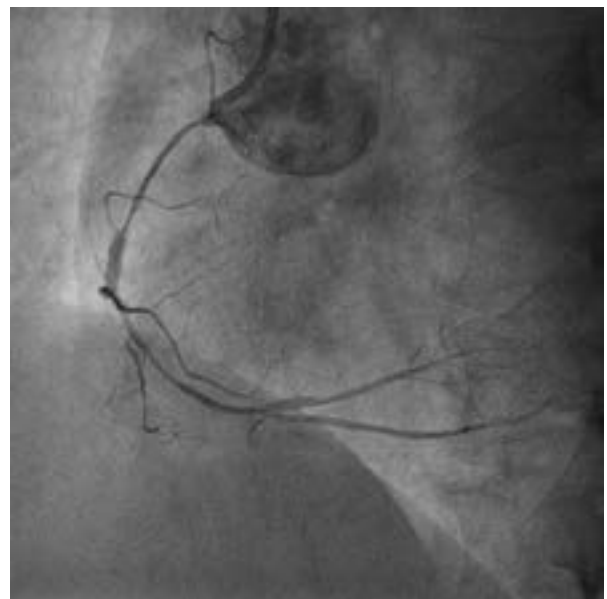

Figure 3. Fielder FC wire being exchanged with Runthrough NS guidewire

the anchor wire was crossed through the most proximal strut of the stent (Figures 5, 6). The stent was advanced carefully to avoid any tangling of the wires. Once properly positioned across the lesion, it was deployed at 12 atm pressure (Figure 7). When the balloon was deflated, the anchor wire was pulled out. The balloon was pulled little beyond the stent and inflated up to 15 atm pressure to achieve ostial flaring of the stent (Figure 8). It was further

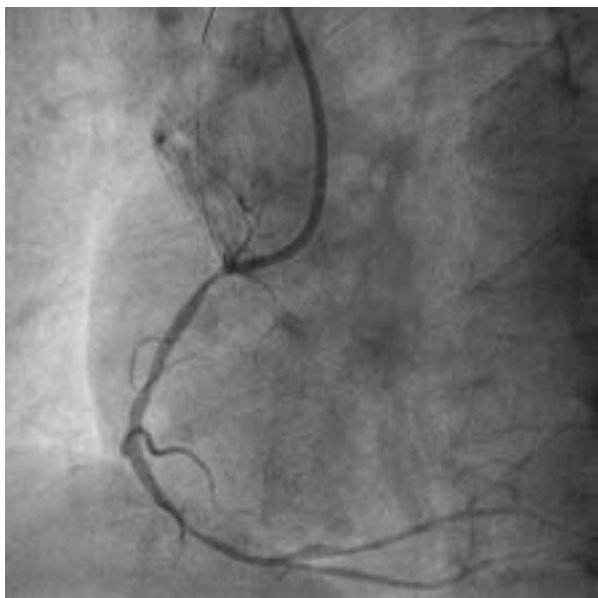

Figure 4. Another runthrough guidewire being parked in aortic sinus, which acted as anchor wire

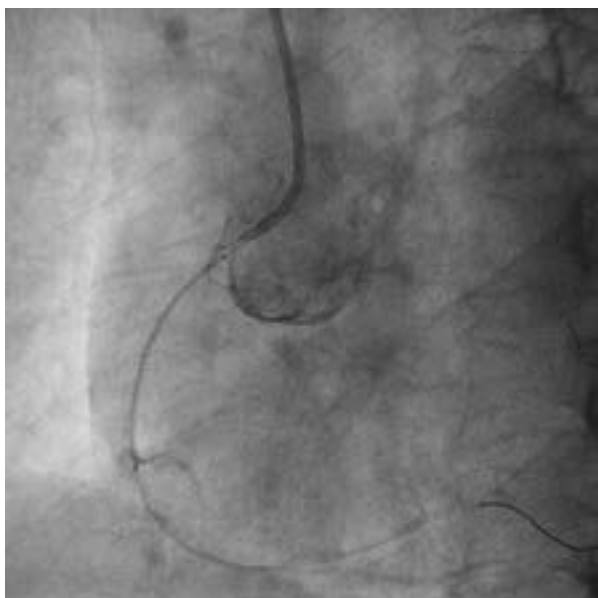

Figure 5. Stent being positioned after mounting over the workhorse wire, while proximal end of the anchor wire was crossed through the most proximal strut of the stent

post dilated with 3.5 x 10 Minitrak non-compliant balloon (Abott, USA) up to 20 atm pressure achieving TIMI 3 flow (Figure 9). The patient was discharged on the third day with aspirin – 150 mg/day, prasugrel – 10 mg/day, atorvastatin – 80 mg/day, metoprolol – 100 mg/day and ramipril – 2.5 mg/day. The patient is doing fine since then with regular follow-ups at our institute.

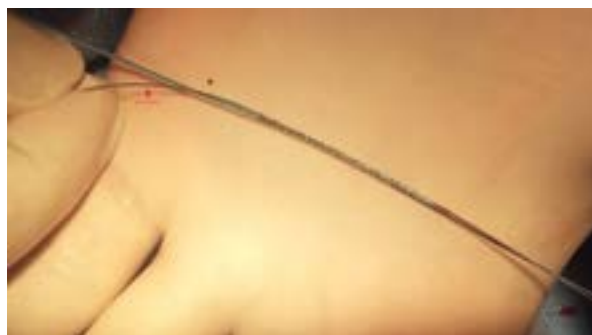

Figure 6. Anchor wire passing through most proximal strut of the stent demonstrating the Szabo technique

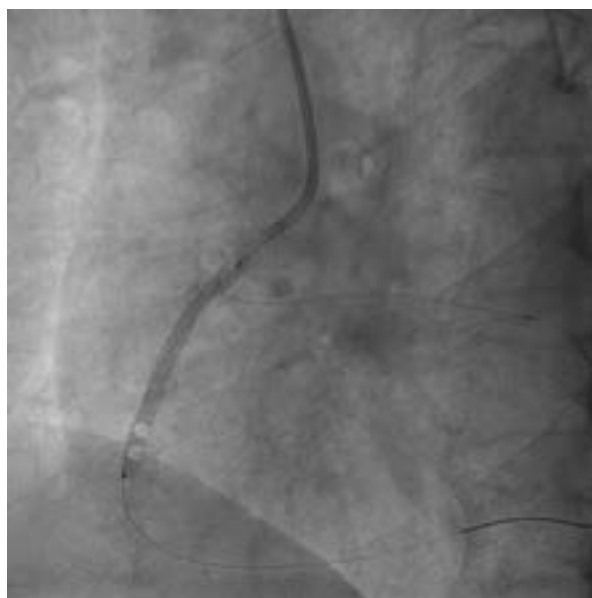

Figure 7. Stent being deployed at 12 atm and anchor wire still holding the proximal end of the stent preventing its distal migration

Discussion

Even with drug-eluting stents, the incidence of adverse cardiac events at twelve months is higher in patients with ostial lesions than in patients with non-ostial lesions [4–6]. In 2005, Szabo et al. [3] proposed a technique for the optimal placement of a stent in ostial lesions and evaluated the in-hospital results of this technique, its success, and possible complications.

The difficulties of the accurate stent placement in ostial lesions are related to a lack of proper visualisation of the lesion, the complex geometry with varying angles between the main and side branches, and varied plaque distribution (Medina 001 or 010) [5]. Although several techniques have been proposed to treat ostial lesions, yet the best strategy remains controversial. The ideal

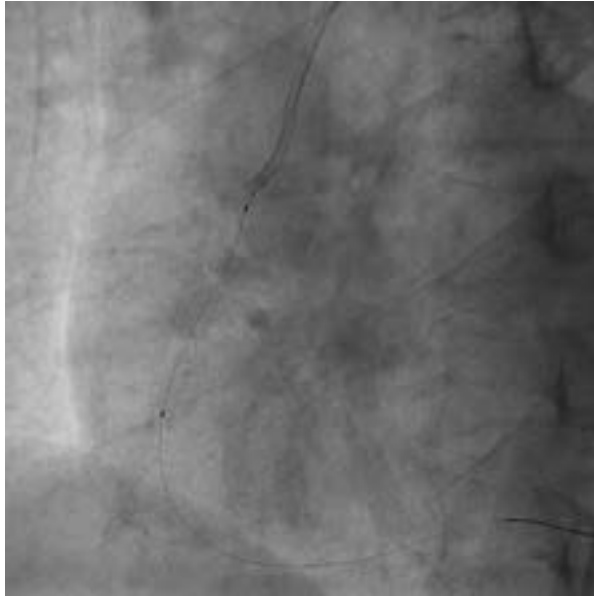

Figure 8. The balloon was pulled little beyond the stent and inflated up to 15 atm pressure to achieve ostial flaring of the stent after removing the anchor wire

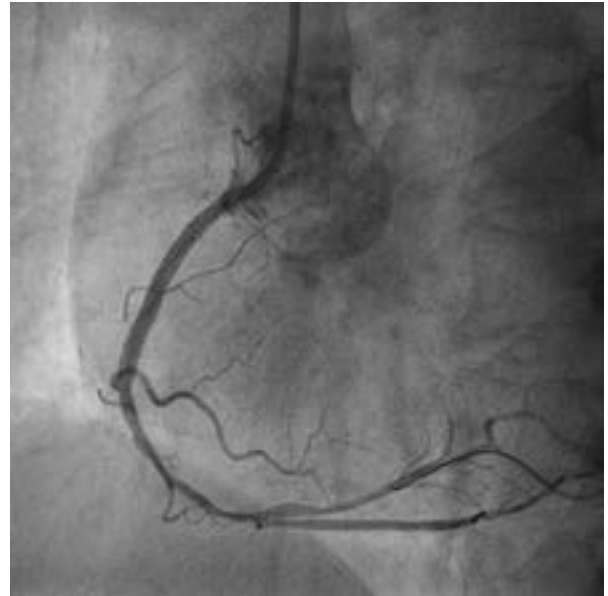

Figure 9. RCA after post dilatation by non-compliant balloon at higher pressure achieving TIMI 3 flow

technique would be the one, which will ensure complete coverage of the ostium with precise stent positioning and implantation. Gutierrez-Chico et al. [6] in their series of 156 patients with ostial lesions in main vessels (Medina 001 or 010) compared the results between the Szabo technique and conventional treatment guided by angiography and observed a distinct advantage with the Szabo technique, with lower rates of stent malposition (6.4% vs. 41%; $P < 0.0001$), stent protrusion in the side branch/ /aorta (6.4% vs. 34.6%, $P < 0.0003$) and incomplete stent coverage of the plaque (0% vs. 7.7%).

However, the potential problems with the Szabo technique are asymmetric stent deformation, stent protrusion

into the main branch, and sometimes, the risk of displacement [5]. Few limitations of this technique are heavily calcified lesions, excessive tortuosity, and failure in pre-dilatation of ostial lesions. In the present case, the Szabo technique allowed the successful treatment of ostial lesions by properly positioning the stent. By carefully following the technique guidelines, the difficulties in performing the technique and the possible complications can be minimised.

Conflict of interest

None

Streszczenie

Przeżytkowa interwencja wieńcowa (PCI, *percutaneous coronary intervention*) w przypadku zmian aortalno-ostialnych z przewlekłym całkowitym zamknięciem tętnicy jest jednym z najtrudniejszych zabiegów, ponieważ niewłaściwe umiejscowienie stentu (ang. *geographic miss*) wiąże się z częstszym występowaniem zdarzeń niepożądanych w obserwacji średnio- i długoterminowej niż w zabiegach dotyczących zmian pozaostialnych. W artykule opisano przypadek 39-letniego mężczyzny z przewlekłym całkowitym zamknięciem prawej tętnicy wieńcowej, u którego skutecznie udrożniono tętnicę i umieszczono stent w prawidłowej lokalizacji, stosując technikę Szabo.

Słowa kluczowe: zmiana aortalno-ostialna, przewlekła całkowita okluzja, przeżytkowa interwencja wieńcowa, technika Szabo

Folia Cardiologica 2018; 13, 4: 342–346

References

1. Jokhi P, Curzen N. Percutaneous coronary intervention of ostial lesions. *EuroIntervention*. 2009; 5(4): 511–514, indexed in Pubmed: 19755342.
2. Dishmon DA, Elhaddi A, Packard K, et al. High incidence of inaccurate stent placement in the treatment of coronary aorto-ostial disease. *J Invasive Cardiol*. 2011; 23(8): 322–326, indexed in Pubmed: 21828393.
3. Szabo S, Abramowitz B, Vaitkus PT. New technique for aorto-ostial stent placement. *Am J Cardiol*. 2005; 96: 212H.
4. Freeman M, Clark DJ, Andrianopoulos N, et al. Melbourne Interventional Group. Outcomes after percutaneous coronary intervention of ostial lesions in the era of drug-eluting stents. *Catheter Cardiovasc Interv*. 2009; 73(6): 763–768, doi: 10.1002/ccd.21941, indexed in Pubmed: 19309731.
5. Vaquerizo B, Serra A, Ormiston J, et al. Bench top evaluation and clinical experience with the Szabo technique: new questions for a complex lesion. *Catheter Cardiovasc Interv*. 2012; 79(3): 378–389, doi: 10.1002/ccd.23087, indexed in Pubmed: 21805569.
6. Gutiérrez-Chico JL, Villanueva-Benito I, Villanueva-Montoto L, et al. Szabo technique versus conventional angiographic placement in bifurcations 010-001 of Medina and in aorto-ostial stenting: angiographic and procedural results. *EuroIntervention*. 2010; 5(7): 801–808, indexed in Pubmed: 20142194.