

Spontaneous coronary artery dissection: not all acute coronary syndromes are the same

Spontaniczna dyssekcja tętnicy wieńcowej
— nie wszystkie ostre zespoły wieńcowe są takie same*

Iwona Gorczyca¹, Michał Bączek^{1,2}, Anna Kot¹,
Anna Michalska², Beata Wożakowska-Kapłon^{1,2}

¹1st Clinic of Cardiology and Electrotherapy, Świętokrzyskie Centre of Cardiology, Kielce, Poland

²Faculty of Medicine and Health Sciences, Jan Kochanowski University, Kielce, Poland

Abstract

A 54-year-old female patient with history of hypertension and smoking has been described. After the infection of the upper respiratory tract, she manifested acute coronary syndrome. Coronary angiography revealed spontaneous artery dissection in the middle part of the left anterior descending artery with a 40–50% blockage. After the risk stratification, strategies for conservative treatment were adopted.

Key words: spontaneous coronary artery dissection, acute coronary syndrome, conservative treatment

Folia Cardiologica 2018; 13, 3: 256–257

Spontaneous coronary artery dissection (SCAD) is an infrequent cause of acute coronary syndrome. According to the aetiology, SCAD can be divided into atherosclerotic and non-atherosclerotic. Non-atherosclerotic reasons for SCAD include congenital connective tissue diseases, dysplasia, vasculopathy, inflammation, and less commonly spasm of a coronary artery caused by excessive physical activity or cocaine use [1]. Coronary artery dissection is more frequent in young females with no risk factors for cardiovascular diseases [2].

A 54-year-old woman, during an upper respiratory tract infection, with a history of smoking and hypertension, was admitted to the Cardiology Department with symptoms of an acute coronary syndrome. Prehospital 12-lead ECG revealed ST-segment elevation in leads

from V1 to V3. The changes were reversed in the next ECG presented at the clinic. Laboratory findings included dynamic elevation of cardiac troponin T concentration up to 629.6 ng/L (0.0–3.0), creatine kinase (CK) 648 U/L (45–300), MB isoenzyme (CK-MB) 59 U/L (0–39), increased concentration of inflammatory markers and low TSH level. The patient received loading dose of aspirin and P2Y₁₂ inhibitor. Echocardiography did not reveal any wall motion abnormalities with a normal left ventricular systolic function and ejection fraction of 60%. Coronary angiography demonstrated a spontaneous artery dissection in the middle part of the left anterior descending artery (LAD) with a 40–50% blockage (Figure 1). The left main, circumflex, and right coronary artery were smooth and normal. The patient was qualified for conservative

*Praca powstała w ramach projektu „Rola innowacyjnych systemów telemonitorowania w procesie wczesnej rehabilitacji kardiologicznej oraz powrocie chorego do pełnej aktywności fizycznej, psychicznej, społecznej i zawodowej”

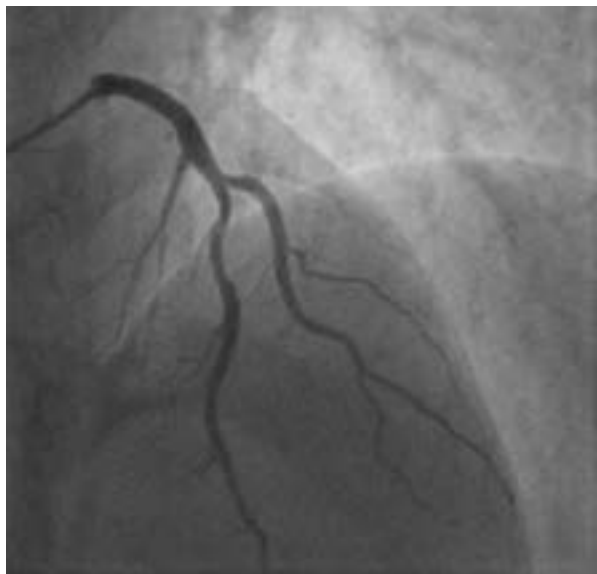


Figure 1. Dissection in the proximal segment of the left anterior descending artery

treatment. During hospitalisation, a steady improvement of the patient condition was observed with a decline of troponin and inflammatory markers concentration. On the seventh day of hospitalisation, the patient was discharged home in a stable condition. After a six month follow-up, there was no recurrence of anginal pain and our patient remained in a stable condition. In case of the presented patient, a diagnosis for fibromuscular dysplasia is indicated, for which the patient did not agree.

In the presented patient, the dissection of the coronary artery was probably caused by upper respiratory tract infection. Treatment strategy in patients with SCAD requires individualised approach and management. Stent implantation into a coronary artery in a patient with SCAD may cause progression of the dissection or lead to intramural haematoma. We decided, that conservative treatment would result in the best outcome. Location of the dissection, its severity and no haemodynamically significant stenosis in coronary arteries were in favour of the conservative strategy.

Streszczenie

Przedstawiono 54-letnią pacjentkę z nadciśnieniem tętniczym oraz nikotynizmem w wywiadzie, u której po przebytej infekcji górnych dróg oddechowych wystąpiły objawy ostrego zespołu wieńcowego. Angiografia wieńcowa ujawniła spontaniczną dyssekcję gałęzi przedniej zstępującej lewej tętnicy wieńcowej w środkowym odcinku z przewężeniem o średnicy 40–50%. Po stratyfikacji ryzyka przyjęto strategię leczenia zachowawczego.

Słowa kluczowe: spontaniczna dyssekcja tętnicy wieńcowej, ostry zespół wieńcowy, leczenie zachowawcze

Folia Cardiologica 2018; 13, 3: 256–257

Piśmiennictwo

1. Ferrari E, Tozzi P, von Segesser LK. Spontaneous coronary artery dissection in a young woman: from emergency coronary artery bypass grafting to heart transplantation. *Eur J Cardiothorac Surg.* 2005; 28(2): 349–351, doi: [10.1016/j.ejcts.2005.04.035](https://doi.org/10.1016/j.ejcts.2005.04.035), indexed in Pubmed: [15949946](https://pubmed.ncbi.nlm.nih.gov/15949946/).
2. Celik SK, Sagcan A, Altintig A, et al. Primary spontaneous coronary artery dissections in atherosclerotic patients. Report of nine cases with review of the pertinent literature. *Eur J Cardiothorac Surg.* 2001; 20(3): 573–576, indexed in Pubmed: [11509281](https://pubmed.ncbi.nlm.nih.gov/11509281/).