

The usefulness of optical coherence tomography in a patient on antiplatelet therapy and requiring surgery

Przydatność optycznej tomografii koherentnej u pacjenta stosującego terapię przeciwplatełkową wymagającego zabiegu operacyjnego

Piotr Kübler^{1,2}, Andrzej Szczepański², Wojciech Kosowski³, Michał Kosowski^{1,2},
Wojciech Zimoch^{1,2}, Krzysztof Reczuch^{1,2}

¹Department of Heart Diseases, Medical University, Wrocław, Poland

²Centre for Heart Diseases, Military Hospital, Wrocław, Poland

³Students Scientific Group of Interventional Cardiology, Department of Heart Diseases, Medical University, Wrocław, Poland

Abstract

Establishing a balance between the risk of stent thrombosis and the risk of perioperative bleeding in patients treated with dual antiplatelet therapy remains a major therapeutic challenge. We report a case of 60-year-old man after stent implantation in left main coronary artery and requiring urgent operative treatment. The result of optical coherence tomography helped us to decide about further proceeding and is an example of a very helpful application of this new imaging technique in everyday practice.

Key words: antiplatelet therapy, perioperative treatment, percutaneous coronary intervention

Folia Cardiologica 2016; 11, 5: 440–442

Introduction

Treatment of patients on dual antiplatelet therapy (DAPT), including the patients after coronary stents implantation, and who require surgical treatment remains problematic. Shortening of DAPT increases the risk of ischemic events (including stent thrombosis), while performing some surgical procedures during DAPT increases the risk of serious bleeding complications. There is an ongoing discussion on perioperative approach in patients with implanted drug-eluting stents [1].

Case report

60-year-old man was admitted for cardiac evaluation prior to urological surgery. The patient was suspected of having bladder tumor, requiring urgent diagnostics and operative

treatment. Ten months earlier the patient underwent an anterior myocardial infarction complicated by cardiogenic shock. He was treated by complex percutaneous coronary intervention (PCI) with implantation of 3 sirolimus-eluting stents to occluded left main coronary artery (LMCA), left anterior descending artery (LAD) and circumflex branch (Cx) with T-stenting technique. Intravascular ultrasound (IVUS) revealed suboptimal result with incomplete stents apposition (with creation of free stent struts inside the vessel lumen – „neocarina”), even after high-pressure postdilations (Figure 1). However, the patient was stable after the procedure, with no chest pain or ischemia during everyday activities. In echocardiography ejection fraction was 35%, without valve abnormalities. DAPT with acetylsalicylic acid and ticagrelor was prescribed for at least 12 months.

Currently we decided to assess the long-term effect of stenting using novel coronary imaging technique – optical

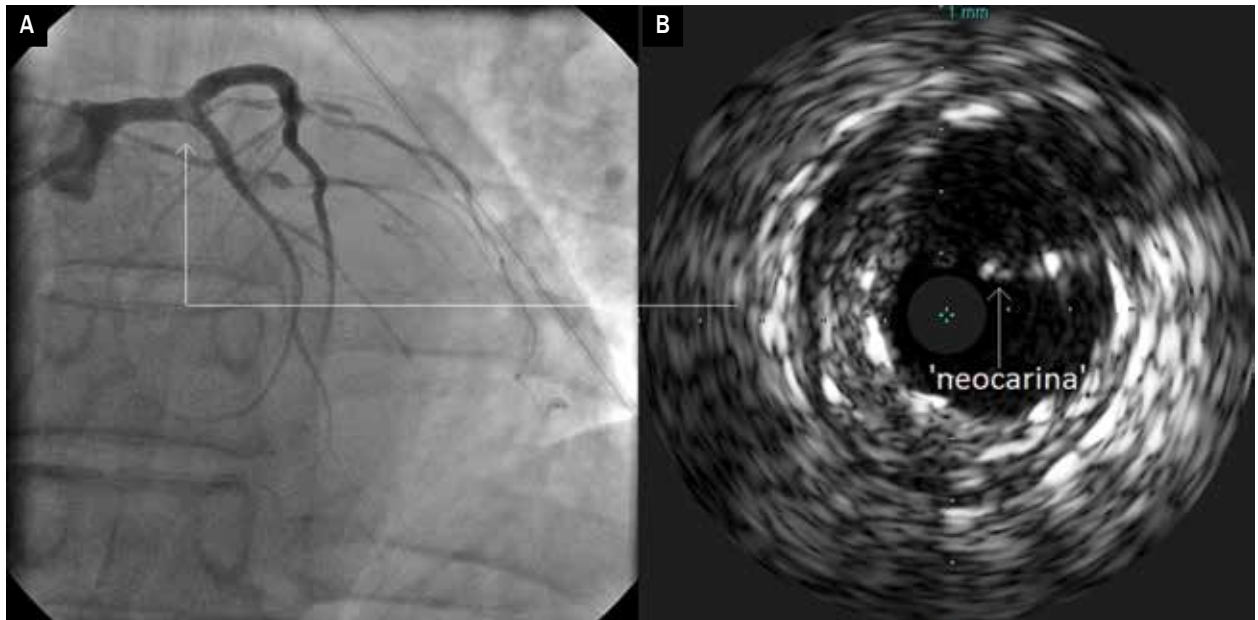


Figure 1A, B. Coronary angiography showing some haziness in distal left main after stents implantation (A) and intravascular ultrasound showing incomplete stents apposition with “neocarina” in this area (B)

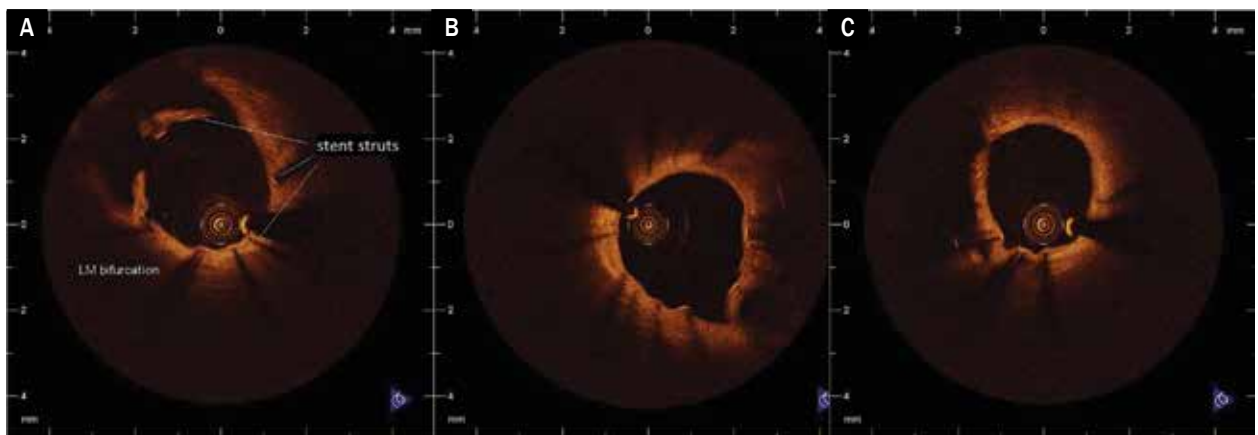


Figure 2A–C. Optical coherence tomography showing endothelium coverage of the vast majority of stents struts in left main bifurcation (A) and satisfactory apposition and endothelium coverage of stent struts in left anterior descending and circumflex artery (B, C)

coherence tomography (OCT), utilizing near-infrared light to visualize the lumen of coronary arteries. Potential incomplete endothelium coverage of the stents increases the risk of thrombosis after antiplatelet drug withdrawal before urological procedure. Whereas, surgery on DAPT increases the risk of fatal hemorrhage. OCT study showed satisfactory apposition and endothelium coverage of the vast majority of stent struts in LMCA, LAD and Cx (Figure 2). This image helped to decide on the withdrawal of one antiplatelet drug – ticagrelor. Urological procedure and following treatment proceeded without complications.

Discussion

Establishing a balance between the risk of stent thrombosis and the risk of perioperative bleeding in patients treated with DAPT remains a major therapeutic challenge. DAPT is recommended for 12 months after the onset of myocardial infarction. Shortening this therapy is associated with increased risk of ischemic events including stent thrombosis, while it is proven that new generation of drug-eluting stents is significantly less thrombogenic and shorter DAPT is acceptable in selected patients [2]. In

our case, because of suboptimal effect of initial PCI in the area of LMCA, the risk of stent thrombosis was particularly high and potentially fatal. On the other hand, urological surgery including bladder interventions is associated with high bleeding risk, especially on DAPT [3]. Therefore, the decision in such patients has to be individual, based on the scope of the coronary intervention performed and the type of the surgery. We additionally decided to use one of the modern imaging techniques – OCT, to assess the extent of endothelium coverage of stent struts [4]. Uncovered struts are strong predictors of stent thrombosis [5]. The result of OCT helped us to decide about ticagrelor withdrawal and further proceeding. This is an example of a very helpful application of OCT in everyday practice. In selected patient the use of bridging therapy

with new short acting antiplatelet drug – cangrelor could be an option as well.

Conclusion

Establishing a balance between the risk of stent thrombosis and the risk of perioperative bleeding in patients on DAPT remains a major therapeutic challenge. The decision often has to be individual, based on the scope of the coronary intervention performed and the type of surgery. In selected cases modern imaging techniques such as OCT can be very helpful.

Conflict of interest

None declared.

Streszczenie

Ustalenie równowagi między ryzykiem zakrzepicy w stencie a ryzykiem krwawienia okołoperacyjnego u pacjentów stosujących podwójną terapię przeciwplateletową pozostaje dużym wyzwaniem terapeutycznym. Przedstawiono przypadek 60-letniego mężczyzny po przebytej implantacji stentów do głównego pnia lewej tętnicy wieńcowej, który wymagał pilnego leczenia operacyjnego. Bardzo pomocne w ustaleniu dalszego postępowania okazało się zastosowanie nowoczesnej techniki obrazowania wewnątrzwieńcowego – optycznej tomografii koherentnej.

Słowa kluczowe: terapia przeciwplateletowa, postępowanie okołoperacyjne, przezskórna interwencja wieńcowa

Folia Cardiologica 2016; 11, 5: 440–442

References

1. Rajwa P., Rempega G., Suliga K., Szygula-Jurkiewicz B. Perioperative procedures in patients with implantable drug-eluting stents. *Folia Cardiol.* 2015; 10: 336–341.
2. Park S.J., Kang S.M., Park D.W. Dual antiplatelet therapy after drug-eluting stents: defining the proper duration. *Coronary Artery Dis.* 2014; 25: 83–89.
3. Rossini R., Bramucci E., Castiglioni B. et al. Coronary stenting and surgery: perioperative management of antiplatelet therapy in patients undergoing surgery after coronary stent implantation. *G Ital. Cardiol.* 2012; 13: 528–551.
4. Roleder T., Jąkała J., Kałuża G. et al. The basics of intravascular optical coherence tomography. *Post. Kardiol. Interw.* 2015; 11: 74–83.
5. Finn A.V., Joner M., Nakazawa G. et al. Pathological correlates of late drug-eluting stent thrombosis: struts coverage as a marker endothelialization. *Circulation* 2007; 115: 2435–2441.