

# Pulmonary embolism – review of diagnostic imaging methods

## Zatorowość płucna – przegląd metod diagnostyki obrazowej

Anna Skornicz<sup>1</sup>, Marcin Madziarski<sup>2</sup>, Aleksandra Gajek<sup>3</sup>, Katarzyna Madziarska<sup>4</sup>

<sup>1</sup>Department of Medical Radiology and Diagnostic Imaging, 4<sup>th</sup> Military Clinical Hospital, Wrocław, Poland

<sup>2</sup>University Teaching Hospital, Wrocław, Poland

<sup>3</sup>Students' Scientific Society, Medical University, Wrocław, Poland

<sup>4</sup>Department and Clinic of Nephrology and Transplant Medicine, Medical University, Wrocław, Poland

Artykuł jest tłumaczeniem pracy: Skornicz A et al. Zatorowość płucna – przegląd metod diagnostyki obrazowej.

Folia Cardiol. 2018; 13 (6): 517–525. DOI: 10.5603/FC.a2018.0118. Należy cytować wersję pierwotną

### Abstract

A pulmonary embolism (PE) is one of the most common life-threatening cardiological disorders. It is the mechanical blockage of a lung artery by a substance, usually a thrombus, that has moved through the bloodstream. The suspicion of PE may be based on specific, yet non-characteristic subjective and objective symptoms, including laboratory investigations and the medical history of the patient. For a clinical assessment of the likelihood of PE, two point scales are recommended – the Wells Scale and the modified Geneva Score. Imaging tests that can confirm or exclude PE include both methods associated with radiation exposure, such as chest radiogram, lung scintigraphy, single-photon emission computed tomography, computed tomographic pulmonary angiography or pulmonary angiography, as well as methods without radiation exposure such as ultrasonography (where venous compression ultrasound and echocardiography are promising, but are not yet ready for widespread use) and magnetic resonance angiography. The choice of imaging method depends on the availability of specific medical equipment and the clinical condition of the patient.

Key words: pulmonary embolism, diagnostics, review

Folia Cardiologica 2018; 13, 6: 526–533

### Introduction

Pulmonary embolism (PE) is defined as mechanical closure of a part of the vascular bed. The most common cause of pulmonary artery embolism is thrombus, rarely an embolus (e.g. elements of bone marrow, fat, cancer cells, air, and amniotic fluid). Pulmonary embolism and deep vein thrombosis Venous thromboembolism (VTE) refers to both pulmonary embolism and deep vein thrombosis (DVT). The source of thromboembolic material are usually deep veins of the thigh and small pelvis, less often veins of the lower leg, liver veins and veins of upper limbs (e.g. in the case of central catheters maintained to

long). Thrombi may also originate from the right atrium and right ventricle [1]. PE is one of the most common cardiac states directly life threatening [1]. It can be fatal in its acute phase or lead to chronic disease and disability. PE is one of the main causes of mortality, morbidity and hospitalizations in Europe [2].

### Clinical picture

Based on etiology, PE risk factors are divided into primary or secondary. The most important risk factors are: injury, large joint surgery (hip, knee), large surgery (3–7 days after surgery), large injuries, and spinal cord injuries. Moderate

risk factors include: history of DVT, arthroscopy of the knee joint, central venous catheter in lying patients, cancer and its treatment (mainly chemotherapy), thrombophilia, paresis, heart failure, pregnancy and puerperium, hormone replacement therapy, oral contraception. Low risk factors are: immobilization for more than 3 days, long journey, age > 40 years, obesity, varicose veins. The coexistence of certain clinical conditions with advanced age or pregnancy results in a multiplication of risk and a higher risk of PE [3]. Pulmonary embolism may also occur in the absence of any known risk factor [2].

Symptoms of PE are not characteristic, but most patients experience dyspnea, chest pain, accelerated respiration rate. Less frequent symptoms include paroxysmal cough, weakness, fainting, haemoptysis, tachycardia, auscultatory changes over the lungs, fever, symptoms of lower limb venous thrombosis [3]. It should be remembered that PE may be completely asymptomatic and may be detected accidentally during diagnostic tests associated with another disease or during autopsy [2]. The variety of occurrence and severity of symptoms often requires differentiation with acute coronary syndrome, pneumonia, infection or neuralgia. Therefore, it is important to determine the clinical probability of pulmonary embolism based on the analysis of risk factors, complaints reported by patients, symptoms and initial examinations, which target further management [3].

Laboratory tests used in the diagnostics of PE include arterial blood gasometry, D-dimer concentration, cardiac troponins and natriuretic peptides. Determination of D-dimer concentration is of high exclusion value, but it is not specific and positive results may occur in other diseases (sepsis, cancer, connective tissue diseases, heart failure, kidney failure, heart attack with shock, DIC syndrome, severe liver damage, severe trauma, advanced age, pregnancy). On the other hand, elevated values of cardiac markers are predictive indicators of high mortality, right ventricular overload and show significant prognostic value [3].

In order to differentiate with other cardiovascular diseases, echocardiography is performed, preceded by electrocardiography (ECG).

In the assessment of clinical probability of PE, two-point scales are currently used - the Wells Scale and the modified Geneva Scale (Table 1) [4, 5], which enable diagnostics and interpretation of additional test results [3].

The next step after clinical suspicion is imaging diagnostics. Imaging methods used in the diagnosis of PE include: chest radiography, angiotomography of pulmonary arteries, magnetic resonance angiography, V/P scan, SPECT scan, pulmonary arteriography, deep vein ultrasonography of lower extremities and echocardiography.

**Table 1.** Assessment of clinical probability of pulmonary embolism (PE) according to Wells Scale (source [4]) and modified Geneva Scale (source [5])

Wells Scale [4]	
Variable	Number of points
Predisposing factors:	
• DVT or PE in the past	1.5
• a recent surgical procedure or immobilization	1.5
• cancer	1
Symptoms:	
• hemoptysis	1
Signs:	
• heart rate > 100/min	1.5
• signs of DVT	3
Clinical evaluation:	
• other diagnosis less probable than PE	3
Interpretation	
<b>Clinical probability (3 levels):</b>	<b>Total amount of points</b>
• low	0–1
• moderate	2–6
• high	≥ 7
<b>Clinical probability (2 levels):</b>	
• low probability of PE	0–4
• possibility of PE	> 4
Modified Geneva Scale [5]	
Variable	Amount of points
Predisposing factors:	
• age > 65-years-old	1
• DVT or PE in the past	3
• surgery or fracture during the last month	2
• cancer (not cured)	2
Symptoms:	
• unilateral lower limb pain	3
• hemoptysis	2
Signs:	
• heart rate 75–94/min	3
• heart rate ≥ 95/min	5
• pain when pressure applied to deep veins of the lower limb and unilateral swelling	4
Interpretation	
<b>Clinical probability (3 levels):</b>	<b>Total amount of points</b>
• low	0–3
• moderate	4–10
• high	≥ 11

DVT – deep vein thrombosis

## Chest X-ray

Thoracic radiogram is the basic diagnostic method of respiratory system changes, however, it does not allow for differentiation of PE. With the help of this examination it is possible to exclude diseases in which symptoms are similar to those of PE, such as pneumothorax, fracture of ribs, pneumonia, pleural disease, cancer of the lungs [1]. Patients with PE have symptoms of pulmonary hypertension on the X-ray of the chest, *i.e.* enlarged heart with visible right ventricular enlargement [6]. The PA radiogram view shows a leftward shift of the outlining of the heart, with the rounding and elevation of the apex over the diaphragm, while the profile radiogram shows an increased adhesion of the figure of the heart to the sternum [7]; dilatation of pulmonary artery and proximal segments of pulmonary arteries or contraction of peripheral pulmonary arteries during the leak reversal phase (Eisenmenger reaction). In the pulmonary parenchyma, lung infarction can be seen as a shade of the pulmonary parenchyma similar in shape to a triangle with the base pointing to the pleura (Hampton's symptom) [6]. On the infarction side there is often a small pleural exudate, diaphragm lift, atelectasis, and multiple unilateral or bilateral infarcts. These foci are reabsorbed within a few weeks or they break down and form an abscess.

In about half of the cases of pulmonary embolism, infarction does not occur due to the formation of collateral circulation through the bronchial arteries [7]. The area of local lung ischemia in the form of increased transparency and reduced number of vessels (Westermarck symptom) is very rarely visible. It should be stressed that a normal chest X-ray image of the lungs and heart does not exclude pulmonary embolism [6].

## Ventilation/perfusion scan

Lung perfusion scintigraphy is a functional radioisotope examination. The most commonly used radiopharmaceuticals are microspheres or macro-aggregates of human blood albumin (MAA) which are 15–50  $\mu\text{m}$  in diameter and are administered intravenously, labelled with the isomer of technetium isotope  $^{99\text{m}}\text{Tc}$ . They are distributed in a similar way to erythrocytes; due to their size, they are retained in precapillary and capillary vessels, which makes it possible to evaluate perfusion [6].

Immediately after administration of the marker, acquisition is performed in anterior, posterior, lateral right and left projections, as well as right and left diagonal projections [6]. A scintigraphy camera is used to record data in the form of a projection of the distribution of radioactivity in the tested body. Such a set of projections forming a direct image is called planar imaging. The scintigraphic image is analogous

to a flat X-ray image, with the difference that the observed radiation comes from the inside of the patient's body. The disadvantage of planar imaging is the overlapping of radioactivity from different structures located on one line [8]. Perfusion scintigraphy is a sensitive but non-specific method. Pulmonary circulation disorders visible in scintigraphy may also result from other disorders leading to limited ventilation of the selected lung area due to segmental airway obstruction, pulmonary parenchymal diseases, cardiovascular malformations or heart disease [6]. The basic criterion for the diagnosis of PE based on perfusion scintigraphy is the presence of losses in the collection of the marker including with the location of anatomical lung segments and a normal chest X-ray image [6]. Perfusion scans are combined with ventilation testing, which uses various markers such as xenon ( $^{133}\text{Xe}$ ),  $^{99\text{m}}\text{Tc}$  marked aerosols or  $^{99\text{m}}\text{Tc}$  marked carbon microparticles (Technegas). Additional ventilation scans are performed to increase the specificity of the study: in acute PE, ventilation is expected to be normal in areas of hypoperfusion [ventilation-perfusion incompatibility (mismatch)]. Performing only a perfusion test is acceptable in patients with normal chest X-ray results; in this situation, any loss of perfusion will be considered a mismatch [2].

Lung scintigraphy results are often classified according to the criteria established in the PIOPED (Prospective Investigation of Pulmonary Embolism Diagnosis) study. A three-stage classification is preferred: normal scan (excluding pulmonary embolism), high probability scan (considered diagnostic for pulmonary embolism in most patients) and non-diagnostic scan [2]. In order to reduce the probability of non-diagnostic results, modified PIOPED – PIOPED II and PISAPED (Prospective Investigative Study of Acute Pulmonary Embolism Diagnosis) [9] (Table 2) criteria are applied.

Results indicating an indirect probability of pulmonary embolism cannot be the basis for a diagnostic decision; the diagnosis should be verified by other available imaging studies. The reasons for undiagnostic images include technical limitations related to single-plane mapping of the distribution of radioactivity in lung projection in the classic scintigraphic method [6]. According to data from the International Commission on Radiological Protection (ICRP), exposure to radiation during lung scintigraphy using  $^{99\text{m}}\text{Tc}$  labeled albumin with a radioactivity of 100 MBq reaches 1.1 mSv for adults and is significantly lower compared to the doses used in spiral computed tomography.

Since we use less contrast and lower radiation dose during scintigraphy, we use it in outpatient patients with low clinical probability and normal chest X-ray, in young patients (especially women), pregnant women, patients with history of anaphylaxis after using a contrast agent, with positive allergic history, severe renal failure, patients with myeloma and paraproteinemia [2].

**Table 2.** Modified scintigraphic criteria PLOPED II and PISAPED (source [9])

Diagnosis	Modified PLOPED II	PISAPED
Confirmation of acute PE	≥ 2 large (> 75% of the segment) segmental perfusion losses without corresponding ventilation disturbances on chest X-ray	≥ 1 wedge-shaped loss of perfusion
Exclusion of acute PE	Normal perfusion	Normal perfusion
Very low probability of acute PE	Changes that do not correspond to the lung segments: <ul style="list-style-type: none"> <li>dilation of hilum of the lung</li> <li>enlargement of the cardiac silhouette</li> <li>diaphragm lift</li> <li>atelectasis</li> <li>blurring of the costophrenic angle in the absence of perfusion losses</li> </ul> Perfusion defects smaller than the lesions visible on the chest X-ray	Minor losses of perfusion
	≤ 3 small (< 25% of the segment) segmental perfusion losses with correct chest X-ray imaging	Changes caused by: <ul style="list-style-type: none"> <li>enlargement of the cardiac silhouette</li> <li>widening of the mediastinal shadow</li> <li>diaphragm lift</li> </ul> Non wedge-shaped perfusion defects
	Overlapping ventilation and perfusion defects and interstitial shading in the middle or upper pulmonary fields on the chest X-ray	
	Perfusion defects surrounded by areas of normal lung perfusion (stripe sign)	
	Pleural reaction covering at least 1/3 of the pleura with no perfusion losses	

## Single-photon emission computed tomography (SPECT)

Recent studies indicate that SPECT imaging with or without low-dose CT may reduce the incidence of undiagnostic scans [2]. Ventilation-perfusion single photon emission computed tomography (V/P SPECT) is a study used in the field of nuclear medicine. The test method and the radiopharmaceuticals used are similar to those used V/P scan. The main difference is the way the image is registered.

The SPECT technique requires the use of a rotary gamma-camera. During the examination, the camera rotates around the long axis of the patient's body, recording successive projections, which form the basis of three-dimensional reconstruction. Appropriate projections with the use of mathematical methods make it possible, to reconstruct the three-dimensional distribution of the radiopharmaceutical in the examined body [8]. SPECT allows you to obtain scintigraphic images with much better resolution in different planes [6]. Better detection of perfusion losses at the subsegmental level was demonstrated, especially in the middle parts of the lungs [10].

According to European Association of Nuclear Medicine (EANM) guidelines, PE may be excluded in the case of a correct perfusion image consistent with the anatomical structure of the lungs, overlapping ventilation and perfusion losses, regardless of their size, shape, number and in the case of changes that do not correspond to the anatomical structure of the lungs. PE is confirmed in the case of at least one segmental or two subsegmental perfusion losses [11]. Non-specific, complex ventilation and perfusion disorders are considered undiagnostic [12].

EANM guidelines also emphasize the importance of holistic evaluation of SPECT studies, which includes information on clinical status and probability of PE, evaluation of chest X-ray, evaluation of pulmonary embolism typical changes based on a map of pulmonary segments and lesions other than PE [12]. The studies showed that SPECT has a higher sensitivity and specificity and a lower number of inconclusive results in diagnostics of PE when compared to two-dimensional imaging [10]. According to ICRP data, exposure to radiation during the V/P SPECT study using <sup>99m</sup>Tc-labelled albumin with radioactivity of 100–120 MBq

and  $^{99m}\text{Tc}$ -labelled aerosol with radioactivity of 25–30 MBq reaches 1.2–2 mSv [11].

## CT pulmonary angiogram

CT pulmonary angiogram is a basic test used in clinically stable patients with suspected PE. This is a first-line examination in patients with abnormal chest X-ray or history of cardiopulmonary disease and can be performed instead of V/P scan in all other patients [13]. Since the introduction of multidirectional CT with high spatial and time resolution and good quality of contrasting arterial vessels, CT pulmonary angiogram has become a method of choice for the assessment of pulmonary vessels in case of suspicion of PE [2].

To achieve optimal results, it is essential to choose the right time and method of administration of the contrasting agent individually. This is particularly important for patients where urgent diagnosis is needed, with reduced cardiac output and prolonged circulatory time. Determination of the individual delay time for image acquisition is based on the injection of a trial bolus or a bolus trigger [13].

A better technique is bolus triggering. It works by taking sample monitoring images with a significantly reduced radiation dose with an appropriate positioning of the table (triggering area) and defining the area of interest (ROI, region of interest) in which vascular enhancement will be measured. After reaching a sufficient level of enhancement (determined visually or by a threshold value of the radiation attenuation rate), a proper spiral acquisition begins [13].

Symptoms of acute PE are complete closure of the artery lumen or loss of filling by the contrasting blood flowing through the lumen [6]. Acute blockages are trapped either in places where the pulmonary artery bifurcate or in peripheral arteries with diameters smaller than the diameter of the thrombus. The 1st ones can occur not only in bifurcation of the pulmonary artery, but also at the segmental or subsegmental level. The level of obstruction of the vessel corresponds to the diameter of the embolism, *i.e.* the place of its origin [13]. The vessel in which the embolism is located is usually dilated [6]. In this case, mosaic perfusion with reduced saturation of the affected segment occurs [13].

If the bilateral circulation through the bronchial arteries is insufficient, pulmonary infarction may occur after just a few hours. Contrasting of the matt glass type may precede formation of a typical wedge-shaped segmental densification. Larger infarctions may contain varying amounts of air. In the unventilated part of the lung, areas suspected of infarction show reduced contrast strengthening. Cavities are often observed in septic infarctions, less frequently in uncomplicated infarctions. Sometimes infarctions are accompanied by pneumothorax [13].

Diagnostic traps in the detection of pulmonary embolism in CT angiography result from the presence of motor

artefacts, banded artefacts associated with high concentrations of the contrasting agent in vessels or catheters, partial volumetric averaging in the case of vessels diagonal to the cross-sectional plane, dilatation of the hilum of the lung, weak strengthening of pulmonary circulation vessels, presence of bronchial mucus and areas of atelectasis or pulmonary parenchyma densification in which the pulmonary arteries are constricted. The above situations may imitate the loss of filling with the contrasting agent in the vessels lumen [14].

Hurwitz and his team for the study in the protocol for the evaluation of pulmonary arteries with the 64-row apparatus determined the radiation dose of  $19.9 \pm 1.38$  mSv [15]. Due to the possibility of allergic reactions and contrast nephropathy, this method is used in patients with high clinical suspicion of PE and elevated levels of D-dimer, in whom pulmonary embolism cannot be excluded without radiological imaging [16].

## Pulmonary artery arteriography

This method has remained a reference method for decades in the diagnosis or exclusion of PE [2]. Digital subtraction angiography (DSA) is a technique used for final diagnosis of PE or DVT when less invasive methods cannot be used [14]. It requires less contrast media than conventional angiography and has excellent imaging quality of peripheral pulmonary vessels in patients who can hold their breath; it is less suitable for imaging of the main pulmonary vessels due to artifacts caused by cardiac motion [2]. In the procedure, a catheter is inserted through the right heart into the pulmonary arteries and the contrasting agent is administered selectively [14].

The diagnosis of acute PE is based on direct evidence of thrombus presence in two projections or in the form of perfusion losses or amputations of the pulmonary artery branch. Indirect symptoms of pulmonary embolism, such as slow contrast flow, regional hypoperfusion and delayed or reduced flow of venous lung blood, are not verified and are therefore not diagnostic [2]. If the presence of a thrombus is unequivocally detected, the diagnosis can be terminated. Patients who are scheduled for surgical removal of the thrombus or thrombolytic treatment are an exception, as it is necessary to determine the location of the thrombus in these patients [14].

Pulmonary arteriography is not without risk of complications. Complications can be divided into those related to the administration of a contrasting agent and secondary ones due to catheterization of the heart and pulmonary vessels. Mortality during surgery reaches 0.5% and is usually a consequence of acute right ventricular failure caused by a transient increase in pulmonary artery pressure after administration of a contrasting agent. Deaths during pulmonary angiography occur almost exclusively in

very severe patients with existing pulmonary hypertension or right ventricular dysfunction [14]. In hemodynamically unstable patients the volume of the contrast agent should be reduced, and non-selective injections should be avoided. Serious complications which did not end with death occurred in 1% and minor complications occurred in 5% of the patients [2]. Because of the relative safety of selective administration of non-ionic contrasts and the high mortality of untreated pulmonary embolism, it is believed that pulmonary artery angiography should be performed only if indications are present [14].

### MRPA, magnetic resonance angiography

MRPA seems to be a promising method of imaging due to the lack of ionizing radiation. Nephrotoxicity and allergic reactions after the use of a gadolinium contrast medium are less of a problem [16]. However, studies indicate that this technique is not yet ready for use in clinical practice due to its low sensitivity, high percentage of ambiguous tests and low availability in most emergency facilities [2]. Motion artifacts of the image and poor filling of segmental and subsegmental vessels are the main reasons for undiagnostic examinations. In addition, the study may be poorly tolerated by patients with claustrophobia,

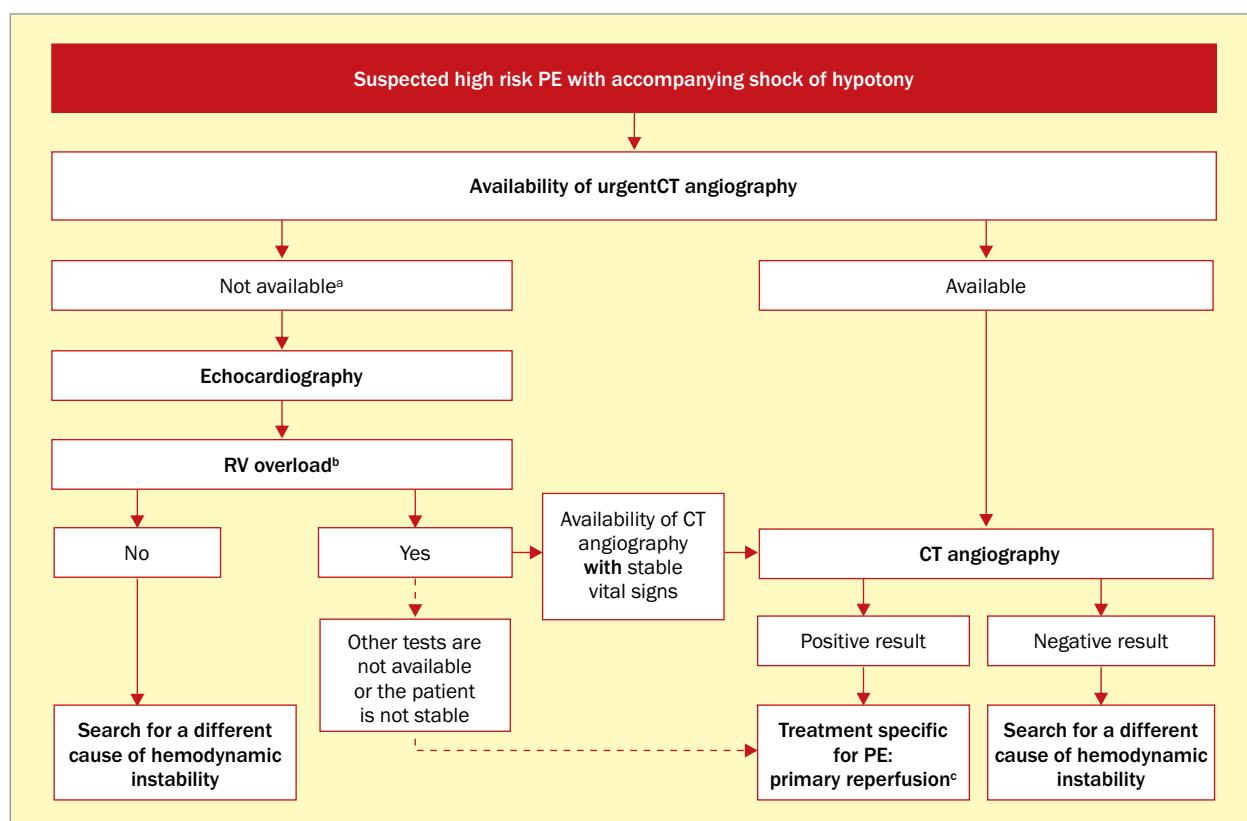
contraindicated during pregnancy and in patients with cerebral vascular clips, metal implants and cardiac pacemakers [16].

### Compression ultrasound (CUS)

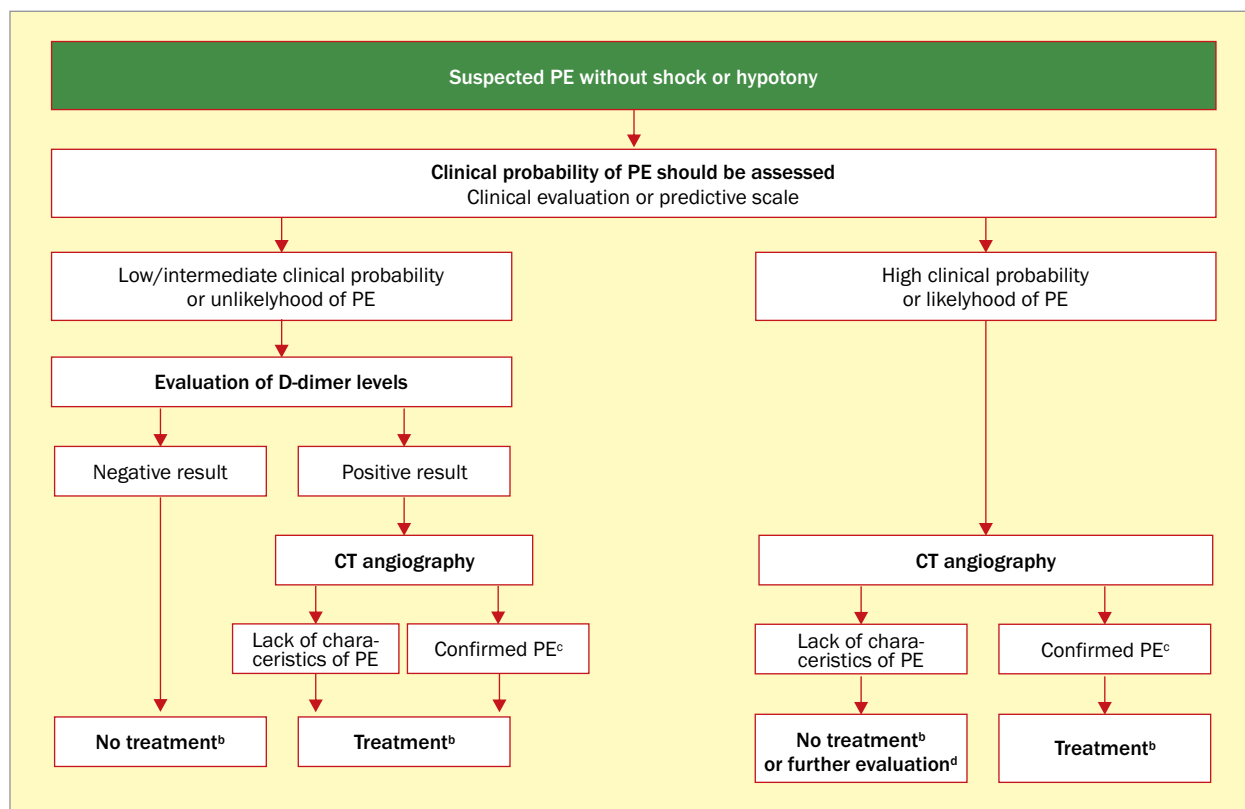
CUS is a non-invasive method of DVT imaging [14]. This is an effective, repetitive and best test to reveal deep vein thrombosis of the lower extremities and to exclude diseases that may resemble deep vein thrombosis, such as rupture of Baker's cyst, subcutaneous tissue inflammation [3], lymphadenopathy, pseudoaneurysms or pelvic tumors that press the hip veins [14].

In most cases, the source of PE is deep vein thrombosis of the lower extremities. In case of suspicion of PE, CUS exam may be limited to a simple assessment of four sites (groins and knee pits). The diagnostic benefits of using CUS in suspected PE can be increased by performing a complete ultrasound examination including distal veins [2].

Ultrasonographic signs of venous thrombosis include: the vessels lumen does not collapse when pressure is applied with the ultrasound probe [6], increase of the vessels diameter by more than 50%, increased echogenicity in the lumen of the vessel [17]; in Doppler examination:



**Figure 1.** Diagnostic algorithm for patients with suspected pulmonary embolism (PE) in the high-risk group; <sup>a</sup>also includes cases in which the patient's condition allows only to perform bedside diagnostic tests; <sup>b</sup>in addition to the diagnosis of RV dysfunction, bedside echocardiography may (in some cases) directly confirm the PE by visualizing the thrombus in the right heart cavities. Additional bedside tests include transesophageal echocardiography, which can show obstruction in the pulmonary artery and its branches, as well as bilateral knee ultrasound, which can confirm deep vein thrombosis and help in making a therapeutic decision; <sup>c</sup>thrombolysis, alternatively surgical embolectomy or a catheter; CT – computed tomography; RV – right ventricle



**Figure 2.** Diagnostic algorithm for patients with suspected low risk pulmonary embolism (PE); two alternative classification schemes can be used to assess the clinical probability of PE: a three-level scheme (low, intermediate and high probability) or a two-level (low probable and probable PE) scheme. The use of tests to determine the concentration of intermediate D-dimer should be reserved for patients with low probability or classified as less likely PE. On the other hand, the high sensitivity tests for the determination of D-dimer can also be used in patients with an intermediate probability of PE. D-dimer plasma levels are of limited utility in hospitalized patients with suspected PE; <sup>b</sup>anticoagulant treatment in PE; <sup>c</sup>CT angiography is considered to be diagnostic in PE diagnosis if it shows PE at the segmental level or more proximal; <sup>d</sup>in case of negative CT angiography in patients with high probability, further diagnostics should be considered before discontinuation of PE-specific treatment; CT – computed tomography

absence of flow in spectrum recording and with colored flow [6]. The only recognized diagnostic criterion of DVT is an incomplete vein compression indicating the presence of a thrombus, while the criteria based on blood flow are unreliable [2].

A positive proximal CUS result is characterized by a high predictive value for PE [2]. Despite the accuracy of the method, a negative CUS result does not exclude PE. Therefore, in patients with negative pressure test results and a high probability of PE [14], diagnosis should be continued [18].

### Echocardiography

Acute PE may lead to right ventricular pressure overload and ventricular dysfunctions, which can be detected by echocardiography [2]. Both transthoracic echocardiography (TTE, transthoracic echocardiography) and transesophageal echocardiography (TEE, transesophageal echocardiography) are used in the diagnosis of PE. TTE is the first additional test that should be performed in case of suspicion of a massive PE. In this case it allows to exclude shock or hypotonia of causes other than PE [1],

showing the presence of cardiac tamponade, acute valve failure, severe impairment of left ventricular function, aortic dissection. In high-risk suspicion of PE, with signs of shock or hypotonia, the lack of echocardiographic features of right ventricular overload or dysfunction practically excludes PE as a cause of hemodynamic instability [2]. Echocardiography is not recommended as part of a planned diagnostic strategy in hemodynamically stable patients with normal blood pressure when PE is suspected [2].

Echocardiographic signs – based either on disturbed right ventricular ejection (so-called “60/60 symptom”) or on impaired right ventricular free wall contractility when compared to the apex of the right ventricle (so-called “McConnell sign”) have a high positive prognostic value for PE, even in the presence of pre-existing cardiopulmonary diseases. Additional echocardiographic features of pressure overload should be found to avoid false diagnosis of acute PE in patients with hypokinesia or akinesia of the right ventricular free wall in the course of right ventricular infarction. Right ventricular mobile thrombus is detected during TTE or TEE in less than 4% of unsorted patients with PE, but their incidence may reach 18% under conditions

of intensive surveillance. Mobile thrombi in the right heart cavities basically confirm the diagnosis of PE, and their presence is associated with right ventricular dysfunction and high early mortality [2].

## Summary

Currently, the first-line imaging method in patients with suspected PE is CT pulmonary angiogram. Numerous studies have shown that the negative predictive value of CT pulmonary angiogram for PE is over 95%. However, the

diagnostic procedure depends on the clinical condition of the patient, clinical probability of PE and the available diagnostic imaging methods. Based on the guidelines of the European Society of Cardiology (ESC) for the diagnosis and management of acute PE from 2014, specific diagnostic algorithms presented in Figures 1 and 2 [2] may be used in the assessment of the above-mentioned factors.

## Conflict(s) of interest

Authors do not declare any conflict of interest.

## Streszczenie

Zatorowość płucną (PE) określa się jako jedną z częstszych kardiologicznych przyczyn bezpośredniego zagrożenia życia. O PE można mówić w przypadku mechanicznego zamknięcia światła łóżyska naczyniowego najczęściej przez płynącą z prądem krwi skrzeplinę. Na PE mogą wskazywać określone, choć nieswoiste objawy podmiotowe i przedmiotowe, w tym należy brać pod uwagę badania laboratoryjne oraz wywiad chorobowy pacjenta. Zalecane do oceny klinicznego prawdopodobieństwa PE są skale punktowe – Wellsa i zmodyfikowana Skala Genewska. Do badań obrazowych, pozwalających potwierdzić lub wykluczyć PE, należą: metody z zastosowaniem promieniowania jonizującego, takie jak radiogram klatki piersiowej, scyntygrafia płuc, tomografia emisyjna pojedynczego fotonu, angiotomografia tętnic płucnych czy klasyczna arteriografia tętnic płucnych; badania bez użycia promieniowania jonizującego, na przykład ultrasonografia – ultrasonograficzna próba uciskowa i echokardiografia czy obiecująca metoda, lecz jeszcze niegotowa do powszechnego stosowania – angiografia metodą rezonansu magnetycznego. Wybór metody obrazowania zależy od dostępności określonych badań oraz stanu klinicznego pacjenta.

Słowa kluczowe: zatorowość płucna, diagnostyka, przegląd

Folia Cardiologica 2018; 13, 6: 526–533

## References

1. Smarż K. Zatorowość płucna. *Post N Med.* 2007; 2–3: 74–79.
2. Konstantinides S, Torbicki A, Agnelli G, et al. Grupa Robocza Europejskiego Towarzystwa Kardiologicznego (ESC) do spraw rozpoznawania i postępowania w ostrej zatorowości płucnej. [2014 ESC Guidelines on the diagnosis and management of acute pulmonary embolism]. *Kardiologia Pol.* 2014; 72(11): 997–1053, doi: 10.5603/KP.2014.0211, indexed in Pubmed: 25524375.
3. Kapitan-Malinowska B, Bogołowska-Stieblich A. Żyłna choroba zakrzepowo-zatorowa. *Post N Med.* 2009; 5: 345–354.
4. Ocena prawdopodobieństwa klinicznego zatorowości płucnej w skali Wellsa. Polskie wytyczne profilaktyki i leczenia żyłnej choroby zakrzepowo-zatorowej – aktualizacja 2012. <http://www.mp.pl/zakrzepica/wytycznearytkuly/wytyczne/show.html?id=78538> (20.10.2018).
5. Ocena prawdopodobieństwa klinicznego zatorowości płucnej wg zmodyfikowanej skali genewskiej. In: *Interna Szczeklika*. red. Szczeklika A, Gajewski P. Podręcznik chorób wewnętrznych. Kraków 2013. <https://www.mp.pl/zakrzepica/praktykakliniczna/narzedzia/97513,ocena-prawdopodobienstwa-klinicznego-zatorowosci-plucnej-wg-zmodyfikowanej-skali-genewskiej> (20.10.2018).
6. Pruszyński B, Leszczyński S. red. Diagnostyka obrazowa – płuca i śródpiersie. PZWL, Warszawa 2010: 408–410.
7. Pruszyński B. red. Radiologia – diagnostyka obrazowa, RTG, TK, USG, MR i medycyna nuklearna. PZWL, Warszawa 2003: 179–180.
8. Brant WE, Helms CA. Podstawy diagnostyki radiologicznej. Tom IV. MediPage, Warszawa 2008: 1509.
9. Zmodyfikowane kryteria scyntygraficzne PLOPED II i PISAPED. <https://www.mp.pl/cteph/nadcisnienie-cteph/90956,diagnostyka-ostrej-zatorowosci-plucnej> (20.10.2018).
10. Skarlovnik A, Hrastnik D, Feticch J, et al. Lung scintigraphy in the diagnosis of pulmonary embolism: current methods and interpretation criteria in clinical practice. *Radiol Oncol.* 2014; 48(2): 113–119, doi: 10.2478/raon-2013-0060, indexed in Pubmed: 24991200.
11. Bajc M, Neilly JB, Miniati M, et al. EANM guidelines for ventilation/perfusion scintigraphy: Part 2. Algorithms and clinical considerations for diagnosis of pulmonary emboli with V/P(SPECT) and MDCT. *Eur J Nucl Med Mol Imaging.* 2009; 36(9): 1528–1538, doi: 10.1007/s00259-009-1169-y, indexed in Pubmed: 19629478.
12. Bajc M, Jonson B. Ventilation/perfusion SPECT for diagnosis of pulmonary embolism and other diseases. *Int J Mol Imaging.* 2011; 2011: 682949, doi: 10.1155/2011/682949, indexed in Pubmed: 21490731.
13. Prokop M, Galanski M. Spiralna i wielorządowa tomografia komputerowa człowieka. MediPage, Warszawa 2007: 837–842.
14. Brant WE, Helms CA. Podstawy diagnostyki radiologicznej. Tom II. MediPage, Warszawa 2008: 473–478.
15. Hurwitz LM, Reiman RE, Yoshizumi TT, et al. Radiation dose from contemporary cardiothoracic multidetector CT protocols with an anthropomorphic female phantom: implications for cancer induction. *Radiology.* 2007; 245(3): 742–750, doi: 10.1148/radiol.2453062046, indexed in Pubmed: 17923509.
16. Huisman MV, Klook FA. How I diagnose acute pulmonary embolism. *Blood.* 2013; 121(22): 4443–4448, doi: 10.1182/blood-2013-03-453050, indexed in Pubmed: 23591793.
17. Schmidt G. Ultrasonografia. MediPage, Warszawa 2008: 259.
18. Bogołowska-Stieblich A, Marcinkowska-Suchowierska E. Zakrzepica w ciąży. *Post N Med.* 2010; 5: 375–381.