

# Implantacja stentów wieńcowych w technice bezpośredniej nie upośledza ich stopnia rozprężenia. Badanie z wykorzystaniem ultrasonografii wewnątrzwieńcowej

## Direct stenting does not impair the expansion of endoprotheses. An intravascular ultrasound study

Tomasz Pawłowski<sup>1</sup>, Robert Gil<sup>1</sup>, Francesco Prati<sup>2</sup>,  
Alessandro Manzoli<sup>2</sup> i Piotr Kwiatkowski<sup>1</sup>

<sup>1</sup>Klinika Kardiologii Inwazyjnej CSK MSWiA w Warszawie

<sup>2</sup>European Imaging Laboratory, Rzym

### Abstract

**Background:** *It has been proved that extensively calcified hard plaques affect stent expansion and geometry. The aims of the study were: 1) to compare the acute results of direct stent implantation with stenting with predilatation; and 2) to verify whether the extent of plaque calcification influences stent expansion and geometry.*

**Material and methods:** *Sixty-five consecutive patients who underwent elective coronary stenting. The patients were divided into 2 groups according to the stenting technique adopted: Group 1 included 35 patients in whom direct stenting was performed, while Group 2 consisted of 30 patients in whom stenting followed by balloon angioplasty was performed. Serial 3-D intravascular ultrasound (IVUS) reconstructions were performed before and after stenting. Reproducible arterial landmarks were used to identify the same arterial segments in serial studies. The external elastic membrane area (EEMA), lumen area (LA), plaque area (PA) and calcific arc were measured at 1 mm intervals throughout the entire stent length.*

**Results:** *There were no differences between the groups regarding baseline clinical and angiographic characteristics. The mean baseline arc of calcium obtained in all the cross-sections analysed was  $81.7 \pm 66.4^\circ$  in Group 1 and  $88.8 \pm 79.2^\circ$  in Group 2 ( $p = NS$ ). No differences between the two groups were observed as regards IVUS LA, PA and EEMA variations after stenting. There were no differences in LA increase between Group 1 and Group 2, although we found LA increase was significantly limited in the cross-sections with the greatest calcific content (a calcific arc greater than  $180^\circ$ ) in both groups in comparison with the non-calcified lesions.*

**Conclusions:** *Direct stenting does not limit the expansion of the endoprotheses. The adequacy and geometry of stent expansion are highly dependent on the IVUS value of lesion calcification.* (Folia Cardiol. 2004; 11: 277–283)

**key words:** intravascular ultrasound, stent, coronary heart disease

Adres do korespondencji: Dr hab. med. Robert Gil  
Klinika Kardiologii Inwazyjnej CSK MSWiA  
ul. Wołoska 137, 02–507 Warszawa  
e-mail: kardiologia.inwazyjna@cskmswia.pl  
Nadesłano: 20.02.2004 r. Przyjęto do druku: 23.03.2004 r.

## Introduction

The widespread use of direct stenting is favoured by the improvement in stent design that nowadays enables endoprotheses to negotiate even tortuous and calcific vessels [1]. A burden of data has proved that extensively calcified hard plaque can affect stent apposition and expansion [2]. It is possible that the restrictive effect of calcific components is more evident when stenting is applied without predilatation. The aim of the study was, therefore, to compare the acute results of direct stent implantation with stenting with predilatation and to verify whether the extent of plaque calcification influences stent expansion.

## Material and methods

### Selection of patients

105 consecutive patients with stable angina, who had undergone intravascular ultrasound (IVUS) guided stenting procedures, were screened. Sixty-five patients (18 female and 47 male, mean age  $54 \pm 9$  years), were enrolled. These fulfilled the following angiographic and procedural pre-specified inclusion criteria: lesion length less than 16 mm at quantitative coronary angiography (QCA), absence of major side branch originating from the segment to be stented, absence of calcifications visible at angiography and use of pre-intervention intravascular ultrasound (IVUS) examination.

The choice of implantation method was left to the operator. 35 of the 65 patients enrolled had direct stenting (Group 1, while in the remaining 30 patients stenting was performed after regular balloon predilatation (Group 2).

### Stenting procedure and IVUS acquisition

In all patients the procedure was performed with a femoral approach, using standard techniques. 48 hours before the procedure the patients started to receive acetylsalicylic acid (300 mg/24 h) and ticlopidine (500 mg/24 h) or clopidogrel (300 mg loading dose + 75 mg/24 h). After the insertion of the arterial sheath, every patient received heparin 70–100 IU per kg and an additional bolus to maintain an activated clotting time of  $> 250$  seconds.

The stenting procedures in Group 1 were performed using low-profile stents implanted at a pressure greater than 10 atm and redilatation as necessary. The procedures in Group 2 were performed using classic balloon inflation for predilatation, followed by stent implantation. The interventions were carried out with IVUS guidance, applying the MU-

SIC criteria of optimal stent expansion which defines a minimal stent area of more than 80% of the mean reference lumen area [3]. After administration of 200  $\mu$ g intracoronary nitroglycerin, the IVUS images were recorded with a commercially available mechanical system (Boston Scientific Co, Natick, MS, USA) using 30 or 40 MHz imaging catheters (Ultracross and Atlantis, Boston Scientific Co, Natick, MS, USA). The IVUS catheter was positioned 3 cm distal to the lesion and pulled back at a speed of 0.5 mm/s until the guiding catheter was reached. The IVUS examinations were performed before intervention and after the last inflation within the stent.

### Off-line QCA and IVUS analyses

Off-line QCA analyses were performed at the European Imaging Laboratory by 2 technicians who were unaware of the IVUS measurements. Angiographic measurements were performed with a computer-assisted system using an automated edge detection algorithm (MEDIS Co, Eindhoven, Netherlands) as previously described [4].

Based on reproducible arterial landmarks (side-branches, calcium deposits and aorto-coronary junction), the same arterial segments were identified at each step of the interventional procedure (i.e. baseline, post stenting and after final redilatation) but only the first and the last images were included in the analysis. The arterial segment analysed by IVUS encompassed the stented segments.

All IVUS recordings were digitised with a commercially available system for 3-D reconstruction (EchoScan, TomTec, Munich, Germany) as previously described [5, 6]. 3-D reconstruction of the segments analysed was performed by applying a longitudinal resolution of 1.0 mm. In total, 437 cross-sections were analysed in Group 1 and 405 in Group 2 ( $p = \text{NS}$ ). The 3-D reconstruction favoured the assessment of the external elastic membrane (EEM) border when the arc of calcium was more than  $90^\circ$  in planimetry. In these cases the EEM area (EEMA) measurement was performed by extrapolation from the closest cross-sections with identifiable EEM borders [5]. The EEMA, minimal lumen area (LA) and plaque area (PA) as plaque + media area were measured in every cross-section of the segments analysed. The stent symmetry index (SSI) was defined as the ratio between maximal and minimal stent diameter. The extent of calcification was classified as none, less than  $90^\circ$ , between  $91^\circ$  and  $180^\circ$  and greater than  $180^\circ$  [7]. If there was more than one calcific deposit in a given imaging slice, then the calcific arcs were added. Applying Simpson's rule, the calcium volumetric burden (Ca Vol) was defined in the way previously

described [8]. The calcium volumetric index (% Ca Vol) was measured as the ratio between Ca Vol and the total plaque volume of the segment analysed.

### Statistics

Statistical analysis was performed using STATISTICA 5.1 software (Stat Soft Co.). Continuous variables are expressed as mean  $\pm$  Standard Deviation (SD). A two-tailed Student's test for unpaired data was used. To detect statistical differences between the groups and subgroups studied two-way ANOVA analysis was performed. Receiver operating characteristic (ROC) curve analysis was performed to assess the predictive values of the data obtained. A value of  $p < 0.05$  was considered statistically significant.

### Results

There were no differences between the groups regarding baseline clinical and angiographic charac-

teristics (tab. 1, 2). The mean baseline arc of calcium obtained in all the cross-sections analysed was  $81.7 \pm 66.4^\circ$  in Group 1 and  $88.8 \pm 79.2^\circ$  in Group 2 ( $p = \text{NS}$ ) and mean baseline Ca Vol was  $26.4 \pm 12.5 \text{ mm}^3$  in Group 1 vs.  $27.6 \pm 23.2 \text{ mm}^3$  in Group 2 ( $p = \text{NS}$ ).

The MUSIC trial criteria optimal stent expansion was achieved in 85% and 90% of Group 1 and 2, respectively ( $p = \text{NS}$ ).

No differences between the two groups were observed as regards the IVUS LA, PA and EEMA measurements obtained after stenting (tab. 3).

After grouping the lesions on the basis of their calcific content, the quantitative IVUS analysis was repeated (tab. 4). No differences in LA increase were found for a stepwise increase in calcium between direct stenting and stenting with predilatation. Both in Group 1 and Group 2 the increases in LA obtained in the subgroup with a calcific content greater than  $180^\circ$  were significantly smaller than those obtained in the subgroup with a calcific content of less than  $90^\circ$  (tab. 4).

**Table 1.** Patient population characteristics

	Group 1 Direct stenting (n = 35)	Group 2 Stenting with predilatation (n = 30)	p
Age [years] (mean $\pm$ SD)	57.4 $\pm$ 9.07	60.9 $\pm$ 10.7	NS
Male	85.8%	78.7%	NS
Diabetes	8.5%	6.6%	NS
Smoking	45.7%	39.6%	NS
Previous myocardial infarction	35.2%	38.5%	NS
<b>Vessel treated</b>			
Left anterior descending artery	22 (63%)	18 (60%)	NS
Left circumflex artery	6 (17%)	5 (17%)	NS
Right coronary artery	7 (20%)	7 (23%)	NS

**Table 2.** Angiographic procedural characteristics (mean  $\pm$  SD)

	Group 1 Direct stenting (n = 35)	Group 2 Stenting with predilatation (n = 30)	p
<b>QCA measurements pre stenting</b>			
Minimal lumen diameter [mm]	1.21 $\pm$ 0.51	1.10 $\pm$ 0.57	NS
Reference diameter [mm]	2.97 $\pm$ 0.73	3.0 $\pm$ 0.67	NS
Diameter stenosis	60.4 $\pm$ 9.3%	60.7 $\pm$ 13.7%	NS
Lesion length [mm]	8.3 $\pm$ 3.2	9.5 $\pm$ 3.6	NS
<b>QCA measurements post stenting</b>			
Minimal lumen diameter [mm]	3.14 $\pm$ 0.72	3.27 $\pm$ 0.52	NS
Reference diameter [mm]	3.46 $\pm$ 0.76	3.52 $\pm$ 0.65	NS
Diameter stenosis	9.7 $\pm$ 9.7%	7.6 $\pm$ 7.3%	NS
Stent size [mm]	3.59 $\pm$ 0.34	3.55 $\pm$ 0.32	NS
Stent length [mm]	10.93 $\pm$ 2.8	11.22 $\pm$ 3.2	NS
Maximal balloon pressure [atm]	14.0 $\pm$ 2.5	14.2 $\pm$ 2.8	NS

**Table 3.** Intravascular ultrasound measurements obtained as the means of all cross-sections (mean ± SD)

	Group 1	Group 2	p
<b>Pre-stenting measurements</b>			
Lumen area [mm <sup>2</sup> ]	6.35±4.54	5.93±3.79	NS
External elastic membrane area [mm <sup>2</sup> ]	19.85±6.61	18.75±6.88	NS
Plaque area [mm <sup>2</sup> ]	13.51±5.77	12.81±5.66	NS
Plaque burden (%)	60.63±17.94	62.99±18.47	NS
<b>Post-stenting measurements</b>			
Lumen area [mm <sup>2</sup> ]	10.18±3.77	9.76±3.03	NS
External elastic membrane area [mm <sup>2</sup> ]	21.76±7.13	21.80±6.92	NS
Plaque area [mm <sup>2</sup> ]	11.58±4.84	12.04±4.77	NS
Plaque burden (%)	53.22±15.30	55.23±14.90	NS

The SSI was significantly reduced in the cross-sections with an arc of calcium of between 181° and 360° in comparison to the remaining subgroups (tab. 5).

Figure 1 refers to the correlation between the stent symmetry index and the arc of calcium obtained in all cross-sections. The increase in the calcium arc was inversely related to the decrease in the stent symmetry ratio in both groups (r = -0.58 for Group 1, p < 0.001 and r = -0.57 for Group 2, p < 0.001). By the ROC analysis obtained in Group 1, a calcific arc of 173° predicted a SSI of 0.7 (positive predictive value of 92% and negative predictive value of 91%, accuracy 78%), while a calcific arc of 111° predicted a SSI of 0.8 (positive predictive value of 74% and negative predictive value of 94%, accuracy 81%). In Group 2 an arc of calcium of 183° predicted a SSI of 0.7 (with the positive predictive value of 72% and negative predictive value of 89%, accuracy 85%) and an arc of 115° predicted a SSI of

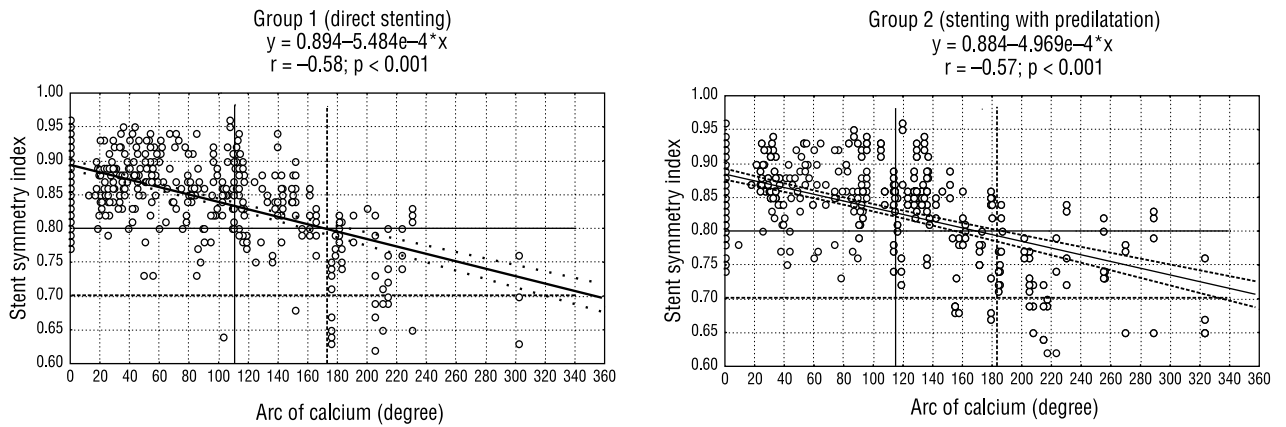
**Table 5.** Stent symmetry index in subgroups with different calcium arcs. P < 0.05 for comparison between the groups with calcific areas of between 181° and 360° and any of the other groups

	Group 1	Group 2	p
0 degree	0.87	0.86	NS
1-90 degree	0.86	0.85	NS
91-180 degree	0.84	0.84	NS
181-360 degree	0.81	0.79	NS

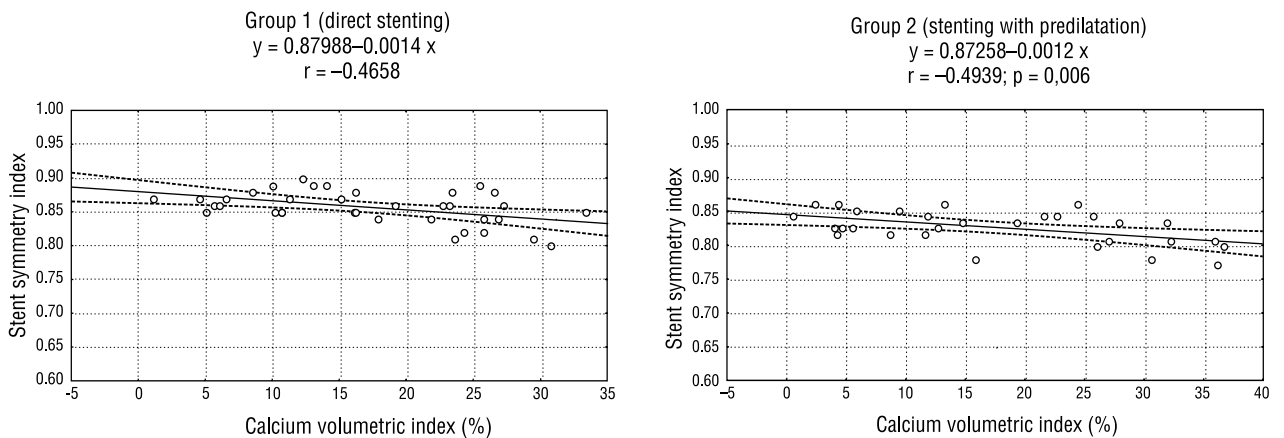
**Table 4.** Intravascular ultrasound measurements obtained in cross-section subgroups by calcific content (mean ±SD)

Number of cross-sections	Calcific arc: 0°		Calcific arc: 1-90°		Calcific arc: 91-180°		Calcific arc: 181-360°	
	Group 1 (n = 114)	Group 2 (n = 121)	Group 1 (n = 175)	Group 2 (n = 139)	Group 1 (n = 82)	Group 2 (n = 96)	Group 1 (n = 66)	Group 2 (n = 49)
LA pre-stenting [mm <sup>2</sup> ]	6.52 ± 4.75	6.61 ± 4.53	6.58 ± 4.23	5.54 ± 3.34	6.24 ± 3.61	5.42 ± 3.56	5.83 ± 3.50	5.49 ± 2.48
LA post-stenting [mm <sup>2</sup> ]	11.25 ± 3.59	11.0 ± 2.85	11.02 ± 6.65	10.34 ± 2.44	10.01 ± 3.48	9.95 ± 3.23	9.25 ± 4.02	9.07 ± 3.0
LA increase [mm <sup>2</sup> ]	4.73 ± 1.59*	4.39 ± 2.59*	4.44 ± 2.59	4.82 ± 3.13	3.77 ± 2.25	4.53 ± 2.85	3.42 ± 2.01*	3.58 ± 2.41#
EEMA pre-stenting [mm <sup>2</sup> ]	18.21 ± 6.06	15.59 ± 7.12	19.05 ± 6.54	17.05 ± 6.38	20.71 ± 7.37	20.28 ± 7.06	19.98 ± 4.99	20.17 ± 5.74
EEMA post-stenting [mm <sup>2</sup> ]	21.84 ± 4.37	17.59 ± 6.59	20.26 ± 5.26	20.28 ± 6.86	21.95 ± 5.62	23.95 ± 7.35	21.98 ± 4.26	22.58 ± 6.45
Mean arc of calcium (°)	0	0	46.12 ± 20.91	48.61 ± 20.95	122.96 ± 24.63	123.93 ± 24.36	213.81 ± 33.32	226.55 ± 41.41

LA — lumen area; EEMA — external elastic membrane area; \*p < 0.05 for comparison between subgroup 181-360° vs. subgroup 0° and 1-90°; #p < 0.05 for comparison between subgroup 181-360° vs. subgroup 0° and 1-90°



**Figure 1.** The relationship between the pre-intervention calcific arc and the stent symmetry index obtained after intervention in both groups. Lines depict the predictive value of the calcium arc for the stent symmetry index: below 0.7 (striped line) and below 0.8 (solid line)



**Figure 2.** The correlation between the calcium volumetric index and mean stent symmetry index in both groups

0.8 (with the positive predictive value of 76% and negative predictive value of 82%, accuracy 81%).

The calcium volumetric index was weakly correlated with the stent symmetry index obtained as the means of all the cross-sections (fig. 2).

There was no relationship, however, between Ca Vol and LA increase in either group ( $p = NS$ ).

### Discussion

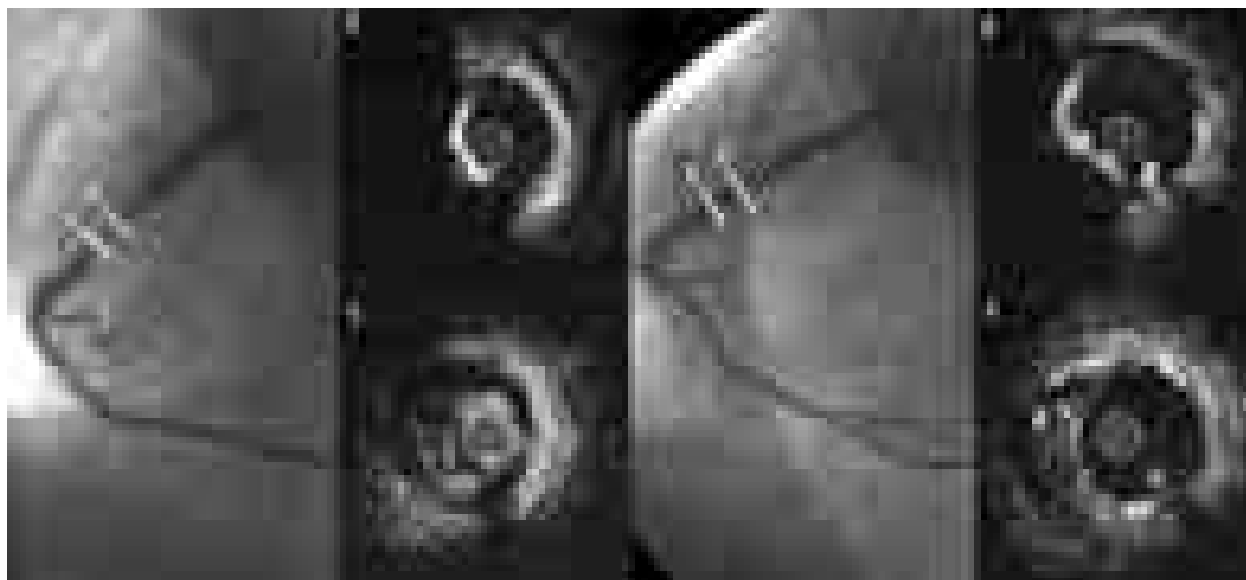The major finding of the present study is that direct stenting does not hamper the expansion of the endoprotheses, which is highly dependent on the amount of lesion calcification found in IVUS examination.

A previous study revealed that plaque calcification detected by angiography impairs the clinical outcome of interventional procedures. Fitzgerald et al. [9] showed that in the presence of a calcific arc of over 180° the risk of plaque dissection is signifi-

cantly higher than in lesions without calcification. Similarly, Gil et al. [10] confirmed that the presence of dissection is related to plaque composition, being favoured by hard plaque, and that the LA increase is significantly lower in the hard plaques than in the soft ones. Based on these previous findings, it was suggested that lesions with calcific deposits at angiography should be treated with stenting preceded by balloon dilatation.

Unlike angiography, IVUS enables the calcific deposit to be visualised with a high degree of accuracy. Mintz et al. [7] reported that in lesions with a calcific arc of 90° and 180°, calcification was detectable by angiography in 25% and 50% of cases respectively.

In the present study we have addressed the impact of IVUS calcification (missed by angiography) on the mechanism of stent expansion, when a modality of direct stent deployment is adopted.



**Figure 3.** Example of a procedure performed in RCA with the direct stenting technique. There is an arc of calcium greater than 180° before stenting (on the left). After the procedure incomplete expansion of the stent is seen (on the right)

We found that, in the presence of the same circumferential amount of calcium, the variation in LA was similar in the two groups. Even in the subgroup with the largest circumferential amount of calcium (between 180° and 360°) similar values in LA increase were found in Group 1 and Group 2 ( $3.42 \pm 2.01^\circ$  vs.  $3.58 \pm 2.41^\circ$ , respectively,  $p = \text{NS}$ ). The finding that balloon predilatation does not ameliorate stent expansion, even in the cross-section with the greatest amount of calcium, further supports the adoption of a strategy based on direct stenting. Recently Dudek et al. [11] have shown that in non-calcified plaques the symmetry indices and stent expansion are similar both during direct stenting and stenting with balloon predilatation. Together with our observations, this evidence can confirm that there is no need to change implantation strategy during stenting (fig. 3).

In the present study we also confirmed the findings by Albrecht et al. [2]. The authors noted that stent deployment for the treatment of highly calcific plaque (with a calcific arc of over 180°) results in decreased stent symmetry when compared with that for a non-calcified lesion. Because reduced stent symmetry may impair the coronary flow and

the shear stress and favours late neointimal formation, the adoption of post deployment high pressure inflation should be encouraged in order to improve stent geometry in these cases.

Accordingly, Vavaranakis et al. [12] have shown that using balloon inflations at 20 atm, the stent area increased significantly in comparison to the baseline IVUS diameters.

### Limitations

Although the study was non-randomised, two homogenous populations were compared. The primary operator was not blind to pre-interventional IVUS assessment and this may have influenced his decision-making. Nonetheless, the QCA and the IVUS target lesion measurements were similar in the two groups.

### Conclusions

Direct stenting does not limit the expansion of the endoprotheses, regardless of the extent of calcification. The adequacy and geometry of stent expansion are highly dependent on the IVUS value for lesion calcification.

### Streszczenie

**Wstęp:** *Silnie zwapniale blaszki miażdżycowe mogą upośledzać stopień rozprężenia i geometrię stentów wieńcowych. Celem niniejszej pracy była ocena wyników bezpośrednich implantacji stentów za pomocą techniki bezpośredniej w porównaniu z techniką z użyciem predylatacji, a także określenie, czy stopień zwapnienia blaszki miażdżycowej może wpływać na stopień rozprężenia i geometrię stentu.*

**Materiał i metody:** *Analizą objęto 65 kolejnych pacjentów poddanych implantacji stentów wieńcowych. Badaną populację podzielono na 2 grupy, stosownie do zastosowanej techniki implantacji stentów. Grupę 1 stanowiło 35 pacjentów poddanych zabiegom z zastosowaniem techniki bezpośredniej, natomiast grupę 2 — 30 chorych, którym implantowano stenty wieńcowe z użyciem predylatacji. U wszystkich pacjentów przeprowadzono ultrasonografię wewnątrzwieńcową (IVUS) przed i po zabiegu z wykorzystaniem trójwymiarowej rekonstrukcji. Analizie poddano wartości całkowitego pola naczynia (EEMA), pola światła naczynia (LA), pola blaszki miażdżycowej (PA) oraz wielkość zwapnień mierzone co 1 mm przez całą długość stentu.*

**Wyniki:** *Nie obserwowano różnic między grupami w zakresie charakterystyki klinicznej i angiograficznej. Średnia wielkość łuku zwapnień we wszystkich analizowanych przekrojach wyniosła  $81,7 \pm 66,4^\circ$  w grupie 1 oraz  $88,8 \pm 79,2^\circ$  w grupie 2 ( $p = NS$ ). Nie stwierdzono różnic między grupami w zakresie wartości EEMA, LA, PA po zabiegu implantacji stentów. Niezamienny statystycznie był także przyrost światła naczynia po zabiegu w obu badanych grupach, jednak w przypadku blaszek ze zwapnieniami powyżej  $180^\circ$  przyrost światła naczynia był istotnie mniejszy niż w przypadku blaszek bez zwapnień.*

**Wnioski:** *Użycie techniki stentowania bezpośredniego nie wpływa na stopień rozprężenia stentu, jednak jego geometria jest istotnie zależna od stopnia zwapnienia blaszki miażdżycowej.* (Folia Cardiol. 2004; 11: 277–283)

**ultrasonografia wewnątrzwieńcowa, stenty, choroba wieńcowa**

## References

1. Figulla H.R., Mudra H., Reifart N., Werner G.S. Direct coronary stenting without predilation: a new therapeutic approach with a special catheter design. *Cathet. Cardiovasc. Diagn.* 1998; 43: 245–252.
2. Albrecht D., Kaspers S., Fussl R., Hopp H., Sechtem U. Coronary plaque morphology affects stent deployment: assessment by intracoronary ultrasound. *Cathet. Cardiovasc. Diagn.* 1996; 38: 229–235.
3. de Jaegere P., Mudra H., Figulla H et al. Intravascular ultrasound-guided optimized stent deployment. Immediate and 6 months clinical and angiographic results from the Multicenter Ultrasound Stenting In Coronaries Study. *Eur. Heart J.* 1998; 19: 1214–1223.
4. Prati F., Di Mario C., Moussa I et al. In-stent neointimal proliferation correlates with the amount of residual plaque burden outside the stent. *Circulation* 1999; 99: 1011–1014.
5. Prati F., Arbustini E., Labellarte A. et al. Eccentric atherosclerotic plaques with positive remodelling have a pericardial distribution: a permissive role of epicardial fat? A three dimensional intravascular ultrasound study of left anterior descending artery lesions. *Eur. Heart J.* (in press).
6. von Birgelen C., Mintz G.S., de Feyter P.J. Reconstruction and quantification with three-dimensional intracoronary ultrasound. An update on techniques, challenges and future directions. *Eur. Heart J.* 1997; 18: 1056–1067.
7. Mintz G., Popma J., Pichard A. et al. Patterns of calcification in coronary artery disease. A statistical analysis of intravascular ultrasound and coronary angiography in 1155 lesions. *Circulation* 1995; 91: 1959–1965.
8. Tinana A., Mintz G., Weissman N. Volumetric intravascular ultrasound quantification of the amount of atherosclerosis and calcium in nonstenotic arterial segments. *Am. J. Cardiol.* 2002; 89: 756–760.
9. Fitzgerald P., Ports T., Yock P. Contribution of localized calcium deposits to dissection after angioplasty: an observational study using intravascular ultrasound. *Circulation* 1992; 86: 64–70.
10. Gil R., Di Mario C., Prati F. et al. Influence of plaque composition on mechanisms of percutaneous transluminal coronary balloon angioplasty assessed by ultrasound imaging. *Am. Heart J.* 1996; 131: 591–597.
11. Dudek D., Legutko J., Kaluza G. et al. Intravascular ultrasonic evaluation of the magnitude of stent expansion and the mechanisms of lumen enlargement after direct stenting and after conventional stenting with balloon predilatation. *Am. J. Cardiol.* 2002; 90: 639–641.
12. Vavuranakis M., Toutouzas K., Stefanadis C. Stent deployment in calcified lesions: can we overcome calcific restraint with high pressure balloon inflations? *Cather. Cardiovasc. Inter.* 2001; 52: 164–172.