



Radioactive iodine (RAI) treatment of hyperthyroidism is safe in patients with Graves' orbitopathy — a prospective study

Terapia nadczynności tarczycy jodem promieniotwórczym jest bezpieczna u chorych na chorobę Gravesa i Basedowa z orbitopatią — badanie prospektywne

Aleksandra Król¹, Aleksandra Koehler¹, Mariusz Nowak², Ewa Paliczka-Cieślik¹, Jolanta Krajewska¹, Michał Kalemba¹, Beata Jurecka-Lubieniecka¹, Kornelia Hasse-Lazar¹, Barbara Michalik¹, Sylwia Szpak-Ulczo¹, Łukasz Zarudzki³, Józef Roskosz¹, Barbara Jarzab¹

¹Nuclear Medicine and Endocrine Oncology Department, M. Skłodowska-Curie Memorial Institute and Centre of Oncology, Gliwice Branch, Poland

²Department of Pathophysiology and Endocrinology, Medical University of Silesia, Zabrze, Poland

³Department of Radiology, M. Skłodowska-Curie Memorial Institute and Centre of Oncology, Gliwice Branch, Poland

Abstract

Introduction: Radioactive iodine (RAI) therapy may induce or worsen orbitopathy (GO) in Graves' disease (GD). The aim of this study was a prospective assessment of the risk of GO exacerbation in a GD patients cohort submitted to RAI therapy for hyperthyroidism.

Material and methods: 208 consecutive GD patients treated with ¹³¹I in 2007 were enrolled. The analysis was performed on 156 patients strictly monitored for one year. Glucocorticosteroid (GCS) prophylaxis was administered if GO symptoms or GO history were present, and in cases of tobacco smokers even without GO symptoms. Clinical and biochemical evaluation at one, three, six, and 12 months after therapy was performed in the whole group, then at 24 months in 138 patients.

Results: There was no severe GO progression in patients without GO symptoms at the time of RAI treatment. The risk of severe GO worsening for preexisting GO patients (demanding systemic GCS administration) during the 12-month follow-up after RAI therapy was 10%. 12 and 24 months after ¹³¹I administration, stable improvement compared to the initial GO status had been achieved in most (98–96%) patients.

Conclusions:

1. In patients with mild GO, the risk of severe GO worsening after RAI therapy is acceptable, as long as RAI therapy is applied with GCS cover.
2. In patients without GO symptoms at the time of RAI therapy but with a history of GO and with subclinical GO diagnosed by MRI only, the risk of severe progression is minimal.
3. Distant outcomes of RAI treatment confirmed its safety in GO patients. (*Endokrynol Pol* 2014; 65 (1): 40–45)

Key words: Graves' orbitopathy; ¹³¹I therapy; glucocorticosteroid prophylaxis

Streszczenie

Wstęp: Leczenie jodem promieniotwórczym (¹³¹I) może indukować lub nasilać objawy orbitopatii u pacjentów z rozpoznaniem choroby Graves-Basedowa (CHGB). Celem pracy była prospektywna ocena ryzyka zaostrzenia orbitopatii w grupie chorych leczonych ¹³¹I z powodu nadczynności tarczycy.

Materiał i metody: Do badania włączono 208 kolejnych pacjentów z rozpoznaniem CHGB leczonych ¹³¹I w 2007. Do analizy włączono 156 chorych ściśle monitorowanych przez rok. Osłona glikokortykoidowa (GCS) była stosowana w przypadku występowania objawów orbitopatii, dodatniego wywiadu w kierunku orbitopatii i u palaczy tytoniu, także bez objawów orbitopatii. Kliniczna i biochemiczna ocena była przeprowadzona w całej grupie 1, 3, 6 i 12 miesięcy po leczeniu ¹³¹I i u 138 chorych po 24 miesiącach.

Wyniki: Nie obserwowano poważnego zaostrzenia orbitopatii u chorych bez objawów GO w chwili leczenia ¹³¹I. Ryzyko istotnej progresji orbitopatii (wymagającej stosowania GKS systemowych) w ciągu 12 miesięcznej obserwacji wynosiło u chorych z wyjściowymi objawami orbitopatii 10%. U większości chorych 12 i 24 miesiące po leczeniu ¹³¹I poprawa orbitopatii w porównaniu ze stanem wyjściowym była trwała.

Wnioski:

1. Ryzyko istotnej progresji objawów po leczeniu ¹³¹I u chorych z orbitopatią o umiarkowanym nasileniu jest akceptowalne,
2. Ryzyko progresji orbitopatii u chorych bez objawów w chwili leczenia ¹³¹I, ale z dodatnim wywiadem w kierunku orbitopatii i z subklinicznymi objawami (obecnymi tylko w badaniu NMR) jest minimalne.
3. Odległa ocena potwierdza bezpieczeństwo terapii radiojodem u chorych z orbitopatią. (*Endokrynol Pol* 2014; 65 (1): 40–45)

Słowa kluczowe: orbitopatią Gravesa; liczenie ¹³¹I; profilaktyka glikokortykosteroidowa



Prof. Barbara Jarzab M.D., Ph.D., Nuclear Medicine and Endocrine Oncology Department, M. Skłodowska-Curie Memorial Cancer Center and Institute of Oncology, Wybrzeże AK 15, 44-101 Gliwice, Poland, tel.: +48 32 278 93 01, fax: +48 32 278 93 10, e-mail: bjarzab@io.gliwice.pl

Introduction

Radioiodine (RAI) therapy is a radical method allowing the achievement of a permanent cure for hyperthyroidism. It is generally the treatment of choice in cases of recurrent hyperthyroidism in the course of Graves' disease (GD). It is also often used as the first-line treatment for GD hyperthyroidism [1, 2].

RAI is an effective and safe treatment method of GD hyperthyroidism. However, in patients showing symptoms of Graves' orbitopathy (GO), this therapy remains controversial because of the data showing RAI to be a risk factor of GO deterioration (according to the published data in 15–37% subjects) [3–6].

Clinically apparent orbitopathy is present in about 30–40% of GD patients: there are severe changes in 5%, while 90% have subclinical eye disease revealed by MRI scan only. Currently, GCS cover is recommended after radioiodine administration to prevent GO worsening. The optimal way of administration, as well as the doses and time of treatment, remain open questions [7]. Most researchers agree that smoking is a serious risk factor influencing orbitopathy [8, 9]. Other suggested risk factors are: thyrotoxicosis at the time of RAI therapy, immunological activity of the disease reflected by high titres of serum TSH receptor antibodies, and post-therapeutic hypothyroidism [10–14].

According to the current guidelines of the European Group on Graves' Orbitopathy, the presence of GO is not considered as a contraindication for RAI treatment [15]. However, risk factors should be assessed individually and the patient must be informed about the possibility of GO exacerbation in order to give informed consent. In patients with mild GO, corticosteroid cover after RAI administration is recommended. In cases of moderate-to-severe GO, intravenous glucocorticoid therapy is the first line treatment and RAI therapy should be considered thoroughly in terms of the risk-to-benefits ratio.

The aim of this study was a prospective evaluation of a GD patients cohort with different preexisting GO activity, focused on the risk of GO worsening after RAI treatment.

Material and methods

208 consecutive patients with Graves' hyperthyroidism were treated with RAI between January and June 2007. Inclusion criteria were: former GD diagnosis, qualification to RAI treatment, minimum age of 18 years, and consent for participation in the study. GO assessment was performed in the whole group. Patients with GO activity above CAS 3 and with constant diplopia were excluded from the study.

156 patients (127 women and 29 men) aged 18–79 were enrolled. All patients were previously pharmacologically treated due to hyperthyroidism, 11 patients underwent thyroid surgery before RAI treatment, whereas 26 were treated with radioiodine.

A strict follow-up was planned, with the first endpoint at 12 months after RAI administration. The initial examination was made by an endocrinologist, including biochemical evaluation of thyroid function, ultrasonography (US) of thyroid gland, GO assessment based on CAS and NOSPECS scores. Previous ophthalmological symptoms, the presence of immunological diseases in a patient or his/her family and smoking history were also taken into consideration. Thyroid function and US as well as GO symptoms (using CAS/NOSPECS scores) were subsequently monitored by the endocrinologist at one, three, six and 12 months after RAI therapy. 24-month follow-up was performed using the same protocol. Ophthalmological evaluation was performed by the same ophthalmologist (M.N.) in each patient between three and six months after RAI. In cases of GO exacerbation, the treatment was supervised by the ophthalmologist.

Therapeutic radioiodine ionising energy dose was calculated according to the Marinelli formula with the goal of 150 Gy for the first treatment and 200 Gy in subjects previously radically treated (surgically or with radioiodine). Radioiodine activities ranged from 5 to 33 mCi (mean 12.4 mCi).

GCS after RAI were administered in 72 (46%) subjects (56 patients with diagnosed orbitopathy and 16 smokers without GO symptoms). Prednisone was administered (with initial oral dose 30 mg daily) starting from the day of RAI therapy and then tapered off over three months.

GO progression was evaluated as significant when CAS score deteriorated by at least 2 points or in the case of presence of new diplopia or exophthalmos, as well as when orbitopathy newly occurred. Intensity of GO symptoms was assessed during 12 months after RAI. Clinical follow-up was performed after 12 and 24 months (12 *v.* 0 and 24 *v.* 0, respectively) with evaluation of GO activity and advancement compared to the initial status.

MRI of orbits was performed in 63/156 patients from the analysed group, among them in 56 patients before and 12 months after RAI treatment.

The study project was approved by the institutional ethics review board.

Results

In the whole group ($n = 156$), there were 56 patients specified as the GO(+) group, comprising 39 patients with GO symptoms and 17 patients with positive

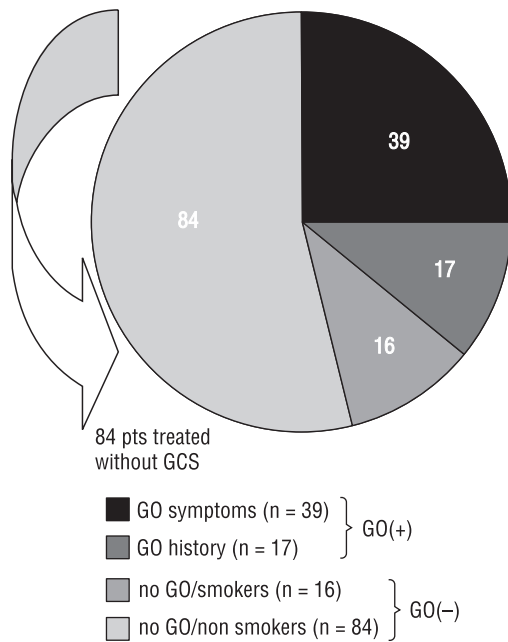


Figure 1. GO status estimated by CAS at the time of RAI therapy in the study group (n = 156). 84 patients without GO and non-smokers were given RAI without GCS cover, while 16 pts without GO who were defined as smokers received RAI under GCS cover. In total, 72 pts received GCS and 84 did not receive any GCS cover

Rycina 1. Obecność i nasilenie objawów orbitopatii w oparciu o CAS w chwili leczenia ¹³¹I w grupie badanej (n = 156). U 84 chorych bez objawów orbitopatii i u niepalących tytoniu nie stosowano steroidoterapii, natomiast u 16 chorych-palaczy bez orbitopatii włączono osłonę steroidową

GO history without GO symptoms at the time of RAI therapy.

In the remaining 100 patients without GO symptoms, the (GO(-) group), 16 smokers were categorised as an at risk group of GO exacerbation.

GCS cover during RAI therapy were administered in GO patients and in no-GO smokers (Fig. 1).

During 12 months after RAI therapy, GO exacerbation was observed in 29 patients from the whole group. In four of them with preexisting GO intravenous GCS were given 5–8 months after RAI therapy. In the remaining 25 patients eye symptoms, classified as slight and transient, disappeared in the short term without any treatment or after using only moisturizing eye drops only (Fig. 2).

Transient GO worsening was stated in 10/39 patients with preexisting GO symptoms and in 6/16 patients with positive GO history; in total in 16/56 patients with GO symptoms or GO history — 29%.

Moreover, transient progression was observed in 9/100 patients (9%) from the GO(-) group — in eight non-smoker subjects and in one smoker. All these cases with mild worsening of GO symptoms were classified as newly diagnosed GO (Fig. 3).

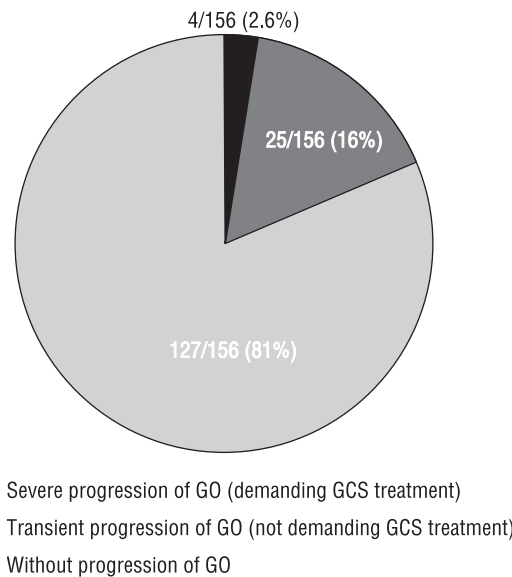


Figure 2. GO dynamic in the whole study group during 12 months of follow-up after RAI. Some pts (16%) showed only transient progression of GO, which did not demand GCS treatment

Rycina 2. Dynamika objawów orbitopatii w całej grupie badanej w ciągu 12-miesięcznego okresu obserwacji po leczeniu ¹³¹I. U części chorych (16%) obserwowano jedynie przejściową progresję, która nie wymagała stosowania glikokortykosteroidów

GO status was reassessed 12 and 24 months after RAI and compared to the initial examination. Clinical deterioration compared to the initial GO status was observed only in 3/156 subjects (2%) from the whole study group, whereas in 16/156 (10%) clinical improvement was stated. In other patients, GO symptoms did not differ significantly before and after RAI therapy. Two years after RAI therapy (138 patients controlled), four cases of deterioration were diagnosed. These patients were only carefully monitored without systemic GCS treatment. There were 15 cases of improvement compared to the initial status (Fig 4).

There were 39 patients with GO symptoms in the whole study group (n = 156) before RAI treatment (25%), among them ten GO patients with CAS 3, while one year after RAI therapy there were 33 symptomatic GO patients (21%) with two patients with CAS 3. Two years after RAI (n = 138) CAS 3 points was present in two of 22 symptomatic GO cases (9%) without any treatment required at that time (Fig. 5).

In the analysed group, 63 MRI examinations of orbits were performed before RAI. Only three MRI results were normal, whereas ten showed radiological features of active GO. In the remaining 50 cases, MRI confirmed inactive chronic GO or only minimal changes (different degrees of exophthalmos or signal abnormalities in eye muscles). To sum up, radiological GO features were present in 60/63 MRI.

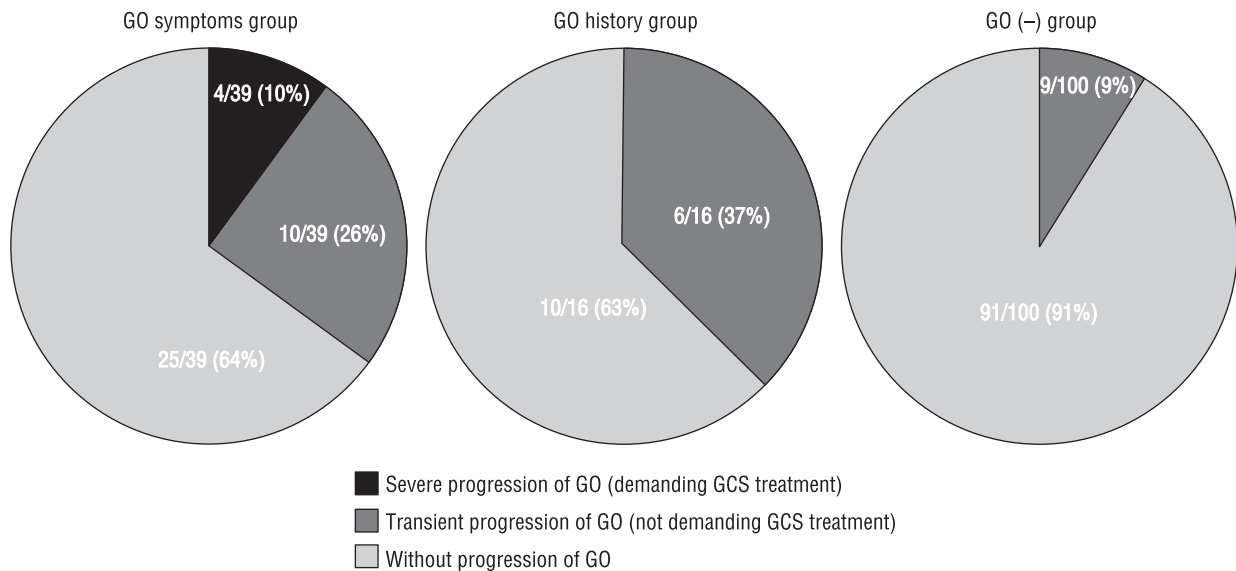


Figure 3. GO severe and transient progression during the 12-month follow-up regarding initial GO presence. Only 10% of patients in the clinically apparent GO symptoms group progressed after RAI therapy despite GCS cover

Rycina 3. Ciężka i przejściowa progresja orbitopatii w ciągu 12-miesięcznego okresu obserwacji w zależności od stanu wyjściowego. Jedynie u 10 % chorych z objawową orbitopatią doszło do progresji po leczeniu ^{131}I , mimo osłony steroidowej

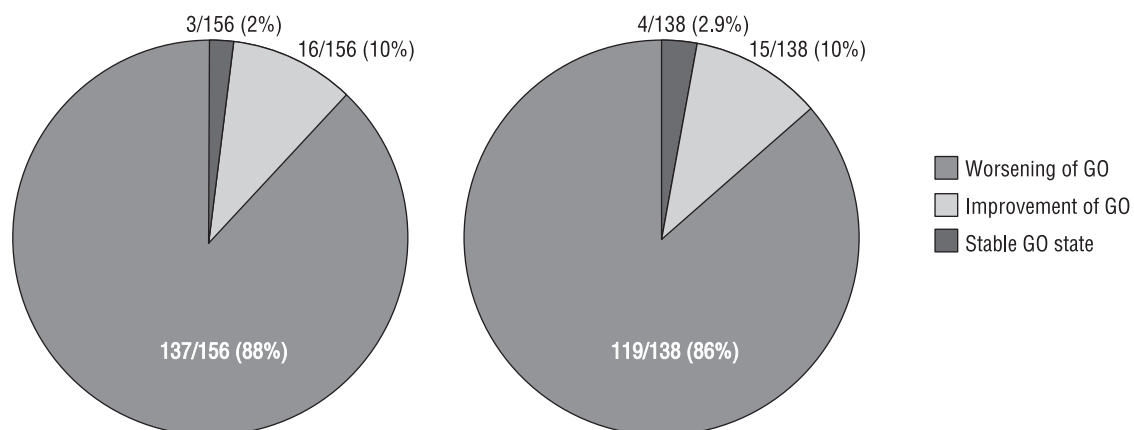


Figure 4. GO worsening/improvement 12 (left) and 24 (right) months after RAI treatment compared to the initial GO status at RAI administration. Most GO patients showed stable GO as estimated 12 months and 24 months after treatment. Only in 3/156 patients had GO status deteriorated 12 months after RAI: these were all pts without GO symptoms at the time of RAI. In 4/138 patients, GO status was worse after 24 months than at the time of RAI: these were three patients with an initial history of GO and one with mild GO at the time of RAI

Rycina 4. Pogorszenie/poprawa objawów orbitopatii 12 (lewy diagram) i 24 (prawy diagram) miesiące po leczeniu ^{131}I w stosunku do stanu wyjściowego w chwili leczenia ^{131}I . Większość chorych prezentowała stabilny stan orbitopatii po 12 i 24 miesiącach od leczenia. Tylko u 3/156 pacjentów stan orbitopatii uległ pogorszeniu po 12 miesiącach od terapii ^{131}I , byli to chorzy wyjściowo bez objawów orbitopatii. U 4/138 chorych stan był gorszy po 24 miesiącach od leczenia ^{131}I , w tym 3 chorych bez wyjściowo obecnej orbitopatii i jednego z łagodną orbitopatią

In 56 patients, MRI was performed twice — before and 12 months after ^{131}I treatment. In 11/56 (20%) cases, improvement was shown (reduction of exophthalmos, decrease of muscle thickness and change in muscle MRI appearance), whereas in 42/56 (75%) stable disease was diagnosed (there were no significant differences between two MRI examinations) and in 2/56 (3.6%) — worsening (increase of exophthalmos and thickening of eye muscles with signal change). One of

the MRI examinations performed 12 months after RAI therapy was inconclusive because maxillary cancer was diagnosed and GO status was difficult to estimate.

Discussion

RAI treatment of hyperthyroidism in GD patients may be related to the risk of GO exacerbation — 15–37% according to the published data [3, 4]. However, the exact

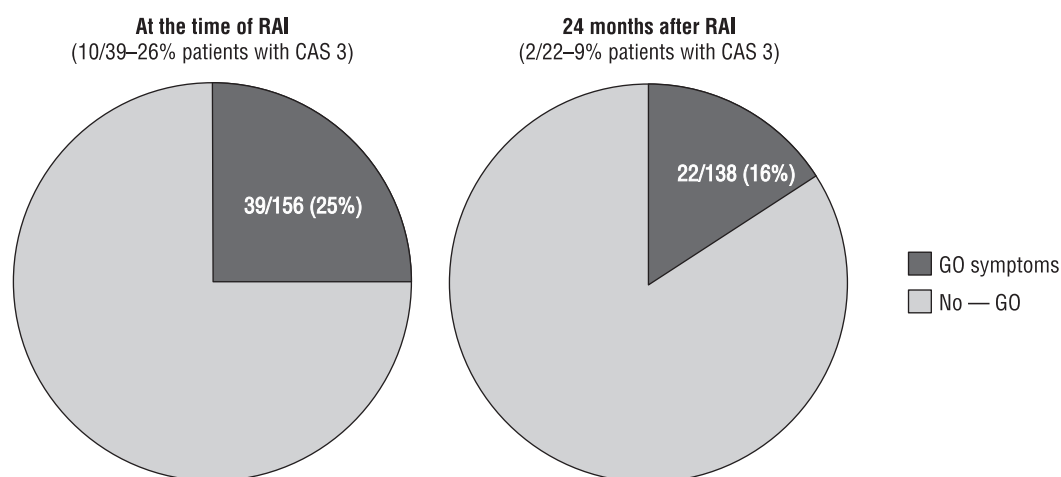


Figure 5. GO status in the study group at the time of RAI and 24 months after RAI. As evaluated 24 months after RAI treatment, patients of the study group showed significant improvement of GO when RAI treatment was performed with adequate GCS cover

Rycina 5. Występowanie objawów orbitopatii w grupie badanej w chwili leczenia ¹³¹I oraz 24 miesiące po terapii. 24 miesiące po terapii obserwowano znaczącą poprawę w zakresie nasilenia orbitopatii, jeżeli terapię ¹³¹I przeprowadzono w osłonie steroidowej

evaluation of progression risk is difficult because most studies are nonrandomised, uncontrolled or retrospective. Moreover, ophthalmological examination is based on non-standardised evaluation of ocular changes. So, a comparison between subsequent assessments is difficult or even impossible.

To properly assess the exacerbation of GO symptoms after RAI treatment, the natural course of the disease should be taken into consideration. Perros et al. demonstrated that 13.5% (8/59) of patients deteriorated progressively during a 12-month follow-up to the extent that immunosuppressive treatment was considered to be necessary. Simultaneously, a natural improvement was observed in more than 64% of subjects [16]. The results of our study confirm this observation.

It is widely known that RAI treatment is more risky than surgery or pharmacotherapy as far as GO is concerned. So, according to some authors, surgical methods seem to be the treatment of choice [17, 18]. According to other authors, the risk of GO exacerbation after RAI treatment is minimal, especially under GCS cover administration [19] and we have proven this view in our study. Efficacy as well as schema of GCS prophylaxis is still under discussion [20–22].

In the present study, we assumed that if GO progression occurred within one year after ¹³¹I treatment, it was most probably due to the ¹³¹I administration. Separate analysis was carried out for severe GO progression demanding GCS treatment and for transient worsening without any treatment needed. The risk of GO progression during the 12-month follow-up and final treatment outcomes (GO status 12 and 24 months after RAI) were analysed separately. Moreover, strict criteria of GO progression during the first year, as well

as improvement criteria after one and two years based on CAS and NOSPECS scores, were established.

This study has been planned on the basis of our own retrospective analysis (not published), which involved 299 GD patients treated with RAI in 2006 (among them 103 with overt GO in whom GCS cover was administered) with at least 12 months of follow-up. GO progression was observed in 7/103 (6.8%) and only four of them needed GCS therapy. The differences in progression rate compared to the present prospective study may be due to the fact that some mild and transient GO exacerbations could be lost in the retrospective observation.

In this prospective study, patients with various stages of GO were qualified to ¹³¹I treatment, among them subjects with active GO, GD patients without any clinical GO features but with positive GO history, as well as patients without any GO symptoms.

Our findings are similar to the published data concerning the frequency of MRI ophthalmological symptoms in GD patients (taking into account also subclinical cases) which show that almost every GD patient must be considered as a potential GO subject. MRI is not usually necessary, only in doubtful cases, hence the assessment of the patients and qualification for GCS prophylaxis were based on physical examination, according to the widely accepted criteria. GCS coverage was used according to the current EUGOGO guidelines. Clinical and MRI evaluation after one and two years confirmed GO improvement in most patients. The rate of deterioration one year after ¹³¹I administration was not higher as in the natural course of GO. However, the question of how to treat patients with active GO remains open and encourages further

prospective studies based on strict ophthalmological criteria involving a large number of patients [23, 24].

Conclusions

1. The risk of GO induction in GD patients without any GO symptoms or with subclinical GO manifestation (diagnosed by MRI) is minimal.
2. We conclude that RAI treatment of GD hyperthyroidism constitutes a safe therapeutic tool in GD patients with mild GO.
3. Distant outcomes of treatment are positive. Clinical improvement confirmed by MRI was stated in most patients one year and two years after RAI.

References

1. Solomon B, Glinoor D, Lagasse R et al. Current trends in the management of Graves' disease. *J Clin Endocrinol Metab* 1990; 70: 1518–1524.
2. Bartalena L, Tanda ML, Piantanida E et al. Relationship between management of hyperthyroidism and course of the ophthalmopathy. *J Endocrinol Invest* 2004; 27: 288–294.
3. Ponto KA, Zang S, Kahaly GJ. The tale of radioiodine and Graves' orbitopathy. *Thyroid* 2010; 20: 785–793.
4. Bartalena L, Marcocci C, Bogazzi F et al. Relation between therapy for hyperthyroidism and the course of Graves' ophthalmopathy. *N Engl J Med* 1998; 338: 73–78.
5. Tallstedt L, Lundell G, Tørring O et al. Occurrence of ophthalmopathy after treatment for Graves' hyperthyroidism. The Thyroid Study Group. *N Engl J Med* 1992; 326: 1733–8.
6. Marcocci C, Bartalena L, Bogazzi F et al. Studies on the occurrence of ophthalmopathy in Graves' disease. *Acta Endocrinol (Copenh)* 1989; 120: 473–478.
7. Bartalena L, Marcocci C, Bogazzi F et al. Use of corticosteroids to prevent progression of Graves' ophthalmopathy after radioiodine therapy for hyperthyroidism. *N Engl J Med* 1989; 321: 1349–1352.
8. Bartalena L, Marcocci C, Tanda ML et al. Cigarette smoking and treatment outcomes in Graves ophthalmopathy. *Ann Intern Med* 1998; 129: 632–635.
9. Marcocci C, Bartalena L, Tanda ML et al. Comparison of the effectiveness and tolerability of intravenous or oral glucocorticoids associated with orbital radiotherapy in the management of severe Graves' ophthalmopathy: results of a prospective, single-blind, randomized study. *J Clin Endocrinol Metab* 2001; 86: 3562–3567.
10. Laurberg P, Wallin G, Tallstedt L et al. TSH-receptor autoimmunity in Graves' disease after therapy with anti-thyroid drugs, surgery, or radioiodine: a 5-year prospective randomized study. *Eur J Endocrinol* 2008; 158: 69–75.
11. Eckstein AK, Plicht M, Lax H et al. Thyrotropin receptor autoantibodies are independent risk factors for Graves' ophthalmopathy and help to predict severity and outcome of the disease. *J Clin Endocrinol Metab* 2006; 91: 3464–3470.
12. Kung AW, Yau CC, Cheng A. The incidence of ophthalmopathy after radioiodine therapy for Graves' disease: prognostic factors and the role of methimazole. *J Clin Endocrinol Metab* 1994; 79: 542–546.
13. Wall JR, Lahooti H. Pathogenesis of thyroid eye disease — does autoimmunity against the TSH receptor explain all cases? *Endokrynol Pol* 2010; 61: 222–227.
14. Sawicka N, Sowiński J. Correlation between thyroid volume and humoral thyroid autoimmunity after radioiodine therapy in Graves' disease. *Endokrynol Pol* 2012; 63: 10–13.
15. Bednarczyk T, Bar-Andziak E., Hubalewska-Dydejczyk A et al. Management of Graves' orbitopathy. Comments on EUGOGO consensus statement. *Endokrynol Pol* 2009; 60: 312–330.
16. Perros P, Crombie AL, Kendall-Taylor P. Natural history of thyroid associated ophthalmopathy. *Clin Endocrinol (Oxf)* 1995; 42: 45–50.
17. Lowery AJ, Kerin MJ. Graves' ophthalmopathy: the case for thyroid surgery. *Surgeon* 2009; 7: 290–296.
18. Stålberg P, Svensson A, Hessman O et al. Surgical treatment of Graves' disease: evidence-based approach. *World J Surg* 2008; 32: 1269–1277.
19. Manso PG, Furlanetto RP, Wolosker AM et al. Prospective and controlled study of ophthalmopathy after radioiodine therapy for Graves' hyperthyroidism. *Thyroid* 1998; 8: 49–52.
20. Bartalena L. Editorial: glucocorticoids for Graves' ophthalmopathy: how and when. *J Clin Endocrinol Metab* 2005; 90: 5497–5499.
21. Bartalena L, Tanda ML, Piantanida E et al. Glucocorticoids and outcome of radioactive iodine therapy for Graves' hyperthyroidism. *Eur J Endocrinol* 2005; 153: 13–14.
22. Vannucchi G, Campi I, Covelli D et al. Graves' orbitopathy activation after radioactive iodine therapy with and without steroid prophylaxis. *J Clin Endocrinol Metab* 2009; 94: 3381–3386.
23. Wiersinga WM. Management of Graves' ophthalmopathy. *Nat Clin Pract Endocrinol Metab* 2007; 3: 396–404.
24. Bartalena L. The dilemma of how to manage Graves' hyperthyroidism in patients with associated orbitopathy. *J Clin Endocrinol Metab* 2011; 96: 592–599.