



Diagnostic and therapeutic guidelines for gastro-entero-pancreatic neuroendocrine neoplasms (recommended by the Polish Network of Neuroendocrine Tumours)

Beata Kos-Kudła¹, Jolanta Blicharz-Dorniak², Janusz Strzelczyk¹, Agata Bałdys-Waligórska^{3*}, Tomasz Bednarczuk^{4*}, Marek Bolański^{5*}, Agnieszka Boratyn-Nowicka^{6*}, Małgorzata Borowska^{2*}, Andrzej Cichoński^{7*}, Jarosław B. Ćwikła^{8*}, Massimo Falconi^{9*}, Wanda Foltyn^{1*}, Daria Handkiewicz-Junak^{10*}, Alicja Hubalewska-Dydejczyk^{11*}, Barbara Jarzab^{10*}, Roman Junik^{12*}, Dariusz Kajdaniuk^{13*}, Grzegorz Kamiński^{14*}, Agnieszka Kolasińska-Ćwikła^{15*}, Aldona Kowalska^{16*}, Robert Król^{17*}, Leszek Królicki^{18*}, Maciej Krzakowski^{19*}, Jolanta Kunikowska^{18*}, Katarzyna Kuśnierz^{20*}, Paweł Lampe^{20*}, Dariusz Lange^{21*}, Anna Lewczuk-Myślicka^{22*}, Andrzej Lewiński^{23*}, Michał Lipiński^{24*}, Magdalena Londzin-Olesik^{2*}, Bogdan Marek^{13*}, Anna Nasierowska-Guttmejer^{25*}, Sergiusz Nawrocki^{26*}, Ewa Nowakowska-Duńska^{27*}, Joanna Pilch-Kowalczyk^{28*}, Violetta Rosiek^{1*}, Marek Ruchała^{29*}, Lucyna Siemińska^{13*}, Anna Sowa-Staszczak^{11*}, Teresa Starzyńska^{30*}, Katarzyna Steinhof-Radwańska^{28*}, Krzysztof Sworczak^{22*}, Anelli Syrenicz^{31*}, Andrzej Szawłowski^{32*}, Marek Szczepkowski^{33*}, Ewa Wachuła^{6*}, Wojciech Zajęcki^{2*}, Anna Zemczak^{2*}, Wojciech Zgliczyński^{34*}, Krzysztof Zieniewicz^{35*}

¹Department of Endocrinology and Neuroendocrine Tumours, Department of Pathophysiology and Endocrinology, Medical University of Silesia, Katowice

²Department of Endocrinology and Neuroendocrine Tumours, Medical University of Silesia, Katowice

³Chair and Department of Endocrinology, Jagiellonian University, Medical College, Krakow

⁴Department of Internal Medicine and Endocrinology, Medical University of Warsaw

⁵Department of Endocrinology, Diabetes, and Isotope Therapy, Wrocław Medical University

⁶Department of Oncology and Radiotherapy, Medical University of Silesia, Katowice

⁷Department of Oncological Surgery, Maria Skłodowska-Curie Memorial Cancer Centre and Institute of Oncology, Warsaw

⁸Department of Radiology, Faculty of Medical Sciences, University of Warmia and Mazury, Olsztyn

⁹Pancreas Translational & Clinical Research Centre, Università Vita e Salute, Milano, Italy

¹⁰Department of Nuclear Medicine and Endocrine Oncology, Maria Skłodowska-Curie Memorial Cancer Centre and Institute of Oncology, Gliwice Branch

¹¹Chair and Department of Endocrinology, Jagiellonian University, Medical College, Krakow

¹²Chair and Department of Endocrinology and Diabetology, Nicolaus Copernicus University in Torun, Collegium Medicum in Bydgoszcz

¹³Division of Pathophysiology, Department of Pathophysiology and Endocrinology, Medical University of Silesia, Katowice

¹⁴Department of Endocrinology and Radioisotope Therapy, Military Institute of Medicine, Warsaw

¹⁵Department of Clinical Oncology, Maria Skłodowska-Curie Memorial Cancer Centre and Institute of Oncology, Warsaw

¹⁶Endocrinology Clinic of Holycross Cancer Centre, Kielce

¹⁷Department of General Vascular and Transplant Surgery, Medical University of Silesia, Katowice

¹⁸Nuclear Medicine Department, Medical University of Warsaw

¹⁹Department of Lung Cancer and Thoracic Tumours, Maria Skłodowska-Curie Memorial Cancer Centre and Institute of Oncology, Warsaw

²⁰Department of Gastrointestinal Surgery, Medical University of Silesia, Katowice

²¹Department of Tumour Pathology, Maria Skłodowska-Curie Memorial Cancer Centre and Institute of Oncology, Gliwice Branch

²²Department of Endocrinology and Internal Diseases, Medical University of Gdansk

²³Department of Endocrinology and Metabolic Diseases, Medical University of Lodz

²⁴Department of Gastroenterology, Central Clinical Hospital of the Ministry of Interior and Administration, Warsaw

²⁵Department of Pathology, The Jan Kochanowski University, Kielce

²⁶Department of Oncology and Radiotherapy, Medical University of Silesia, Katowice

²⁷Department of Gastroenterology and Hepatology, Medical University of Silesia, Katowice

²⁸Department of Radiology and Nuclear Medicine, Medical University of Silesia, Katowice

²⁹Department and Clinic of Endocrinology, Metabolism, and Internal Diseases, University of Medical Sciences, Poznan

³⁰Department of Gastroenterology, Pomeranian Medical University, Szczecin

³¹Department of Endocrinology, Metabolic and Internal Disease, Pomeranian Medical University, Szczecin

*other authors in alphabetical order



prof. Beata Kos-Kudła M.D., Department of Endocrinology and Neuroendocrine Tumours, Department of Pathophysiology and Endocrinology, Medical University of Silesia, Ceglana St. 35, 40-952 Katowice, Poland, tel./fax: +48 32 358 13 66, e-mail: endoklin@sum.edu.pl

³²Maria Skłodowska-Curie Memorial Cancer Centre and Institute of Oncology, Warsaw

³³Department of Colorectal, General, and Oncological Surgery, Centre of Postgraduate Medical Education, Warsaw

³⁴Department of Endocrinology, Postgraduate Medical Education Centre, Warsaw

³⁵Chair and Department of General, Transplant, and Liver Surgery, Medical University of Warsaw

Abstract

Progress in the diagnostics and therapy of gastro-entero-pancreatic (GEP) neuroendocrine neoplasms (NEN), results of new randomised clinical trials, and publication of the new guidelines by the European Neuroendocrine Tumour Society (ENETS) have led the Polish Network of Neuroendocrine Tumours to update its 2013 guidelines regarding on management of these neoplasms.

This article presents the general recommendations for the management of NENs, developed by experts during the 3rd Round Table Conference — *Diagnosis and therapy of gastro-entero-pancreatic neuroendocrine neoplasms: Polish recommendations in view of current European recommendations*, which took place in December 2016 in Żelechów near Warsaw. Based on the extensive experience of the centres dealing with this type of neoplasms we believe that we have developed the optimal management system, for these patients which applies the most recent achievements and can be implemented effectively in Poland.

These management guidelines have been arranged in the following order:

gastric and duodenal NENs (including gastrinoma); pancreatic NENs; NENs of the small intestine and appendix, and colorectal NENs. (*Endokrynol Pol* 2017; 68 (2): 79–110)

Key words: gastro-entero-pancreatic neuroendocrine neoplasms; diagnosis; therapy

1. Epidemiology

Gastro-entero-pancreatic neuroendocrine neoplasms/tumours (GEP NENs/NETs) develop from the diffuse endocrine system (DES) cells present in the gastrointestinal tract and in the pancreas. The detection rate for neuroendocrine neoplasms (NENs) has increased recently [1, 2]. Between 1973 and 2004, the incidence rates of NENs increased from 2.1 to 5.25 new cases/100,000 people/year, with the most frequently reported primary tumour site being the small intestine (37.4%). Since the year 2000, rectal NENs are detected more frequently than small intestinal NENs [1–4].

The prevalence of NENs in the years 1994–2009 increased from 2.48 to 5.86 per 100,000 / year [4].

Following epidemiological studies conducted in the USA (SEER: Surveillance Epidemiology End Results) and Norway (NRC: Norwegian Registry of Cancer), an increase in the incidence of gastric and rectal NENs has been observed, as well as lower incidence of NENs of the appendix [3]. Currently, the mean general prevalence rate for these neoplasms is 35 cases in 100,000. A slight dominance of male patients (5.35/100,000/year) has been observed, compared to females (4.76/100,000/year) [1, 3, 5]. Approximately 70% of neuroendocrine tumours are GEP NENs, which account for approx. 2% of all gastrointestinal neoplasms [1, 4] and constitute a rare, heterogeneous group of neoplasms [6, 7]. If these neoplasms demonstrate hormonal activity they are called functional tumours. Those that do not produce hormones and/or biogenic amines in quantities sufficient to present clinical symptoms are called non-functional tumours. Over 50% of GEP NENs are neoplasms, which are most frequently found accidentally, during a surgical procedure, in the small intestine and in the appendix, as well as in the diagnosis of distant metastases, mostly to the liver [1].

The incidence rate of NENs, both functional and non-functional, derived from different parts of the gastrointestinal tract and the pancreas are discussed in other sections of this document.

2. Diagnostics

2.1. Biochemical diagnostics

In the biochemical diagnostics of NENs the following should be considered:

A. Non-specific markers

Determination of serum (or, less often, plasma) chromogranin A (CgA) concentration is the most commonly used test [1, 8, 9]. In the blood, CgA is a relatively stable protein. However, there are different methods of determining CgA concentration: radioimmunological (RIA) or enzymatic (ELISA) methods using blood serum or plasma [10]. Unfortunately, there are no international CgA standards, and the differences between available tests are significant. To monitor the course of the disease, it is recommended to determine the CgA concentration using the same method [1]. ENETS experts emphasise in recent guidelines that CgA may be useful for the diagnosis, assessment of response to treatment, and detection of disease progress or early stage recurrence. However, they indicate an urgent need to standardise the determination of CgA [4].

The CgA assay is useful in:

- **Diagnosing NEN** CgA levels are raised in most gastrointestinal and respiratory NENs, particularly in the generalisation phase, but results within reference range do not exclude the diagnosis of NET. The sensitivity of the CgA concentration test varies in different neoplasms, ranging from 10% to 100%, while its specificity is 68 to 100%. The highest sensitivities have been observed in gastrinoma, glucagonoma, and small intestinal NETs. Particularly high

CgA concentrations are found in NENs of the small intestine, with hepatic metastases and symptoms of carcinoid syndrome, where the CgA concentration may be up to an order of magnitude higher than normal. On the other hand, in benign insulinomas CgA concentrations are often within the reference range. In neuroendocrine carcinomas (NECs), CgA concentrations are often lower than in well-differentiated NETs. Concentrations exceeding the reference values are not always caused by a NEN, therefore they are not tantamount to diagnosis [1, 11, 12]. Therefore, while interpreting CgA results, it is necessary to know which test has been used and whether possible causes for false positive or false negative results arise (Table I) [1].

- **As a prognostic factor for survival and a marker for monitoring the course of the disease, and of GEP NEN treatment.** CgA concentrations are independent prognostic factors for survival in patients with small intestinal and pancreatic NENs [1, 13]. Use of somatostatin analogues (SSA) considerably lowers CgA concentrations, in the case of progressing disease. Increased CgA concentration during treatment with somatostatin analogues may reflect lack of control of the tumour secretory function and/or its growth. Early decrease in CgA concentration in patients with pancreatic NETs during treatment with everolimus is also a favourable prognostic factor for progression-free survival [1, 13].

Another non-specific NEN marker is neuron-specific enolase (NSE). NSE has lower sensitivity and specificity (30–50%) in diagnosing GEP NENs, compared to CgA. Increased NSE concentration may be associated with poorly differentiated NECs. The specificity of this marker is 63% in LCNEC (large cell NEC) and 62% in SCNEC (small cell NEC). NSE is also an independent prognostic factor for NECs. Its sensitivity in NET G1 and G2 is significantly lower: 19% and 54%, respectively. Simultaneous CgA and NSE determination is more sensitive and specific in the diagnosis of NENs [13, 14].

Pancreatic polypeptide (PP) may be a useful marker for non-functional pancreatic NENs, especially those associated with MEN1 syndrome [9].

Chromogranin B (CgB) is also mentioned as a non-specific marker as its concentration may be increased in insulinoma, rectal NETs and NETs of the ovaries. Pancreostatin is a fragment of CgA, and it has been suggested that proton pump inhibitors (PPIs) do not affect pancreostatin concentration. The availability of these tests in Poland is limited [1, 9].

Highly promising are new molecular markers, especially the NETest, which analyses the expression profiles of selected gene transcripts, specific for NENs. Performing this test is justified at the stage of NEN diagnosis, as

Table I. Reasons other than GEP-NEN, for elevated serum CgA concentration [1]

Reasons other than GEP NEN for increased serum CgA concentration
Receiving proton pump inhibitors and histamine H2-receptor blockers (if possible, they should be discontinued at least 7–14 days before the test)
Atrophic gastritis
Renal failure
Meal or physical effort 2–4 hours before the blood draw
Other neoplasms: prostate cancer, small cell lung carcinoma, medullary thyroid cancer, pheochromocytoma, hepatic cancer, pancreatic adenocarcinoma
Other non-neoplastic causes of increased CgA concentration (usually with a lesser effect on CgA levels):
— chronic inflammations, including rheumatoid arthritis (presence of IgM rheumatoid factor), COPD
— gastrointestinal diseases, including inflammatory bowel disease, hepatitis, cirrhosis, and pancreatitis
— cardio-vascular diseases, including cardiac failure, myocardial infarction
— endocrine diseases, including hyperthyroidism or hyperparathyroidism, treatment with glucocorticoids
— others, e.g. Parkinson's disease

well as for monitoring the course of the disease, response to treatment, and early detection of progression [15–17].

Circulating microRNAs are promising biomarkers of NENs, due to their presence and stability in the body fluids, and their specificity for particular neoplasms [18].

B. Specific markers

The choice of specific GEP NEN markers depends on the clinical manifestation and type of neoplasm suspected (Table II) [6, 12, 19, 20]. Direct measurement of the concentrations of specific peptides, biogenic amines, and hormones produced by NET cells is useful not only in diagnosing, but also in monitoring the treatment [12]. Details of biochemical diagnostics in individual clinical syndromes are discussed in other sections of this recommendation.

The most frequently observed set of clinical symptoms associated with hormonal activity of NEN is the carcinoid syndrome. The clinical picture is discussed in the section on NENs of the small intestine and the appendix (*see* p. 223–236). The classical form depends mainly on excessive serotonin secretion. An atypical form is observed in pulmonary carcinoid tumours and in gastric NENs; it depends on excessive secretion of serotonin, 5-hydroxytryptophan (5-HT; serotonin precursor), and/or histamine.

Serotonin is produced by 70% of NETs, mostly arising in the small intestine, including the ileum, the proximal large intestine, and the appendix, and by

Table II. Selected biochemical markers in GEP NEN diagnostics [1, 6, 12, 19, 20]

Primary NEN site	Biochemical markers
Stomach – type I, II	Gastrin
Duodenum	Gastrin
Duodenum, pancreas	SST (somatostatin)
Small intestine, ileum, proximal large intestine	5HIAA
Pancreas	glucose, insulin, peptide C
	Gastrin
	Glucagon
	VIP

10–35% of gastric and pulmonary NENs. The screening test for carcinoid syndrome includes two assays of daily urinary excretion of a serotonin metabolite: 5-hydroxyindoleacetic acid (5-HIAA), provided that a proper diet has been followed. It is also important to acidify urine during sample collection (Table III) [1, 11, 12, 21]. The reference range is 2–8 mg/day (10–42 mmol/d). Possible false-positives and false negatives are presented in Table III [1, 11, 12, 21].

Gastro-entero-pancreatic NENs (mostly of the pancreas) may cause ectopic production of: ACTH (causing ACTH-dependent Cushing's syndrome), GHRH (causing acromegaly), vasopressin (causing SIADH), and PTH-rP (causing hypercalcaemia). The diagnostics of these syndromes depends on clinical symptoms [1].

In all patients with foregut NENs, particularly in patients with NENs of the thymus, duodenum (gastrinoma), and pancreas, examinations for multiple endocrine neoplasia type 1 (MEN1) should be performed [22]. Basic screening tests in MEN1 include concentrations of ionized or total calcium, parathyroid hormone (intact PTH), gastrin, prolactin, and IGF-1. In patients with suspected MEN1, molecular tests should be considered to detect mutation in the MEN1 menin-coding gene [1, 23].

Minimal consensus statement on biochemical examinations:

- In patients with suspected NEN, CgA concentration should be determined (*evidence level 3).
- In patients diagnosed with NEN in the dissemination phase, CgA concentration should be determined (*evidence level 3) — also concentrations of hormones and substances specific for a given syndrome, depending on the clinical symptoms presented by the patient.
- If MEN1 is suspected, it is recommended that the concentration of ionized calcium, parathyroid hormone (PTH), and pituitary hormones (mainly prolactin) are determined, and conducting genetic tests should be considered (*evidence level 3).

Table III. Causes of false-positive and false-negative assessments of daily urinary 5-HIAA excretion [1, 11, 12, 21]

False-positives	False-negatives
Food products rich in tryptophan: avocado, bananas, kiwi, pineapples, walnuts, plums, aubergine, and cheese.	Food products: ethanol
Discontinue 3 days before the collection	
Medicines: paracetamol, phenobarbital, ephedrine, and certain cytostatics (Cisplatin, 5-fluorouracil)	Medicines: neuroleptics, MAO inhibitors, methyl dopa, isoniazid, acetylsalicylic acid, heparin, and tricyclic antidepressants
Discontinue 3 days before the collection	Discontinue 3 days before the collection
	Renal failure
	Abnormal urine acidification! During the sample collection, add 10 ml of 25% HCL to urine, to reduce the pH to 1.5–4.0.
	Incorrectly collected daily urine sample (determination of daily creatinine excretion, plastic containers, stored in a fridge)

Details of biochemical diagnostics are discussed in other sections of this recommendation.

The proposed algorithm of diagnostic and therapeutic management is presented in Figure 1 [1].

2.2. Pathomorphological diagnostics

2.2.1. Histopathological classification of NENs

Following the recommendations of the European Neuroendocrine Tumour Society (ENETS), since 2000 neuroendocrine neoplasms/tumours (NENs/NETs) have been diagnosed on the basis of the type of cell and site organ, histological type, including their differentiation and histological maturity grading (G), and pathomorphological advancement (pTNM), as well as clinical advancement staging (S) [1]. In 2006, Rindi proposed an organ-based assessment of the pathological advancement of NENs, pTNM/ENETS [24]. However, according to ENETS, the most important histopathological characteristic of clinical significance is the grade (G) of the neoplasm's histological differentiation, assessed based on the Ki-67 proliferative index and the number of mitotic figures. The histopathological grade (G) is the key microscopic feature with a prognostic and predictive value in the treatment of patients with gastrointestinal NENs. It is an independent parameter dividing NENs into three groups, according to the predicted clinical behaviour

*evidence level according to OCEBM [274]

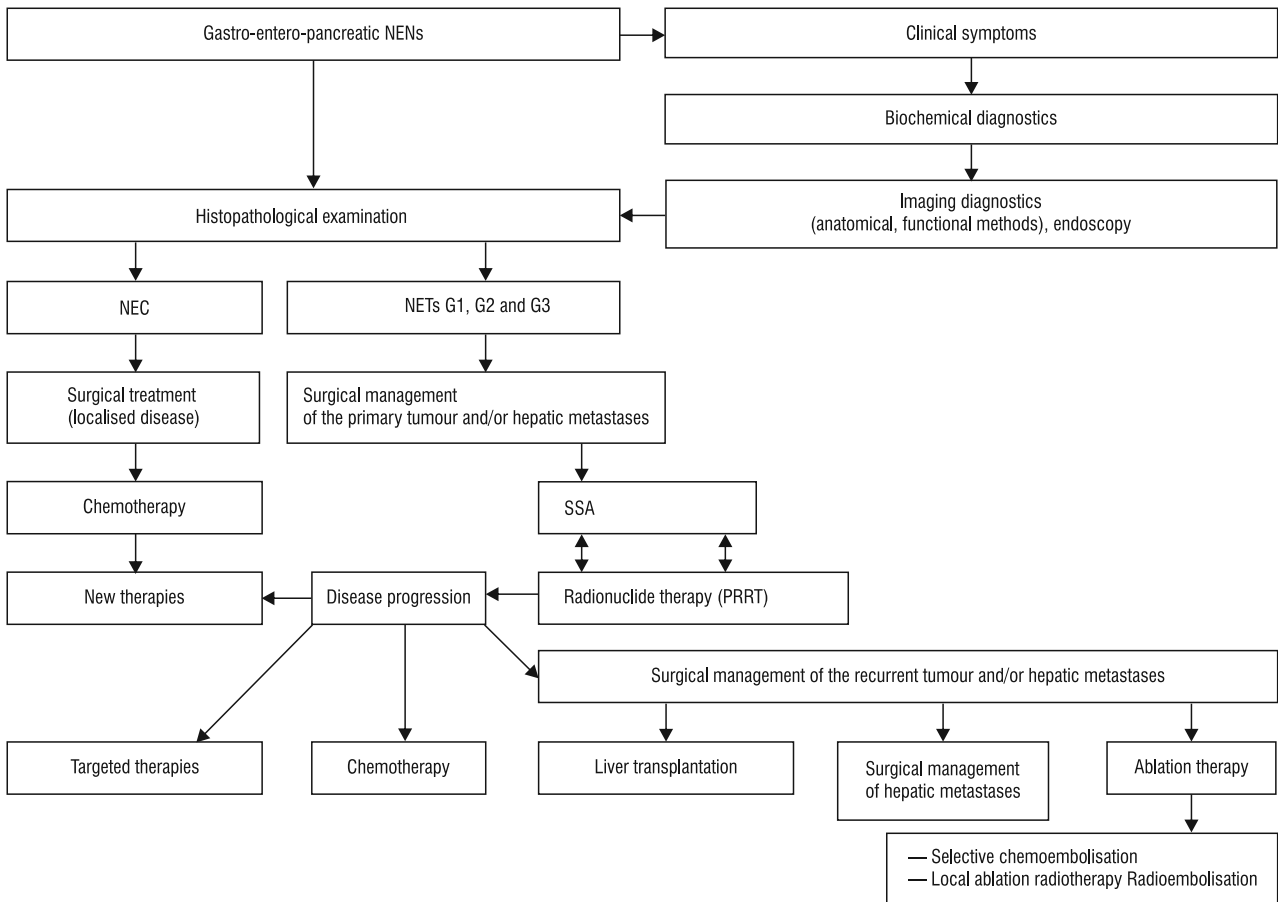


Figure 1. Proposed GEP NEN management algorithm [1]

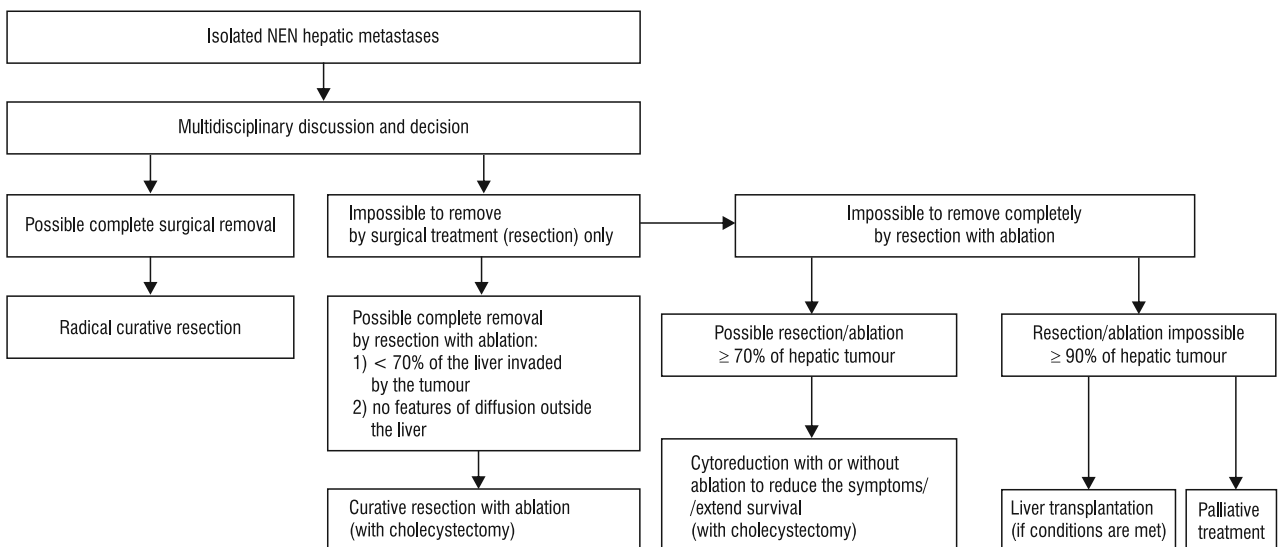


Figure 2. Principles of treating liver NET metastases [modified after refs. to 1, 160, 161]

of the disease: lesions of low (G1), moderate (G2), and high (G3) malignancy. The criteria for the assessment of the G feature defined by ENETS in 2006 [24] were subsequently adopted by the WHO, which resulted in the

ENETS/WHO 2010 integrated system for the assessment of histological grading of NENs. Table IV [25] presents two methods for assessing the histological malignancy grading of NENs, based on two criteria. The first is the

*evidence level according to OCEBM [274]

number of mitotic figures, counted in ten high-power fields with a magnification of $40 \times$ (1 HPF = 2 mm²). It is recommended to examine 50 high-power fields and select 10 fields of the highest mitotic activity (hot spots). The other criterion is the assessment of the Ki-67 proliferation index, determined by immunohistochemical analysis of the MIB1 antigen expression. It is expressed as the percentage of cells with MIB1 immunohistochemical expression in the highest activity fields, calculated in 500 to 2000 tumour cells. Where the assessment by these two methods provides different grades for the tumour, the Ki-67 proliferation index usually provides a higher value, and it should be accepted as the recommended grade. The above-mentioned division of NENs into two groups is the basis for the classification systems and therapeutic choices for this group of neoplasms [26, 27, 28].

The WHO 2010 classification system, based on the differentiation and histological maturity grade (G), introduced the division of gastro-entero-pancreatic NENs into two basic categories, different in terms of clinical behaviour and treatment [25]. The first group comprises well-differentiated neoplasms, morphologically corresponding to those referred to as carcinoids before 2000, and with a proliferation index of $\leq 20\%$ — NET G1 and NET G2 (well-differentiated neuroendocrine tumours, G1 and G2). They are made up of cells resembling normal neuroendocrine cells, forming a trabecular, rosette nest, or pseudoglandular structures and expressing neuroendocrine markers in the cytoplasm, usually demonstrating extensive synaptophysin, CgA, and hormonal expression, dependent on the tumour location, and a small or medium nuclear atypia, below 20 mitotic figures / 10 HPF. Tumours in this category are classified and treated according to criteria applicable to well-differentiated neuroendocrine neoplasms, NETs [29, 30]. The other group were neuroendocrine neoplasms, with a Ki-67 proliferation index above 20%, in the WHO 2010 classification system referred to as neuroendocrine carcinomas (NECs). According to the 2017 American Joint Committee on Cancer (AJCC/UICC) 8th Edition, the group of poorly differentiated G3 neuroendocrine neoplasms (NECs) is heterogeneous. Within this group, in each organ of the gastrointestinal system a small group of well-differentiated neoplasms was distinguished, with Ki-67 above 20%, usually from 21% to 50% (well differentiated G3 NETs) [31–37]. Contrary to NET G3, the remaining poorly differentiated neuroendocrine neoplasms with Ki-67 above 20%, typically of over 50%, were high-grade neuroendocrine carcinomas (NECs), divided into large and small cell carcinomas. Their course is particularly aggressive, resembling lung cancers of similar morphology. They are composed of small or large cells, only occasionally creating structures that

Table IV. Grading criteria for assessment malignancy of neuroendocrine tumours [34, 35, 37]

Histological malignancy grade of NEN (G)	Mitotic activity/no. of mitotic figures /10 HPF	Ki-67 proliferation index/% of cells (per 2,000 cells)
G1 — well differentiated of low malignancy	< 2	< 3
G2 — moderately differentiated, of medium malignancy	2–20	3–20
G3 — poorly differentiated, of high malignancy	> 20	> 20

resemble those of neuroendocrine tumours. NECs usually demonstrate an intense and extensive expression of synaptophysin, with a weaker expression of CgA, marked nuclear atypia, necrosis, and over 20 mitotic figures/10 HPF. Information about the heterogeneity of poorly differentiated neuroendocrine neoplasms with a proliferation index above 20% is presented in various publications [38–41]. In a study published in 2017, Italian authors from Milan demonstrated a correlation between overall survival (OS) and the NEC group. According to their studies, the OS for NET G3 was 43.6 months, for NECs with a proliferation index Ki-67 between 20% and 55% the OS was 24.5 months, and for NECs with Ki-67 equal to or higher than 55% it was 5.3 months [42]. A proposed new classification of NENs, including groups in the NEC category according to 2017 AJCC/UICC, is presented in Table V [31–36].

The next group consists of neoplasms characterised by a complex exocrine and endocrine structure (mixed adenoendocrine carcinoma), and at least a 30% content of a given component determines its diagnosis. The diagnosis of this type of neoplasm is confirmed by immunohistochemical examinations with the use of particular antibodies [37, 43–46].

High-grade neuroendocrine carcinomas (NECs), goblet-cell carcinoids, and other mixed glandular-neuroendocrine cancers are classified following the criteria for classical glandular cancers typical for a given organ of the gastrointestinal tract.

2.2.2. Obligatory and conditional methods of pathomorphological examination in NENs

ENETS guidelines present rules for examinations of the material, depending on its type. Fine-needle aspiration biopsy is not recommended as a diagnostic method in the case of non-diagnosed primary tumour. It may be used to confirm the presence of metastases from the established point of origin [24, 47, 48].

*evidence level according to OCEBM [274]

Table V. Proposed NEN classification incorporating the heterogeneous NEC group, according to AJCC [31–37]

NEUROENDOCRINE NEOPLASMS, NEN			
NEN with proliferation index below 20%		NEN with proliferation index above 20%	
NET G1	NET G2	NET G3	NEC
Well-differentiated tumours			Neuroendocrine cancers
Well-differentiated tumours with Ki-67 proliferation index below 3%	Well-differentiated tumours with Ki-67 proliferation index from 3% to 20%	Well-differentiated tumours with Ki-67 proliferation index above 20%, usually between 21 and 55%	Neuroendocrine cancers with proliferation index above 21%, usually above 55% — large-cell cancers — small-cell cancers

Table VI. Principles of cytological and histopathological examination of tissue specimens in neuroendocrine neoplasms [24, 46, 47]

Type of material tested	Recommendations, assessment methods
FNA — fine needle aspiration	In metastases with an established primary tumour site
Biopsy from the primary tumour or from metastases (liver, lymph nodes)	Tissue material preserved in formalin The preparation directly undergoes the process of technical preparation (without macroscopic assessment)
Surgical material	Conditional: Recommended freezing of the tumour sample before preservation in formalin Obligatory: Tissue specimen preserved in formalin, examined macroscopically, undergoes the process of technical preparation for microscopic preparations

The principles of preparation of the biopsy material from the primary tumour or from metastases, and of the surgical material, are presented in Table VI and VII.

Minimal consensus statement on pathomorphological examination:

1. *In the pathomorphological diagnostics of a small biopsy (excision from the lesion), it is recommended to diagnose the type of neoplasm, well-differentiated — NET, or poorly differentiated — NEC, neuroendocrine neoplasm/tumour — MINEN (mixed neuroendocrine non-neuroendocrine neoplasms), and the grade (G1, G2, G3 in NETs). However, the quantity of biopsy material may be insufficient and not representative of the entire tumour. TNM staging of the neoplasm is also recommended in the diagnostics of surgical material and polyps with the morphology of NENs, or a biopsy from the liver, with an established original tumour site, or to complete the data from imaging examinations. The assessment of resection margins*

Table VII. Principles of macroscopic examination of surgically obtained NEN tissues [24, 46, 47]

Principles of macroscopic examination of surgical NEN material
Obligatory:
— determination of: location, number of tumours, size (three dimensions)
— assessment of tumour cross-section appearance: solid/cystic, necrosis present
— assessment of tissues surrounding the tumour / invasion of adjacent organs
— marking surgical margins with ink
— excision of lymph nodes
Conditional:
— obtaining and preserving a fresh fragment of the tumour for scientific research
Immunohistochemical examination
Obligatory:
— Immunohistochemical assessment of neuroendocrine markers: synaptophysin, chromogranin A
— immunohistochemical assessment of Ki-67/MIB1 proliferative activity
Conditional:
Immunohistochemical examination of hormonal expression (insulin, gastrin, serotonin, etc.) if symptoms of tumour hormonal activity occur:
— assessment of metastases of functional tumours to the liver or lymph nodes if the original tumour site is unknown
— confirmation of the clinical symptoms of functional tumours
— immunohistochemical assessment of somatostatin receptors (e.g. SSTR2) for therapeutic purposes
— immunohistochemical assessment of vascular markers expression to examine angiogenesis

of a polyp with the morphology of a NET following its endoscopic excision (obligatory in the case of colonic NET), or surgical margins in the surgical material, is clinically useful. Pathomorphological diagnosis of a NEN should always be confirmed by immunohistochemical examination, including the assessment of expression of chromogranin A, synaptophysin, and the Ki-67 proliferation activity with the MIB1 antibody.

*evidence level according to OCEBM [274]

2. *The minimum histopathological report for the NEN surgical material should include:*

- *clinical data: anatomical location of the tumour, clinical symptoms in the case of functional neoplasms, and the name of the endoscopic or surgical procedure;*
- *macroscopic features: tumour description, including its location, cross-sectional appearance, relation to the surrounding tissue and surgical margins, according to the guidelines for the organ;*
- *microscopic features: description of the histoformative tumour structures and determination of the cell type, determination of the Ki-67/MIB1 proliferation index, and of the mitotic index according to the ENETS/WHO system (G1-G3), studied in the regions of the highest activity (hot-spot), and determination of histological maturity (G feature);*
- *description of histopathological parameters of tumour invasion: angiolymphatic invasion, nerve infiltration, presence of necrosis, invasion of the tumour capsule (pseudo-capsule), and determination of the depth of infiltration into the organ wall or adjacent tissue and organs;*
- *determination of immunohistochemical expression: obligatory CgA, synaptophysin, and Ki-67 with MIB1 antibodies, and conditionally, as ordered by clinicians, other hormonal markers;*
- *description of the tumour metastases, if present;*
- *description of surgical margins;*
- *description of other parameters, if present, such as inflammation, or another neoplastic component.*

3. *Diagnosis (pathomorphological diagnosis)*

The histopathological report should end with a diagnosis containing the following parameters:

- *type of neoplasm according to the WHO classification (obligatory);*
- *histological grade (G) according to the ENETS/WHO 2017 guidelines, updated by 2017 AJCC Cancer Staging 8th edition (obligatory);*
- *pTNM pathological staging according to the ENET and/or TNM AJCC/UICC criteria, with the year of edition (obligatory);*
- *polypectomy margins or surgical margins;*
- *assessment of the dominant cell type (conditional);*
- *preoperative secretion levels of insulin, gastrin, and serotonin (if secreted);*
- *suggested original tumour site in the case of hepatic tumours or metastases to the lymph nodes with unknown original NEN location (*evidence level 3).*

2.3. Diagnostic imaging

Diagnostic imaging of NENs is difficult due to their small size, often atypical location, and non-specific clinical symptoms. Therefore, it is necessary to use different imaging methods, both anatomical and functional.

The anatomical imaging methods include:

- ultrasonography (USG), especially endoscopic ultrasonography (EUS),
- computed tomography (CT),
- magnetic resonance imaging (MRI),
- endoscopy,
- capsule endoscopy.

Classical imaging methods (i.e. CT, USG, MRI) are useful primarily in the assessment of the stage of the disease, and monitoring of the response to treatment. They also play an important role in planning the surgical management of the primary tumour. Moreover, they enable the performing of a fine-needle or large-needle biopsy.

Over the last few years, endoscopic techniques have developed significantly. Their accessibility has also increased. Today, these methods enable the conducting of both diagnostic and therapeutic procedures.

An important achievement in the diagnostics of NENs was the introduction of scintigraphic examinations demonstrating the expression of somatostatin receptors (SRI, somatostatin receptor imaging). These are functional tests, which enable the characterisation of lesions on the molecular level [49, 50].

In Poland, ¹¹¹In-labelled somatostatin analogues are no longer used in the diagnostics of NENs. In clinical practice, commonly used are ^{99m}Tc-labelled agonists of somatostatin receptors: ^{99m}Tc-HYNIC-TATE and ^{99m}Tc-EDDA/HYNIC-TOC, both characterised by a similar sensitivity in the imaging of NENs [51].

Tests using these methods demonstrate a higher sensitivity in the diagnosis of primary tumours, as well as of osseous and pulmonary metastases.

Combined use of morphological and functional imaging techniques has improved the sensitivity and specificity of diagnostic methods in NENs [52–55].

Morphological and functional examinations are used in:

- assessment of the extension of the disease,
- locating the primary tumour,
- planning the surgical treatment,
- assessment of the response to treatment,
- qualification for radioisotope therapy.

2.3.1. Ultrasonography

2.3.1.1. Transabdominal ultrasonography

USG examination, due to its high availability and low cost, is usually the first imaging test performed. The sensitivity of the test depends on the tumour location, experience of the physician and on anatomical and technical conditions [1].

In clinical practice, USG examination is used mostly in the preliminary diagnostics of pancreatic endocrine tumours and of hepatic metastases. Due to technical

*evidence level according to OCEBM [274]

limitations, USG is not useful in the assessment of other parts of the gastrointestinal tract [1].

The image of NEN in a USG examination is non-specific. The tumour is often well-circumscribed, hypoechogenic, sometimes with a hyperechoic capsule, foci of necrosis, and calcifications. However, the tumour may also be hyperechoic or isoechoic. Most tumour foci in a Doppler examination demonstrate extensive vascularisation [1].

The sensitivity of transabdominal USG in the diagnostics of metastatic foci in the liver ranges from 82% to 88%, and specificity is between 92% and 95% [56]. The sensitivity of the method in the diagnosis of pancreatic tumours is much lower at 39% (17–79%) [47, 57, 58]. Using contrast material in the ultrasonographic diagnostics of NEN (contrast enhanced ultrasonography, CEUS) is very useful; 78–86% of tumour foci demonstrate contrast enhancement in the arterial phase. The sensitivity of CEUS in the diagnostics of hepatic metastases rises to 99% [59].

2.3.1.2. Endoscopic ultrasonography

Currently, the basic examination used in the diagnostics of NENs of the pancreas and rectum is endoscopic ultrasonography (EUS). The small distance between the source of the ultrasound and the object studied enables the use of ultrasonic waves of higher frequency than in a conventional USG device, which results in a much better image resolution [1].

Accepted indications for EUS include assessment of local advancement of neoplastic lesions in the gastrointestinal tract, diagnostics of submucosal lesions and of diseases of the pancreas and bile ducts. The examination enables visualisation of small-volume lesions, and assessment of regional lymph nodes. This method allows for precise determination of anatomical relations (i.e. tumour location relative to the bile ducts and main vessels) and assessment of the depth of gastrointestinal wall infiltration [1]. EUS examination is particularly useful in the diagnostics of pancreatic NENs (due to their typically small size). The sensitivity of the method depends on the location of the tumour: for tumours located in the head and body of the pancreas, it is approximately 90% (77–100%) [50, 52–55, 60], for tumours located peripherally it is 75–80% [47, 57]. The specificity of the method is estimated at 98% [61]. In the diagnostics of the neoplastic foci located in the pancreas in high-risk patients, EUS is more sensitive than CT [60].

Transrectal EUS is the most sensitive method for pre-operative assessment of the stage of rectal tumour advancement; its sensitivity in the assessment of the tumour and invasion of the rectum wall is 76–93%, and of the regional lymph nodes metastases it is 61–88% [62, 63].

Intra-operative ultrasonography

Intra-operative ultrasonography (IOUS) is used primarily to diagnose focal lesions in the pancreas. The sensitivity of this technique is 90% (74–96%), especially in combination with intra-operative palpation assessment [64, 65, 66].

Intraductal ultrasonography

Mini-probes may be introduced through the endoscope biopsy channel into the pancreatic duct or bile duct. This technique enables the assessment of the inside of the duct and of its wall (intraductal sonography, IDUS). It allows better visualisation, compared to EUS, of pancreatic NEN in the immediate vicinity of the pancreatic duct, and of the endo-luminal lesions. The sensitivity of this examination is approximately 94% [67], and it increases to almost 100% for lesions larger than 3 mm located in the pancreatic duct [68, 69].

2.3.2. Endoscopic examinations

Endoscopy is the basic method in the diagnostics of neuroendocrine neoplasms originating in the gastric or duodenal wall [70].

Using colonoscopy as a tool for colorectal cancer enables diagnosis of GEP NEN lesions in the colon and rectum. These are usually found accidentally, during examinations performed due to non-specific symptoms, such as dyspepsia or anaemia, or during screening tests. GEP NEN lesions are usually in the form of polypoid mucosal elevation, and only histopathological examination enables proper diagnosis to be achieved [4, 71]. The size of the lesion, degree of gastrointestinal wall infiltration, and potential presence of locoregional metastases determine the therapeutic strategy, and can be assessed based on an **EUS examination**. This test also allows specimens to be obtained for histopathological assessment [4, 72].

Panendoscopy (oesophago-gastroduodenoscopy, upper gastrointestinal endoscopy) and **colonoscopy with ileoscopy** are frequently the first examinations to be performed in patients with suspected or diagnosed NENs of unknown origin, after lymph node or hepatic metastases are found [1, 71]. This situation is especially common with neuroendocrine tumours originating in the small intestine. The location of the primary tumour site may be important for the choice of optimal management, despite a diagnosis based on the histopathological and immunohistochemical examination of the material obtained in targeted biopsy of the metastases.

In the case of any doubt, an upper gastrointestinal examination with an endoscope with lateral optics is recommended because it enables a better evaluation of the hepatopancreatic ampulla (ampulla of Vater)

*evidence level according to OCEBM [274]

area. A properly performed endoscopic examination in the search for the original tumour site in patients with hepatic metastases enables the detection of nearly 100% of primary lesions located in the stomach, and 86% of lesions in the large intestine [5, 73, 74].

Currently, **capsule endoscopy and enteroscopy** enable examination of the small intestine. Video Capsule Endoscopy (VCE), or Wireless Endoscopy, is a non-invasive examination of the small intestine performed with a single-use, wireless capsule. Swallowed by the patient, the capsule passively moves through the gastrointestinal tract, allowing the assessment of the small intestinal mucosa along its entire length. This examination does not substitute gastroscopy or colonoscopy. Contrary to a traditional endoscope, the current capsules are not steerable, so repetitive assessment of a chosen part of the intestine is impossible [5, 75, 76]. The limitation of capsule endoscopy is the run-time of its battery, which means that in some patients with disturbed peristalsis the latter part of the ileum may remain unexamined. The most common complication (0.75% of all patients) is capsule incarceration in the narrowing of the small intestine resulting from the use of non-steroidal anti-inflammatory drugs, or due to other diseases such as Crohn's disease. Also, small intestinal NENs, due to secreted growth factors which lead to desmoplastic reactions of the mesentery, may result in a significant intestinal narrowing [1, 77]. Current reports indicate a relatively low sensitivity of the test with the use of an endoscopic capsule in the detection of midgut lesions, especially in the detection of submucosal and eccentric lesions; the sensitivity is approximately 45%. Small intestinal tumours are diagnosed mostly by accident, during the diagnostics for gastrointestinal haemorrhage, for example [1, 7, 77, 78].

Balloon enteroscopy (single-balloon, double-balloon) or spiral enteroscopy [1, 79] enable assessment of the small intestine and obtaining tissue material for a histopathological examination with the possibility of endoscopic treatment. While conducting the examination, it is possible to use EUS with miniature heads with an external diameter of 2 or 2.6 mm, introduced through the enteroscope biopsy channel [1, 10, 80].

Capsule endoscopy and balloon enteroscopy are complementary methods. Non-invasive capsule endoscopy enables initial location of the tumour, while enteroscopy helps to obtain material for histopathological examination and to conduct therapeutic procedures [1, 79, 81].

Complete assessment of the small intestine via enteroscopy is achieved in approximately 80% of patients. The diagnostic effectiveness of the examination is approx. 55% [82–84].

2.3.3. Computed tomography

Computed tomography examination is currently the standard method to assess the location of tumour foci and to determine NEN staging. CT is also used to monitor the effects of treatment. However, this examination demonstrates relatively low sensitivity in locating the primary tumour site if the patient is not properly prepared for the test [1, 85].

Currently, spiral MDCT (multi-detector computed tomography) devices are in common use. Depending on the manner of filling the gastrointestinal lumen, the examination is referred to as CT enterography (if the patient receives low-absorption contrast material), or CT enteroclysis (if it is administered using a probe introduced into the small intestine). After proper filling of the gastrointestinal tract, a CT examination is performed before and after the administration of the contrast material. Scanning after intravenous administration of contrast should be conducted in two phases — arterial and portal venous, over all of intestines and of the liver to detect possible metastases [1].

Symptoms indicating malignancy of the tumour include: large volume, necrosis, and characteristics of infiltration of adjacent tissues (lesions occur in approximately 20% of patients). In the arterial phase, hyperdense lesions are most frequently found; rarely are they hypovascularised or cystic. In the portal venous phase, NETs are mostly hypodense lesions because the contrast material is quickly washed out [1].

The sensitivity of the CT examination in the diagnostics of pancreatic tumours is 73% (63–82%), and specificity is 96% (83–100%) [1, 86–88]. The test's sensitivity in the assessment of hepatic metastases is 82% (78–100%), and the specificity is 92% (83–100%) [1, 47, 89–91]. The sensitivity of the CT examination in the diagnostics of extrahepatic metastases is 75% (63–90%), and the specificity is 99% (98–100%) [1, 47].

In the monitoring of the response to treatment, it is recommended to apply both anatomic and functional methods as the sensitivity and specificity of individual tests is insufficient [92].

CT colonography

Computed tomography also enables virtual colonoscopy (VC). This method allows for three-dimensional imaging of the walls and content of the large intestine. For perfect 3D reconstructions, it is necessary to use a submillimetre layer thickness [1].

The patient requires proper preparation, similarly to traditional colonoscopy. The preparation consists of complete emptying of the large intestine from faecal masses and liquid (residual faecal masses may result in false-positives) [1, 93].

*evidence level according to OCEBM [274]

Full assessment of the examination includes the analysis of topical scan and axial cross-section images (treated as reference images), and the analysis of multiplanar and three-dimensional reconstructions (including 3D algorithms of the navigator type). A novel feature that improves the effectiveness of result interpretation is computer aided diagnosis (CAD) [1].

CT colonography is a safe and well-tolerated diagnostic method. The sensitivity and specificity of the method is comparable to classical colonoscopy.

The sensitivity of CT and endoscopic colonography is similar; according to different authors it is 90% for lesions > 10 mm and 85% for lesions > 6 mm; the sensitivity and specificity in the diagnostics of malignant neoplasms is 88–100%, and in benign neoplasms is 86% [94, 95].

The quality of the obtained images depends on patient co-operation and preparation [93].

2.3.4. Magnetic resonance imaging

The sensitivity and specificity of magnetic resonance imaging (MRI) are similar to CT in the diagnosis of the primary focus and metastases of NENs [96]. The examination protocol includes performance of the following images/sequences:

- T1-weighted (spin-echo, SE),
- T1-weighted with fat saturation,
- T1-weighted (gradient echo, GRE) after administration of the contrast material (dynamic and static examination), thin axial layers,
- 3D T1 GRE, with fat saturation — before and after *i.v.* administration of the contrast material,
- T2-weighted (fast spin-echo, FSE), T2-weighted with fat saturation [97],
- DWI with ADC mapping.

Tumours demonstrate a hypointense signal in T1-weighted images, and a hyperintense signal in T2-weighted images (rarely hypointense — if they contain a large fibrous tissue component), and they are strongly enhanced after administration of the contrast material. Cystic tumours with necrotic foci are ring-enhanced. 75% of metastatic foci in the MRI scan demonstrate a hypointense signal in T1-weighted images, most being strongly enhanced after administration of the contrast material. The MRI technique also enables a CT colonography-type examination to be conducted. The advantages and disadvantages of this method are similar to those of CT colonography [1].

MRI — following the optimal protocol — allows the diagnosis of 80–95% of metastatic foci in the liver [91, 95, 98, 99], and 73–93% of pancreatic NENs [91, 100]. In the diagnostics of extra-pancreatic and extra-hepatic foci, the test's sensitivity is much lower, i.e. 68–89% [101, 102].

Whole-body MRI is considered to be a second-line test in the assessment of hepatic metastases smaller than 10 mm, and in the assessment of foci with non-specific enhancement on the CT scan. It is also recommended in patients allergic to the iodine contrast agents used in CT imaging [1].

There are also studies describing the use of DWI sequence for whole-body examinations in patients with neuroendocrine tumours, as a particularly sensitive method in the detection of metastases [103, 104].

2.3.5. CT/MRI enteroclysis/enterography

Currently, to assess the small intestine, CT/MRI enterography/enteroclysis are used. These methods increase the CT sensitivity even to 100% [85, 105, 106].

The techniques enable the identification of even small, segmental thickening of the intestinal wall, small intramural nodules, and segmental narrowing of the lumen. The MRI examination provides better tissue resolution than CT; it enables assessment of intestinal wall layers and of the level of its infiltration by the tumour. The scope of the examination should include the field from the level of the liver to the pubic symphysis [1].

In CT/MRI enteroclysis, the contrast medium is administered through a probe introduced under fluoroscopic control beyond the duodenojejunal angle. An anti-reflux balloon prevents a reflux of the contrast material into the duodenum. After the contrast material has been administered, an MRI examination of the abdominal cavity is performed, using a surface coil. Fast T1-weighted and T2-weighted sequences should be performed (e.g. HASTE, FIESTA), as well as T2-weighted sequences with fat saturation, and examination after intravenous administration of the contrast material (T1-weighted images) should show the layers to be 3–5 mm thick. As a standard procedure, the patient should be in the supine position (the prone position is uncomfortable, and the patient cannot stay in it for long; therefore, it is rarely used, generally only if artefacts are present). In CT enteroclysis, following the filling of the intestinal lumen with a negative contrast medium (e.g. an aqueous Lactulose solution), an intravenous contrast material is administered, 1.5–2 ml/kg, at 3–4 ml/s. The test is performed in the arterial phase starting with the smart prep function with a 30–60-s delay (from 45 seconds — intestinal phase), the layers should be 1–3.0 mm thick [1, 85].

In CT/MRI enterography, the contrast material is administered orally, an hour before the examination. In MRI, intravenous administration of medicines slowing intestinal peristalsis is recommended (e.g. 1 ampoule of Buscolysin 20 mg in 1 ml; either intravenous or intramuscular administration are possible if the patient has no contraindications) [1].

*evidence level according to OCEBM [274]

MRI enteroclysis provides a better level of extension of the intestinal loops and the ability to assess peristalsis; however, the patient's tolerance to the test is lower compared to enterography. Sensitivities of CT enterography and enteroclysis are similar. Due to the long duration of the data acquisition process in MRI, enteroclysis is recommended for this test [1, 85]. Recent studies report that in MRI enteroclysis a sensitivity of 86–94% is achievable, and a specificity of 95–97% in the detection of small tumours in the small intestine [106].

The examination time in CT enteroclysis is shorter than in MRI enteroclysis. Therefore, the quality of the test is less dependent on co-operation with the patient. However, it is associated with the patient's exposure to ionizing radiation [1].

Minimal consensus on imaging examination:

*The choice of imaging examination depends on the primary focus location and the stage of the disease: USG, CT, MRI, endoscopy (*evidence level 3–4).*

Detailed tests for individual organs are discussed in later sections.

2.4. Radioisotope diagnostics

2.4.1. Radioisotope-labelled somatostatin analogues imaging

Radioisotope-labelled somatostatin analogues are the most sensitive method of diagnostic imaging for NETs. Somatostatin receptor imaging (SRI) is performed using scintigraphy (planar examination, SPECT, or SPECT/CT), or using positron emission tomography PET/CT. The sensitivity of SRI depends on the method (it is the highest in PET/CT examination). For most types of GEP NET and locations the SRI sensitivity images between 54 and 100% [107–115]. Insulinoma is an exception, as somatostatin receptor overexpression is found in 50–60% of cases [116].

Clinical indications for SRI are: location of the primary tumour, determination of the stage of the disease, monitoring of the patient following radical surgical treatment, assessment of the effectiveness of the applied treatment, and qualification of patients for antiproliferative treatment with SSA and targeted radioisotope therapy [1].

As the CLARINET study showed the antiproliferative effect of lanreotide in the presence of somatostatin receptors with an uptake at least comparable to that of the liver, an SRI should be performed before introducing antiproliferative SSA [117].

In 2017, a new classification for neuroendocrine neoplasms NEN has been introduced, comprising NETs G1, G2, and G3, and NECs [31–35]. Previously published data refer to NETs G1 and G2. There is no data available on the imaging of somatostatin recep-

tors in NETs G3. Considering the well-differentiated character of NET G3 neoplastic cells, it seems justified to conduct examinations using ^{68}Ga -somatostatin analogues for the diagnostics of this group. In the case of NECs, imaging examination of somatostatin receptors is not performed routinely; however, it may be useful before deciding on the introduction of SSA treatment.

2.4.1.1. Isotope diagnostics using indium-labelled ^{111}In -pentreotide (OctreoScan®)

In 1994, the USA Federal Drug Administration (FDA) authorised indium-labelled ^{111}In -pentreotide (OctreoScan®) for marketing. This compound demonstrates a high affinity to SSTR2, a much lower affinity to SSTR5 and SSTR3, and no affinity to SSTR1 and SSTR4 [1, 118]. The sensitivity of receptor scintigraphy with the use of ^{111}In -pentreotide is 54–86%, with an average of 80% [108, 109]. Currently, due to the higher sensitivity of tests with other tracers, lower dose absorption by the patient, and the duration and cost of the examination, in most centres the use of ^{111}In -pentreotide has been abandoned.

2.4.1.2. Diagnostics imaging with technetium-labelled somatostatin analogues ($^{99\text{m}}\text{Tc}$)

$^{99\text{m}}\text{Tc}$ -labelled somatostatin analogues are increasingly used in the radioisotope diagnostics of NETs [1, 112, 119–121]. The physical properties of $^{99\text{m}}\text{Tc}$ significantly increase the quality of imaging, compared to ^{111}In -pentreotide. Currently, the standard in imaging examinations is the WB-SPECT technique, including acquisition of the test in the SPECT tomographic technique using CT (WB-SPECT/CT) for attenuation correction, and for structural location with CT. The examination concerns structures similar to those in the PET technique.

Limited scientific reports demonstrate a higher sensitivity of the scintigraphic examination with the use of $^{99\text{m}}\text{Tc}$ -HYNICTOC compared to ^{111}In -pentreotide [122]. Due to the positive Polish experience with $^{99\text{m}}\text{Tc}$ -HYNICTOC (Tectrotide®) and $^{99\text{m}}\text{Tc}$ -HYNICTATE, scintigraphy with the use of ^{111}In -pentreotide has been completely substituted by this method in those centres that do not offer positron emission tomography, in Poland and in many other European countries [51, 120, 121]. This is due to shorter time of examination, lower patient exposure, and every day availability of $^{99\text{m}}\text{Tc}$ -HYNICTOC (Tectrotide®), and $^{99\text{m}}\text{Tc}$ -HYNICTATE in a nuclear medicine laboratory.

2.4.1.3. Diagnostics imaging with positron emitting tracer-labelled somatostatin analogues

Of all radioisotope examinations, scintigraphy using positron-emitting tracers offers the highest resolution. Literature data suggest higher sensitivity of scintigraphy

*evidence level according to OCEBM [274]

with somatostatin analogues labelled with positron emitting tracers (^{68}Ga) compared to the SPECT test with ^{111}In -pentreotide or $^{99\text{m}}\text{Tc}$ - HYNICTOC [1, 107–115, 123]. The somatostatin analogues currently in use include DOTATATE, DOTATOC, and DOTANOC, which differ in their affinity to individual SSTRs. The sensitivity, specificity, and diagnostic accuracy in PET examinations using ^{68}Ga -labelled somatostatin analogues are 97%, 92%, and 96%, respectively [1, 52, 124, 125]. The sensitivity of ^{68}Ga -DOTATATE PET/CT demonstrated in a meta-analysis comprising 10 studies was 90.9% (95% CI: 81.4%, 96.4%), and its specificity was 90.6% (95% CI: 77.8%, 96.1%) [115]. PET/CT with ^{68}Ga -labelled somatostatin analogues is particularly useful in the detection of the primary lesions, in the pre-operative exclusion of metastases, and in the assessment of somatostatin receptor expression before a planned radioisotope treatment. PET/CT with ^{68}Ga -labelled somatostatin analogues is more sensitive than a classical scintigraphic examination in the detection of occult or clinically suspected osseous metastases, which is the fourth most frequent location of metastases, or lymph node metastases. PET/CT with ^{68}Ga -labelled somatostatin analogues significantly affects the change of treatment in 13–71% of patients [107, 124, 126–128].

Moreover, in a PET/CT with Ga-DOTA somatostatin analogues, it is possible to measure the standardised uptake value (SUVmax). The SUVmax value is correlated with the density of somatostatin receptors present on the cell surface, which is crucial in establishing the patient's eligibility for the treatment with labelled somatostatin analogues (PRRT) [129]. Eligibility for PRRT includes patients with tumour/metastases uptake of at least the same intensity as that in the liver, i.e. a the Krenning score of 2 [130].

The reference organ used to obtain the value (the liver) demonstrates the lowest physiological accumulation rate of all organs [131].

Therefore, the best results for PRRT treatment are achieved when the uptake in the metastatic lesions is 2.2 times higher than in the liver, or SUVmax > 16.4 [132]. In centres with a PET scanner, examination with ^{68}Ga -labelled somatostatin analogues should be the test of choice.

Recently, 64-copper (^{64}Cu)-labelled SSA has also been used in examinations [133, 134]. Due to its longer half-life, ^{64}Cu enables images to be obtained even 24 hours after administration of the tracer. Currently, no conclusive data are available to demonstrate any advantage of ^{64}Cu -DOTATATE over the ^{68}Ga -labelled somatostatin analogues currently in use [134].

2.4.1.4. Intra-operative imaging of somatostatin analogues

Due to the use of intra-operative scintillation probes, it is possible to visualise somatostatin analogues intraope-

ratively. The examination is useful in the visualisation of the primary lesion, and in the detection of metastases to regional lymph nodes, significantly facilitating and shortening the surgical procedure. Intra-operative examination involves $^{99\text{m}}\text{Tc}$ - or ^{68}Ga -labelled somatostatin analogues [135, 136].

2.4.2. Radioisotope diagnostics with fluorodeoxyglucose ^{18}F FDG

So far, PET/CT with the use of radioisotope-labelled 18F-fluorodeoxyglucose (^{18}F FDG) was considered to be of limited value in the diagnostics of NETs, due to its low sensitivity. However, it has been demonstrated that collection of ^{18}F FDG in neoplastic foci is a significant negative prognostic factor, enabling a more precise characterisation of the biological tumor malignancy [137–140]. Results of PET/CT with ^{18}F FDG are positive in approximately 30% of NET G1, 60% of NET G2, and over 80% of NECs [141, 142]. A statistically significantly shorter progression-free survival (PFS), as well shorter overall survival (OS), were found in patients with positive ^{18}F FDG PET/CT result [138, 143]. An arbitrary value of SUVmax > 2.5 is frequently associated with a more aggressive course of the disease and should be the basis for prompt introduction of second line therapy [138].

Due to the diverse biological properties of neuroendocrine neoplasms, PET/CT with ^{18}F FDG and assessment of somatostatin receptor expression in SRI are necessary to properly qualify the patient for radioisotope treatment [138].

2.4.3. Radioisotope diagnostics with radioisotope-labelled dihydroxyphenylalanine ^{18}F -DOPA

PET diagnostics with dihydroxyphenylalanine (DOPA) labelled with fluorine-18 (^{18}F -DOPA) is a promising method in the imaging of NETs [1]. ^{18}F -DOPA PET/CT has demonstrated a sensitivity of 65–96% in the diagnosis of NETs [144–146]. However, the role of this examination is not conclusive [139, 146–148]. It would appear to be useful in the case of functional pancreatic tumours and in other GEP NETs, if SRI is negative [145, 148].

2.4.4. Diagnostics with radioisotope-labelled meta-iodobenzylguanidine $^{123/131}\text{I}$ -MIBG

Another tracer used in the diagnostics and therapy of NEN is guanidine derivative labelled with iodine, meta-iodobenzylguanidine ($^{123/131}\text{I}$ -MIBG), which is accumulated in cells via the VMAT1 and VMAT2 mechanism.

Imaging with the use of $^{123/131}\text{I}$ -MIBG is performed primarily in pheochromocytoma and neuroblastoma, and rarely in other neoplasms of neuroendocrine origin. The sensitivity of $^{123/131}\text{I}$ -MIBG scintigraphy in NETs is

*evidence level according to OCEBM [274]

approximately 50% (40–85%) and is lower than that with ^{111}In -pentreotide imaging [149, 150]. The best results are achieved using ^{123}I -MIBG in the visualisation of hepatic metastases. However, in this case, receptor scintigraphy is more sensitive [150]. Therefore, $^{123}/^{131}\text{I}$ -MIBG scintigraphy is currently primarily performed in patient qualification for isotope ^{131}I -MIBG treatment, if SRI is negative [1].

2.4.5. Other radioisotope tracers

Apart from the above radiotracers, numerous studies are currently being conducted, such using like ^{11}C -5-hydroxytryptophan (^{11}C -HTP), or other new receptor tracers such as glucagon-like peptide-1 (GLP1) analogues in the case of insulinoma, and gastrin or bombesin analogues in the case of medullary thyroid carcinoma [151–155].

Particularly promising are the GLP-1 analogues in the diagnostics of insulinoma. GLP-1 analogues labelled with ^{111}In , $^{99\text{m}}\text{Tc}$, and ^{68}Ga have been used in several studies [151, 153, 155]. The initial results indicate the lack of GLP-1 receptor expression in the majority of malignant insulinomas (where usually SRI is positive), which suggests the usefulness of imaging with labelled GLP-1 analogues in the differentiation of benign and malignant forms of insulin tumours [151, 153].

However, due to limited availability, these tracers are not used in routine diagnostics.

Minimal consensus statement on radioisotope examinations:

- Somatostatin receptor radioisotope imaging (SRI) using PET/CT with radiolabelled somatostatin analogues with ^{68}Ga , and in those centres which do not have a PET scanner — SPECT/CT (SPECT) with $^{99\text{m}}\text{Tc}$ radiolabelled somatostatin analogues; for determination of the primary tumour site, assessment of the disease stage, assessment of the treatment results, and qualification for PRRT therapy/antiproliferative treatment with SSA (*evidence level 2).
- ^{18}F FDG- PET/CT for NECs, in qualification for radioisotope treatment and for rapidly growing NETs (*evidence level 3).

3. Treatment

3.1. Surgical treatment

In GEP NENs the treatment of choice is surgical management, the scope of which depends on the patient's general condition and on tumour location, stage, and specificity (biology) of the neoplasm (*evidence level 4) [1, 6].

Unlike in most frequent gastrointestinal adenocarcinomas, due to the diverse biology and clinical presentation of GEP NENs, methods used for their treatment and indications for their surgical management in differ-

ent parts of the gastrointestinal tract will be discussed in detail in the following sections of this document.

Tumour diameter is one of the main parameters when deciding on the treatment of non-functional GEP NENs (especially NETs G1 and G2). Small lesions (tumour size limits are determined for individual organs) may be treated conservatively or observed, whereas larger neoplasms should be treated surgically, with removal of the lymph nodes [156]. Functional tumours should be resected regardless of the size of the lesion.

In GEP NENS, in particular NET G3 and NECs, i.e. neuroendocrine tumours with a proliferation index of over 20% (Table V), the same management principles should be applied as in other malignant gastrointestinal neoplasms [157]. In clinical stages I, II, and III, radical therapy (with the intention to cure) is applied. In clinical stage IV, when the neoplasm dissemination (distant metastases present, e.g. in the liver or lungs), palliative treatment can be introduced to improve the quality of life and/or extend patient survival.

In stage IV G1-G2 GEP NETs with M1 feature in the liver the surgical procedure does not have to be tantamount to palliative treatment [158]. Radical resection of the primary tumour and hepatic metastases can have a curative effect and is the best therapeutic option [159] (*evidence level 2). Resection of the metastases should be accompanied by removal of regional lymph nodes [158].

Cytoreduction of hepatic metastases should be considered in patients with functional tumours and uncontrolled symptoms, and in patients with non-functional tumours and symptoms related to the tumour, if the disease is stable for over 6 months. Cytoreduction is indicated for better symptom control, especially if the tumour mass can be reduced by 90% [158, 160] (*evidence level 2). If metastases cannot be resected, ablation techniques should be considered (embolisation, chemoembolisation, RFA, and SIRT) [158]. The principles of treatment of NEN metastases to the liver are presented in Figure 2 [161].

In the case of NENs with a proliferation index above 20%, especially above 55%, and with advanced metastases, resection, cytoreduction, or ablation of the hepatic metastases are not recommended [157].

A specific form of palliative treatment of NET is cytoreductive therapy, which consists of reduction of the neoplasm mass in order to reduce the symptoms and obtain better effects of systemic treatment if hepatic metastases are present [156].

Resection of stage IV primary tumour with non-resectable hepatic metastases is under consideration [162] (*evidence level 3).

*evidence level according to OCEBM [274]

3.1.1. Indications for liver transplantation in GEP NETs

Liver transplantation in patients with GEP NET should be considered if non-resectable neoplastic lesions are found in the liver parenchyma, both primary and metastatic. This method of treatment is also indicated in patients with hepatic recurrence of neoplastic disease, after liver resection, ablation therapy, or systemic treatment due to GEP NET [1, 163]. Liver transplant may be performed in the case of symptomatic or non-symptomatic tumours [1, 164, 165].

Qualification for liver transplantation depends on confirmation of exclusively hepatic location of the metastases of the primary GEP NET (no extra-hepatic metastases in imaging examinations, PET/CT, or diagnostic laparoscopy/laparotomy) and on its histopathological grade of G1 or G2 according to the WHO classification system [164] (*evidence level 3). Prior to liver transplantation, removal of the primary focus is also recommended (especially in the case of pancreatic NET). It should be noted that a Ki-67 of < 10% provides the most favourable prognosis (*evidence level 3) [164, 166]. The viability of qualification of young patients and those who have exhausted the options of symptomatic treatment is emphasised [158].

Adverse prognostic factors for survival include infiltration of the large hepatic vessels and simultaneous resection of the neoplasm outside the liver [166].

Minimal consensus statement of surgical management:

- In GEP NETs, the treatment of choice is surgical management, the scope of which depends on the patient's general condition and on the location, stage, and biology of the neoplasm (*evidence level 4).
- Tumour diameter is one of the main parameters when deciding on the treatment of non-functional GEP NETs (G1, G2). Small lesions may be treated conservatively or observed, whereas larger neoplasms should be treated surgically, with removal of the lymph nodes (*evidence level 2). Functional tumours should be resected regardless of the size of the lesion.
- In the case of GEP NETs G1-G2 with metastases in the liver, radical resection of the primary tumour and the hepatic metastases is the best therapeutic option. Resection of the metastases should be accompanied by removal of the regional lymph nodes. In NET G3 and NECs, the same principles of oncological management should be applied as that in other gastrointestinal neoplasms. In the case of NENs with a proliferation index above 20% and with advanced metastases, resection, cytoreduction or ablation of the hepatic metastases are not recommended (*evidence level 3).
- Cytoreduction of hepatic metastases should be considered in patients with functional tumours and uncon-

controlled symptoms, and in patients with non-functional tumours and symptoms related to the tumour, if the disease is stable for over 6 months. If metastases cannot be resected, ablation techniques should be considered.

- A form of palliative treatment for GEP NETs is cytoreductive therapy which consists of the reduction of the neoplasm mass in order to reduce the symptoms and obtain better effects of systemic treatment if hepatic metastases are present (*evidence level 3).
- Liver transplant should be considered in certain patients with non-resectable G1 or G2 GEP NETs in the liver parenchyma, if metastases outside the liver are not found (*evidence level 3).

3.2. Endoscopic treatment

The main purpose of the treatment of GEP NENs is complete removal of the tumour, and, in the case of functional tumours, also control of the clinical symptoms associated with the production of specific hormones [1].

Although the basic method of radical treatment is surgical resection, technological progress in endoscopic equipment and development of new therapeutic endoscopic techniques justify the use of this treatment in certain cases. This is possible mainly due to the introduction of methods such as endoscopic ultrasonography which enables precise assessment of the gastrointestinal tract wall and its individual layers with surrounding structures, and adequate qualification of patients for endoscopic or surgical procedures, as well as endoscopic mucosal resection (EMR) and endoscopic submucosal dissection (ESD) [1, 167–169]. The therapeutic approach to GEP NENs located in the upper gastrointestinal tract and in the large intestine, often detected during diagnostic endoscopic examination, depends on the tumour size, depth of invasion, and the presence of metastases at the diagnosis. Endoscopic resection of GEP NENs may be used as a treatment method only in well-differentiated G1 and T1 tumours, according to the TNM classification. Before deciding on endoscopic treatment, endosonographic examination is necessary to determine the size of the lesion and the depth of infiltration into the gastrointestinal tract wall, as well as to assess the regional lymph nodes. The test may be completed with fine-needle biopsy of the primary lesion and lymph nodes. Only lesions limited to the mucosa and submucosa qualify for endoscopic removal, while in all other cases local or radical surgical excision is recommended, possibly with supporting therapy or chemotherapy [1].

It is estimated that approximately 20% of gastric NENs, 10% of duodenal NENs, and as many as 70% of rectal tumours qualify for endoscopic removal [170].

*evidence level according to OCEBM [274]

Classical polypectomy performed with the use of electrocoagulation loop is not recommended as a therapeutic method in GEP NENs, as it often leaves a positive margin after the procedure. The optimum method is endoscopic mucosal resection or endoscopic submucosal dissection. Endoscopic resection conducted by the injection and cut technique consists in lifting of the lesion from the muscular layer of the wall by injection of a substance to create a “bubble” under the lesion, and in subsequent removal of the lesion with a diathermic loop. Lifting of the lesion is a condition for qualifying for this procedure; the absence of this phenomenon (non-lifting sign) indicates infiltration of the deeper layers of the gastrointestinal tract wall, and is a contraindication for endoscopic resection. Other EMR techniques include injection, lifting and section (strip biopsy), endoscopic mucosal resection with ligation (EMR-L) or cap assisted endoscopic mucosal resection (EMR-C). Lesions limited to the mucosa, well-differentiated, convex, smaller than 2 cm and without ulceration qualify for endoscopic resection [1, 171].

Endoscopic submucosal dissection is a technique which enables the removal of lesions of diameter greater than 3 cm in one piece (en-block) within the normal tissue. It involves marking by means of electrocoagulation of the mucosa surrounding the lesion, injecting a solution into the submucosal membrane and lifting the lesion above the muscularis propria, performing a circular dissection of the lamina propria mucosa around the lesion, and removing the lesion together with the submucosal membrane [172–176].

The most common complications following mucosal resection and endoscopic submucosal dissection are haemorrhage (up to 7%) and perforation (5%). They are more frequent in duodenal or gastric lesion removal than in rectal lesions. A submucosal dissection, compared to mucosal resection, is characterised by a higher size-independent ratio of the lesions removed en-bloc (OR 13.87), and a lower local recurrence ratio (OR 0.09), but this technique takes longer to perform and leads to a higher rate of complications (haemorrhage OR 2.2; perforation OR 4.09) [177]. Due to the higher rate of R0 resections, ESD should be the method of choice in the endoscopic treatment of NENs [178].

The radicality of an endoscopic procedure is determined by the following histopathological criteria: complete removal of the lesion (negative margins), absence of angioinvasion, as well as low mitotic activity and low proliferation index. In the majority of cases further surveillance is recommended after endoscopic treatment, although detailed monitoring principles have not been established in all cases [179].

Endoscopic methods can also be used in palliative treatment of NEN in the case of:

- mechanical jaundice due to pressure on biliary ducts (prosthesis of the biliary ducts);
- obstruction of the gastrointestinal tract (prosthesis of the gastrointestinal tract);
- gastrointestinal bleeding (endoscopic methods for stemming bleeding);
- pain (EUS-controlled solar plexus neurolysis);
- functional tumours with clinical symptoms (EUS-controlled ablation in patients at high risk of surgical treatment) [180, 181].

Minimal consensus statement for endoscopic treatment:

- *In certain clinical situations (a well-differentiated gastric, duodenal, and rectal G1 and T1 tumour, according to the TNM classification), endoscopic methods such as endoscopic mucosal resection (EMR) and endoscopic submucosal dissection (ESD) may provide a beneficial alternative to surgical treatment. Endoscopic ultrasonography (EUS) enables precise assessment of the gastrointestinal tract wall and its individual layers with surrounding structures, as well as adequate qualification of patients for endoscopic or surgical procedures.*
- *Endoscopy also enables palliative treatment of mechanical jaundice due to pressure on the biliary ducts, obstruction of the gastrointestinal tract, gastrointestinal haemorrhaging, pain (EUS-controlled solar plexus neurolysis) and, in special cases, ablation of functional tumours causing clinical symptoms (*evidence level 3).*

3.3. Systemic therapy

3.3.1. Somatostatin analogues

Introduction of SSA marked the greatest progress in the treatment of well-differentiated GEP NETs [182–185]. Basic indications for SSA therapy include:

A. Symptomatic treatment of functional GEP NETs

- SSA are the ‘gold standard’ in the treatment of functional tumours; these medications reduce the secretion of hormones and biologically active substances, control the symptoms of the disease, and significantly improve the quality of life [1].
- In long-term treatment octreotide LAR (10–30 mg i.m. every 4 weeks, but the lowest dose is rarely used), and lanreotide Autogel (60–120 mg s.c. every 4–6 weeks, but the lowest dose is rarely used), are recommended. Treatment effectiveness is monitored primarily on the basis of clinical symptoms.
- Therapy with long-acting SSA is the treatment of choice for the following syndromes: carcinoid syndrome, glucagonoma, VIP-oma (*symptomatic treatment in these syndromes is presented in guidelines for pancreatic and small intestinal NENs*) [156].

*evidence level according to OCEBM [274]

- SSA are not first-line therapy in insulinoma (diazoxide is initially used to control hypoglycaemia) or gastrinoma (in the treatment of ulcer disease, high doses of PPI are used). In malignant forms of insulinoma and gastrinoma, using SSA as the second-line therapy, may be effective in reducing symptoms of the disease (*see p. 79–110*) [186].
- Short-acting SSA (octreotide, solution for injections 100 µg/amp) are still used if prompt control of clinical GEP NET symptoms is required (including carcinoid crisis), in the perioperative period or in certain cases before introducing a treatment with long-acting analogues, in order to assess drug tolerance (*see NENs p. 223–236*) [156].

B. Stabilisation of the disease in GEP NEN patients

- In antiproliferative treatment, octreotide LAR (30 mg i.m. every 4 weeks), or lanreotide Autogel (120 mg s.c. every 4 weeks) is recommended [187].
 - Antiproliferative effects of SSA have been confirmed in two randomised, double-blind, placebo-controlled, phase three studies: PROMID and CLARINET [188, 189].
 - PROMID involved 85 patients with well-differentiated, functional, and non-functional, metastatic midgut NETs. Using octreotide LAR 30 mg at 4 week intervals extended the mean progression-free survival, and after 6 months of therapy the disease was stabilised in approximately 67% of patients, regardless of NET hormonal activity. The median time to tumour progression (TTP) was assessed at 14.3 months, compared to six months in the control group. The most beneficial effect was stabilisation of the tumour growth, reflected in extended PFS. The response to treatment in functional and non-functional NETs was similar; however, patients who underwent resection of the primary lesion, and those with hepatic metastases mass < 10% demonstrated better responses to antiproliferative treatment. On the basis of the PROMID study, octreotide LAR (30 mg i.m. at 4 week intervals) was registered for the treatment of patients with advanced NETs originating in the midgut or with unknown original site [188].
 - The CLARINET study involved 204 patients with non-functional NETs G1 and G2 (Ki-67 < 10%). The primary location of the NETs was the pancreas (45%), midgut (36%), hindgut (7%), or unknown (13%). Two-year treatment with Lanreotide Autogel 120 mg every 4 weeks demonstrated the absence of disease progression or death in 65% of the treated patients, compared to 33% of the placebo patients. Lanreotide statistically significantly increased the median PFS (progression-free survival) vs. placebo (mean PFS was not achieved in the treatment group, compared to 18 months in the placebo group). Increased median PFS was observed in patients with non-functional NETs G1 and G2 (Ki-67 < 10%) originating in the midgut and pancreas, regardless of the hepatic metastases volume of ≤ 25% and > 25%. The hazard ratio (HR) was 0.47, which means reduced risk of disease progression or death in 53% of patients treated with lanreotide. Based on the CLARINET study, Lanreotide Autogel (120 mg s.c. every 4 weeks) was registered for the treatment of non-functional gastro-entero-pancreatic neuroendocrine tumours (GEP-NET) G1, and certain G2 tumours (Ki-67 index up to 10%) of the midgut (including the small intestine), of the pancreas, or of unknown origin, in adult patients with non-surgical, locally advanced, or metastatic tumours [189–191].
- On the basis of on this study, the Polish Network of Neuroendocrine Tumours experts, following the 2016 ENETS guidelines, decided that SSA can be used in a stable or progressive disease or in patients with NENs of undetermined course.
- SSA are recommended as the first-line therapy in midgut and pancreatic NET. Octreotide is recommended for the control of midgut NET G1 with low hepatic tumour load, while lanreotide is recommended in midgut and pancreatic NET G1 and G2 (Ki-67 index up to 10%) irrespective of hepatic tumour load (**evidence level 1*) [158].
- General comments on the therapy with SSA:
- SSA are usually well-tolerated, and associated adverse reactions are rare. Initial adverse effects, such as: discomfort in the abdominal cavity, flatulence or steatorrhoea, usually disappear spontaneously within a few weeks, or during symptomatic treatment (e.g. pancreatic enzyme preparations). Other side effects include impaired glucose tolerance and cholelithiasis, and occur in 20–50% of patients (rarely symptomatic). Therefore, if surgical treatment and long-term pharmacotherapy with long-acting SSA are planned, cholecystectomy should be considered [1, 12].
 - Withdrawal of SSA before planned SPECT receptor examination or PET/CT is recommended for 4 weeks in the case of long-acting products, and for 24–48 hours in the case of short-acting products. The treatment with SSA should be completed before the planned administration of PRRT. A 5-week discontinuation is recommended for long-acting products, and 24-hour discontinuation for short-acting forms.

*evidence level according to OCEBM [274]

Minimal consensus statement of the treatment with somatostatin analogues:

*Therapy with somatostatin analogues is the treatment of choice in patients with functional and non-functional GEP NENs, in disease stabilisation or progression phase, preferably in patients with low Ki-67 proliferation index (*evidence level 1).*

3.3.2. Interferon alpha

Interferon alpha (INF- α) is used in similar indications as SSA [1]. Due to the larger number of adverse reactions, it is used as second-line treatment to control the clinical symptoms of functional tumours. Antiproliferative INF- α therapy may be indicated for GEP NENs with a proliferative index lower than 2–3% [191]. Due to limited availability in Poland, there is no previous experience of using INF- α for GEP NEN management.

3.3.3. Chemotherapy

Chemotherapy (ChTh) is one of many therapeutic options in gastrointestinal NENs.

In GEP NEN patients it is primarily determined by the histological properties of the neoplasm (histological grade G, Ki-67%), its primary site, disease dynamics, and patient's general condition, as well as comorbidities [1]. The use of chemotherapy is limited in well-developed neuroendocrine neoplasms, but it is the fundamental therapy in poorly differentiated and aggressive cancers.

Adjuvant chemotherapy

In gastrointestinal G1 and G2 neoplasms, there are no indications for adjuvant therapy following surgical treatment.

In NET G3, given the high recurrence rate after radical surgical treatment, adjuvant platin- and etoposide-based therapy should be considered and, in certain cases, also in combination with radiotherapy, although there is no conclusive evidence to support such management [5, 155].

Combined treatment may be considered in patients following radical resection of locally advanced NECs, e.g. of the oesophagus, stomach, or rectum; however, the decision should be made on an individual basis [5].

It should be emphasised that there is no conclusive evidence from controlled clinical trials supporting the effectiveness of adjuvant therapy in G3 neuroendocrine neoplasms, but merely indications from data provided by individual centres, on which this expert opinion is based (*evidence level 5).

Palliative chemotherapy

In patients with well-differentiated and moderately differentiated neoplasms (NET G1 and NET G2) chemotherapy

may be considered only as palliative management in the case of primary generalisation of the neoplastic disease (metastatic phase), impossibility of radical surgical treatment (locally advanced process), or non-radicality (following cytoreductive treatment), as well as in the recurrence of the disease after a radical treatment with a massive diffusion. The most important eligibility criterion for palliative chemotherapy is the symptomatic character of the disease and/or its dynamics, and good general condition of the patient (WHO/ECOG 0-2).

Palliative systemic treatment of NETs G1 and G2 should be considered in the following cases:

- moderately differentiated NENs with signs of progressive disease, with large tumour mass, threatening organ sufficiency, and a relatively high proliferation index: Ki-67 > 10% (NET G2);
- locally advanced pancreatic neuroendocrine neoplasms NET G2 with Ki-67 5–20% in order to enable resection of the lesion;
- progressing* well- or moderately-differentiated neoplasms of NET G1, NET G2, before and/or after surgery, and if previously implemented treatment methods failed (biological/radioisotope/locoregional/targeted therapies).

(*the proposed criterion is progression according to the RECIST score, compared against test results over the last 12 months).

In the absence of clinical symptoms nor risk of organ insufficiency, confirmation of disease progression according to the RECIST criteria within a maximum period of one year, may be a relative eligibility criterion. RECIST progression over more than a year is not treated as an independent indication for chemotherapy [1, 5, 192].

It should be emphasised that chemotherapy is generally moderately effective in NET G1 and NET G2. In each case of advanced well-differentiated/moderately-differentiated GEP NEN, before deciding on chemotherapy, palliative local treatment of the primary lesion and/or metastases: excision (of the primary lesion and/or certain resectable metastases), removal of metastases (thermoablation, radio frequency (RF) ablation, NanoKnife) and palliative local techniques (radioembolisation and CT-controlled brachytherapy), or less toxic methods of systemic management, should be considered (biotherapy with cold SSA, peptide radioisotope therapy with hot SSA — PRRT — targeted therapy). The above suggestions are based on the opinion of experts, on international guidelines, and recommendations regarding treatment of GEP NETs (*evidence level 4).

The effectiveness of chemotherapy on well-differentiated or moderately-differentiated GEP NETs (NET G1 and NET G2) is considerably higher in the

*evidence level according to OCEBM [274]

neoplasms of pancreatic origin than in those from other sites [193].

Indirect comparison of the results of clinical studies involving patients with GEP NENs demonstrates a higher probability of response in patients treated due to pancreatic NENs (43–70% compared to 5–15% in GEP NENs in other locations) [195, 196]. Interpretation of the results of previous studies is difficult due to the heterogeneity of the groups of patients regarding prognostic factors and the criteria used to assess the response (several studies involved patients who were not stratified according to the level of tumour differentiation; a high number of patients with poorly differentiated tumours [G3] was likely included: in earlier analyses the radiological assessment of the response to chemotherapy was suboptimal from today's objective response rate [ORR] perspective) [196].

Multi-drug regimens using streptozocin (STZ) and 5-fluorouracil (5-FU) or doxorubicin (DOX) are more effective compared to monotherapy, considering the response and survival rates (ORR — 42.7%, median overall survival [OS] — 15–30 months). Currently, three-drug regimens, especially with the use of cisplatin, are not recommended, due to the high risk of complications [197–199].

The effectiveness of streptozocin-based treatment was confirmed in a phase III study [196] involving 69 patients with pancreatic neuroendocrine neoplasms, after using the STZ + DOX regimen vs. STZ + 5-FU. The obtained response rate (RR) was 69% vs. 45%, respectively, the mean response time was 18 vs. 14 months, and median overall survival (OS) was 26 vs. 18 months [200]. However, the use of doxorubicin is limited to a cumulative dose of 500 mg/m², due to the risk of cardiotoxicity [156].

Currently, in the therapy of pancreatic NET G1/G2, most expert recommendations suggest using streptozocin as the main cytostatic agent in a two-drug regimen, as it demonstrates optimum effectiveness/toxicity ratio. The most recent retrospective analysis of a German team, based on of 96 patients, including 79.2% with G2 neoplasms and 6.3% with G3 neoplasms, treated between 1998 and 2014, and monitored on the basis of CT/MR examinations, with (re-)assessment according to the RECIST 1.0 criteria, demonstrated high efficacy of combined streptozocin + 5-fluorouracil (STZ 500 mg/m² + 5-FU 400 mg/m², day 1–5, ever 5–6 weeks), and acceptable tolerance of the treatment. At the start of the treatment as many as 25% of patients did not show radiological signs of neoplasm progression (as a new diagnosis). In 44% of patients the therapy was a second-line or later-line treatment. However, in most cases (93.7%) it was first-line palliative therapy. In the whole group of patients, the objective response rate was

42.7%, disease stabilisation was obtained in 40.6%, and time to progression was estimated at 19.4 months. In 23% of the patients, long-term stabilisation was observed over 2 years. Patients with Ki-67 < 15% demonstrated a slightly higher (but not statistically significant) response rate, RR, of approx. 45%. In a small group of patients with Ki-67 15–40%, the response rate was lower (RR 25%). Adverse effects typical for this regimen were observed: apart from haematological toxicity, 36% of patients complained of nausea/vomiting, in 23% the fatigue syndrome was observed, in 17% symptoms of mucositis, in 14% diarrhoea, in 12% paraesthesias, and 25% of patients demonstrated renal impairment, of whom chronic impairment was stated in 4% of patients [197].

In pancreatic NENs, STZ + 5-FU is still considered the standard treatment, although there are no randomised studies comparing STZ-based regimens with other therapies (radioembolisation, other chemotherapy regimens, PRRT or targeted therapies). It is worth noting that STZ is not registered in Poland, and is not easily available at present. The treatment of pancreatic NENs using new regimens based on capecitabine and temozolomide (CAPTEM) can be considered, following the recommendations of the European Neuroendocrine Tumour Society (ENETS), as an alternative regimen, depending on the availability of STZ/5-FU. On the basis of on small, prospective and retrospective studies with the use of temozolomide in combination with antiangiogenics or capecitabine, the response rates (RR) range between 15% and 70% [195, 202, 203]. The value of temozolomide administered as monotherapy or in combination with capecitabine or antiangiogenic agents is still being assessed in prospective clinical studies. It appears that a higher objective response rate following the use of alkalisating drugs, including temozolomide in pancreatic NENs may be correlated with the expression of the DNA-fixing enzyme — MGMT (O6-methylguanine DNA methyltransferase). Deficiency of this enzyme is more often observed (in approx. 50%) in neuroendocrine neoplasms of the pancreas than in neuroendocrine tumours of the small intestine [205–207]. However, determination of MGMT expression or methylation status is not currently recommended as a criterion for the choice of chemotherapy, due to lack of standardised methods of MGMT determination, and to lack of prospective clinical studies [156].

In patients with pancreatic NENs, after failure of the first-line therapy, there are several options for a systemic therapy available for patients in good general condition:

— in the case of progression with STZ, temozolomide +/- capecitabine (CAPTEM) is considered as second-line treatment;

*evidence level according to OCEBM [274]

— if CAPTEM is used as first-line treatment (if STZ is unavailable), after progression, chemotherapy with oxaliplatin + 5-FU or capecitabine.

The effectiveness of oxaliplatin-based chemotherapy in the available studies was from 17% to 30%, and stabilisation was achieved in 50–67% of patients. However, the studies involved very small groups of patients, and require further confirmation [208].

Due to the limited number of studies and their contradictory results it is difficult to assess the actual value of chemotherapy in patients with well-differentiated and moderately differentiated GEP NENs located outside the pancreas. In some expert recommendations chemotherapy is not listed as a therapeutic option in this indication as the objective response rates (ORR) are limited. Systemic chemotherapy is not recommended for extrapancreatic NETs, except in the case for biologically aggressive tumours, after other treatment methods have been exhausted. If the treatment is to be considered, two-drug regimens are used, analogous to those used in pancreatic neuroendocrine neoplasms. In clinical practice, the regimen with doxorubicin and 5-fluorouracil, doxorubicin, streptozocin, or decarbonize is usually chosen (**evidence level 4*) [208, 209], or an entirely oral regimen of temozolomide and capecitabine (CAPTEM) [211]. The effectiveness of combined oxaliplatin and 5-fluorouracil derivatives [212], or irinotecan and 5-fluorouracil [213] has been indicated in some reports.

Poorly differentiated neoplasms — neuroendocrine cancers

Chemotherapy is the basic method of palliative treatment in advanced, poorly differentiated NECs. Poorly differentiated, aggressive GEP NECs with a high proliferation index constitute over 10% of all neuroendocrine neoplasms. Their rapid growth makes them more sensitive to cytotoxic treatment than well-differentiated neoplasms, but their prognosis is much worse. The treatment of choice in the case of poorly differentiated GEP NECs is cisplatin and etoposide-based CTH, which enables a response of 42–70% to be obtained in patients (including complete response in 20–25% of patients), with a response time rarely longer than 10 months, and median overall survival ranging from 15 to 19 months [214, 215]. According to the results of NORDIC NEC, cisplatin can be substituted by carboplatin [216] (**evidence level 3*).

Currently, the significant heterogeneity of neuroendocrine cancers is emphasised. Some of them are biologically closer to small-cell neoplasms with TP53 mutations, with a high proliferative fraction (Ki-67 80–90%) and high chemosensitivity — they should be treated similarly to small-cell lung cancer (G3b). Some demonstrate lower chemosensitivity, a less

dynamic and aggressive course, and are associated with DAXX/ATRX mutations (G3a). On the basis of a retrospective data analysis in the Nordic study, it is suggested that the two populations can be differentiated on the basis of Ki-67 (cut-off point at 55%), while other studies indicate the significance of morphological structure (small- vs. large-cell cancer). In patients with G3a neoplasms one may use less aggressive chemotherapy regimens may use: capecitabine + temozolomide (CAPTEM), oxaliplatin + capecitabine (CapOX/XELOX); however, this is speculation only, unsupported by scientific evidence (**evidence level 5*) [216–218].

In the NORDIC study, patients with Ki-67 > 55% demonstrated a higher response rate than the patients with Ki-67 < 55% (ORR 42% and 15%, respectively), but shorter survival (OS 10 and 14 months, respectively). Analysis of the 305 patients in this study revealed the following adverse prognostic factors: low physical fitness (WHO/ECOG > 2), primary tumours located in the large intestine and rectum, and increased blood platelet count or concentration of lactic dehydrogenase (LDH). All those factors were associated with shorter overall survival (OS) [216].

Clearly, in neuroendocrine cancers, escalation of chemotherapy beyond the two-drug regimen is not justified. A third cytostatic agent (e.g. paclitaxel), tested only in very small series, results in better response, but significantly increased toxicity [219]. In clinical practice, it is not recommended to use other regimens than cisplatin/carboplatin + etoposide (e.g. cisplatin and irinotecan, or oxaliplatin and fluorouracil) as the first-line treatment, unless dictated by the toxicity profile regard to the patient's comorbidities.

Data regarding second-line chemotherapy after progression on PE/CE (cisplatin + etoposide/carboplatin + etoposide) are limited.

Second-line therapy may be considered individually, only in patients with good function levels [155] (**evidence level 4*).

Topotecan proved to be ineffective in the therapy of NECs G3 [216]. Regimens based on oxaliplatin (FOLFOX, XELOX), temozolomide (CAPTEM), [218] or irinotecan (FOLFIRI, IP) are recommended [220–223], as they enable 23–40% response rates to be achieved (**evidence level 4*).

In the case of good response to first-line chemotherapy, maintained for at least 3 months after completion of the treatment, and without therapy-related toxicity (e.g. neurotoxicity, ototoxicity, or renal failure), reinduction with platin derivatives following the PE/CE regimen (cisplatin + etoposide/carboplatin + etoposide) may be considered.

*evidence level according to OCEBM [274]

In the case of pancreatic and gastrointestinal NET G3 and NEC (well- and moderately differentiated tumours with Ki-67 > 20% to 55%, which are to be specifically identified according to the new 2017 AJCC/ UICC classification), the preferred treatment method is chemotherapy with temozolomide and capecitabine (CAPTEM). Other drugs used in the treatment of these cases include taxanes [224].

Minimal consensus statement of the systemic chemotherapy:

- In patients with NET G1 and G2 chemotherapy may be considered only in advanced stages. It depends on the histological characteristics of the NET (level of neoplasm differentiation), its primary location, dynamics (with a significant disease progression within ≤ 6 –12 months), the patient's general condition (WHO/ECOG 0–2), and comorbidities. The main eligibility criterion for chemotherapy is the symptomatic character of the disease or very dynamic progression, especially in NET G2 or NENs without SSTR expression.
- Advanced NET G1/2 of the pancreas requires individualised treatment, depending on the proliferation fraction and symptoms of the disease. Chemotherapy is not the basic first-line treatment. In patients with Ki-67 < 10% it may be considered in the case of progression on SSA treatment [*evidence level 2b], or following failure of targeted therapy — everolimus or sunitinib [*evidence level 1b]). If the disease threatens organ sufficiency, or if it is pronounced, symptoms difficult to control occur, a two-drug regimen, optimally streptozocin-based regimen is recommended (*evidence level 2b). Currently, since streptozocin is not unavailable in Poland, temozolomide- and capecitabine-based (CAPTEM) may be considered.
- In small intestinal NETs, chemotherapy is not recommended in most cases (*evidence level 3). In this situation, as well as in neoplasms located in other parts of the gastrointestinal tract or with unknown site of origin, chemotherapy may be considered after exhausting all other therapeutic, to be used to alleviate the symptoms.
- The basic first-line treatment of NECs is cisplatin and etoposide-based chemotherapy (*evidence level 3), especially in the case of NECs with a high proliferation index of Ki-67 > 55%. In the case of NETs G3 and NECs (Ki 67 < 55%) – STZ +/- 5-Fu +/- ADM may be considered, or alternatively, capecitabine and temozolomide (CAPTEM).

3.3.4. Targeted therapy

Molecular targeted therapies

In patients with gastrointestinal NETs, molecular targeted therapy was found to be effective and safe. The mechanism of action of targeted medications consists in

blocking the function of numerous receptors related to neoangiogenesis and neoplastic cell proliferation, and in inhibiting metastases. The effectiveness of targeted therapies was confirmed for the first time in pancreatic NET G1/G2 (PNET) where, at an advanced stage of the disease, two drugs demonstrating antiangiogenic properties were used:

- everolimus, selective m-TOR (mammalian target of rapamycin) pathway inhibitor, and
- sunitinib, RTKs (receptor tyrosine kinases) inhibitor [224–226]. In Poland and other EU countries, both medications were registered for the treatment of non-surgical and/or metastatic well- or moderately-differentiated neuroendocrine tumours of the pancreas in adult patients with progressive disease [228, 229]. Their therapeutic role is discussed in recommendations on pancreatic NENs (see p. 169–197).

On the basis of the RADIANT-4 trial, everolimus was registered in the US and in Europe, for treatment of advanced non-functional NET G1/G2 originating in the parts of gastrointestinal tract other than the pancreas, and in the lungs. This prospective, placebo-controlled, randomised phase III study involved 302 patients, of whom 24% were patients with small intestinal neoplasms, 13% were patients with rectal NENs, and approx. 30% were patients with NENs of the lungs. Also studied was a group of patients with unknown primary tumour site. A significant prolongation of progression-free survival was observed in the everolimus group, compared to the placebo group (11 vs. 3.9 months), with an over two-fold reduction in the risk of progression or death (HR, 0.48; 95% CI, 0.35–0.67; $p < 0.00001$). In most patients, disease stabilisation was observed (81% in the everolimus group, compared to 64% in the placebo group), while objective responses were sporadic [230]. Currently (December 2016), everolimus therapy for extrapancreatic tumour sites is not refundable in Poland.

Targeted drugs, everolimus or sunitinib, may be considered as first-line or second-line therapeutic options after chemotherapy, “cold” SSA treatment or “hot” SSA treatment — PRRT in locally advanced, non-surgical or metastatic, well-differentiated (G1 and G2) gastrointestinal NETs. In compliance with the consensus, targeted therapies should not be widely used as first-line treatment, due to the potential risk of complications, and lack of reliable study results [158]. Moreover, there is no evidence to determine the precise order of various therapeutic options in the management of NENs [231]. In the case of sequential therapy, its potential toxicity should be considered, as indicated by an Italian retrospective, multi-centre

*evidence level according to OCEBM [274]

study involving 169 patients [232]. This study revealed a significant increase in toxicity in patients who received everolimus, and were previously treated with PRRT and/or chemotherapy. The results of a smaller Dutch retrospective study involving 24 patients indicated that previous use of PRRT does not affect the safety of everolimus therapy [233]. A currently conducted prospective study (SECTOR) addresses the antiproliferative effect of everolimus, compared to the combination of STZ/5-FU in advanced pancreatic NENs, in a cross-over system where therapies are switched upon progression (www.clinicaltrials.gov).

Understanding the side effects of treatments and the profile of patient's comorbidities helps in deciding targeted therapy between everolimus or sunitinib.

According to CTCAE (Common Terminology Criteria for Adverse Events v 3.0 — CTCAE) [234], the basic first and second degree adverse events associated with everolimus include: mucosal lesions (64%), rash (49%), diarrhoea (34%), fatigue syndrome (31%) and infections (23%), while third- and fourth-degree AEs include: anaemia (6%) and hyperglycaemia (5%). During the sunitinib therapy first- and second-degree CTCAE complications included: diarrhoea (54%), nausea (45%), weakness (34%) and fatigue (32%), and serious third- and fourth-degree complications involved neutropenia (12%) and arterial hypertension (10%) [225, 226].

Both targeted medications are oral preparations, administered continuously until disease progression or unacceptable toxicity occur (everolimus at 10 mg/day, sunitinib at 37.5 mg/day).

Restrictions in the use of everolimus include uncontrolled diabetes mellitus or lung diseases (non-infectious pneumonia is a classic effect of rapamycin derivatives, including everolimus) [228], and serious cardiovascular diseases for sunitinib [229].

Using of targeted therapies in combination with SSA in the treatment of functional NETs is a standard practice according to ENETS [156]. Everolimus demonstrated the effectiveness in the treatment of insulinoma functional pancreatic tumours regarding control of symptoms such as hypoglycaemia [234, 235], as well as in control of carcinoid syndrome symptoms (RADIANT-2) [238]. A similar hypoglycaemic effect was demonstrated in individual cases of pancreatic NETs treated with sunitinib [238].

Combination of molecularly targeted medications with SSA (everolimus and octreotide) in the first-line therapy of non-functional NETs is justified only if somatostatin receptor expression is observed. Any evidence for the superiority of a combined targeted drug and

SSA therapy over the medication used in monotherapy is still insufficient (benefits regarding disease control > 90%, without effects on PFS) [239].

Using sunitinib with lanreotide or without SSA in the treatment of midgut NETs is currently under investigation in prospective, randomised, clinical studies (SUNLAND study). The results are not yet available, so the mentioned medications should only be used in clinical trials.

Currently, there is insufficient evidence to support the use of other targeted therapies, such as bevacizumab, sorafenib, pazopanib, or axitinib, in the treatment of gastrointestinal NENs [240–243].

At present, application of targeted therapy in the treatment of NECs in clinical practice is not justified, due to the lack of evidence from controlled, prospective clinical trials.

Molecularly targeted therapies — adjuvant treatment

There is no scientific evidence to justify the use of targeted therapies in adjuvant management (complementary treatment after completed surgical procedure), neither in gastrointestinal NET G1/G2, nor in NECs or NET G3.

Minimal consensus statement on targeted therapy:

- Targeted therapy (everolimus or sunitinib) may be considered only for palliative treatment in advanced stages, in well-differentiated pancreatic NET G1/G2 (*evidence level 1b). The main qualification criterion for targeted therapy is progression while on SSA, PRRT, or chemotherapy (moderate or slow progression dynamics). The therapy is registered and available in Poland as part of the National Health Fund programme.
- The combination of targeted therapy with SSA in the management of functional NETs is a standard procedure, implemented for its antiproliferative effect and improved control of hormonal disturbances, e.g. recurring hypoglycaemia in a metastatic insulinoma tumour (*evidence level 3).
- Targeted therapy with everolimus in non-functional gastrointestinal NENS located outside the pancreas (NENs of the small intestine, large intestine, hepatic metastases from an unknown primary focus) may be considered after other therapeutic options have been exhausted, as a second- or third-line therapy (ineffective SSA treatment or progression following PRRT therapy) (*evidence level 1b).
- In Poland and elsewhere in the EU, therapy in this indication is registered, but is not refundable in Poland.
- Targeted therapy in NET G3 and NECs — Currently there is no evidence to support its effectiveness.
- Targeted therapy as adjuvant (complementary) treatment — currently there is no justification.

*evidence level according to OCEBM [274]

3.4. Radioisotope treatment

Patients with advanced, non-surgical NETS G1 and G2 are qualified for peptide receptor radionuclide therapy with radiolabelled somatostatin analogues (PRRT). There are no indications for radioisotope treatment as an adjuvant therapy following radical surgical management [1]. The role of radioisotope treatment in differentiated neoplasms with high mitotic index (NET G3) is not well understood, and requires further investigation. In radioisotope therapy of NETs radioisotope-labelled somatostatin analogues are used. In the treatment of neuroendocrine neoplasms, metaiodobenzylguanidine (^{131}I -MIBG) derivatives labelled with ^{131}I are currently used only sporadically [1].

3.4.1. Treatment with radioisotope-labelled somatostatin analogues

Previous experience in radioisotope therapy of NETs involved the use of DOTA-Tyr3-octreotide and DOTA-Tyr3-octreotate labelled with ^{177}Lu or ^{90}Y isotopes, or their combination. Non-randomised clinical studies indicate that response to PRRT (complete and partial remission) can be achieved in approximately 8–46% of patients, with mean progression-free survival (PFS) after the treatment of 25 to 36 months [244–253]. In a prospective, randomised, phase III study to assess the effects of treatment with ^{177}Lu -DOTATATE + 30 mg Octreotide LAR (patients with carcinoid syndrome symptoms) vs. 60 mg Octreotide LAR in midgut neoplasms, a 79% (95% CI 83% to 64%) reduction in the risk of progression of the neoplastic disease was found in the group of patients treated with PRRT. The response rate to radioisotope treatment (complete and partial remission) was 19% (95% CI: 11–26%). This study demonstrated for the first time the effect of PRRT on overall survival [253].

Patients with enhanced uptake of radiotracer in all neoplastic foci, in the case of small lesions with homogeneous tracer uptake, are candidates for radioisotope treatment. If uptake is not seen in all neoplastic foci and/or large foci of necrosis are found, the aim of the treatment is palliative in the form of extended progression-free survival, and of reduction of the neoplastic disease symptoms (e.g. carcinoid syndrome symptoms and other symptoms associated with advanced NET process). In individual cases, radioisotope therapy as a neoadjuvant treatment may be considered in order to reduce the tumour mass before the planned surgical treatment [254].

Qualification for treatment with radioisotope-labelled somatostatin analogues

Qualified for treatment with radioisotope-labelled somatostatin analogues are patients with well-differentiated and moderately differentiated GEP NETs, who

demonstrate high somatostatin receptor overexpression confirmed by SRI the uptake should be at least comparable with that in the healthy liver, or higher. The best therapeutic effects are achieved if the uptake in the metastatic lesions is 2.2 times higher than that in the liver or in the PET/CT with an radiolabelled somatostatin analogues SUVmax of 16.4 [255].

Exclusion criteria for PRRT treatment

1. No patient consent;
2. Pregnant patient (negative pregnancy test required);
3. Lactation;
4. Patient's performance status (PS) 3 or 4 according to WHO/ECOG classification, or according to Karnofsky classification < 60;
5. No radiotracer uptake in SRI;
6. Bone marrow insufficiency, namely:
 - Hb < 8 g/dL,
 - blood platelets < $80 \times 10^3/\mu\text{l}$,
 - WBC < $2 \times 10^3/\mu\text{l}$ *,
 - lymphocytes < $0.5 \times 10^3/\mu\text{l}$,
 - neutrocytes < $1 \times 10^3/\mu\text{l}$;
7. Renal failure (GFR < 30 ml/min)*, BUN > 45 mg/dl, creatinine > 150 $\mu\text{mol/l}$;
8. Liver failure (three-fold increase in bilirubin concentration).

Due to the increased risk of adverse reactions, patients with leukopaenia < 3,000, neutropaenia < 1,500, thrombocytopaenia < 100,000, and creatinine clearance < 60 mg/ml, should be qualified individually [250, 256].

Data on the regarding effectiveness of the treatment in patients under 18 years of age are limited; therefore, treatment in this age group should always be considered on an individual basis.

Qualification tests prior to PRRT:

- Neuroendocrine tumour confirmed by histopathological examination;
- Positive result of SRI within 12 weeks prior to therapy, in order to assess the radioisotope uptake in the lesions;
- Prior to first PRRT cycle, the patient should undergo multiphase CT examination or, alternatively, dynamic MRI examination to assess the extent of the disease and to correlate with the somatostatin receptor examination;
- GFR assessment (in non-conclusive cases, assessment based on scintigraphy is recommended);
- Laboratory tests:
 - Complete blood count with a smear,
 - Urea and creatinine, uric acid, with biochemical assessment of GFR,

*evidence level according to OCEBM [274]

- ALAT, AspAT, AP, and bilirubin (alkaline phosphatase to exclude cases with occult subclinical intra- and extrahepatic cholestasis),
- CgA,
- Other laboratory tests, according to the patient's clinical condition.

PET/CT examination with ^{18}F FDG is recommended as a qualification test for PRRT, in order to assess the biological malignancy of the neoplastic disease, and as a prognostic factor [257, 258, 259].

Radioisotope treatment regimens

Treatment is usually conducted in four cycles, with intervals of 8–12 weeks, with the use of somatostatin analogues radiolabelled with ^{90}Y , ^{177}Lu , or $^{90}\text{Y}/^{177}\text{Lu}$. Currently, due to lower nephrotoxicity, most centres prefer the use of ^{177}Lu isotope the $^{90}\text{Y}/^{177}\text{Lu}$ tandem treatment. During radioisotope treatment, it is necessary to administer intravenously a solution of amino acids to radioprotect of the kidneys [260]. There is no conclusive evidence that treatment with octreotide/lanreotide reduces the effectiveness of radioisotope-labelled somatostatin analogue therapy. This therapy should not be discontinued during the radioisotope treatment; however, it is best if the interval between administrations of a long-acting analogue is at least 4 weeks. If the treatment with a SSA needs to be continued before PRRT, short-acting analogues are recommended [260]. Data on biotherapy with SSA following isotope treatment (in patients without carcinoid syndrome) are limited [261, 262]; therefore, decisions should be taken on an individual basis.

Adverse effects of PRRT

Adverse effects of the treatment concern mostly the haematopoietic system and kidneys. Possible adverse reactions should be monitored on every application, using oncological criteria, optimally based on the CTC-AE NCI ver. 4.03 or later [263]. The risk of post-radiation damage to the kidneys is reduced by the intravenous administration of positively charged amino acids — L-lysine and arginine — prior to treatment. Patients with carcinoid syndrome, who may experience a carcinoid crisis during the therapy, require special attention. Short-acting SSA should be used with these patients directly before, during, and directly after PRRT.

Retreatment with radioisotope-labelled somatostatin analogues

In the case of progression after achieving a long-lasting, positive effect of radioisotope therapy, if other thera-

peutic methods are not available, retreatment of PRRT may be considered [264].

3.4.2. Treatment with ^{131}I -MIBG

Since most of patients diagnosed with well-differentiated/moderately differentiated NET qualify for treatment with labelled SSA, currently the treatment with ^{131}I -MIBG is used very rarely. It may be considered in patients with negative results of SRI and present uptake of ^{131}I -MIBG in the primary tumour and/or metastases. The treatment is primarily palliative, to alleviate of the clinical symptoms, including the carcinoid syndrome and other clinical symptoms associated with an advanced neoplastic process [264, 265]. Contraindications for this therapy include bone marrow suppression, according to the above criteria. In patients with a functional thyroid gland, it is necessary to block the uptake of free ^{131}I not bound with the MIBG carrier (Lugol solution may be used) [1].

Qualification for ^{131}I -MIBG radioisotope treatment

Basic tests performed to qualify a patient for radioisotope treatment include diagnostic ^{131}I -MIBG or ^{123}I -MIBG scintigraphy. Iodine-123 isotope is preferred (but its availability in Poland is limited, due to high costs), as it enables performance of a whole-body SPECT/CT, including precise location of radiotracer uptake, and comparison with the visible NET foci in CT or MRI examinations. Complete blood count with a smear, liver and kidney tests with creatinine clearance complete the preparation for this therapy [1, 155, 267].

3.4.3. Evaluation of effects of radioisotope therapy

Evaluation of therapeutical effects should include morphological examinations (e.g. CT, MR) [269] and somatostatin receptor imaging (note: in order to assess the effectiveness of treatment, SRI must be performed using the same technique as the treatment qualifying test), approx. 3 months after completion of treatment, next every 6 months for 2 years. Further follow-up depends on the clinical course of the disease. To assess the objective response rate (ORR), RECIST classification is used; depending on the adopted model, RECIST v. 1.0 classification is still in use in NENs. The current classification is RECIST 1.1. In assessment of the response to PRRT, the optimum methods and criteria are still searched for [269, 270].

3.4.4. Role of PRRT in the therapy of advanced neuroendocrine neoplasms

There are no conclusive data on the GEP NEN treatment stage at which PRRT should be considered. Progression of neoplastic disease is an indication for

*evidence level according to OCEBM [274]

implementing cytotoxic therapy (chemotherapy/radiotherapy/targeted therapy), but there is no agreement as to the most effective first-line treatment. The location of the primary focus, dynamics of the neoplastic process, and high overexpression of somatostatin receptors should be taken into account.

The main indication for PRRT is disease progression after biotherapy with SSA (**evidence level 1* in NETs of the small intestine); however, in the case of advanced disease, associated with the risk of organ insufficiency, radioisotope treatment as the first-line therapy can be considered (**evidence level 3*). In other GEP NEN locations, radioisotope treatment may be considered in case of advanced disease, especially after progression is demonstrated in imaging examinations and if high somatostatin receptor overexpression is shown in SRI (**evidence level 4*) [1, 250].

Minimal consensus statement on the use of therapy with labelled somatostatin analogues

PRRT may be considered as first-line treatment in patients with diffused or non-surgical NETs, in particular those originating in the midgut, with high overexpression of somatostatin receptors in SRI, depending on the stage of disease.

*In selected cases, treatment of patients with non-surgical GEP NENs may be conducted with the use of ¹³¹I-MIBG, after uptake of radioisotope-labelled biogenic amine analogue is confirmed in diagnostic examination (*evidence level 3).*

3.5. Radiotherapy in neuroendocrine neoplasms

The common opinion that neuroendocrine neoplasms demonstrate low radiosensitivity is not supported by the published studies. Retrospective studies indicate potential benefits of teleradiotherapy as a palliative treatment or as complementary therapy following surgical management. In the past decade Stereotactic Ablative Body Radiotherapy (SABR) — or Stereotactic Body Radiotherapy (SBRT) have emerged, enabling delivery of high ablative radiation doses with high precision. SABR results in local control of 70–100%, comparable with surgical resection or with other ablation methods. SABR can be used in non-resectable gastro-entero-pancreatic tumours (e.g. pancreatic or hepatic lesions).

Indications for radiotherapy are individual, and in symptomatic cases, with regard to metastatic lesions (osseous metastases, cerebral metastases). Radiotherapy may be considered as an alternative to surgical management in non-operative gastro-entero-pancreatic tumours (pancreas, liver, stomach). Complementary radiotherapy can be individually considered after R1 resections in gastro-entero-pancreatic tumours. Small, retrospective studies indicate improved local control fol-

lowing complementary RT in patients who underwent R1 radical surgeries due to pancreatic NENs.

The application of radiotherapy in combined radical treatment of gastro-entero-pancreatic neuroendocrine cancers (of the rectum, rectal canal, stomach, oesophagus, and pancreas) is a separate issue. There is no consensus with regard to management standards for these indications. No studies are available to suggest whether management guidelines should follow neuroendocrine cancers (mainly surgical treatment with adjuvant chemotherapy), or those related to managing adenocarcinoma or squamous cell carcinoma (pre-operative or post-operative radiotherapy or chemotherapy, or chemotherapy instead of surgical treatment). It appears that the clinical course of neuroendocrine carcinomas is determined by biological factors resulting from the histopathological type (small-cell cancers demonstrate highly metastatic characteristics), but also by the anatomical properties of the organs (lymph drainage and high risk of local recurrence); therefore, any decision regarding combined treatment involving radiotherapy or chemotherapy should always be made by a multidisciplinary team of experienced specialists [271–273].

Minimal consensus statement on radiotherapy:

Radiotherapy as palliative or adjuvant treatment should be considered on an individual basis (teleradiotherapy, including Stereotactic Ablative Body Radiotherapy — SABR, or Stereotactic Body Radiotherapy — SBRT):

- *in osseous or cerebral metastases,*
- *as an alternative to surgical management in non-operative gastro-entero-pancreatic tumours (pancreas, liver, stomach),*
- *as a complementary therapy following R1 resections in gastro-entero-pancreatic tumours.*

4. Follow-up

Treatment monitoring should include clinical examinations, laboratory tests (CgA) and imaging methods.

It is recommended to monitor the disease by imaging examinations, such as CT, MRI, USG, and endoscopic examinations, and of biochemical markers determination (CgA) every 6–12 months in NET G1-G2. Radioisotope somatostatin receptors imaging SRI should be performed 4–6 months after surgical treatment, and repeated every 6–24 months in NETs demonstrating somatostatin receptor expression.

Indications for SRI in further monitoring depend on the clinical advancement and location of the tumour; these are discussed in respective sections.

In patients with NECs, imaging examinations should be performed every 3–6 months, depending on the course of the disease.

*evidence level according to CEBM [274]

References

- Kos-Kudła B, Blicharz-Dorniak J, Handkiewicz-Junak D, et al. Consensus Conference, Polish Network of Neuroendocrine Tumours. Diagnostic and therapeutic guidelines for gastro-entero-pancreatic neuroendocrine neoplasms (recommended by the Polish Network of Neuroendocrine Tumours). *Endokrynol Pol.* 2013; 64(6): 418–443, doi: [10.5603/EP.2013.0028](https://doi.org/10.5603/EP.2013.0028), indexed in Pubmed: [24431116](https://pubmed.ncbi.nlm.nih.gov/24431116/).
- Plöckinger U, Rindi G, Arnold R, et al. European Neuroendocrine Tumour Society. Guidelines for the diagnosis and treatment of neuroendocrine gastrointestinal tumours. A consensus statement on behalf of the European Neuroendocrine Tumour Society (ENETS). *Neuroendocrinology.* 2004; 80(6): 394–424, doi: [10.1159/000085237](https://doi.org/10.1159/000085237), indexed in Pubmed: [15838182](https://pubmed.ncbi.nlm.nih.gov/15838182/).
- Yao JC, Hassan M, Phan A, et al. One hundred years after. *J Clin Oncol.* 2008; 26(18): 3063–3072, doi: [10.1200/JCO.2007.15.4377](https://doi.org/10.1200/JCO.2007.15.4377), indexed in Pubmed: [18565894](https://pubmed.ncbi.nlm.nih.gov/18565894/).
- Ramage JK, De Herder WW, Delle Fave G, et al. Vienna Consensus Conference participants. ENETS Consensus Guidelines Update for Colorectal Neuroendocrine Neoplasms. *Neuroendocrinology.* 2016; 103(2): 139–143, doi: [10.1159/000443166](https://doi.org/10.1159/000443166), indexed in Pubmed: [26730835](https://pubmed.ncbi.nlm.nih.gov/26730835/).
- Öberg K, Knigge U, Kwekkeboom D, et al. ESMO Guidelines Working Group. Neuroendocrine gastro-entero-pancreatic tumors: ESMO Clinical Practice Guidelines for diagnosis, treatment and follow-up. *Ann Oncol.* 2012; 23 Suppl 7: vii124–vii130, doi: [10.1093/annonc/mds295](https://doi.org/10.1093/annonc/mds295), indexed in Pubmed: [22997445](https://pubmed.ncbi.nlm.nih.gov/22997445/).
- Ramage JK, Ahmed A, Ardill J, et al. UK and Ireland Neuroendocrine Tumour Society. Guidelines for the management of gastroenteropancreatic neuroendocrine (including carcinoid) tumours (NETs). *Gut.* 2012; 61(1): 6–32, doi: [10.1136/gutjnl-2011-300831](https://doi.org/10.1136/gutjnl-2011-300831), indexed in Pubmed: [22052063](https://pubmed.ncbi.nlm.nih.gov/22052063/).
- Blicharz-Dorniak J, Kos-Kudła B, Foltyn W, et al. Is determination of matrix metalloproteinases and their tissue inhibitors serum concentrations useful in patients with gastroenteropancreatic and bronchopulmonary neuroendocrine neoplasms? *Endokrynol Pol.* 2012; 63(6): 470–476, indexed in Pubmed: [23339005](https://pubmed.ncbi.nlm.nih.gov/23339005/).
- Kanakis G, Kaltsas G. Biochemical markers for gastroenteropancreatic neuroendocrine tumours (GEP-NETs). *Best Pract Res Clin Gastroenterol.* 2012; 26: 791–802.
- Glinicki P, Jeske W, Glinicki P, et al. Chromogranin A (CgA)—the influence of various factors in vivo and in vitro, and existing disorders on its concentration in blood. *Endokrynol Pol.* 2010; 61(4): 384–387, indexed in Pubmed: [20806183](https://pubmed.ncbi.nlm.nih.gov/20806183/).
- Glinicki P, Kapuścińska R, Jeske W. The differences in chromogranin A (CgA) concentrations measured in serum and in plasma by IRMA and ELISA methods. *Endokrynol Pol.* 2010; 61(4): 346–350, indexed in Pubmed: [20806177](https://pubmed.ncbi.nlm.nih.gov/20806177/).
- Witkowska A, Jańczyk A, Nyckowski P, et al. Elevated serum chromogranin A patient with incidentally detected tumors in the caudate lobe of the liver plan. *Endokrynol Pol.* 2012; 63(Suppl 3): 7–8.
- Telega A, Kos-Kudła B, Foltyn W, et al. Selected neuroendocrine tumour markers, growth factors and their receptors in typical and atypical bronchopulmonary carcinoids. *Endokrynol Pol.* 2012; 63(6): 477–482, indexed in Pubmed: [23339006](https://pubmed.ncbi.nlm.nih.gov/23339006/).
- Yao JC, Pavel M, Phan AT, et al. Chromogranin A and neuron-specific enolase as prognostic markers in patients with advanced pNET treated with everolimus. *J Clin Endocrinol Metab.* 2011; 96(12): 3741–3749, doi: [10.1210/jc.2011-0666](https://doi.org/10.1210/jc.2011-0666), indexed in Pubmed: [21994954](https://pubmed.ncbi.nlm.nih.gov/21994954/).
- Baudin E, Gigliotti A, Ducreux M, et al. Neuron-specific enolase and chromogranin A as markers of neuroendocrine tumours. *Br J Cancer.* 1998; 78(8): 1102–1107, indexed in Pubmed: [9792158](https://pubmed.ncbi.nlm.nih.gov/9792158/).
- Modlin IM, Drozdov I, Alaimo D, et al. Circulating Transcript Analysis (NETest) in GEP-NETs Treated With Somatostatin Analogs Defines Therapy. *Endocr Relat Cancer.* 2014 :615-28, doi: [10.1530/ERC-14-0190](https://doi.org/10.1530/ERC-14-0190).
- Ćwikła JB, Bodei L, Kolasinska-Ćwikła A, et al. Blood measurement of neuroendocrine gene transcripts defines the effectiveness of operative resection and ablation strategies. *J Clin Endocrinol Metab.* 2015: E1437-45, doi: [10.1210/jc.2015-2792](https://doi.org/10.1210/jc.2015-2792).
- Modlin IM, Frilling A, Salem RR, et al. Blood measurement of neuroendocrine gene transcripts defines the effectiveness of operative resection and ablation strategies. *Surgery.* 2016; 159(1): 336–347, doi: [10.1016/j.surg.2015.06.056](https://doi.org/10.1016/j.surg.2015.06.056), indexed in Pubmed: [26456125](https://pubmed.ncbi.nlm.nih.gov/26456125/).
- Miller HC, Frampton AE, Malczewska A, et al. MicroRNAs associated with small bowel neuroendocrine tumours and their metastases. *Endocr Relat Cancer.* 2016; 23(9): 711–726, doi: [10.1530/ERC-16-0044](https://doi.org/10.1530/ERC-16-0044), indexed in Pubmed: [27353039](https://pubmed.ncbi.nlm.nih.gov/27353039/).
- Gaztambide S, Vazquez F, Castaño L. Diagnosis and treatment of multiple endocrine neoplasia type 1 (MEN1). *Minerva Endocrinol.* 2013; 38(1): 17–28, indexed in Pubmed: [23435440](https://pubmed.ncbi.nlm.nih.gov/23435440/).
- Kajdaniuk D, Marek B, Borgiel-Marek H, et al. Transforming growth factor b1 (TGFb1) in physiology and pathology. *Endokrynol Pol.* 2013; 64: 384–396.
- Niederle B, Pape UF, Costa F, et al. Vienna Consensus Conference participants. ENETS Consensus Guidelines Update for Neuroendocrine Neoplasms of the Jejunum and Ileum. *Neuroendocrinology.* 2016; 103(2): 125–138, doi: [10.1159/000443170](https://doi.org/10.1159/000443170), indexed in Pubmed: [26758972](https://pubmed.ncbi.nlm.nih.gov/26758972/).
- Kos-Kudła B, Zemczak A. [Contemporary methods of diagnosis and treatment of neuroendocrine gastrointestinal tumors]. *Endokrynol Pol.* 2006; 57(2): 174–186, indexed in Pubmed: [16773594](https://pubmed.ncbi.nlm.nih.gov/16773594/).
- Yao JC, Pavel M, Phan AT, et al. Chromogranin A and neuron-specific enolase as prognostic markers in patients with advanced pNET treated with everolimus. *J Clin Endocrinol Metab.* 2011; 96(12): 3741–3749, doi: [10.1210/jc.2011-0666](https://doi.org/10.1210/jc.2011-0666), indexed in Pubmed: [21994954](https://pubmed.ncbi.nlm.nih.gov/21994954/).
- Rindi G, Klöppel G, Alhman H, et al. all other Frascati Consensus Conference participants, European Neuroendocrine Tumor Society (ENETS). TNM staging of foregut (neuro)endocrine tumors: a consensus proposal including a grading system. *Virchows Arch.* 2006; 449(4): 395–401, doi: [10.1007/s00428-006-0250-1](https://doi.org/10.1007/s00428-006-0250-1), indexed in Pubmed: [16967267](https://pubmed.ncbi.nlm.nih.gov/16967267/).
- Bosman FT, Carneiro F, Hruban RH, et al. WHO Classification of Tumours of the Digestive System. IARC: Lyon 2010: 13–14.
- Rosiek V, Kunikowska J, Kos-Kudła B. A non-functioning pancreatic neuroendocrine tumour: a case report. *Endokrynol Pol.* 2012; 63(1): 59–64, indexed in Pubmed: [22378100](https://pubmed.ncbi.nlm.nih.gov/22378100/).
- Klimstra DS, Modlin IR, Coppola D, et al. The pathologic classification of neuroendocrine tumors: a review of nomenclature, grading, and staging systems. *Pancreas.* 2010; 39(6): 707–712, doi: [10.1097/MPA.0b013e3181ec124e](https://doi.org/10.1097/MPA.0b013e3181ec124e), indexed in Pubmed: [20664470](https://pubmed.ncbi.nlm.nih.gov/20664470/).
- Klöppel G, Rindi G, Perren A, et al. The ENETS and AJCC/UICC TNM classifications of the neuroendocrine tumors of the gastrointestinal tract and the pancreas: a statement. *Virchows Arch.* 2010; 456(6): 595–597, doi: [10.1007/s00428-010-0924-6](https://doi.org/10.1007/s00428-010-0924-6), indexed in Pubmed: [20422210](https://pubmed.ncbi.nlm.nih.gov/20422210/).
- Kvols LK, Brendtro KL. North American Neuroendocrine Tumor Society (NANETS). The North American Neuroendocrine Tumor Society (NANETS) guidelines: mission, goals, and process. *Pancreas.* 2010; 39(6): 705–706, doi: [10.1097/MPA.0b013e3181eb7451](https://doi.org/10.1097/MPA.0b013e3181eb7451), indexed in Pubmed: [20664469](https://pubmed.ncbi.nlm.nih.gov/20664469/).
- Maroun J, Kocha W, Kvols L, et al. Guidelines for the diagnosis and management of carcinoid tumours. Part 1: the gastrointestinal tract. A statement from a Canadian National Carcinoid Expert Group. *Curr Oncol.* 2006; 13(2): 67–76, indexed in Pubmed: [17576444](https://pubmed.ncbi.nlm.nih.gov/17576444/).
- Woltering EA, Bergsland EK, Beyer DT, et al. Neuroendocrine Tumors of the Stomach. American Joint Committee on Cancer 2017. In: Amin M. B. et al (eds) *AJCC Cancer Staging Manual.* Eight Edition. Springer 2017: 351-359, DOI [10.1007/978-3-319-40618-3_30](https://doi.org/10.1007/978-3-319-40618-3_30).
- Bergsland E, Woltering E, Rindi G, et al. Neuroendocrine Tumors of the Duodenum and Ampulla of Vater. *AJCC Cancer Staging Manual.* 2016: 361–373, doi: [10.1007/978-3-319-40618-3_30](https://doi.org/10.1007/978-3-319-40618-3_30).
- Woltering EA, Bergsland EK, Beyer DT, et al. Neuroendocrine Tumors of the Jejunum and Ileum. American Joint Committee on Cancer 2017. In: Amin M. B. et al (eds) *AJCC Cancer Staging Manual.* Eight Edition. Springer 2017: 375-387, DOI [10.1007/978-3-319-40618-3_30](https://doi.org/10.1007/978-3-319-40618-3_30).
- Woltering EA, Bergsland EK, Beyer DT, et al. Neuroendocrine Tumors of the Appendix. American Joint Committee on Cancer 2017. In: Amin M. B. et al (eds) *AJCC Cancer Staging Manual.* Eight Edition. Springer 2017: 389-394, DOI [10.1007/978-3-319-40618-3_30](https://doi.org/10.1007/978-3-319-40618-3_30).
- Shi Ch, Woltering E, Deyer DT, et al. Neuroendocrine Tumors of the Colon and Rectum. American Joint Committee on Cancer 2017. In: Amin M. B. et al (eds) *AJCC Cancer Staging Manual.* Eight Edition. Springer 2017: 395-406, DOI [10.1007/978-3-319-40618-3_30](https://doi.org/10.1007/978-3-319-40618-3_30).
- Brierley JD, Gospodarowicz MK, Wittekind C, et al (eds). *UICC TNM Classification of Malignant Tumours.* Eight Edition. Wiley Blackwell 2017.
- WHO Classification of Tumours of the Digestive System. IARC: Lyon 2017 (in press)
- Basturk O, Tang L, Hruban RH, et al. Poorly differentiated neuroendocrine carcinomas of the pancreas: a clinicopathologic analysis of 44 cases. *Am J Surg Pathol.* 2014; 38(4): 437–447, doi: [10.1097/PAS.000000000000169](https://doi.org/10.1097/PAS.000000000000169), indexed in Pubmed: [24503751](https://pubmed.ncbi.nlm.nih.gov/24503751/).
- Heetfeld M, Chougnat CN, Olsen IH, et al. other Knowledge Network members. Characteristics and treatment of patients with G3 gastroenteropancreatic neuroendocrine neoplasms. *Endocr Relat Cancer.* 2015; 22(4): 657–664, doi: [10.1530/ERC-15-0119](https://doi.org/10.1530/ERC-15-0119), indexed in Pubmed: [26113608](https://pubmed.ncbi.nlm.nih.gov/26113608/).
- Basturk O, Yang Z, Tang LH, et al. The high-grade (WHO G3) pancreatic neuroendocrine tumor category is morphologically and biologically heterogeneous and includes both well differentiated and poorly differentiated neoplasms. *Am J Surg Pathol.* 2015; 39(5): 683–690, doi: [10.1097/PAS.0000000000000408](https://doi.org/10.1097/PAS.0000000000000408), indexed in Pubmed: [25723112](https://pubmed.ncbi.nlm.nih.gov/25723112/).
- Crippa S, Partelli S, Belfiori G, et al. Management of neuroendocrine carcinomas of the pancreas (WHO G3): A tailored approach between proliferation and morphology. *World J Gastroenterol.* 2016; 22(45): 9944–9953, doi: [10.3748/wjg.v22.i45.9944](https://doi.org/10.3748/wjg.v22.i45.9944), indexed in Pubmed: [28018101](https://pubmed.ncbi.nlm.nih.gov/28018101/).
- Milione M, Maisonneuve P, Spada F, et al. The Clinicopathologic Heterogeneity of Grade 3 Gastroenteropancreatic Neuroendocrine Neoplasms: Morphological Differentiation and Proliferation Identify Different Prognostic Categories. *Neuroendocrinology.* 2017; 104(1): 85–93, doi: [10.1159/000445165](https://doi.org/10.1159/000445165), indexed in Pubmed: [26943788](https://pubmed.ncbi.nlm.nih.gov/26943788/).
- Nasierowska-Guttmejer A. Patomorfologia guzów neuroendokrynnych układu pokarmowego. *Onk po Dyplomie.* ; 2005: 25–30.

44. Nasierowska-Guttmejer A, Malinowska M. Guzy neuroendokrynne układu pokarmowego (GEP/NET) — dyskusja wokół nazewnictwa i klasyfikacji. *Przeegl Gastroenterol.* 2006; 1: 1–4.
45. Nasierowska-Guttmejer A. Nowa klasyfikacja NET. *Onco Review.* 2011; 1: 46–50.
46. Oberg K, Akerström G, Rindi G, et al. ESMO Guidelines Working Group. Neuroendocrine gastroenteropancreatic tumours: ESMO Clinical Practice Guidelines for diagnosis, treatment and follow-up. *Ann Oncol.* 2010; 21 Suppl 5: v223–v227, doi: [10.1093/annonc/mdq192](https://doi.org/10.1093/annonc/mdq192), indexed in Pubmed: 20555086.
47. Rindi G, de Herder WW, O’Toole D, et al. Consensus guidelines for the management of patients with digestive neuroendocrine tumors: why such guidelines and how we went about it. *Neuroendocrinology.* 2006; 84(3): 155–157, doi: [10.1159/000098006](https://doi.org/10.1159/000098006), indexed in Pubmed: 17312374.
48. Rindi G, de Herder WW, O’Toole D, et al. Consensus guidelines for the management of patients with digestive neuroendocrine tumors: the second event and some final considerations. *Neuroendocrinology.* 2008; 87(1): 5–7, doi: [10.1159/000109975](https://doi.org/10.1159/000109975), indexed in Pubmed: 17940331.
49. Ito T, Jensen RT. Molecular imaging in neuroendocrine tumors: recent advances, controversies, unresolved issues, and roles in management. *Curr Opin Endocrinol Diabetes Obes.* 2017; 24(1): 15–24, doi: [10.1097/MED.0000000000000300](https://doi.org/10.1097/MED.0000000000000300), indexed in Pubmed: 27875420.
50. Deroose CM, Hindié E, Kebebew E, et al. Molecular Imaging of Gastroenteropancreatic Neuroendocrine Tumors: Current Status and Future Directions. *J Nucl Med.* 2016; 57(12): 1949–1956, doi: [10.2967/jnumed.116.179234](https://doi.org/10.2967/jnumed.116.179234), indexed in Pubmed: 27811124.
51. Opalińska M, Hubalewska-Dydejczyk A, Sowa-Staszczak A, et al. NEN - the role of somatostatin receptor scintigraphy in clinical setting. *Nucl Med Rev Cent East Eur.* 2016; 19(2): 118–125, doi: [10.5603/NMR.2016.0023](https://doi.org/10.5603/NMR.2016.0023), indexed in Pubmed: 27479789.
52. Sundin A, Vullierme MP, Kaltsas G, et al. Mallorca Consensus Conference participants, European Neuroendocrine Tumor Society. ENETS Consensus Guidelines for the Standards of Care in Neuroendocrine Tumors: radiological examinations. *Neuroendocrinology.* 2009; 90(2): 167–183, doi: [10.1159/000184855](https://doi.org/10.1159/000184855), indexed in Pubmed: 19077417.
53. Kwekkeboom DJ, Krenning EP, Scheidhauer K, et al. Mallorca Consensus Conference participants, European Neuroendocrine Tumor Society. ENETS Consensus Guidelines for the Standards of Care in Neuroendocrine Tumors: somatostatin receptor imaging with (111)In-pentetreotide. *Neuroendocrinology.* 2009; 90(2): 184–189, doi: [10.1159/000225946](https://doi.org/10.1159/000225946), indexed in Pubmed: 19713709.
54. Gabriel M, Oberauer A, Dobrozemsky G, et al. 68Ga-DOTA-Tyr3-octreotide PET in neuroendocrine tumors: comparison with somatostatin receptor scintigraphy and CT. *J Nucl Med.* 2007; 48(4): 508–518, indexed in Pubmed: 17401086.
55. Fanti S, Ambrosini V, Tomassetti P, et al. Evaluation of unusual neuroendocrine tumours by means of 68Ga-DOTA-NOC PET. *Biomed Pharmacother.* 2008; 62(10): 667–671, doi: [10.1016/j.biopha.2008.01.010](https://doi.org/10.1016/j.biopha.2008.01.010), indexed in Pubmed: 18358680.
56. Chiti A, Fanti S, Savelli G, et al. Comparison of somatostatin receptor imaging, computed tomography and ultrasound in the clinical management of neuroendocrine gastro-entero-pancreatic tumours. *Eur J Nucl Med.* 1998; 25(10): 1396–1403, indexed in Pubmed: 9818279.
57. Gouya H, Vignaux O, Augui J, et al. CT, endoscopic sonography, and a combined protocol for preoperative evaluation of pancreatic insulinomas. *AJR Am J Roentgenol.* 2003; 181(4): 987–992, doi: [10.2214/ajr.181.4.1810987](https://doi.org/10.2214/ajr.181.4.1810987), indexed in Pubmed: 14500214.
58. Anderson MA, Carpenter S, Thompson NW, et al. Endoscopic ultrasound is highly accurate and directs management in patients with neuroendocrine tumors of the pancreas. *Am J Gastroenterol.* 2000; 95(9): 2271–2277, doi: [10.1111/j.1572-0241.2000.02480.x](https://doi.org/10.1111/j.1572-0241.2000.02480.x), indexed in Pubmed: 11007228.
59. Hoeffel C, Job L, Ladam-Marcus V, et al. Detection of hepatic metastases from carcinoid tumor: prospective evaluation of contrast-enhanced ultrasonography. *Dig Dis Sci.* 2009; 54(9): 2040–2046, doi: [10.1007/s10620-008-0570-x](https://doi.org/10.1007/s10620-008-0570-x), indexed in Pubmed: 19034651.
60. Manta R, Nardi E, Pagano N, et al. Pre-operative Diagnosis of Pancreatic Neuroendocrine Tumors with Endoscopic Ultrasonography and Computed Tomography in a Large Series. *J Gastrointest Liver Dis.* 2016; 25(3): 317–321, indexed in Pubmed: 27689195.
61. Puli SR, Kalva N, Bechtold ML, et al. Diagnostic accuracy of endoscopic ultrasound in pancreatic neuroendocrine tumors: a systematic review and meta analysis. *World J Gastroenterol.* 2013; 19(23): 3678–3684, doi: [10.3748/wjg.v19.i23.3678](https://doi.org/10.3748/wjg.v19.i23.3678), indexed in Pubmed: 23801872.
62. Nelson H, Petrelli N, Carlin A, et al. National Cancer Institute Expert Panel. Guidelines 2000 for colon and rectal cancer surgery. *J Natl Cancer Inst.* 2001; 93(8): 583–596, indexed in Pubmed: 11309435.
63. Chen HJ, Xu GQ, Teng XD, et al. Diagnostic accuracy of endoscopic ultrasonography for rectal neuroendocrine neoplasms. *World J Gastroenterol.* 2014; 20(30): 10470–10477, doi: [10.3748/wjg.v20.i30.10470](https://doi.org/10.3748/wjg.v20.i30.10470), indexed in Pubmed: 25132764.
64. Hiramoto JS, Feldstein VA, LaBerge JM, et al. Intraoperative ultrasound and preoperative localization detects all occult insulinomas; discussion 1025-6. *Arch Surg.* 2001; 136(9): 1020–1025, indexed in Pubmed: 11529824.
65. Mörk H, Ignee A, Schuessler G, et al. Analysis of neuroendocrine tumour metastases in the liver using contrast enhanced ultrasonography. *Scand J Gastroenterol.* 2007; 42(5): 652–662, doi: [10.1080/00365520601021765](https://doi.org/10.1080/00365520601021765), indexed in Pubmed: 17454888.
66. Marcal LP, Patnana M, Bhosale P, et al. Intraoperative abdominal ultrasound in oncologic imaging. *World J Radiol.* 2013; 5(3): 51–60, doi: [10.4329/wjr.v5.i3.51](https://doi.org/10.4329/wjr.v5.i3.51), indexed in Pubmed: 23671741.
67. Yamao K, Nakamura T, Suzuki T, et al. Endoscopic diagnosis and staging of mucinous cystic neoplasms and intraductal papillary-mucinous tumors. *J Hepatobiliary Pancreat Surg.* 2003; 10(2): 142–146, doi: [10.1007/s00534-002-0802-y](https://doi.org/10.1007/s00534-002-0802-y), indexed in Pubmed: 14505147.
68. Yasuda K, Sakata M, Ueda M, et al. The use of pancreatoscopy in the diagnosis of intraductal papillary mucinous tumor lesions of the pancreas. *Clin Gastroenterol Hepatol.* 2005; 3(7 Suppl 1): S53–S57, indexed in Pubmed: 16012998.
69. Sun Bo, Hu B. The role of intraductal ultrasonography in pancreaticobiliary diseases. *Endosc Ultrasound.* 2016; 5(5): 291–299, doi: [10.4103/2303-9027.191607](https://doi.org/10.4103/2303-9027.191607), indexed in Pubmed: 27803901.
70. Scherübl H, Cadiot G, Jensen RT, et al. Neuroendocrine tumors of the stomach (gastric carcinoids) are on the rise: small tumors, small problems? *Endoscopy.* 2010; 42(8): 664–671, doi: [10.1055/s-0030-1255564](https://doi.org/10.1055/s-0030-1255564), indexed in Pubmed: 20669078.
71. Attili F, Capurso G, Vanella G, et al. Diagnostic and therapeutic role of endoscopy in gastroenteropancreatic neuroendocrine neoplasms. *Dig Liver Dis.* 2014; 46(1): 9–17, doi: [10.1016/j.dld.2013.04.007](https://doi.org/10.1016/j.dld.2013.04.007), indexed in Pubmed: 23731843.
72. Ito T, Hijioka S, Masui T, et al. Advances in the diagnosis and treatment of pancreatic neuroendocrine neoplasms in Japan. *J Gastroenterol.* 2017; 52(1): 9–18, doi: [10.1007/s00535-016-1250-9](https://doi.org/10.1007/s00535-016-1250-9), indexed in Pubmed: 27539256.
73. Wang SC, Parekh JR, Zuraek MB, et al. Identification of unknown primary tumors in patients with neuroendocrine liver metastases. *Arch Surg.* 2010; 145(3): 276–280, doi: [10.1001/archsurg.2010.10](https://doi.org/10.1001/archsurg.2010.10), indexed in Pubmed: 20231629.
74. Cerwenka H. Neuroendocrine liver metastases: contributions of endoscopy and surgery to primary tumor search. *World J Gastroenterol.* 2012; 18(10): 1009–1014, doi: [10.3748/wjg.v18.i10.1009](https://doi.org/10.3748/wjg.v18.i10.1009), indexed in Pubmed: 22416174.
75. van Tuyl SAC, van Noorden JI, Timmer R, et al. Detection of small-bowel neuroendocrine tumors by video capsule endoscopy. *Gastrointest Endosc.* 2006; 64(1): 66–72, doi: [10.1016/j.gie.2006.01.054](https://doi.org/10.1016/j.gie.2006.01.054), indexed in Pubmed: 16813805.
76. Frilling A, Smith G, Clift AK, et al. Capsule endoscopy to detect primary tumour site in metastatic neuroendocrine tumours. *Dig Liver Dis.* 2014; 46(11): 1038–1042, doi: [10.1016/j.dld.2014.07.004](https://doi.org/10.1016/j.dld.2014.07.004), indexed in Pubmed: 25086997.
77. Neumann H, Fry LC, Neurath MF. Review article on current applications and future concepts of capsule endoscopy. *Digestion.* 2013; 87(2): 91–99, doi: [10.1159/000345346](https://doi.org/10.1159/000345346), indexed in Pubmed: 23306733.
78. Zagorowicz ES, Pietrzak AM, Wronska E, et al. Small bowel tumors detected and missed during capsule endoscopy: single center experience. *World J Gastroenterol.* 2013; 19(47): 9043–9048, doi: [10.3748/wjg.v19.i47.9043](https://doi.org/10.3748/wjg.v19.i47.9043), indexed in Pubmed: 24379629.
79. Milewski J, Ryzewska G. Enteroskopia dwubalonowa - nowa technika diagnostyki i terapii endoskopowej chorób jelita cienkiego. *Przeegl Gastroenterol.* 2006; 1: 54–59.
80. Fukumoto A, Manabe N, Tanaka S, et al. Usefulness of EUS with double-balloon enteroscopy for diagnosis of small-bowel diseases. *Gastrointest Endosc.* 2007; 65(3): 412–420, doi: [10.1016/j.gie.2006.08.045](https://doi.org/10.1016/j.gie.2006.08.045), indexed in Pubmed: 17321241.
81. Kosmala W, Milewski J, Ryzewska G. Cztery lata doświadczeń w enteroskopii dwubalonowej na świecie. *Przeegl Gastroenterol.* 2007; 2: 305–310.
82. Domagk D, Bretthauer M, Lenz P, et al. Carbon dioxide insufflation improves intubation depth in double-balloon enteroscopy: a randomized, controlled, double-blind trial. *Endoscopy.* 2007; 39(12): 1064–1067, doi: [10.1055/s-2007-966990](https://doi.org/10.1055/s-2007-966990), indexed in Pubmed: 18072057.
83. Ethun CG, Postlewait LM, Baptiste CG, et al. Small bowel neuroendocrine tumors: A critical analysis of diagnostic work-up and operative approach. *J Surg Oncol.* 2016; 114(6): 671–676, doi: [10.1002/jso.24390](https://doi.org/10.1002/jso.24390), indexed in Pubmed: 27511436.
84. Sulbaran M, de Moura E, Bernardo W, et al. Overtube-assisted enteroscopy and capsule endoscopy for the diagnosis of small-bowel polyps and tumors: a systematic review and meta-analysis. *Endosc Int Open.* 2016; 4(2): E151–E163, doi: [10.1055/s-0041-108261](https://doi.org/10.1055/s-0041-108261), indexed in Pubmed: 26878042.
85. Leszczyński S, Pilch-Kowalczyk J. Diagnostyka obrazowa Układ trawienny. PZWL, Warszawa 2012.
86. Procacci C, Carbognin G, Accordini S, et al. Nonfunctioning endocrine tumors of the pancreas: possibilities of spiral CT characterization. *Eur Radiol.* 2001; 11(7): 1175–1183, doi: [10.1007/s003300000714](https://doi.org/10.1007/s003300000714), indexed in Pubmed: 11471608.

87. Fidler JL, Fletcher JG, Reading CC, et al. Preoperative detection of pancreatic insulinomas on multiphasic helical CT. *AJR Am J Roentgenol.* 2003; 181(3): 775–780, doi: [10.2214/ajr.181.3.1810775](https://doi.org/10.2214/ajr.181.3.1810775), indexed in Pubmed: 12933480.
88. Takumi K, Fukukura Y, Higashi M, et al. Pancreatic neuroendocrine tumors: Correlation between the contrast-enhanced computed tomography features and the pathological tumor grade. *Eur J Radiol.* 2015; 84(8): 1436–1443, doi: [10.1016/j.ejrad.2015.05.005](https://doi.org/10.1016/j.ejrad.2015.05.005), indexed in Pubmed: 26022520.
89. Kumbasar B, Kamel IR, Tekes A, et al. Imaging of neuroendocrine tumors: accuracy of helical CT versus SRS. *Abdom Imaging.* 2004; 29(6): 696–702, doi: [10.1007/s00261-003-0162-3](https://doi.org/10.1007/s00261-003-0162-3), indexed in Pubmed: 15162235.
90. Cwikla JB, Buscombe JR, Caplin ME, et al. Diagnostic imaging of carcinoid metastases to the abdomen and pelvis. *Med Sci Monit.* 2004; 10 Suppl 3: 9–16, indexed in Pubmed: 16538192.
91. Baur ADJ, Pavel M, Prasad V, et al. Diagnostic imaging of pancreatic neuroendocrine neoplasms (pNEN): tumor detection, staging, prognosis, and response to treatment. *Acta Radiol.* 2016; 57(3): 260–270, doi: [10.1177/0284185115579932](https://doi.org/10.1177/0284185115579932), indexed in Pubmed: 25855665.
92. de Mestier L, Dromain C, d'Assignies G, et al. Evaluating digestive neuroendocrine tumor progression and therapeutic responses in the era of targeted therapies: state of the art. *Endocr Relat Cancer.* 2014; 21(3): R105–R120, doi: [10.1530/ERC-13-0365](https://doi.org/10.1530/ERC-13-0365), indexed in Pubmed: 24351682.
93. Lebda-Wyborny T, Barczyk A, Pilch-Kowalczyk J. Wirtualna kolonoskopia CT – nowa metoda oceny patologii jelita grubego. *Chirurgia polska.* 2008; 10(2): 89–101.
94. Johnson CD, Chen MH, Toledano AY, et al. Accuracy of CT colonography for detection of large adenomas and cancers. *N Engl J Med.* 2008; 359(12): 1207–1217, doi: [10.1056/NEJMoa0800996](https://doi.org/10.1056/NEJMoa0800996), indexed in Pubmed: 18799557.
95. Regge D, Laudi C, Galatola G, et al. Diagnostic accuracy of computed tomographic colonography for the detection of advanced neoplasia in individuals at increased risk of colorectal cancer. *JAMA.* 2009; 301(23): 2453–2461, doi: [10.1001/jama.2009.832](https://doi.org/10.1001/jama.2009.832), indexed in Pubmed: 19531785.
96. Kaltsas G, Rockall A, Papadogias D, et al. Recent advances in radiological and radionuclide imaging and therapy of neuroendocrine tumours. *Eur J Endocrinol.* 2004; 151(1): 15–27, indexed in Pubmed: 15248818.
97. Elmaoglu M, Celik A. Rezonans magnetyczny, podstawy fizyczne, obrazowanie, ułożenie pacjenta, protokoły, Medipage, Warszawa 2015.
98. Dromain C, de Baere T, Lumbroso J, et al. Detection of liver metastases from endocrine tumors: a prospective comparison of somatostatin receptor scintigraphy, computed tomography, and magnetic resonance imaging. *J Clin Oncol.* 2005; 23(1): 70–78, doi: [10.1200/JCO.2005.01.013](https://doi.org/10.1200/JCO.2005.01.013), indexed in Pubmed: 15625361.
99. Sankowski AJ, Cwikla JB, Nowicki ML, et al. The clinical value of MRI using single-shot echoplanar DWI to identify liver involvement in patients with advanced gastroenteropancreatic neuroendocrine tumors (GEP-NETs), compared to FSE T2 and FFE T1 weighted image after i.v. Gd-EOB-DTPA contrast enhancement. *Med Sci Monit.* 2012; 18(5): MT33–MT40, indexed in Pubmed: 22534718.
100. Oberg K, Akerström G, Rindi G, et al. ESMO Guidelines Working Group. Neuroendocrine gastroenteropancreatic tumours: ESMO Clinical Practice Guidelines for diagnosis, treatment and follow-up. *Ann Oncol.* 2010; 21 Suppl 5: v223–v227, doi: [10.1093/annonc/mdq192](https://doi.org/10.1093/annonc/mdq192), indexed in Pubmed: 20555086.
101. Van Hoe L, Gryspeerd S, Marchal G, et al. Helical CT for the preoperative localization of islet cell tumors of the pancreas: value of arterial and parenchymal phase images. *AJR Am J Roentgenol.* 1995; 165(6): 1437–1439, doi: [10.2214/ajr.165.6.7484581](https://doi.org/10.2214/ajr.165.6.7484581), indexed in Pubmed: 7484581.
102. Kim JH, Eun HW, Kim YJ, et al. Staging accuracy of MR for pancreatic neuroendocrine tumor and imaging findings according to the tumor grade. *Abdom Imaging.* 2013; 38(5): 1106–1114, doi: [10.1007/s00261-013-0011-y](https://doi.org/10.1007/s00261-013-0011-y), indexed in Pubmed: 23728305.
103. Moryoussef F, de Mestier L, Belkebir M, et al. Impact of Liver and Whole-Body Diffusion-Weighted MRI for Neuroendocrine Tumors on Patient Management: A Pilot Study. *Neuroendocrinology.* 2017; 104(3): 264–272, doi: [10.1159/000446369](https://doi.org/10.1159/000446369), indexed in Pubmed: 27120316.
104. Carlbom L, Caballero-Corbalán J, Granberg D, et al. Whole-body MRI including diffusion-weighted MRI compared with 5-HTP PET/CT in the detection of neuroendocrine tumors. *Ups J Med Sci.* 2017; 122(1): 43–50, doi: [10.1080/03009734.2016.1248803](https://doi.org/10.1080/03009734.2016.1248803), indexed in Pubmed: 27894208.
105. Kamaoui I, De-Luca V, Ficarella S, et al. Value of CT enteroclysis in suspected small-bowel carcinoid tumors. *AJR Am J Roentgenol.* 2010; 194(3): 629–633, doi: [10.2214/AJR.09.2760](https://doi.org/10.2214/AJR.09.2760), indexed in Pubmed: 20173138.
106. Ganeshan D, Bhosale P, Yang T, et al. Imaging features of carcinoid tumors of the gastrointestinal tract. *AJR Am J Roentgenol.* 2013; 201(4): 773–786, doi: [10.2214/AJR.12.9758](https://doi.org/10.2214/AJR.12.9758), indexed in Pubmed: 24059366.
107. Gabriel M, Decristoforo C, Kendler D, et al. 68Ga-DOTA-Tyr3-octreotide PET in neuroendocrine tumors: comparison with somatostatin receptor scintigraphy and CT. *J Nucl Med.* 2007; 48(4): 508–518, indexed in Pubmed: 17401086.
108. Buchmann I, Henze M, Engelbrecht S, et al. Comparison of 68Ga-DOTATOC PET and 111In-DTPAOC (Octreoscan) SPECT in patients with neuroendocrine tumours. *Eur J Nucl Med Mol Imaging.* 2007; 34(10): 1617–1626, doi: [10.1007/s00259-007-0450-1](https://doi.org/10.1007/s00259-007-0450-1), indexed in Pubmed: 17520251.
109. Srirajaskanthan R, Kayani I, Quigley AM, et al. The role of 68Ga-DOTATATE PET in patients with neuroendocrine tumors and negative or equivocal findings on 111In-DTPA-octreotide scintigraphy. *J Nucl Med.* 2010; 51(6): 875–882, doi: [10.2967/jnumed.109.066134](https://doi.org/10.2967/jnumed.109.066134), indexed in Pubmed: 20484441.
110. Van Binnebeek S, Vanbilloen B, Baete K, et al. Comparison of diagnostic accuracy of (111)In-pentetreotide SPECT and (68)Ga-DOTATOC PET/CT: A lesion-by-lesion analysis in patients with metastatic neuroendocrine tumours. *Eur Radiol.* 2016; 26(3): 900–909, doi: [10.1007/s00330-015-3882-1](https://doi.org/10.1007/s00330-015-3882-1), indexed in Pubmed: 26162577.
111. Lee I, Paeng JC, Lee SJ, et al. Comparison of Diagnostic Sensitivity and Quantitative Indices Between (68)Ga-DOTATOC PET/CT and (111)In-Pentetreotide SPECT/CT in Neuroendocrine Tumors: a Preliminary Report. *Nucl Med Mol Imaging.* 2015; 49(4): 284–290, doi: [10.1007/s13139-015-0356-y](https://doi.org/10.1007/s13139-015-0356-y), indexed in Pubmed: 26550047.
112. Etchebehere EC, de Oliveira Santos A, Gumz B, et al. 68Ga-DOTATATE PET/CT, 99mTc-HYNIC-octreotide SPECT/CT, and whole-body MR imaging in detection of neuroendocrine tumors: a prospective trial. *J Nucl Med.* 2014; 55(10): 1598–1604, doi: [10.2967/jnumed.114.144543](https://doi.org/10.2967/jnumed.114.144543), indexed in Pubmed: 25168627.
113. Poeppel TD, Binsse I, Petersenn S, et al. 68Ga-DOTATOC versus 68Ga-DOTATATE PET/CT in functional imaging of neuroendocrine tumors. *J Nucl Med.* 2011; 52(12): 1864–1870, doi: [10.2967/jnumed.111.091165](https://doi.org/10.2967/jnumed.111.091165), indexed in Pubmed: 22072704.
114. Wild D, Bomanji JB, Benkert P, et al. Comparison of 68Ga-DOTANOC and 68Ga-DOTATATE PET/CT within patients with gastroenteropancreatic neuroendocrine tumors. *J Nucl Med.* 2013; 54(3): 364–372, doi: [10.2967/jnumed.112.111724](https://doi.org/10.2967/jnumed.112.111724), indexed in Pubmed: 23297077.
115. Deppen S, Blume J, Bobbey A, et al. 68Ga-DOTATATE compared to 111In-DTPA-octreotide and conventional imaging for pulmonary and gastroenteropancreatic neuroendocrine tumors: a systematic review and meta-analysis. *J Nucl Med.* 2016. doi: [10.2967/jnumed.115.16580](https://doi.org/10.2967/jnumed.115.16580)
116. Reubi JC, Schär JC, Waser B, et al. Affinity profiles for human somatostatin receptor subtypes SST1–SST5 of somatostatin radiotracers selected for scintigraphic and radiotherapeutic use. *Eur J Nucl Med.* 2000; 27(3): 273–282, indexed in Pubmed: 10774879.
117. Caplin ME, Pavel M, Cwikla JB, et al. CLARINET Investigators. Lanreotide in metastatic enteropancreatic neuroendocrine tumors. *N Engl J Med.* 2014; 371(3): 224–233, doi: [10.1056/NEJMoa1316158](https://doi.org/10.1056/NEJMoa1316158), indexed in Pubmed: 25014687.
118. Reubi JC, Schär JC, Waser B, et al. Affinity profiles for human somatostatin receptor subtypes SST1–SST5 of somatostatin radiotracers selected for scintigraphic and radiotherapeutic use. *Eur J Nucl Med.* 2000; 27(3): 273–282, indexed in Pubmed: 10774879.
119. Decristoforo C, Mather SJ, Cholewinski W, et al. 99mTc-EDDA/HYNIC-TOC: a new 99mTc-labelled radiopharmaceutical for imaging somatostatin receptor-positive tumours; first clinical results and intra-patient comparison with 111In-labelled octreotide derivatives. *Eur J Nucl Med.* 2000; 27(9): 1318–1325, indexed in Pubmed: 11007513.
120. Hubalewska-Dydejczyk A, Fröss-Baron K, Mikolajczak R, et al. 99mTc-EDDA/HYNIC-octreotate scintigraphy, an efficient method for the detection and staging of carcinoid tumours: results of 3 years' experience. *Eur J Nucl Med Mol Imaging.* 2006; 33(10): 1123–1133, doi: [10.1007/s00259-006-0113-7](https://doi.org/10.1007/s00259-006-0113-7), indexed in Pubmed: 16721571.
121. Cwikla JB, Mikolajczak R, Pawlak D, et al. Initial direct comparison of 99mTc-TOC and 99mTc-TATE in identifying sites of disease in patients with proven GEP-NETs. *J Nucl Med.* 2008; 49(7): 1060–1065, doi: [10.2967/jnumed.107.046961](https://doi.org/10.2967/jnumed.107.046961), indexed in Pubmed: 18552141.
122. Gabriel M, Decristoforo C, Donnemiller E, et al. An intrapatient comparison of 99mTc-EDDA/HYNIC-TOC with 111In-DTPA-octreotide for diagnosis of somatostatin receptor-expressing tumors. *J Nucl Med.* 2003; 44(5): 708–716, indexed in Pubmed: 12732671.
123. Krausz Y, Freedman N, Rubinstein R, et al. 68Ga-DOTA-NOC PET/CT imaging of neuroendocrine tumors: comparison with 111In-DTPA-octreotide (OctreoScan®). *Mol Imaging Biol.* 2011; 13(3): 583–593, doi: [10.1007/s11307-010-0374-1](https://doi.org/10.1007/s11307-010-0374-1), indexed in Pubmed: 20652423.
124. Ambrosini V, Campana D, Bodei L, et al. 68Ga-DOTANOC PET/CT clinical impact in patients with neuroendocrine tumors. *J Nucl Med.* 2010; 51(5): 669–673, doi: [10.2967/jnumed.109.071712](https://doi.org/10.2967/jnumed.109.071712), indexed in Pubmed: 20395323.
125. Virgolini I, Ambrosini V, Bomanji JB, et al. Procedure guidelines for PET/CT tumour imaging with 68Ga-DOTA-conjugated peptides: 68Ga-DOTA-TOC, 68Ga-DOTA-NOC, 68Ga-DOTA-IATE. *Eur J Nucl Med Mol Imaging.* 2010; 37(10): 2004–2010, doi: [10.1007/s00259-010-1512-3](https://doi.org/10.1007/s00259-010-1512-3), indexed in Pubmed: 20596866.
126. Sadowski SM, Neychev V, Millo C, et al. Prospective Study of 68Ga-DOTATATE Positron Emission Tomography/Computed Tomography for Detecting Gastro-Entero-Pancreatic Neuroendocrine Tumors and Unknown Primary Sites. *J Clin Oncol.* 2016; 34(6): 588–596, doi: [10.1200/JCO.2015.64.0987](https://doi.org/10.1200/JCO.2015.64.0987), indexed in Pubmed: 26712231.

127. Frilling A, Sotiropoulos GC, Radtke A, et al. The impact of 68Ga-DOTATOC positron emission tomography/computed tomography on the multimodal management of patients with neuroendocrine tumors. *Ann Surg.* 2010; 252(5): 850–856, doi: [10.1097/SLA.0b013e3181fd37e8](https://doi.org/10.1097/SLA.0b013e3181fd37e8), indexed in Pubmed: 21037441.
128. Ruf J, Heuck F, Schiefer J, et al. Impact of Multiphase 68Ga-DOTATOC-PET/CT on therapy management in patients with neuroendocrine tumors. *Neuroendocrinology.* 2010; 91(1): 101–109, doi: [10.1159/000265561](https://doi.org/10.1159/000265561), indexed in Pubmed: 19996582.
129. Kaemmerer D, Peter L, Lupp A, et al. Molecular imaging with ⁶⁸Ga-SSTR PET/CT and correlation to immunohistochemistry of somatostatin receptors in neuroendocrine tumours. *Eur J Nucl Med Mol Imaging.* 2011; 38(9): 1659–1668, doi: [10.1007/s00259-011-1846-5](https://doi.org/10.1007/s00259-011-1846-5), indexed in Pubmed: 21626438.
130. Kwekkeboom DJ, Teunissen JJ, Bakker WH, et al. Radiolabeled somatostatin analog [¹⁷⁷Lu-DOTA0,Tyr3]octreotate in patients with endocrine gastroenteropancreatic tumors. *J Clin Oncol.* 2005; 23(12): 2754–2762, doi: [10.1200/JCO.2005.08.066](https://doi.org/10.1200/JCO.2005.08.066), indexed in Pubmed: 15837990.
131. Kunikowska J, Królicki L, Pawlak D, et al. Semiquantitative analysis and characterization of physiological biodistribution of (68)Ga-DOTA-TATE PET/CT. *Clin Nucl Med.* 2012; 37(11): 1052–1057, doi: [10.1097/RLU.0b013e31825b2555](https://doi.org/10.1097/RLU.0b013e31825b2555), indexed in Pubmed: 22996234.
132. Kratochwil C, Stefanova M, Mavriopoulou E, et al. SUV of [68Ga] DOTATOC-PET/CT Predicts Response Probability of PRRT in Neuroendocrine Tumors. *Mol Imaging Biol.* 2015; 17(3): 313–318, doi: [10.1007/s11307-014-0795-3](https://doi.org/10.1007/s11307-014-0795-3), indexed in Pubmed: 25319765.
133. Pfeifer A, Knigge U, Binderup T, et al. ⁶⁴Cu-DOTATATE PET for Neuroendocrine Tumors: A Prospective Head-to-Head Comparison with ¹¹¹In-DTPA-Octreotide in 112 Patients. *J Nucl Med.* 2015; 56(6): 847–854, doi: [10.2967/jnumed.115.156539](https://doi.org/10.2967/jnumed.115.156539), indexed in Pubmed: 25952736.
134. Johnbeck CB, Knigge U, Loft A, et al. Head-to-Head Comparison of (64) Cu-DOTATATE and (68)Ga-DOTATOC PET/CT: A Prospective Study of 59 Patients with Neuroendocrine Tumors. *J Nucl Med.* 2017; 58(3): 451–457, doi: [10.2967/jnumed.116.180430](https://doi.org/10.2967/jnumed.116.180430), indexed in Pubmed: 27660147.
135. Hubalewska-Dydejczyk A, Kulig J, Szybinski P, et al. Radio-guided surgery with the use of [^{99m}Tc-EDDA/HYNIC]octreotate in intra-operative detection of neuroendocrine tumours of the gastrointestinal tract. *Eur J Nucl Med Mol Imaging.* 2007; 34(10): 1545–1555, doi: [10.1007/s00259-007-0476-4](https://doi.org/10.1007/s00259-007-0476-4), indexed in Pubmed: 17653543.
136. Kunikowska J, Słodkowski M, Koperski L, et al. Radioguided surgery in patient with pancreatic neuroendocrine tumour followed by PET/CT scan as a new approach of complete resection evaluation—case report. *Nucl Med Rev Cent East Eur.* 2014; 17(2): 110–114, doi: [10.5603/NMR.2014.0028](https://doi.org/10.5603/NMR.2014.0028), indexed in Pubmed: 25088113.
137. Binderup T, Knigge U, Loft A, et al. Functional imaging of neuroendocrine tumors: a head-to-head comparison of somatostatin receptor scintigraphy, ¹²³I-MIBG scintigraphy, and ¹⁸F-FDG PET. *J Nucl Med.* 2010; 51(5): 704–712, doi: [10.2967/jnumed.109.069765](https://doi.org/10.2967/jnumed.109.069765), indexed in Pubmed: 20395333.
138. Severi S, Nanni O, Bodei L, et al. Role of ¹⁸FDG PET/CT in patients treated with ¹⁷⁷Lu-DOTATATE for advanced differentiated neuroendocrine tumours. *Eur J Nucl Med Mol Imaging.* 2013; 40(6): 881–888, doi: [10.1007/s00259-013-2369-z](https://doi.org/10.1007/s00259-013-2369-z), indexed in Pubmed: 23443937.
139. July M, Santhanam P, Giovannella L, et al. Role of positron emission tomography imaging in Multiple Endocrine Neoplasia syndromes. *Clin Physiol Funct Imaging.* 2016 [Epub ahead of print], doi: [10.1111/cpf.12391](https://doi.org/10.1111/cpf.12391), indexed in Pubmed: 27677981.
140. Sansovini M, Severi S, Ianniello A, et al. Long-term follow-up and role of FDG PET in advanced pancreatic neuroendocrine patients treated with (¹⁷⁷Lu-D) OTATATE. *Eur J Nucl Med Mol Imaging.* 2017; 44(3): 490–499, doi: [10.1007/s00259-016-3533-z](https://doi.org/10.1007/s00259-016-3533-z), indexed in Pubmed: 27704193.
141. Oh S, Prasad V, Lee DS, et al. Effect of Peptide Receptor Radionuclide Therapy on Somatostatin Receptor Status and Glucose Metabolism in Neuroendocrine Tumors: Intraindividual Comparison of Ga-68 DOTANOC PET/CT and F-18 FDG PET/CT. *Int J Mol Imaging.* 2011; 2011: 524130, doi: [10.1155/2011/524130](https://doi.org/10.1155/2011/524130), indexed in Pubmed: 22121482.
142. Kunikowska J, Królicki L, Pawlak D. Is PET/CT with ¹⁸FDG necessary for qualification patients to Peptide Receptor Radionuclide Therapy (PRRT) –preliminary report? *Eur J Nucl Med Mol Imaging.* 2011; 38: S425–S425.
143. Binderup T, Knigge U, Loft A, et al. ¹⁸F-fluorodeoxyglucose positron emission tomography predicts survival of patients with neuroendocrine tumors. *Clin Cancer Res.* 2010; 16(3): 978–985, doi: [10.1158/1078-0432.CCR-09-1759](https://doi.org/10.1158/1078-0432.CCR-09-1759), indexed in Pubmed: 20103666.
144. Jager PL, Chirakal R, Marriotti CJ, et al. 6-L-¹⁸F-fluorodihydroxyphenylalanine PET in neuroendocrine tumors: basic aspects and emerging clinical applications. *J Nucl Med.* 2008; 49(4): 573–586, doi: [10.2967/jnumed.107.045708](https://doi.org/10.2967/jnumed.107.045708), indexed in Pubmed: 18344441.
145. Ambrosini V, Morigi JJ, Nanni C, et al. Current status of PET imaging of neuroendocrine tumours ([¹⁸F]FDOPA, [⁶⁸Ga]tracers, [¹¹C]/[¹⁸F]-HTP). *Q J Nucl Med Mol Imaging.* 2015; 59(1): 58–69, indexed in Pubmed: 25677589.
146. Balogova S, Talbot JN, Nataf V, et al. ¹⁸F-fluorodihydroxyphenylalanine vs other radiopharmaceuticals for imaging neuroendocrine tumours according to their type. *Eur J Nucl Med Mol Imaging.* 2013; 40(6): 943–966, doi: [10.1007/s00259-013-2342-x](https://doi.org/10.1007/s00259-013-2342-x), indexed in Pubmed: 23417499.
147. Becherer A, Szabó M, Karanikas G, et al. Imaging of advanced neuroendocrine tumors with (¹⁸F)-FDOPA PET. *J Nucl Med.* 2004; 45(7): 1161–1167, indexed in Pubmed: 15235062.
148. Haug A, Auernhammer CJ, Wängler B, et al. Intraindividual comparison of 68Ga-DOTA-TATE and ¹⁸F-DOPA PET in patients with well-differentiated metastatic neuroendocrine tumours. *Eur J Nucl Med Mol Imaging.* 2009; 36(5): 765–770, doi: [10.1007/s00259-008-1030-8](https://doi.org/10.1007/s00259-008-1030-8), indexed in Pubmed: 19137293.
149. Timmers HJ, Chen CC, Carrasquillo JA, et al. Comparison of ¹⁸F-fluoro-L-DOPA, ¹⁸F-fluoro-deoxyglucose, and ¹⁸F-fluorodopamine PET and ¹²³I-MIBG scintigraphy in the localization of pheochromocytoma and paraganglioma. *J Clin Endocrinol Metab.* 2009; 94(12): 4757–4767, doi: [10.1210/jc.2009.1248](https://doi.org/10.1210/jc.2009.1248), indexed in Pubmed: 19864450.
150. Binderup T, Knigge U, Loft A, et al. Functional imaging of neuroendocrine tumors: a head-to-head comparison of somatostatin receptor scintigraphy, ¹²³I-MIBG scintigraphy, and ¹⁸F-FDG PET. *J Nucl Med.* 2010; 51(5): 704–712, doi: [10.2967/jnumed.109.069765](https://doi.org/10.2967/jnumed.109.069765), indexed in Pubmed: 20395333.
151. Wild D, Christ E, Caplin ME, et al. Glucagon-like peptide-1 versus somatostatin receptor targeting reveals 2 distinct forms of malignant insulinomas. *J Nucl Med.* 2011; 52(7): 1073–1078, doi: [10.2967/jnumed.110.085142](https://doi.org/10.2967/jnumed.110.085142), indexed in Pubmed: 21680696.
152. Sowa-Staszczak A, Pach D, Mikołajczak R, et al. Glucagon-like peptide-1 receptor imaging with [^{99m}Tc-EDDA(99mTc)/EDDA]NH₂-exendin-4 for the detection of insulinoma. *Eur J Nucl Med Mol Imaging.* 2013; 40(4): 524–531, doi: [10.1007/s00259-012-2299-1](https://doi.org/10.1007/s00259-012-2299-1), indexed in Pubmed: 23224740.
153. Sowa-Staszczak A, Trofimiuk-Müldner M, Stefańska A, et al. ^{99m}Tc Labeled Glucagon-Like Peptide-1-Analogue (^{99m}Tc-GLP1) Scintigraphy in the Management of Patients with Occult Insulinoma. *PLoS One.* 2016; 11(8): e0160714, doi: [10.1371/journal.pone.0160714](https://doi.org/10.1371/journal.pone.0160714), indexed in Pubmed: 27526057.
154. Kunikowska J, Ziemińska K, Pawlak D, et al. Medullary thyroid carcinoma - PET/CT imaging with 68Ga-labelled gastrin and somatostatin analogues. *Endokrynol Pol.* 2016; 67(1): 68–71, doi: [10.5603/EP2016.0010](https://doi.org/10.5603/EP2016.0010), indexed in Pubmed: 26884118.
155. Luo Y, Yu M, Pan Q, et al. ⁶⁸Ga-NOTA-exendin-4 PET/CT in detection of occult insulinoma and evaluation of physiological uptake. *Eur J Nucl Med Mol Imaging.* 2015; 42(3): 531–532, doi: [10.1007/s00259-014-2946-9](https://doi.org/10.1007/s00259-014-2946-9), indexed in Pubmed: 25398421.
156. Gurusamy K, Davidson B. Diagnostic accuracy of different imaging modalities following computed tomography (CT) scanning for assessing the resectability with curative intent in pancreatic and periampullary cancer. *Cochrane Database of Systematic Reviews.* 2015, doi: [10.1002/14651858.cd011515](https://doi.org/10.1002/14651858.cd011515).
157. Garcia-Carbonero R, Sorbye H, Baudin E, et al. Vienna Consensus Conference participants. ENETS Consensus Guidelines for High-Grade Gastroenteropancreatic Neuroendocrine Tumors and Neuroendocrine Carcinomas. *Neuroendocrinology.* 2016; 103(2): 186–194, doi: [10.1159/000443172](https://doi.org/10.1159/000443172), indexed in Pubmed: 26731334.
158. Pavel M, O’Toole D, Costa F, et al. Vienna Consensus Conference participants. ENETS Consensus Guidelines Update for the Management of Distant Metastatic Disease of Intestinal, Pancreatic, Bronchial Neuroendocrine Neoplasms (NEN) and NEN of Unknown Primary Site. *Neuroendocrinology.* 2016; 103(2): 172–185, doi: [10.1159/000443167](https://doi.org/10.1159/000443167), indexed in Pubmed: 26731013.
159. Bacchetti S, Pasqual EM, Bertozzi S, et al. Curative versus palliative surgical resection of liver metastases in patients with neuroendocrine tumors: a meta-analysis of observational studies. *Gland Surg.* 2014; 3(4): 243–251, doi: [10.3978/j.issn.2227-684X.2014.02.05](https://doi.org/10.3978/j.issn.2227-684X.2014.02.05), indexed in Pubmed: 25493256.
160. Maxwell JE, Sherman SK, O’Dorisio TM, et al. Liver-directed surgery of neuroendocrine metastases: What is the optimal strategy? *Surgery.* 2016; 159(1): 320–333, doi: [10.1016/j.surg.2015.05.040](https://doi.org/10.1016/j.surg.2015.05.040), indexed in Pubmed: 26454679.
161. Lee SY, Cheow PC, Teo JY, et al. Surgical treatment of neuroendocrine liver metastases. *Int J Hepatol.* 2012; 2012: 146590, doi: [10.1155/2012/146590](https://doi.org/10.1155/2012/146590), indexed in Pubmed: 22319650.
162. Guo J, Zhang Q, Bi X, et al. Systematic review of resecting primary tumor in MNETs patients with unresectable liver metastases. *Oncotarget.* 2016 [Epub ahead of print], doi: [10.18632/oncotarget.14156](https://doi.org/10.18632/oncotarget.14156), indexed in Pubmed: 28030811.
163. Le Treut YP, Grégoire E, Klempnauer J, et al. For ELITA. Liver transplantation for neuroendocrine tumors in Europe — results and trends in patient selection: a 213-case European liver transplant registry study. *Ann Surg.* 2013; 257(5): 807–815, doi: [10.1097/SLA.0b013e31828ee17c](https://doi.org/10.1097/SLA.0b013e31828ee17c), indexed in Pubmed: 23532105.
164. Lerut JP, Orlando G, Adam R, et al. European Liver Transplant Registry. The place of liver transplantation in the treatment of hepatic epithelioid hemangioendothelioma: report of the European liver transplant registry. *Ann Surg.* 2007; 246(6): 949–57; discussion 957, doi: [10.1097/SLA.0b013e31815c2a70](https://doi.org/10.1097/SLA.0b013e31815c2a70), indexed in Pubmed: 18043096.

165. Gu P, Wu J, Newman E, et al. Treatment of liver metastases in patients with neuroendocrine tumors of gastroesophageal and pancreatic origin. *Int J Hepatol.* 2012; 2012: 131659, doi: [10.1155/2012/131659](https://doi.org/10.1155/2012/131659), indexed in Pubmed: [22518318](https://pubmed.ncbi.nlm.nih.gov/22518318/).
166. Sher LS, Levi DM, Wechsler JS, et al. Liver transplantation for metastatic neuroendocrine tumors: Outcomes and prognostic variables. *J Surg Oncol.* 2015; 112(2): 125–132, doi: [10.1002/jso.23973](https://doi.org/10.1002/jso.23973), indexed in Pubmed: [26171686](https://pubmed.ncbi.nlm.nih.gov/26171686/).
167. Fendrich V, Bartsch DK. Surgical treatment of gastrointestinal neuroendocrine tumors. *Langenbecks Arch Surg.* 2011; 396(3): 299–311, doi: [10.1007/s00423-011-0741-7](https://doi.org/10.1007/s00423-011-0741-7), indexed in Pubmed: [21279821](https://pubmed.ncbi.nlm.nih.gov/21279821/).
168. Turaga KK, Kvols LK. Recent progress in the understanding, diagnosis, and treatment of gastroenteropancreatic neuroendocrine tumors. *CA Cancer J Clin.* 2011; 61(2): 113–132, doi: [10.3322/caac.20097](https://doi.org/10.3322/caac.20097), indexed in Pubmed: [21388967](https://pubmed.ncbi.nlm.nih.gov/21388967/).
169. Evans JA, Chandrasekhara V, Chathadi KV, et al. ASGE Standards of Practice Committee. The role of endoscopy in the management of premalignant and malignant conditions of the stomach. *Gastrointest Endosc.* 2015; 82(1): 1–8, doi: [10.1016/j.gie.2015.03.1967](https://doi.org/10.1016/j.gie.2015.03.1967), indexed in Pubmed: [25935705](https://pubmed.ncbi.nlm.nih.gov/25935705/).
170. Basuroy R, Srirajaskanthan R, Prachalias A, et al. Review article: the investigation and management of gastric neuroendocrine tumours. *Aliment Pharmacol Ther.* 2014; 39(10): 1071–1084, doi: [10.1111/apt.12698](https://doi.org/10.1111/apt.12698), indexed in Pubmed: [24628514](https://pubmed.ncbi.nlm.nih.gov/24628514/).
171. Antillon MR, Chen Y. Leczenie endoskopowe nowotworów żołądka. In: Ginsber G, Kochman ML, Norton J, Gostout ChJ (eds.). *Kliniczna endoskopia przewodu pokarmowego*. Medipage, Warszawa 2009: 533–560.
172. Gotoda T, Kondo H, Ono H, et al. A new endoscopic mucosal resection procedure using an insulation-tipped electrosurgical knife for rectal flat lesions: report of two cases. *Gastrointest Endosc.* 1999; 50(4): 560–563, indexed in Pubmed: [10502182](https://pubmed.ncbi.nlm.nih.gov/10502182/).
173. Scherübl H, Cadiot G, Jensen RT, et al. Neuroendocrine tumors of the stomach (gastric carcinoids) are on the rise: small tumors, small problems? *Endoscopy.* 2010; 42(8): 664–671, doi: [10.1055/s-0030-1255564](https://doi.org/10.1055/s-0030-1255564), indexed in Pubmed: [20669078](https://pubmed.ncbi.nlm.nih.gov/20669078/).
174. Li QL, Zhang YQ, Chen WF, et al. Endoscopic submucosal dissection for foregut neuroendocrine tumors: an initial study. *World J Gastroenterol.* 2012; 18(40): 5799–5806, doi: [10.3748/wjg.v18.i40.5799](https://doi.org/10.3748/wjg.v18.i40.5799), indexed in Pubmed: [23155323](https://pubmed.ncbi.nlm.nih.gov/23155323/).
175. Son HJ, Sohn DK, Hong CW, et al. Factors associated with complete local excision of small rectal carcinoid tumor. *Int J Colorectal Dis.* 2013; 28(1): 57–61, doi: [10.1007/s00384-012-1538-z](https://doi.org/10.1007/s00384-012-1538-z), indexed in Pubmed: [22821140](https://pubmed.ncbi.nlm.nih.gov/22821140/).
176. Ishii N, Horiki N, Itoh T, et al. Endoscopic submucosal dissection and preoperative assessment with endoscopic ultrasonography for the treatment of rectal carcinoid tumors. *Surg Endosc.* 2010; 24(6): 1413–1419, doi: [10.1007/s00464-009-0791-x](https://doi.org/10.1007/s00464-009-0791-x), indexed in Pubmed: [20033710](https://pubmed.ncbi.nlm.nih.gov/20033710/).
177. Pimentel-Nunes P, Dinis-Ribeiro M, Ponchon T, et al. Endoscopic submucosal dissection: European Society of Gastrointestinal Endoscopy (ESGE) Guideline. *Endoscopy.* 2015; 47(9): 829–854, doi: [10.1055/s-0034-1392882](https://doi.org/10.1055/s-0034-1392882), indexed in Pubmed: [26317585](https://pubmed.ncbi.nlm.nih.gov/26317585/).
178. Lee EJ, Lee JB, Lee SH, et al. Endoscopic submucosal dissection for colorectal tumors—1,000 colorectal ESD cases: one specialized institute's experiences. *Surg Endosc.* 2013; 27(1): 31–39, doi: [10.1007/s00464-012-2403-4](https://doi.org/10.1007/s00464-012-2403-4), indexed in Pubmed: [22729707](https://pubmed.ncbi.nlm.nih.gov/22729707/).
179. Arnold R, Chen YJ, Costa F, et al. Mallorca Consensus Conference participants, European Neuroendocrine Tumor Society. ENETS Consensus Guidelines for the Standards of Care in Neuroendocrine Tumors: follow-up and documentation. *Neuroendocrinology.* 2009; 90(2): 227–233, doi: [10.1159/000225952](https://doi.org/10.1159/000225952), indexed in Pubmed: [19713715](https://pubmed.ncbi.nlm.nih.gov/19713715/).
180. Armellini E, Crinò S, Ballarè M, et al. Endoscopic ultrasound-guided radiofrequency ablation of a pancreatic neuroendocrine tumor. *Endoscopy.* 2015; 47(S 01): E600–E601, doi: [10.1055/s-0034-1393677](https://doi.org/10.1055/s-0034-1393677).
181. Bhutani MS, Arora A. New developments in endoscopic ultrasound-guided therapies. *Endosc Ultrasound.* 2015; 4(4): 304–311, doi: [10.4103/2303-9027.170419](https://doi.org/10.4103/2303-9027.170419), indexed in Pubmed: [26643698](https://pubmed.ncbi.nlm.nih.gov/26643698/).
182. Öberg K, Lamberts SWJ. Somatostatin analogues in acromegaly and gastroenteropancreatic neuroendocrine tumours: past, present and future. *Endocr Relat Cancer.* 2016; 23(12): R551–R566, doi: [10.1530/ERC-16-0151](https://doi.org/10.1530/ERC-16-0151), indexed in Pubmed: [27697899](https://pubmed.ncbi.nlm.nih.gov/27697899/).
183. Melen-Mucha G, Lawnicka H, Kierszniewska-Stepien D, et al. The place of somatostatin analogs in the diagnosis and treatment of the neuroendocrine glands tumors. *Recent Pat Anticancer Drug Discov.* 2006; 1(2): 237–254, indexed in Pubmed: [18221040](https://pubmed.ncbi.nlm.nih.gov/18221040/).
184. Pisarek H, Pawlikowski M, Kunert-Radek J, et al. SSTR1 and SSTR5 subtypes are the dominant forms of somatostatin receptor in neuroendocrine tumors. *Folia Histochem Cytobiol.* 2010; 48(1): 142–147, doi: [10.2478/v10042-008-0103-7](https://doi.org/10.2478/v10042-008-0103-7), indexed in Pubmed: [20529830](https://pubmed.ncbi.nlm.nih.gov/20529830/).
185. Orlewska E, Bednarczuk T, Kaminski G, et al. LanroNET study group*. LanroNET, a non-interventional, prospective study to assess the resource utilization and cost of lanreotide autogel 120 mg in Polish patients with neuroendocrine tumors - results of interim analysis. *Contemp Oncol (Pozn).* 2014; 18(6): 442–447, doi: [10.5114/wo.2014.47908](https://doi.org/10.5114/wo.2014.47908), indexed in Pubmed: [25784845](https://pubmed.ncbi.nlm.nih.gov/25784845/).
186. Jawarczyk A, Bolanowski M, Strycka J, et al. Effective therapy of insulinoma by using long-acting somatostatin analogue. A case report and literature review. *Exp Clin Endocrinol Diabetes.* 2012; 120(2): 68–72, doi: [10.1055/s-0031-1287792](https://doi.org/10.1055/s-0031-1287792), indexed in Pubmed: [22187292](https://pubmed.ncbi.nlm.nih.gov/22187292/).
187. Rosiek V, Kunikowska J, Kos-Kudła B. A non-functioning pancreatic neuroendocrine tumour: a case report. *Endokrynol Pol.* 2012; 63(1): 59–64, indexed in Pubmed: [22378100](https://pubmed.ncbi.nlm.nih.gov/22378100/).
188. Rinke A, Müller HH, Schade-Brittinger C, et al. PROMID Study Group. Placebo-controlled, double-blind, prospective, randomized study on the effect of octreotide LAR in the control of tumor growth in patients with metastatic neuroendocrine midgut tumors: a report from the PROMID Study Group. *J Clin Oncol.* 2009; 27(28): 4656–4663, doi: [10.1200/JCO.2009.22.8510](https://doi.org/10.1200/JCO.2009.22.8510), indexed in Pubmed: [19704057](https://pubmed.ncbi.nlm.nih.gov/19704057/).
189. Kos-Kudła B. Treatment of neuroendocrine tumors: new recommendations based on the CLARINET study. *Contemp Oncol (Pozn).* 2015; 19(5): 345–349, doi: [10.5114/wo.2015.56006](https://doi.org/10.5114/wo.2015.56006), indexed in Pubmed: [26793016](https://pubmed.ncbi.nlm.nih.gov/26793016/).
190. Caplin ME, Pavel M, Ćwikła JB, et al. CLARINET Investigators. Antitumour effects of lanreotide for pancreatic and intestinal neuroendocrine tumours: the CLARINET open-label extension study. *Endocr Relat Cancer.* 2016; 23(3): 191–199, doi: [10.1530/ERC-15-0490](https://doi.org/10.1530/ERC-15-0490), indexed in Pubmed: [26743120](https://pubmed.ncbi.nlm.nih.gov/26743120/).
191. Cidon EU. New therapeutic approaches to metastatic gastroenteropancreatic neuroendocrine tumors: A glimpse into the future. *World J Gastrointest Oncol.* 2017; 9(1): 4–20, doi: [10.4251/wjgo.v9.i1.4](https://doi.org/10.4251/wjgo.v9.i1.4), indexed in Pubmed: [28144395](https://pubmed.ncbi.nlm.nih.gov/28144395/).
192. Öberg K. (ed.). *Advances in Neuroendocrine Tumor Management*. Future Medicine October 2011. Ebook pages 52-63, doi: [10.2217/ebo.11.89](https://doi.org/10.2217/ebo.11.89).
193. Pisegna JR. (ed.). *Management of Pancreatic Neuroendocrine Tumors*. Springer, New York 2014: 65–75.
194. Okusaka T, Ueno H, Morizane C, et al. Cytotoxic chemotherapy for pancreatic neuroendocrine tumors. *J Hepatobiliary Pancreat Sci.* 2015; 22(8): 628–633, doi: [10.1002/jhbp.257](https://doi.org/10.1002/jhbp.257), indexed in Pubmed: [25940377](https://pubmed.ncbi.nlm.nih.gov/25940377/).
195. Strosberg JR, Fine RL, Choi J, et al. First-line chemotherapy with capecitabine and temozolomide in patients with metastatic pancreatic endocrine carcinomas. *Cancer.* 2011; 117(2): 268–275, doi: [10.1002/cncr.25425](https://doi.org/10.1002/cncr.25425), indexed in Pubmed: [20824724](https://pubmed.ncbi.nlm.nih.gov/20824724/).
196. Moertel CG, Hanley JA, Johnson LA. Streptozocin alone compared with streptozocin plus fluorouracil in the treatment of advanced islet-cell carcinoma. *N Engl J Med.* 1980; 303(21): 1189–1194, doi: [10.1056/NEJM198011203032101](https://doi.org/10.1056/NEJM198011203032101), indexed in Pubmed: [6252466](https://pubmed.ncbi.nlm.nih.gov/6252466/).
197. Dilz LM, Denecke T, Steffen IG, et al. Streptozocin/5-fluorouracil chemotherapy is associated with durable response in patients with advanced pancreatic neuroendocrine tumours. *Eur J Cancer.* 2015; 51(10): 1253–1262, doi: [10.1016/j.ejca.2015.04.005](https://doi.org/10.1016/j.ejca.2015.04.005), indexed in Pubmed: [25935542](https://pubmed.ncbi.nlm.nih.gov/25935542/).
198. Meyer T, Qian W, Caplin ME, et al. Capecitabine and streptozocin ± cisplatin in advanced gastroenteropancreatic neuroendocrine tumours. *Eur J Cancer.* 2014; 50(5): 902–911, doi: [10.1016/j.ejca.2013.12.011](https://doi.org/10.1016/j.ejca.2013.12.011), indexed in Pubmed: [24445147](https://pubmed.ncbi.nlm.nih.gov/24445147/).
199. Turner NC, Strauss SJ, Sarker D, et al. Chemotherapy with 5-fluorouracil, cisplatin and streptozocin for neuroendocrine tumours. *Br J Cancer.* 2010; 102(7): 1106–1112, doi: [10.1038/sj.bjc.6605618](https://doi.org/10.1038/sj.bjc.6605618), indexed in Pubmed: [20234360](https://pubmed.ncbi.nlm.nih.gov/20234360/).
200. Moertel CG, Lefkopoulo M, Lipsitz S, et al. Streptozocin-doxorubicin, streptozocin-fluorouracil or chlorozotocin in the treatment of advanced islet-cell carcinoma. *N Engl J Med.* 1992; 326(8): 519–523, doi: [10.1056/NEJM199202203260804](https://doi.org/10.1056/NEJM199202203260804), indexed in Pubmed: [1310159](https://pubmed.ncbi.nlm.nih.gov/1310159/).
201. Pavel M, O'Toole D, Costa F, et al. Vienna Consensus Conference participants. ENETS Consensus Guidelines Update for the Management of Distant Metastatic Disease of Intestinal, Pancreatic, Bronchial Neuroendocrine Neoplasms (NEN) and NEN of Unknown Primary Site. *Neuroendocrinology.* 2016; 103(2): 172–185, doi: [10.1159/000443167](https://doi.org/10.1159/000443167), indexed in Pubmed: [26731013](https://pubmed.ncbi.nlm.nih.gov/26731013/).
202. Chan JA, Stuart K, Earle CC, et al. Prospective study of bevacizumab plus temozolomide in patients with advanced neuroendocrine tumors. *J Clin Oncol.* 2012; 30(24): 2963–2968, doi: [10.1200/JCO.2011.40.3147](https://doi.org/10.1200/JCO.2011.40.3147), indexed in Pubmed: [22778320](https://pubmed.ncbi.nlm.nih.gov/22778320/).
203. Kulke MH, Stuart K, Enzinger PC, et al. Phase II study of temozolomide and thalidomide in patients with metastatic neuroendocrine tumors. *J Clin Oncol.* 2006; 24(3): 401–406, doi: [10.1200/JCO.2005.03.6046](https://doi.org/10.1200/JCO.2005.03.6046), indexed in Pubmed: [16421420](https://pubmed.ncbi.nlm.nih.gov/16421420/).
204. Kulke MH, Hornick JL, Fraumeni JF, et al. O6-methylguanine DNA methyltransferase deficiency and response to temozolomide-based therapy in patients with neuroendocrine tumors. *Clin Cancer Res.* 2009; 15(1): 338–345, doi: [10.1158/1078-0432.CCR-08-1476](https://doi.org/10.1158/1078-0432.CCR-08-1476), indexed in Pubmed: [19118063](https://pubmed.ncbi.nlm.nih.gov/19118063/).
205. Cives M, Ghayouri M, Morse B, et al. Analysis of potential response predictors to capecitabine/temozolomide in metastatic pancreatic

- neuroendocrine tumors. *Endocr Relat Cancer*. 2016; 23(9): 759–767, doi: [10.1530/ERC-16-0147](https://doi.org/10.1530/ERC-16-0147), indexed in Pubmed: 27552969.
206. Cros J, Hentic O, Rebours V, et al. MGMT expression predicts response to temozolomide in pancreatic neuroendocrine tumors. *Endocr Relat Cancer*. 2016; 23(8): 625–633, doi: [10.1530/ERC-16-0117](https://doi.org/10.1530/ERC-16-0117), indexed in Pubmed: 27353036.
207. Kolasinska-Cwikla A. Chemioterapia w guzach neuroendokrynych układu pokarmowego (GEP-NEN). *OncoReview* 2012; 2(4): 255–261.
208. Cassier PA, Walter T, Eymard B, et al. Gemcitabine and oxaliplatin combination chemotherapy for metastatic well-differentiated neuroendocrine carcinomas: a single-center experience. *Cancer*. 2009; 115(15): 3392–3399, doi: [10.1002/cncr.24384](https://doi.org/10.1002/cncr.24384), indexed in Pubmed: 19472402.
209. Öberg K. Management of neuroendocrine tumours. *Ann. Oncol*. 2004; suppl. 4: 293–8.
210. O'Toole D, Hentic O, Corcos O, et al. Chemotherapy for gastro-enteropancreatic endocrine tumours. *Neuroendocrinology*. 2004; 80 Suppl 1: 79–84, doi: [10.1159/000080747](https://doi.org/10.1159/000080747), indexed in Pubmed: 15477723.
211. Fine RL, Gulati AP, Krantz BA, et al. Capecitabine and temozolomide (CAPTEM) for metastatic, well-differentiated neuroendocrine cancers: The Pancreas Center at Columbia University experience. *Cancer Chemother Pharmacol*. 2013; 71(3): 663–670, doi: [10.1007/s00280-012-2055-z](https://doi.org/10.1007/s00280-012-2055-z), indexed in Pubmed: 23370660.
212. Spada F, Antonuzzo L, Marconcini R, et al. Oxaliplatin-Based Chemotherapy in Advanced Neuroendocrine Tumors: Clinical Outcomes and Preliminary Correlation with Biological Factors. *Neuroendocrinology*. 2016; 103(6): 806–814, doi: [10.1159/000444087](https://doi.org/10.1159/000444087), indexed in Pubmed: 26789262.
213. Wada Y, Hirayama Y, Seki R, et al. [Long-term remission survival with a case of rectal carcinoid tumor with metastasis in the soft tissue effectively treated with the combination therapy of irinotecan/5-fluorouracil/levofolinate followed by resection]. *Nihon Naika Gakkai Zasshi*. 2007; 96(11): 2513–2515, indexed in Pubmed: 18069303.
214. Moertel C, Kvols L, O'Connell M, et al. Treatment of neuroendocrine carcinomas with combined etoposide and cisplatin. Evidence of major therapeutic activity in the anaplastic variants of these neoplasms. *Cancer*. 1991; 68(2): 227–232, doi: [10.1002/1097-0142\(19910715\)68:2<227::aid-cncr2820680202>3.0.co;2-i](https://doi.org/10.1002/1097-0142(19910715)68:2<227::aid-cncr2820680202>3.0.co;2-i).
215. Mitry E, Baudin E, Ducreux M, et al. Treatment of poorly differentiated neuroendocrine tumours with etoposide and cisplatin. *Br J Cancer*. 1999; 81(8): 1351–1355, doi: [10.1038/sj.bjc.6690325](https://doi.org/10.1038/sj.bjc.6690325), indexed in Pubmed: 10604732.
216. Sorbye H, Welin S, Langer SW, et al. Predictive and prognostic factors for treatment and survival in 305 patients with advanced gastrointestinal neuroendocrine carcinoma (WHO G3): the NORDIC NEC study. *Ann Oncol*. 2013; 24(1): 152–160, doi: [10.1093/annonc/mds276](https://doi.org/10.1093/annonc/mds276), indexed in Pubmed: 22967994.
217. Welin S, Sorbye H, Sebjornsen S, et al. Clinical effect of temozolomide-based chemotherapy in poorly differentiated endocrine carcinoma after progression on first-line chemotherapy. *Cancer*. 2011; 117(20): 4617–4622, doi: [10.1002/cncr.26124](https://doi.org/10.1002/cncr.26124), indexed in Pubmed: 21456005.
218. Bajetta E, Catena L, Procopio G, et al. Are capecitabine and oxaliplatin (XELOX) suitable treatments for progressing low-grade and high-grade neuroendocrine tumours? *Cancer Chemother Pharmacol*. 2007; 59(5): 637–642, doi: [10.1007/s00280-006-0306-6](https://doi.org/10.1007/s00280-006-0306-6), indexed in Pubmed: 16937105.
219. Hainsworth JD, Spigel DR, Litchy S, et al. Phase II trial of paclitaxel, carboplatin, and etoposide in advanced poorly differentiated neuroendocrine carcinoma: a Minnie Pearl Cancer Research Network Study. *J Clin Oncol*. 2006; 24(22): 3548–3554, doi: [10.1200/JCO.2005.05.0575](https://doi.org/10.1200/JCO.2005.05.0575), indexed in Pubmed: 16877720.
220. Okita NT, Kato K, Takahashi D, et al. Neuroendocrine tumors of the stomach: chemotherapy with cisplatin plus irinotecan is effective for gastric poorly-differentiated neuroendocrine carcinoma. *Gastric Cancer*. 2011; 14(2): 161–165, doi: [10.1007/s10120-011-0025-5](https://doi.org/10.1007/s10120-011-0025-5), indexed in Pubmed: 21327441.
221. Nakano K, Takahashi S, Yuasa T, et al. Feasibility and efficacy of combined cisplatin and irinotecan chemotherapy for poorly differentiated neuroendocrine carcinomas. *Jpn J Clin Oncol*. 2012; 42(8): 697–703, doi: [10.1093/jjco/hys085](https://doi.org/10.1093/jjco/hys085), indexed in Pubmed: 22701038.
222. Okuma HS, Iwasa S, Shoji H, et al. Irinotecan plus cisplatin in patients with extensive-disease poorly differentiated neuroendocrine carcinoma of the esophagus. *Anticancer Res*. 2014; 34(9): 5037–5041, indexed in Pubmed: 25202088.
223. Ramella Munhoz R, de Mendonça Rego JF, de Celis Ferrari AR, et al. Combination of irinotecan and a platinum agent for poorly differentiated neuroendocrine carcinomas. *Rare Tumors*. 2013; 5(3): e39, doi: [10.4081/rt.2013.e39](https://doi.org/10.4081/rt.2013.e39), indexed in Pubmed: 24179651.
224. Sorbye H, Strosberg J, Baudin E, et al. Gastroenteropancreatic high-grade neuroendocrine carcinoma. *Cancer*. 2014; 120(18): 2814–2823, doi: [10.1002/cncr.28721](https://doi.org/10.1002/cncr.28721), indexed in Pubmed: 24771552.
225. Yao JC, Shah MH, Ito T, et al. RAD001 in Advanced Neuroendocrine Tumors, Third Trial (RADIANT-3) Study Group. Everolimus for advanced pancreatic neuroendocrine tumors. *N Engl J Med*. 2011; 364(6): 514–523, doi: [10.1056/NEJMoa1009290](https://doi.org/10.1056/NEJMoa1009290), indexed in Pubmed: 21306238.
226. Raymond E, Dahan L, Raoul JL, et al. Sunitinib malate for the treatment of pancreatic neuroendocrine tumors. *N Engl J Med*. 2011; 364(6): 501–513, doi: [10.1056/NEJMoa1003825](https://doi.org/10.1056/NEJMoa1003825), indexed in Pubmed: 21306237.
227. Rosiek V, Kos-Kudła B. Terapie celowane w nowotworach neuroendokrynych, Targeted therapies in neuroendocrine neoplasms. *OncoReview*. 2012; 2(3): 163–170.
228. ChPL – Afinitor (everolimus) - <https://ec.europa.eu/health/documents/community-register>.
229. ChPL – Sutent (sunitinib) - <https://ec.europa.eu/health/documents/community-register>.
230. Yao JC, Fazio N, Singh S, et al. RAD001 in Advanced Neuroendocrine Tumours, Fourth Trial (RADIANT-4) Study Group. *Lancet*. 2016 Mar 5; 387(10022): 968–77.
231. Grande E. Sequential treatment in disseminated well- and intermediate-differentiated pancreatic neuroendocrine tumors: Common sense or low rationale? *World J Clin Oncol*. 2016; 7(2): 149–154, doi: [10.5306/wjco.v7.i2.149](https://doi.org/10.5306/wjco.v7.i2.149), indexed in Pubmed: 27081637.
232. Panzuto F, Rinzivillo M, Fazio N, et al. Real-world study of everolimus in advanced progressive neuroendocrine tumors. *Oncologist*. 2014; 19(9): 966–974, doi: [10.1634/theoncologist.2014-0037](https://doi.org/10.1634/theoncologist.2014-0037), indexed in Pubmed: 25117065.
233. Kamp K, Gumz B, Feelders RA, et al. Safety and efficacy of everolimus in gastrointestinal and pancreatic neuroendocrine tumors after (177) Lu-octreotide. *Endocr Relat Cancer*. 2013; 20(6): 825–831, doi: [10.1530/ERC-13-0254](https://doi.org/10.1530/ERC-13-0254), indexed in Pubmed: 24036133.
234. Trotti A, Colevas AD, Setzer A, et al. CTCAE v3.0: development of a comprehensive grading system for the adverse effects of cancer treatment. *Semin Radiat Oncol*. 2003; 13(3): 176–181, doi: [10.1016/S1053-4296\(03\)00031-6](https://doi.org/10.1016/S1053-4296(03)00031-6), indexed in Pubmed: 12903007.
235. Bernard V, Lombard-Bohas C, Taquet MC, et al. French Group of Endocrine Tumors. Efficacy of everolimus in patients with metastatic insulinoma and refractory hypoglycemia. *Eur J Endocrinol*. 2013; 168(5): 665–674, doi: [10.1530/EJE-12-1101](https://doi.org/10.1530/EJE-12-1101), indexed in Pubmed: 23392213.
236. Kulke MH, Bergsland EK, Yao JC. Glycemic control in patients with insulinoma treated with everolimus. *N Engl J Med*. 2009; 360(2): 195–197, doi: [10.1056/NEJMc0806740](https://doi.org/10.1056/NEJMc0806740), indexed in Pubmed: 19129539.
237. Pavel ME, Hainsworth JD, Baudin E, et al. RADIANT-2 Study Group. Everolimus plus octreotide long-acting repeatable for the treatment of advanced neuroendocrine tumours associated with carcinoid syndrome (RADIANT-2): a randomised, placebo-controlled, phase 3 study. *Lancet*. 2011; 378(9808): 2005–2012, doi: [10.1016/S0140-6736\(11\)61742-X](https://doi.org/10.1016/S0140-6736(11)61742-X), indexed in Pubmed: 22119496.
238. Chen J, Wang C, Han J, et al. Therapeutic effect of sunitinib malate and its influence on blood glucose concentrations in a patient with metastatic insulinoma. *Expert Rev Anticancer Ther*. 2013; 13(6): 737–743, doi: [10.1586/era.13.45](https://doi.org/10.1586/era.13.45), indexed in Pubmed: 23573816.
239. Bajetta E, Catena L, Fazio N, et al. Everolimus in combination with octreotide long-acting repeatable in a first-line setting for patients with neuroendocrine tumors: an ITMO group study. *Cancer*. 2014; 120(16): 2457–2463, doi: [10.1002/cncr.28726](https://doi.org/10.1002/cncr.28726), indexed in Pubmed: 24752410.
240. Hobday TJ, Yin J, Pettinger A, et al. Multicenter prospective phase II trial of bevacizumab (bev) for progressive pancreatic neuroendocrine tumor (PNET) *J Clin Oncol*. 2015; 33 suppl:abstr 409.
241. Castellano D, Capdevila J, Sastre J, et al. Sorafenib and bevacizumab combination targeted therapy in advanced neuroendocrine tumour: a phase II study of Spanish Neuroendocrine Tumour Group (GETNE0801). *Eur J Cancer*. 2013; 49(18): 3780–3787, doi: [10.1016/j.ejca.2013.06.042](https://doi.org/10.1016/j.ejca.2013.06.042), indexed in Pubmed: 24012098.
242. Strosberg J, Goldman J, Costa F, et al. The Role of Chemotherapy in Well-Differentiated Gastroenteropancreatic Neuroendocrine Tumors. *Front Horm Res*. 2015; 44: 239–247, doi: [10.1159/000403785](https://doi.org/10.1159/000403785), indexed in Pubmed: 26303716.
243. Grande E, Capdevila J, Castellano D, et al. Pazopanib in pretreated advanced neuroendocrine tumors: a phase II, open-label trial of the Spanish Task Force Group for Neuroendocrine Tumors (GETNE). *Ann Oncol*. 2015; 26(9): 1987–1993, doi: [10.1093/annonc/mdv252](https://doi.org/10.1093/annonc/mdv252), indexed in Pubmed: 26063633.
244. Paganelli G, Bodei L, Handkiewicz Junak D, et al. 90Y-DOTA-D-Phe1-Tyr3-octreotide in therapy of neuroendocrine malignancies. *Biopolymers*. 2002; 66(6): 393–398, doi: [10.1002/bip.10349](https://doi.org/10.1002/bip.10349), indexed in Pubmed: 12658726.
245. Cwikla JB, Sankowski A, Seklecka N, et al. Efficacy of radionuclide treatment DOTATATE Y-90 in patients with progressive metastatic gastroenteropancreatic neuroendocrine carcinomas (GEP-NEIs): a phase II study. *Ann Oncol*. 2010; 21(4): 787–794, doi: [10.1093/annonc/mdp372](https://doi.org/10.1093/annonc/mdp372), indexed in Pubmed: 19833821.
246. Sowa-Staszczak A, Pach D, Kunikowska J, et al. Efficacy and safety of 90Y-DOTATATE therapy in neuroendocrine tumours. *Endokrynol Pol*. 2011; 62(5): 392–400, indexed in Pubmed: 22069099.
247. Bodei L, Cremonesi M, Grana CM, et al. Peptide receptor radionuclide therapy with ¹⁷⁷Lu-DOTATATE: the IEO phase I-II study. *Eur J Nucl Med Mol Imaging*. 2011; 38(12): 2125–2135, doi: [10.1007/s00259-011-1902-1](https://doi.org/10.1007/s00259-011-1902-1), indexed in Pubmed: 21892623.

248. Imhof A, Brunner P, Marinck N, et al. Response, survival, and long-term toxicity after therapy with the radiolabeled somatostatin analogue [90Y-DOTA]-TOC in metastasized neuroendocrine cancers. *J Clin Oncol.* 2011; 29(17): 2416–2423, doi: [10.1200/JCO.2010.33.7873](https://doi.org/10.1200/JCO.2010.33.7873), indexed in Pubmed: 21555692.
249. Pach D, Sowa-Staszczak A, Kunikowska J, et al. Repeated cycles of peptide receptor radionuclide therapy (PRRT)—results and side-effects of the radioisotope 90Y-DOTA TATE, 177Lu-DOTA TATE or 90Y/177Lu-DOTA TATE therapy in patients with disseminated NET. *Radiother Oncol.* 2012; 102(1): 45–50, doi: [10.1016/j.radonc.2011.08.006](https://doi.org/10.1016/j.radonc.2011.08.006), indexed in Pubmed: 21885142.
250. Kunikowska J, Króllicki L, Sowa-Staszczak A, et al. Polish experience in Peptide receptor radionuclide therapy. *Recent Results Cancer Res.* 2013; 194: 467–478, doi: [10.1007/978-3-642-27994-2_26](https://doi.org/10.1007/978-3-642-27994-2_26), indexed in Pubmed: 22918776.
251. Vinjamuri S, Gilbert TM, Banks M, et al. Peptide receptor radionuclide therapy with (90Y)-DOTATATE/(90Y)-DOTATOC in patients with progressive metastatic neuroendocrine tumours: assessment of response, survival and toxicity. *Br J Cancer.* 2013; 108(7): 1440–1448, doi: [10.1038/bjc.2013.103](https://doi.org/10.1038/bjc.2013.103), indexed in Pubmed: 23492685.
252. Bertani E, Fazio N, Radice D, et al. Resection of the Primary Tumor Followed by Peptide Receptor Radionuclide Therapy as Upfront Strategy for the Treatment of G1-G2 Pancreatic Neuroendocrine Tumors with Unresectable Liver Metastases. *Ann Surg Oncol.* 2016; 23(Suppl 5): 981–989, doi: [10.1245/s10434-016-5550-3](https://doi.org/10.1245/s10434-016-5550-3), indexed in Pubmed: 27613553.
253. Strosberg J, El-Haddad G, Wolin E, et al. NETTER-1 Trial Investigators. Phase 3 Trial of (177)Lu-Dotatate for Midgut Neuroendocrine Tumors. *N Engl J Med.* 2017; 376(2): 125–135, doi: [10.1056/NEJMoa1607427](https://doi.org/10.1056/NEJMoa1607427), indexed in Pubmed: 28076709.
254. Sowa-Staszczak A, Pach D, Stefańska A, et al. Case report of a patient with initially inoperable well-differentiated midgut neuroendocrine tumor (WDNT)—PRRT and long-acting somatostatin analogs as the neoadjuvant therapy. *Nucl Med Rev Cent East Eur.* 2012; 15(2): 137–139, indexed in Pubmed: 22936508.
255. Kratochwil C, Stefanova M, Mavriopoulou E, et al. SUV of [68Ga] DOTATOC-PET/CT Predicts Response Probability of PRRT in Neuroendocrine Tumors. *Mol Imaging Biol.* 2015; 17(3): 313–318, doi: [10.1007/s11307-014-0795-3](https://doi.org/10.1007/s11307-014-0795-3), indexed in Pubmed: 25319765.
256. Bergsma H, Konijnenberg MW, Kam BLR, et al. Subacute haematotoxicity after PRRT with (177)Lu-DOTA-octreotate: prognostic factors, incidence and course. *Eur J Nucl Med Mol Imaging.* 2016; 43(3): 453–463, doi: [10.1007/s00259-015-3193-4](https://doi.org/10.1007/s00259-015-3193-4), indexed in Pubmed: 26419852.
257. Severi S, Nanni O, Bodei L, et al. Role of 18FDG PET/CT in patients treated with 177Lu-DOTATATE for advanced differentiated neuroendocrine tumours. *Eur J Nucl Med Mol Imaging.* 2013; 40(6): 881–888, doi: [10.1007/s00259-013-2369-z](https://doi.org/10.1007/s00259-013-2369-z), indexed in Pubmed: 23443937.
258. Binderup T, Knigge U, Loft A, et al. 18F-fluorodeoxyglucose positron emission tomography predicts survival of patients with neuroendocrine tumors. *Clin Cancer Res.* 2010; 16(3): 978–985, doi: [10.1158/1078-0432.CCR-09-1759](https://doi.org/10.1158/1078-0432.CCR-09-1759), indexed in Pubmed: 20103666.
259. Sampathirao N, Basu S. MIB-1 Index-Stratified Assessment of Dual-Tracer PET/CT with (68)Ga-DOTATATE and (18)F-FDG and Multimodality Anatomic Imaging in Metastatic Neuroendocrine Tumors of Unknown Primary in a PRRT Workup Setting. *J Nucl Med Technol.* 2017; 45(1): 34–41, doi: [10.2967/jnmt.116.185777](https://doi.org/10.2967/jnmt.116.185777), indexed in Pubmed: 28154019.
260. Bodei L, Mueller-Brand J, Baum RP, et al. The joint IAEA, EANM, and SNMMI practical guidance on peptide receptor radionuclide therapy (PRRT) in neuroendocrine tumours. *Eur J Nucl Med Mol Imaging.* 2013; 40(5): 800–816, doi: [10.1007/s00259-012-2330-6](https://doi.org/10.1007/s00259-012-2330-6), indexed in Pubmed: 23389427.
261. Handkiewicz-Junak D, Sygula A, Hasse-Lazar K, et al. Consolidation treatment with somatostatin analogues after radiolabeled peptide therapy. *Eur J Nucl Med Mol Imaging.* 2014; 41: S212–S212.
262. Sowa-Staszczak A, Stefanska A, Chrapczynski P, et al. Does combination of „cold” and „hot” somatostatin analogs prolong survival of patients with neuroendocrine neoplasms?. *Endocr J.* 2016 Nov 17. [Epub ahead of print]
263. https://evs.nci.nih.gov/ftp1/CTCAE/CTCAE_4.03_2010-06-14_QuickReference_5x7.pdf.
264. Severi S, Sansovini M, Ianniello A, et al. Feasibility and utility of retreatment with (177)Lu-DOTATATE in GEP-NENs relapsed after treatment with (90)Y-DOTATOC. *Eur J Nucl Med Mol Imaging.* 2015; 42(13): 1955–1963, doi: [10.1007/s00259-015-3105-7](https://doi.org/10.1007/s00259-015-3105-7), indexed in Pubmed: 26112388.
265. Buscombe JR, Cwikla JB, Caplin ME, et al. Long-term efficacy of low activity meta-[131I]iodobenzylguanidine therapy in patients with disseminated neuroendocrine tumours depends on initial response. *Nucl Med Commun.* 2005; 26(11): 969–976, indexed in Pubmed: 16208174.
266. Bomanji JB, Papathanasiou ND. ¹¹¹In-DTPA-octreotide (Octreoscan), ¹³¹I-MIBG and other agents for radionuclide therapy of NETs. *Eur J Nucl Med Mol Imaging.* 2012; 39 Suppl 1: S113–S125, doi: [10.1007/s00259-011-2013-8](https://doi.org/10.1007/s00259-011-2013-8), indexed in Pubmed: 22388626.
267. Vinjamuri S, Gilbert TM, Banks M, et al. Peptide receptor radionuclide therapy with (90Y)-DOTATATE/(90Y)-DOTATOC in patients with progressive metastatic neuroendocrine tumours: assessment of response, survival and toxicity. *Br J Cancer.* 2013; 108(7): 1440–1448, doi: [10.1038/bjc.2013.103](https://doi.org/10.1038/bjc.2013.103), indexed in Pubmed: 23492685.
268. Yalchin M, Oliveira A, Theocharidou E, et al. The Impact of Radiological Response to Peptide Receptor Radionuclide Therapy on Overall Survival in Patients With Metastatic Midgut Neuroendocrine Tumors. *Clin Nucl Med.* 2017; 42(3): e135–e141, doi: [10.1097/RLU.0000000000001457](https://doi.org/10.1097/RLU.0000000000001457), indexed in Pubmed: 27922860.
269. Garcia-Carbonero R, Garcia-Figueiras R, Carmona-Bayonas A, et al. Spanish Cooperative Group of Neuroendocrine Tumors (GETNE). Imaging approaches to assess the therapeutic response of gastroenteropancreatic neuroendocrine tumors (GEP-NETs): current perspectives and future trends of an exciting field in development. *Cancer Metastasis Rev.* 2015; 34(4): 823–842, doi: [10.1007/s10555-015-9598-5](https://doi.org/10.1007/s10555-015-9598-5), indexed in Pubmed: 26433592.
270. Sansovini M, Severi S, Ianniello A, et al. Long-term follow-up and role of FDG PET in advanced pancreatic neuroendocrine patients treated with (177)Lu-D DOTATATE. *Eur J Nucl Med Mol Imaging.* 2017; 44(3): 490–499, doi: [10.1007/s00259-016-3533-z](https://doi.org/10.1007/s00259-016-3533-z), indexed in Pubmed: 27704193.
271. Contessa JN, Griffith KA, Wolff E, et al. Radiotherapy for pancreatic neuroendocrine tumors. *Int J Radiat Oncol Biol Phys.* 2009; 75(4): 1196–1200, doi: [10.1016/j.ijrobp.2008.12.044](https://doi.org/10.1016/j.ijrobp.2008.12.044), indexed in Pubmed: 19327905.
272. Arvold ND, Willett CG, Fernandez-del Castillo C, et al. Pancreatic neuroendocrine tumors with involved surgical margins: prognostic factors and the role of adjuvant radiotherapy. *Int J Radiat Oncol Biol Phys.* 2012; 83(3): e337–e343, doi: [10.1016/j.ijrobp.2011.12.068](https://doi.org/10.1016/j.ijrobp.2011.12.068), indexed in Pubmed: 22414286.
273. Zagar TM, White RR, Willett CG, et al. Resected pancreatic neuroendocrine tumors: patterns of failure and disease-related outcomes with or without radiotherapy. *Int J Radiat Oncol Biol Phys.* 2012; 83(4): 1126–1131, doi: [10.1016/j.ijrobp.2011.09.041](https://doi.org/10.1016/j.ijrobp.2011.09.041), indexed in Pubmed: 22270161.
274. *OCEBM Levels of Evidence Working Group. “The Oxford 2011 Levels of Evidence”. Oxford Centre for Evidence-Based Medicine. <http://www.cebm.net/index.aspx?o=5653>.