

Supplementary File

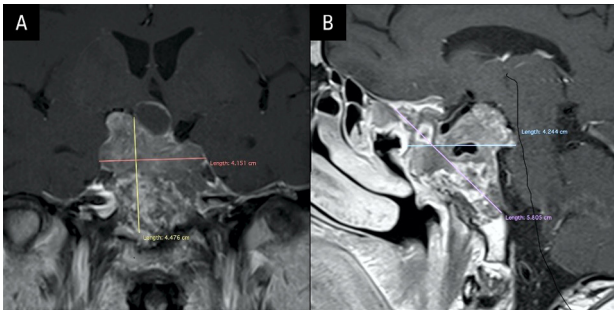


Figure S1. Magnetic resonance imaging (MRI) before temozolomide treatment — 24.06.2021. **A.** Cranio-caudal (CC) plane; **B.** Sagittal (Sag) plane

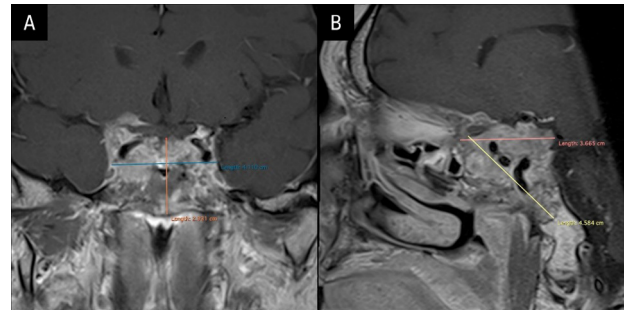


Figure S2. Magnetic resonance imaging (MRI) after 3 cycles of temozolomide treatment — 08.10.2021. **A.** Cranio-caudal (CC) plane; **B.** Sagittal (Sag) plane