



Submitted: 24.01.2023
 Accepted: 26.01.2023
 Early publication date: 27.03.2023

Endokrynologia Polska
 DOI: 10.5603/EPa2023.0017
 ISSN 0423–104X, e-ISSN 2299–8306
 Volume/Tom 74; Number/Numer 2/2023

Liquid levothyroxine in the treatment of myxoedema coma

Grzegorz Sokołowski¹, Marcin Motyka², Aleksandra Gilis-Januszewska¹, Agnieszka Stefańska², Alicja Hubalewska-Dydejczyk¹

¹Chair and Department of Endocrinology, Jagiellonian University Medical College, Krakow, Poland

²Department of Endocrinology, Endocrine Oncology, and Nuclear Medicine, University Hospital, Krakow, Poland

Key words: hypothyroidism; myxoedema coma; liquid levothyroxine

Myxoedema coma, also known as myxoedema crisis, is the most serious complication of untreated or highly inadequately treated hypothyroidism. Its most common symptoms include decreased mental status, hypothermia, and multiple organ disorders, mostly involving the cardiovascular and nervous system. Myxoedema coma is a life-threatening condition; therefore, early treatment initiation is extremely important. The recommended treatment involves intravenous administration of thyroid hormones, but due to infrequent occurrence of myxoedema coma, intravenous levothyroxine (LT4) is not always immediately available in Polish conditions (direct import, short expiration date of the drug). Thus, liquid levothyroxine administered through a gastric tube seems to be a good alternative.

This article presents 3 cases of patients with myxoedema coma and severe hypothyroidism who received liquid LT4 (Tirosint-SOL) [1–4] and achieved an increase in serum free thyroxine and resolution of the life-threatening condition associated with thyroid hormone deficiency.

Case 1

A 67-year-old woman hospitalized in the intensive care unit (ICU) for over a month was connected to a ventilator for respiratory failure in the course of SARS-CoV-2 infection. She was unconscious, had respiratory and circulatory failure, massive peripheral oedema, and progressive multiple organ dysfunction. The patient was transferred to the palliative care unit for patients with no prognosis for recovery. The patient had a history of schizophrenia, hypertension, and hypothyroidism diagnosed many years earlier.

Despite administering LT4 tablets at a dose of 100 µg/d through the gastric tube, the thyroid-stimulating hormone (TSH) level was 57.2 µU/mL (reference range: 0.27–4.2

µU/mL) and the free thyroxine (FT4) level was 5.41 pmol/L (reference range: 12–22 pmol/L). Low bioavailability of LT4 tablets administered by gastric tube in a critically ill patient with massive oedema and malabsorption was considered the cause of poor hormonal compensation.

The medication was switched to liquid LT4 at a dose of 150 µg/d administered through the gastric tube. After 2 weeks of treatment, TSH was 22.5 µU/mL, free triiodothyronine (FT3) was 2.85 pmol/L (reference range: 3.1–6.8 pmol/L), and FT4 was 9.84 pmol/L. The patient's condition was still serious, but it improved — she was conscious, able to answer simple questions, and was breathing partially on her own supported by passive oxygen therapy.

After another 2 weeks, further improvement in laboratory results (TSH — 18.6 µU/mL; FT3 — 3.63 pmol/L; FT4 — 14.5 pmol/L) was observed.

After another week, the patient was disconnected from the ventilator, and treatment with liquid LT4 at a dose of 125 µg/d was continued. In a follow-up assessment at 3 weeks, the TSH value was 1.57 uIU/mL. The patient was transferred from the ICU to rehabilitation ward.

Case 2

A 69-year-old man was admitted urgently to the endocrinology department from the emergency unit due to myxoedema coma. The patient had been less communicative for 2 days and lost consciousness on the day of admission.

At the beginning of hospitalization, the patient's condition was serious; he had respiratory failure, bradypnea, and shallow breathing with periodic apnoea up to 30 s. He was conscious but unable to communicate logically; he was very sluggish, and his speech was slurred and unintelligible. Physical examination showed systemic oedema and pale, dry, cold skin. His blood pressure was 138/57 mm Hg with a subsequent drop to 70/40 mm Hg,



Alicja Hubalewska-Dydejczyk, Chair and Department of Endocrinology, Jagiellonian University Medical College Jakubowskiego 2 St., 30–688 Krakow, Poland, tel: +48 12 400 23 00, fax: +48 12 400 23 37; e-mail: alahub@cm-uj.krakow.pl

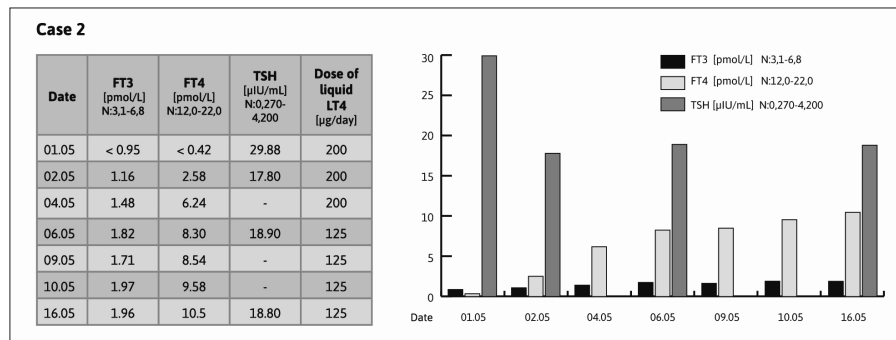


Figure 1. Changes in thyroid-stimulating hormone (TSH), free triiodothyronine (FT3), and free thyroxine (FT4) concentrations during the treatment with liquid levothyroxine in patient 2

pulse about 50/min, temperature 33.2°C, and blood oxygen saturation (SpO₂) — 91–95% on oxygen therapy of 2 L/min through a nasal cannula. Laboratory results were as follows: TSH — 29.88 uIU/mL, FT4 < 0.42 ng/dL, FT3 < 0.95 pg/mL, cortisol level within the reference range (although inadequately low for the severity of the patient's condition), and high anti-thyroid peroxidase antibodies (aTPO). Moreover, hyponatraemia and hyperlipidaemia were detected. Chest X-ray revealed pulmonary congestion. Electrocardiography (ECG) showed sinus bradycardia (about 50 beats/min), AV 1 block, intermediate electrical axis, and intraventricular conduction disturbances without fresh ST-T ischaemic changes.

Due to unavailability of intravenous LT4, liquid LT4 was administered at a dose of 200 μg with hydrocortisone cover. Norepinephrine infusion was used to stabilize circulation.

After 5 days, the following results were obtained: TSH — 18.9 uIU/mL, FT3 — 1.82 pmol/L, FT4 — 8.3 pmol/L, and sodium — 144 mmol/L [reference range: 136–145mmol/L]. After another 10 days of the treatment, FT3 was 1.96 pmol/L, while FT4 was 10.5 pmol/L (Fig. 1).

The patient's general condition also improved. Treatment with liquid LT4 at a dose of 125 μg/d was continued.

Case 3

A 75-year-old woman with Graves' orbitopathy was admitted to the ICU after resuscitation due to a sudden cardiac arrest following orbital decompression surgery. The patient's condition was serious; she was unconscious, intubated, and mechanically ventilated. The patient had a history of hypothyroidism after ¹³¹I therapy, atrial fibrillation, hypertension, type 2 diabetes, chronic coronary syndrome, chronic heart failure, chronic obstructive pulmonary disease, systemic atherosclerosis, mitral and tricuspid valve regurgitation.

Multidisciplinary integrated treatment was initiated (analgo-sedation, mechanical ventilation, cardiovascular stabilization). The patient was fed enterally, and this

route was used to administer LT4 at an initial dose of 175 μg/d. Due to increasing clinical and laboratory features of hypothyroidism, the dose was increased, and then, in the absence of a satisfactory outcome, the therapy was switched from tablets to liquid LT4 at a dose of 200 μg/d. After the switch, thyroid hormones increased, TSH decreased, and finally, metabolic normalization was achieved. Despite the treatment, the patient could not be disconnected from the ventilator and was transferred to a long-term care facility.

In the presented cases of patients with myxoedema coma, rapid improvement of thyroid function was achieved after implementation of enteral liquid LT4. Considering not only the effectiveness [2–4] but also the number of ready-to-use doses and convenience of administration [5] in the aforementioned life-threatening situations, we suggest that liquid LT4 should be available in hospital pharmacies.

Acknowledgements

The authors would like to thank Proper Medical Writing and IBSA Poland Sp. z o. o. for their support in the preparation of this manuscript.

Funding

No funding was available.

References

1. Yue CS, Scarsi C, Ducharme MP. Pharmacokinetics and potential advantages of a new oral solution of levothyroxine vs. other available dosage forms. *Arzneimittelforschung*. 2012; 62(12): 631–636, doi: [10.1055/s-0032-1329951](https://doi.org/10.1055/s-0032-1329951), indexed in Pubmed: [23154888](https://pubmed.ncbi.nlm.nih.gov/23154888/).
2. Ruchała M. Increased efficacy of hypothyroidism control with liquid levothyroxine. *Endokrynol Pol*. 2021; 72(3): 271–275, doi: [10.5603/ep.a2021.0049](https://doi.org/10.5603/ep.a2021.0049), indexed in Pubmed: [34292578](https://pubmed.ncbi.nlm.nih.gov/34292578/).
3. Bornikowska K, Gietka-Czernel M, Raczkiewicz D, et al. Improvements in Quality of Life and Thyroid Parameters in Hypothyroid Patients on Ethanol-Free Formula of Liquid Levothyroxine Therapy in Comparison to Tablet LT4 Form: An Observational Study. *J Clin Med*. 2021; 10(22), doi: [10.3390/jcm10225233](https://doi.org/10.3390/jcm10225233), indexed in Pubmed: [34830515](https://pubmed.ncbi.nlm.nih.gov/34830515/).
4. Ruchała M, Bossowski A, Brzozka MM, et al. Liquid levothyroxine improves thyroid control in patients with different hypothyroidism aetiology and variable adherence — case series and review. *Endokrynol Pol*. 2022; 73(5): 893–902, doi: [10.5603/EPa2022.0078](https://doi.org/10.5603/EPa2022.0078), indexed in Pubmed: [36621916](https://pubmed.ncbi.nlm.nih.gov/36621916/).
5. Pirola I, Daffini L, Gandossi E, et al. Comparison between liquid and tablet levothyroxine formulations in patients treated through enteral feeding tube. *J Endocrinol Invest*. 2014; 37(6): 583–587, doi: [10.1007/s40618-014-0082-9](https://doi.org/10.1007/s40618-014-0082-9), indexed in Pubmed: [24789541](https://pubmed.ncbi.nlm.nih.gov/24789541/).