



Submitted: 19.09.2021
Accepted: 04.01.2022
Early publication date: 20.05.2022

Endokrynologia Polska
DOI: 10.5603/EPa2022.0039
ISSN 0423-104X, e-ISSN 2299-8306
Volume/Tom 73; Number/Numera 4/2022

Giant pseudocyst of the retroperitoneal space mimicking a lesion arising from the left adrenal gland

Marek Olakowski, Jakub Ciosek

Department of Digestive Tract Surgery, Medical University of Silesia, Katowice, Poland

Key words: giant pseudocysts; retroperitoneal pseudocyst; adrenal cysts

A retroperitoneal pseudocyst (RPC) is an uncommon lesion, and often the origin cannot be precisely defined. Adrenal cysts should always be included in the differential diagnosis of cystic abdominal lesions [1].

We report a case of a pseudocyst of the retroperitoneal space, which was initially diagnosed as a left adrenal cyst.

A woman, aged 30 years, was admitted to the hospital because of a giant retroperitoneal space cyst diagnosed by computed tomography (CT). She suffered from mild epigastric pain, periodic vomiting and a feeling of a mass in the upper left quadrant of the abdomen. The first symptoms appeared about 6 months before admission. She had a subtotal thyroidectomy for papillary thyroid carcinoma 2 years before. On physical examination, a fixed, elastic tumour of approximately 20 cm in diameter was palpable in the left upper quadrant of the abdominal cavity. Blood pressure and heart rate parameters were normal (RR 120/80 mmHg, HR 72/min). Laboratory analyses (including hormonal tests — methoxycatecholamines in daily urine collection, dexamethasone test, thyroid-stimulating factor (TSH), free triiodothyronine (fT3), and free thyroxine (fT4) did not show any abnormalities. CT revealed a 15 × 19 × 20 cm cyst in the left upper abdominal quadrant, adjacent to the body and tail of the pancreas, spleen, posterior gastric wall, and anterior surface of the left kidney (Fig. 1). The splenic vessels were tense at the upper part of the lesion. The small bowel loops were displaced downward and to the right by the cyst. The wall of the cyst was smooth and 15 mm thick. The content of the cyst was homogeneous without the presence of septa or wall nodules and had a density of 14 Hounsfield units. A CT scan did not show the left adrenal gland, so it was suspected to be the origin of the cyst.

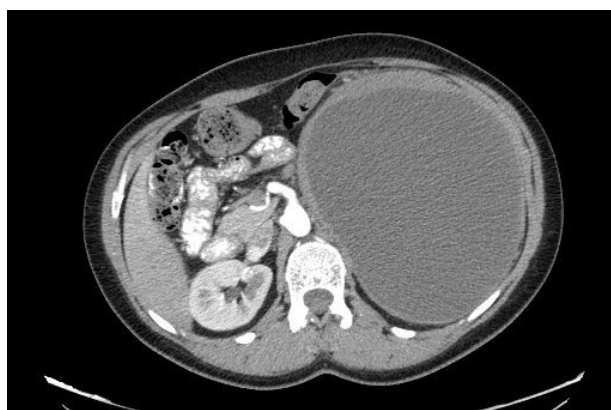

Figure 1. Retroperitoneal pseudocyst on computed tomography (CT) scan

The course of the left middle adrenal artery, the distal end of which penetrated into the tissues of the lower part of the cyst, confirmed an adrenal-related aetiology. At the same time, it was not excluded that the cyst could also be related to the pancreas. The patient was qualified for an exploratory laparotomy, and the cyst was excised together with its capsule and the left adrenal gland (Fig. 2). The splenic flexure of the colon was also resected, because the vessels present in the distal part of the mesentery of the transverse colon adhered closely to the cyst capsule and could not be separated. The postoperative course was uncomplicated. The patient left the hospital on postoperative day 7. The histopathological examination showed a simple cyst without epithelial lining, measuring 19 × 16.5 × 16.5 cm, weighting with fluid approximately 3000 g and 730 g after emptying. The fluid was dense but did not contain cellular elements. The cyst wall was 0.2–1.2 cm thick, composed of connective tissue with lymphocytic inflammatory in-



Dr hab. med. Marek Olakowski, Department of Digestive Tract Surgery, Medical University of Silesia, Katowice, Medyków 14, 40-752 Katowice, Poland; e-mail: olakom@mp.pl

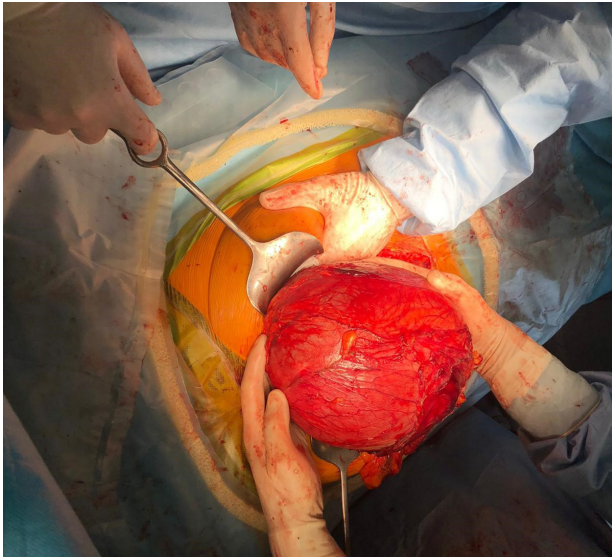


Figure 2. Intraoperative image of a retroperitoneal pseudocyst

filtrates of moderate to high density. A normal, adrenal gland measuring $6.5 \times 3.5 \times 0.2$ cm was found within the connective tissue of the cyst. Seven lymph nodes with chronic inflammation were found in the fatty tissue around the cyst. The microscopic image of the resected colon was normal. At follow-up 6 and 12 months after surgery, the patient reported no complaints.

Identification of cystic lesions within the retroperitoneal space is a rare event that poses the challenge of a difficult diagnosis and management. Retroperitoneal cysts are a group of lesions that range from common benign to rare aggressive malignant neoplasms. In a majority of cases image-guided procedures allow for a pathological diagnosis, offering the chance of an appropriate treatment. However, the overall clinical assessment of retroperitoneal cysts is highly demanding [2].

Adrenal pseudocysts are cystic lesions arising within the adrenal gland surrounded by a fibrous tissue wall without a recognizable lining layer. Even in mild-looking cysts, adrenal cortical cancer cells may be present.

Approximately 7% of pseudocysts are associated with malignancy [3].

Adrenal cysts may occur simultaneously with other adrenal tumours associated with hormonal hypersecretion. In all cases of adrenal cysts, even asymptomatic ones, hormonal evaluation is necessary to rule out subclinical disease [4].

The hormonal tests performed in our patient showed no abnormalities.

Management of retroperitoneal cystic lesions can be conservative or surgical. Biopsy and percutaneous aspiration are an alternative conservative treatment option if the cyst is not hormonally active and suspected of being neoplastic. It allows a reduction of the compression of the surrounding structures and the analysis of the nature of the cystic liquid. The treatment of choice for retroperitoneal cysts is total excision, which enables histopathological diagnosis and reduces the risk of future complications. The choice of surgical technique (laparoscopy versus laparotomy) depends on the preferences and surgical experience [2].

We decided to perform a classical laparotomy due to the size of the cyst and the compression of the surrounding structures. Currently, laparoscopic surgery is recommended in the case of RPC [5].

References

1. Sioka E, Symeonidis D, Chatzinikolaou I, et al. A giant adrenal cyst difficult to diagnose except by surgery. *Int J Surg Case Rep.* 2011; 2(7): 232–234, doi: [10.1016/j.ijscr.2011.05.007](https://doi.org/10.1016/j.ijscr.2011.05.007), indexed in Pubmed: [22096737](https://pubmed.ncbi.nlm.nih.gov/22096737/).
2. Morotti A, Busso M, Barozzino MC, et al. Detection and management of retroperitoneal cystic lesions: A case report and review of the literature. *Oncol Lett.* 2017; 14(2): 1602–1608, doi: [10.3892/ol.2017.6323](https://doi.org/10.3892/ol.2017.6323), indexed in Pubmed: [28789385](https://pubmed.ncbi.nlm.nih.gov/28789385/).
3. Wilkinson M, Fanning DM, Moloney J, et al. Giant adrenal pseudocyst harbouring adrenocortical cancer. *BMJ Case Rep.* 2011; 2011, doi: [10.1136/bcr.05.2011.4169](https://doi.org/10.1136/bcr.05.2011.4169), indexed in Pubmed: [22679267](https://pubmed.ncbi.nlm.nih.gov/22679267/).
4. Cavallaro G, Crocetti D, Paliotta A, et al. Cystic adrenal lesions: clinical and surgical management. The experience of a referral centre. *Int J Surg.* 2015; 13: 23–26, doi: [10.1016/j.ijvsu.2014.11.023](https://doi.org/10.1016/j.ijvsu.2014.11.023), indexed in Pubmed: [25447606](https://pubmed.ncbi.nlm.nih.gov/25447606/).
5. Latif E, Musthafa S, Ahmed A, et al. Idiopathic Retroperitoneal Non-pancreatic Pseudocyst in an Adult Male: Radiological Images and Surgical Video of Laparoscopic Excision. *Cureus.* 2020; 12(3): e7243, doi: [10.7759/cureus.7243](https://doi.org/10.7759/cureus.7243), indexed in Pubmed: [32284918](https://pubmed.ncbi.nlm.nih.gov/32284918/).