



Submitted: 07.07.2021  
Accepted: 10.07.2021  
Early publication date: 06.10.2021

Endokrynologia Polska  
DOI: 10.5603/EPa2021.0086  
Volume/Tom 72; Number/Numer 6/2021  
ISSN 0423-104X, e-ISSN 2299-8306

## Childhood thyroid carcinoma — single-centre experience

Hanna Borysewicz-Sańczyk<sup>1</sup>, Marta Paślawska<sup>2</sup>, Magdalena Zdrodowska<sup>2</sup>, Beata Sawicka<sup>1</sup>, Janusz Pomaski<sup>1</sup>, Daria Handkiewicz-Junak<sup>3</sup>, Jolanta Krajewska<sup>3</sup>, Agnieszka Czarniecka<sup>3</sup>, Barbara Jarząb<sup>3</sup>, Janusz Dziecioł<sup>4</sup>, Artur Bossowski<sup>1</sup>

<sup>1</sup>Department of Paediatrics, Endocrinology, and Diabetology with a Cardiology Division, Medical University of Białystok, Poland

<sup>2</sup>Student Research Group by the Department of Paediatrics, Endocrinology, and Diabetology with a Cardiology Division, Medical University of Białystok, Poland

<sup>3</sup>Maria Skłodowska-Curie Memorial Cancer Centre and Institute of Oncology in Gliwice, Poland

<sup>4</sup>Department of Human Anatomy, Medical University of Białystok, Poland

**Keywords:** papillary thyroid carcinoma (PTC); children; thyroid ultrasonography; elastography; surgery; radioactive iodine (RAI)

Thyroid cancer (TC) in Polish children constitutes 2.3% of all diagnosed cases [1, 2]. The predominant histological type is papillary thyroid carcinoma (PTC).

We present three patients diagnosed with PTC in the Department of Paediatrics, Endocrinology, and Diabetology with a Cardiology Division, Medical University of Białystok, Poland treated with the cooperation of the Department of Nuclear Medicine and Endocrine Oncology at M. Skłodowska-Curie National Research Institute in Gliwice, Poland.

A 14-year-old girl with goitre was diagnosed with thyroiditis. Ultrasonography (US) revealed a heterogeneous thyroid gland with hypoechogenic areas, the largest in the right lobe (15 × 11 × 21 mm) — TR5 according to the TI-RADS scale [3] and U5 according to Thyroid Nodules-Ultrasound (BTA) [4], ROI1/ROI2 = 6.3 in elastography. Fine-needle aspiration biopsy (FNAB) revealed papillary carcinoma cells. Total thyroidectomy with lymphadenectomy was performed. Histopathological examination showed multifocal PTC in both lobes and metastatic cells in lymph nodes (pT2mN1aM0). She underwent complementary radioactive iodine (RAI) therapy. Postoperative imaging revealed a pathological lymph node in the upper neck, confirmed as lymph node metastasis in FNAB. The patient underwent modified right, lateral, cervical lymphadenectomy and RAI treatment in Gliwice.

A 17-year-old girl was referred due to a nodule on her neck. US demonstrated hypoechogenic area (20 × 14 × 17 mm) with calcifications in the right lobe (TR5, U5). FNAB confirmed PTC. Total bilateral stru-

mectomy was performed. Histopathological examination revealed PTC in the right lobe with blood vessel invasion (pT1mNxM0), hyperplastic cells were also found in the left lobe. After confirmation of lymph node metastases, the patient was surgically treated in Gliwice and underwent RAI therapy. In post-therapeutic imaging, RAI uptake in the thyroid bed was found. FNAB confirmed local recurrence. The patient was surgically treated with the revision of the bed. Once again RAI treatment was applied.

A 13-year-old boy referred due to a partially empty sella syndrome showed goitre in physical examination. Thyroid as well as pituitary gland hormones remained normal. US showed a large hypoechogenic area (15 × 17 × 19 mm) with micro and macro calcifications (TR5, U5) (Fig. 1), elastography ROI1/ROI2=10 (Fig. 2). The right side lymph nodes were enlarged. FNAB revealed the PTC (Bethesda VI). The patient underwent total thyroidectomy with central neck dissection in Gliwice. A histopathology examination confirmed papillary thyroid cancer with lymph node metastases (pT3aN1bMx). RAI was given as a postoperative treatment.

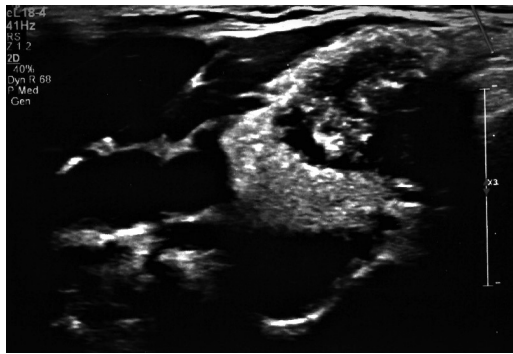
At the final follow-up, all patients were disease-free and fulfilled the criteria of the ATA indeterminate or excellent response [5].

The diagnostic process of TC usually starts when palpable nodules or goitre are discovered.

US has become the most useful imaging in the diagnosis of thyroid nodules. According to the Polish Guidelines, US should be performed in palpable thyroid nodules,



Dr med. Hanna Borysewicz-Sańczyk, Department of Paediatrics, Endocrinology, and Diabetology with a Cardiology Division, Medical University of Białystok, Poland; e-mail: hannaborysewicz@poczta.fm



**Figure 1.** Ultrasound of the thyroid: large hypoechoic area of  $15 \times 17 \times 19$  mm with numerous micro and macro calcifications; patient 3

thyroid asymmetry, and/or cervical lymphadenopathy. In children with AITD, after RAI, and at a high risk of thyroid neoplasia in the course of inherited syndromes thyroid US should be performed at least once a year [1, 2].

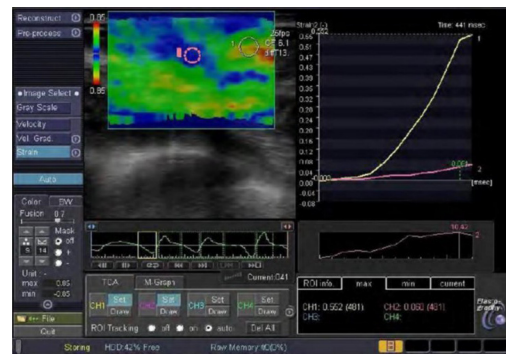
Elastography is non-invasive diagnostic tool revealing the stiffness of the tissue. Malignant thyroid nodules are less flexible (higher deformation index ROI1/ROI2) than benign ones. Elastography was performed in 2 presented cases and indicated tough nodules. According to the Polish recommendations, elastography may be helpful to evaluate the malignancy risk in children [1, 2].

Although several imaging methods are available, FNAB remains the gold standard in the diagnosis of thyroid, with high sensitivity and specificity. In all presented patients the FNAB result agreed with histopathological examination.

Total thyroidectomy became the gold treatment standard in paediatric patients with TC [1,6]. Compared to adults, TCs in children have higher incidence of lymph node (LNM) and distant metastases. International experts have highlighted the experience of surgeons and treatment centres as the most significant factors to reduce the risk of postoperative complications and achieve better treatment outcomes.

The indication for routine adjuvant postoperative RAI therapy in PTC children is a subject of debate. However, in young patients with lymph node and/or distant metastases, there is abundant evidence to show that at least disease-free survival is improved by RAI therapy [7]. Nevertheless, RAI in children may be associated with transient acute or late side effects [8]. The risk is statistically low; however, young patients have a long expected survival rate and may face a risk of developing second primary malignancy (SPM). Therefore, potential benefits and risks associated with RAI therapy should be carefully considered.

TC in children is a rare condition. Nevertheless, a detailed diagnostic processes should be carried out



**Figure 2.** Elastography: ROI 1/ROI 2 = 10; patient 3

among children with risk factors, in order to detect TC and implement treatment quickly and efficiently.

### Disclosure statement

The authors have no conflicts of interest to disclose.

### Statements of ethics

The research was conducted ethically in accordance with the World Medical Association Declaration of Helsinki. Data were collected retrospectively.

### Funding

No funding was available.

### Competing interests

None declared.

### References

- Niedziela M, Handkiewicz-Junak D, Malecka-Tendera E, et al. Diagnostics and treatment of differentiated thyroid carcinoma in children - Guidelines of Polish National Societies. *Endokrynol Pol.* 2016; 67(6): 628–642, doi: [10.5603/EP.2016.0072](https://doi.org/10.5603/EP.2016.0072), indexed in Pubmed: [28042655](https://pubmed.ncbi.nlm.nih.gov/28042655/).
- Jarząb B, Dedecjus M, Słowińska-Klencka D, et al. Guidelines of Polish National Societies Diagnostics and Treatment of Thyroid Carcinoma. 2018 Update. *Endokrynol Pol.* 2018; 69(1): 34–74, doi: [10.5603/EP.2018.0014](https://doi.org/10.5603/EP.2018.0014), indexed in Pubmed: [29442352](https://pubmed.ncbi.nlm.nih.gov/29442352/).
- Tessler FN, Middleton WD, Grant EG, et al. ACR Thyroid Imaging, Reporting and Data System (TI-RADS): White Paper of the ACR TI-RADS Committee. *J Am Coll Radiol.* 2017; 14(5): 587–595, doi: [10.1016/j.jacr.2017.01.046](https://doi.org/10.1016/j.jacr.2017.01.046), indexed in Pubmed: [28372962](https://pubmed.ncbi.nlm.nih.gov/28372962/).
- Perros P, Boelaert K, Colley S, et al. British Thyroid Association. Guidelines for the management of thyroid cancer. *Clin Endocrinol (Oxf).* 2014; 81 Suppl 1: 1–122, doi: [10.1111/cen.12515](https://doi.org/10.1111/cen.12515), indexed in Pubmed: [24989897](https://pubmed.ncbi.nlm.nih.gov/24989897/).
- Haugen BR, Alexander EK, Bible KC, et al. 2015 American Thyroid Association Management Guidelines for Adult Patients with Thyroid Nodules and Differentiated Thyroid Cancer: The American Thyroid Association Guidelines Task Force on Thyroid Nodules and Differentiated Thyroid Cancer. *Thyroid.* 2016; 26(1): 1–133, doi: [10.1089/thy.2015.0020](https://doi.org/10.1089/thy.2015.0020), indexed in Pubmed: [26462967](https://pubmed.ncbi.nlm.nih.gov/26462967/).
- Czarnecka A, Woźniak G, Kropińska A, et al. Surgical approach to differentiated thyroid cancers (DTC) in children [Specyfika leczenia chirurgicznego zróżnicowanych raków tarczycy (ZRT) u dzieci]. *Endokrynol Pol.* 2019; 70(4): 357–366, doi: [10.5603/ep.a2019.0033](https://doi.org/10.5603/ep.a2019.0033), indexed in Pubmed: [31489960](https://pubmed.ncbi.nlm.nih.gov/31489960/).
- Handkiewicz-Junak D, Wloch J, Roskosz J, et al. Total thyroidectomy and adjuvant radioiodine treatment independently decrease locoregional recurrence risk in childhood and adolescent differentiated thyroid cancer. *J Nucl Med.* 2007; 48(6): 879–888, doi: [10.2967/jnumed.106.035535](https://doi.org/10.2967/jnumed.106.035535), indexed in Pubmed: [17536106](https://pubmed.ncbi.nlm.nih.gov/17536106/).
- Rubino C, de Vathaire F, Dottorini ME, et al. Second primary malignancies in thyroid cancer patients. *Br J Cancer.* 2003; 89(9): 1638–1644, doi: [10.1038/sj.bjc.6601319](https://doi.org/10.1038/sj.bjc.6601319), indexed in Pubmed: [14583762](https://pubmed.ncbi.nlm.nih.gov/14583762/).