



# Unusual case of radioactive iodine-induced Graves' disease with orbitopathy following total thyroidectomy in a patient with papillary thyroid microcarcinoma

Kajetan Zgubieński<sup>1</sup>, Agnieszka Walczyk<sup>2,3</sup>, Aldona Kowalska<sup>2,3</sup>

<sup>1</sup>ESKULAP Student Scientific Organisation, Collegium Medicum, Jan Kochanowski University, Kielce, Poland

<sup>2</sup>Department of Endocrinology, Holycross Cancer Centre, Kielce, Poland

<sup>3</sup>Collegium Medicum, Jan Kochanowski University, Kielce, Poland

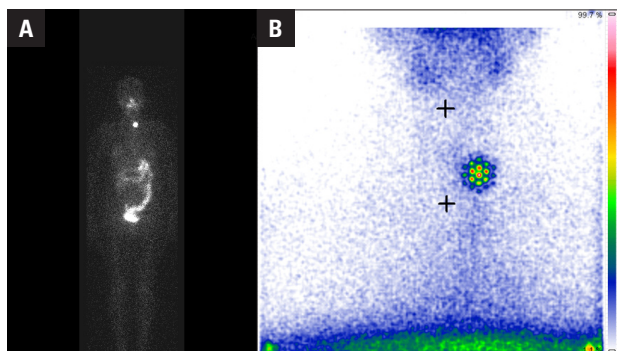
**Key words:** Graves' disease; Graves' orbitopathy; radioiodine; thyroidectomy; TSH-receptor antibodies

This study describes a patient who developed radioactive iodine (RAI)-induced Graves' disease (GD) with orbitopathy following total thyroidectomy for papillary thyroid microcarcinoma. The patient was a 49-year-old woman, who underwent total thyroidectomy for a nodular goitre, which was postoperatively diagnosed as papillary thyroid microcarcinoma. Following administration of low-activity RAI for performance of a diagnostic whole-body scan (WBS), she developed a clinically significant orbitopathy related to GD. Graves' disease has been reported in patients receiving therapeutic RAI, but it is considered rare and usually presents as post-RAI immunogenic hyperthyroidism [1]. To our knowledge, this is the first report of RAI-induced GD manifesting as orbitopathy in a patient with thyroid remnants after administration of low-activity RAI.

A 49-year-old female patient with a history of non-toxic nodular goitre was diagnosed with papillary thyroid microcarcinoma and underwent total thyroidectomy at a regional hospital. Pathologic examination showed a single focus of papillary thyroid cancer (PTC) 0.15 cm in diameter, with no metastatic lymph nodes or histological features of tumour aggressiveness. For postoperative examination, the patient was admitted to the Endocrinology Clinic of Holycross Cancer Centre (HCC). The patient showed no ocular symptoms, and ultrasound examination of the neck revealed no focal lesions in the thyroid bed. Immunoassays showed that this patient had normal concentrations of antibodies against thyroid-stimulating hormone (TSH) receptor (TRAb; 0.444 IU/L; reference range, 0–1.5 IU/L) and thyroglobulin (86.91 IU/mL; refer-

ence range, 0–115 IU/mL), and abnormally high concentrations of anti-thyroid peroxidase antibodies (TPOAb; 108.60 IU/mL; reference range, 0–34 IU/mL). A diagnostic WBS was performed after stimulation with recombinant human TSH and administration of 185 MBq of RAI. Uptake of marker was negligible on the left side of the thyroid bed, with an iodine uptake during the 24<sup>th</sup> hour of 0.3%, and with WBS showing no abnormal uptake outside the thyroid bed (Fig. 1). Three months after RAI WBS, the patient developed clinically significant orbitopathy. Assay by a local laboratory showed that her TRAb level was elevated (40 IU/L; reference range, 0–1 IU/L). Repeated laboratory tests showed similar results, and the patient was administered oral methylprednisolone therapy by a regional endocrinologist. Subsequently, the patient was admitted to HCC for follow-up of PTC. Physical examination showed an orbitopathy with a clinical activity score (CAS) of 2/7. TRAb remained elevated at 17.13 IU/L (reference range, 0–1.5 IU/L). Magnetic resonance imaging showed radiographic features typical of Graves' orbitopathy (GO) (Fig. 2). One month later, her TRAb concentration remained elevated (20.61 IU/L) with orbitopathy having a CAS of 2/7. However, there was slight subjective clinical improvement. Methylprednisolone therapy was continued while tapering doses. Follow-up four months later showed decreases in TRAb (12.63 IU/L) and orbitopathy (CAS 1/7), as well as clinical improvements. Her methylprednisolone dose was lowered, with the intention of withdrawal. Three months later, at the most recent follow-up visit in December 2019, the patient showed no evidence of ocular symptoms or signs, although her TRAb level



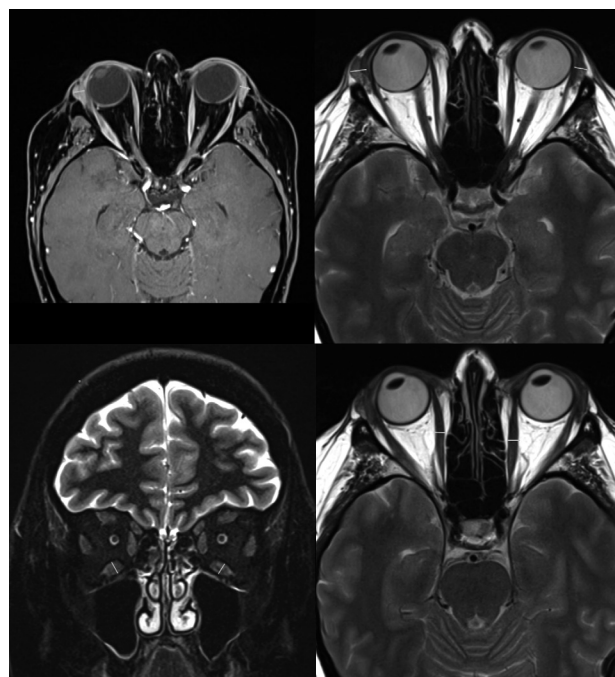


**Figure 1.** Diagnostic thyroid bed scanning and whole-body scanning following administration of low-activity radioiodine. **A.** Diagnostic whole-body radioiodine scanning, showing negligible uptake of iodine in the thyroid bed and no abnormal uptake outside the thyroid bed. **B.** Thyroid bed scan, showing uptake of 0.3% radioiodine during the 24<sup>th</sup> hour

remained elevated (14.50 IU/L). Methylprednisolone therapy was stopped.

Several pathophysiological mechanisms are thought to be responsible for the development of a very rare phenomenon, autoimmune hyperthyroidism, after RAI therapy for autonomous thyroid disease. Radiation damage to the thyrocytes results in the release of thyroid antigens and the activation of autoimmune reactions, inducing TRAb overexpression and GD. Graves' orbitopathy is caused by the cross-reaction of those antibodies with tissue components in the orbit. In one study, only 15 (1.1%) of 1357 patients with autonomous thyroid disease developed post-RAI immunogenic hyperthyroidism between 1 and 13 months after RAI therapy, but only one of those 15 patients presented with endocrine orbitopathy [1]. Patients with elevated TPOAb before RAI therapy were found to be at 10-fold higher risk of developing post-radioiodine GD than patients with normal TPOAb levels. Although GD after previous RAI therapy is rare, it is related to higher RAI activities, averaging 370–555 MBq, and to preservation of the thyroid gland [3, 4]. Overt hyperthyroidism may be induced after total thyroidectomy by thyroid hormones produced by metastatic lesions of follicular thyroid cancer (FTC), but positive TRAb and GD is rarely triggered by repeated high activity RAI therapy in patients with metastatic FTC after total thyroidectomy [5]. The characteristics of our patient were unusual: a thyroid remnant after surgery, no metastases of thyroid cancer, administration of low-activity RAI, and RAI-induced GD manifesting clinically as GO and abnormally high TRAb.

In summary, the results in this patient indicate that GD/GO may be induced by RAI administration follow-



**Figure 2.** Magnetic resonance imaging of the patient's orbits. Magnetic resonance imaging showing stage I of radiological protrusion and enlargement of the eyelids and the extraocular muscles, including the inferior rectus and medial rectus muscles

ing thyroid gland removal, particularly in TPO-positive patients.

### Funding

Project financed under the program of the Minister of Science and Higher Education called "Regional Initiative of Excellence", project no. 024/RID/2018/19, amount of financing 11,999,000.00 zł.

### Conflict of interest

None declared.

### References

- Schmidt M, Gorbauch E, Dietlein M, et al. Incidence of postradioiodine immunogenic hyperthyroidism/Graves' disease in relation to a temporary increase in thyrotropin receptor antibodies after radioiodine therapy for autonomous thyroid disease. *Thyroid*. 2006; 16(3): 281–288, doi: [10.1089/thy.2006.16.281](https://doi.org/10.1089/thy.2006.16.281), indexed in Pubmed: [16571091](https://pubmed.ncbi.nlm.nih.gov/16571091/).
- Vannucchi G, Campi I, Covelli D, et al. Graves' orbitopathy activation after radioactive iodine therapy with and without steroid prophylaxis. *J Clin Endocrinol Metab*. 2009; 94(9): 3381–3386, doi: [10.1210/jc.2009-0506](https://doi.org/10.1210/jc.2009-0506), indexed in Pubmed: [19567525](https://pubmed.ncbi.nlm.nih.gov/19567525/).
- Shen G, Cui F, Huang R, et al. Graves disease following radioiodine therapy for toxic adenoma: Clinical case report. *Medicine (Baltimore)*. 2017; 96(45): e8550, doi: [10.1097/MD.00000000000008550](https://doi.org/10.1097/MD.00000000000008550), indexed in Pubmed: [29137069](https://pubmed.ncbi.nlm.nih.gov/29137069/).
- Yürekli Y, Cengiz A, Güney E. Graves Disease Induced by Radioiodine Therapy for Toxic Nodular Goiter: A Case Report. *Mol Imaging Radionucl Ther*. 2015; 24(3): 135–137, doi: [10.4274/mirt.74046](https://doi.org/10.4274/mirt.74046), indexed in Pubmed: [27529890](https://pubmed.ncbi.nlm.nih.gov/27529890/).
- Aoyama M, Takizawa H, Tsuboi M, et al. A case of metastatic follicular thyroid carcinoma complicated with Graves' disease after total thyroidectomy. *Endocr J*. 2017; 64(12): 1143–1147, doi: [10.1507/endocrj.ej17-0220](https://doi.org/10.1507/endocrj.ej17-0220), indexed in Pubmed: [28883260](https://pubmed.ncbi.nlm.nih.gov/28883260/).