



Neuroendocrine neoplasms of the small intestine and appendix — management guidelines (recommended by the Polish Network of Neuroendocrine Tumours)

Tomasz Bednarczuk^{1*}, Marek Bolanowski^{2*}, Anna Zemczak³, Agata Baldys-Waligórska^{4}, Jolanta Blicharz-Dorniak^{3**}, Agnieszka Boratyn-Nowicka^{5**}, Małgorzata Borowska^{3**}, Andrzej Cichocki^{6**}, Jarosław B. Cwikła^{7**}, Massimo Falconi^{8**}, Wanda Foltyn^{9**}, Daria Handkiewicz-Junak^{10**}, Alicja Hubalewska-Dydejczyk^{4**}, Barbara Jarzab^{10**}, Roman Junik^{11**}, Dariusz Kajdaniuk^{12**}, Grzegorz Kamiński^{13**}, Agnieszka Kolasińska-Cwikła^{14**}, Aldona Kowalska^{15**}, Robert Król^{16**}, Leszek Królicki^{17**}, Jolanta Kunikowska^{17**}, Katarzyna Kuśnierz^{18**}, Paweł Lampe^{18**}, Dariusz Lange^{19**}, Anna Lewczuk-Mysłicka^{20**}, Andrzej Lewiński^{21**}, Michał Lipiński^{22**}, Magdalena Londzin-Olesik^{3**}, Bogdan Marek^{12**}, Anna Nasierowska-Guttmejer^{23**}, Ewa Nowakowska-Duńska^{24**}, Jakub Pałucki^{25**}, Joanna Pilch-Kowalczyk^{26**}, Violetta Rosiek^{9**}, Marek Ruchała^{27**}, Lucyna Siemińska^{12**}, Anna Sowa-Staszczak^{4**}, Teresa Starzyńska^{28**}, Katarzyna Steinhof-Radwańska^{26**}, Janusz Strzelczyk^{9**}, Krzysztof Sworczak^{20**}, Anhelli Syrenicz^{29**}, Andrzej Szawłowski^{30**}, Marek Szczepkowski^{31**}, Ewa Wachuła^{5**}, Wojciech Zajęcki^{3**}, Wojciech Zgliczyński^{32**}, Beata Kos-Kudła^{9**}**

¹Department of Internal Medicine and Endocrinology, Medical University of Warsaw, Poland

²Department of Endocrinology, Diabetes, and Isotope Therapy, Wrocław Medical University, Poland

³Department of Endocrinology and Neuroendocrine Tumours, Medical University of Silesia, Katowice, Poland

⁴Chair and Department of Endocrinology, Jagiellonian University, Medical College, Krakow, Poland

⁵Department of Oncology and Radiotherapy, Medical University of Silesia, Katowice, Poland

⁶Department of Oncological Surgery, Maria Skłodowska-Curie Memorial Cancer Centre and Institute of Oncology, Warsaw, Poland

⁷Department of Radiology, Faculty of Medical Sciences, University of Warmia and Mazury, Olsztyn, Poland

⁸Pancreas Translational & Clinical Research Center, Università Vita e Salute, Milano (Italy)

⁹Department of Endocrinology and Neuroendocrine Tumours, Department of Pathophysiology and Endocrinology, Medical University of Silesia, Katowice, Poland

¹⁰Department of Nuclear Medicine and Endocrine Oncology, Maria Skłodowska-Curie Memorial Cancer Centre and Institute of Oncology, Gliwice Branch, Poland

¹¹Chair and Department of Endocrinology and Diabetology, Nicolaus Copernicus University in Torun, Collegium Medicum in Bydgoszcz, Poland

¹²Division of Pathophysiology, Department of Pathophysiology and Endocrinology, Medical University of Silesia, Katowice, Poland

¹³Department of Endocrinology and Radioisotope Therapy, Military Institute of Medicine, Warsaw, Poland

¹⁴Department of Clinical Oncology, Maria Skłodowska-Curie Memorial Cancer Centre and Institute of Oncology, Warsaw, Poland

¹⁵Endocrinology Clinic of Holycross Cancer Centre, Kielce, Poland

¹⁶Department of General Vascular and Transplant Surgery, Medical University of Silesia, Katowice, Poland

¹⁷Nuclear Medicine Department, Medical University of Warsaw, Poland

¹⁸Department of Gastrointestinal Surgery, Medical University of Silesia, Katowice, Poland

¹⁹Department of Tumour Pathology, Maria Skłodowska-Curie Memorial Cancer Centre and Institute of Oncology, Gliwice Branch, Poland

²⁰Department of Endocrinology and Internal Diseases, Medical University of Gdansk, Poland

²¹Department of Endocrinology and Metabolic Diseases, Medical University of Lodz, Poland

²²Department of Gastroenterology, Central Clinical Hospital of the Ministry of Interior and Administration, Warsaw, Poland

²³Department of Pathology, The Jan Kochanowski University, Kielce, Poland

²⁴Department of Gastroenterology and Hepatology, Medical University of Silesia, Katowice, Poland

²⁵Department of Radiology, Maria Skłodowska-Curie Memorial Cancer Centre and Institute of Oncology, Warsaw, Poland

²⁶Department of Radiology and Nuclear Medicine, Medical University of Silesia, Katowice, Poland

²⁷Department and Clinic of Endocrinology, Metabolism and Internal Diseases, University of Medical Sciences, Poznan, Poland

²⁸Department of Gastroenterology, Pomeranian Medical University, Szczecin, Poland

²⁹Department of Endocrinology, Metabolic and Internal Diseases, Pomeranian Medical University, Szczecin

³⁰Maria Skłodowska-Curie Memorial Cancer Centre and Institute of Oncology, Warsaw, Poland

³¹Department of Colorectal, General, and Oncological Surgery, Centre of Postgraduate Medical Education, Warsaw, Poland

³²Department of Endocrinology, Postgraduate Medical Education Centre, Warsaw, Poland

*co-first authors

**other authors arranged in alphabetical order

***senior author



prof. Tomasz Bednarczuk M.D., Department of Internal Medicine and Endocrinology, Medical University of Warsaw, Banacha St. 1A, 02-097 Warsaw, Poland, phone: +48 22 599 29 75, fax: +48 22 599 19 75, e-mail: tbednarczuk@wum.edu.pl

Abstract

This study presents the revised Polish guidelines regarding the management of patients suffering from neuroendocrine neoplasms (NENs) of the small intestine and appendix. The small intestine, especially the ileum, is the most common location for these neoplasms. Most are well differentiated and slow growing. Their symptoms may be atypical, which can result in delayed or accidental diagnosis. Appendicitis is usually the first manifestation of NEN in this location. Typical symptoms of carcinoid syndrome occur in approximately 20–30% of patients suffering from small intestinal NENs with distant metastases. The main cause of death in patients with carcinoid syndrome is carcinoid heart disease. The most useful laboratory test is the determination of chromogranin A, while concentration of 5-hydroxyindoleacetic acid is helpful in the diagnostics of carcinoid syndrome. For visualisation, ultrasound, computed tomography, magnetic resonance imaging, colonoscopy, video capsule endoscopy, double-balloon enteroscopy, and somatostatin receptor scintigraphy may be used. A detailed histological report is crucial for the proper diagnostics and therapy of NENs of the small intestine and appendix. The treatment of choice is surgical management, either radical or palliative. The pharmacological treatment of the hormonally active and non-active small intestinal NENs as well as NENs of the appendix is based on long-acting somatostatin analogues. In patients with generalised NENs of the small intestine in progress during the SSA treatment, with good expression of somatostatin receptors, the first-line treatment should be radioisotope therapy, while targeted therapies, such as everolimus, should be considered afterwards. When the above therapies are exhausted, in certain cases chemotherapy may be considered. (*Endokrynol Pol* 2017; 68 (2): 223–236)

Key words: neuroendocrine neoplasms; guidelines; small intestine; appendix; carcinoid syndrome; somatostatin analogues; PRRT, radioisotope therapy; everolimus

Introduction

Neuroendocrine neoplasms (NEN) of the small intestine originate in the midgut, with the small intestine being the third most common site of their occurrence, after the pancreas and large intestine. From the clinical point of view, we distinguish between hormonally active and non-active NENs. Hormonally active NENs secrete substances that cause the characteristic symptoms known as carcinoid syndrome. Most small intestinal NENs are well differentiated and grow slowly. Rarely, they may be poorly differentiated, with rapid growth and a poor prognosis. However, small intestinal NENs are often diagnosed in the generalised stage with distant metastases. Tumours in this location are very rarely part of MEN 1 syndrome [1–4].

Neuroendocrine neoplasms of the end part of the small intestine and the appendix are mostly composed of EC (enterochromaffin) cells, responsible for serotonin production. Certain NENs demonstrate the ability to secrete enteroglucagon, glucagon, or other peptides. It is believed that ileum NENs are more aggressive than the neuroendocrine tumours of the duodenum, tumours of the stomach built of ECL (enterochromaffin-like) cells, or tumours of the rectum. They demonstrate a higher metastatic ability, associated to a lesser degree with the size of the tumour [1–3].

1. Epidemiology

The small intestine, particularly the ileum, is the most common site of NENs in the human body. Small intestinal NENs occur equally often in male and female patients; they affect all age groups, with the peak in the 6th and 7th decades of life. The estimated prevalence is 0.32–1.12 per 100,000 of the population per year, including malignancy in 0.29 per 100,000. Apart

from the small intestine, they also affect the appendix [3, 5–11]. In post-mortem examinations the reported prevalence increases to 1.22% [3, 12]. Tumours originating from the lower part of the jejunum and the ileum constitute 23–38% of all gastro-entero-pancreatic endocrine neoplasms, and they are more common than endocrine neoplasms of the appendix, also described in paediatric patients [3, 13, 14]. Hormonally active neuroendocrine neoplasms of the small intestine are often multifocal, and in 15% of cases are associated with other neoplasms such as gastrointestinal adenocarcinoma or breast cancer [3].

The term *carcinoid* is still associated with a certain ambiguity. In the past, the term referred to a neuroendocrine neoplasm, regardless of the location of the primary tumour site or the level of malignancy. Later, in Europe, carcinoids were limited to neoplasms originating from the midgut, secreting serotonin and associated with carcinoid syndrome symptoms. However, the World Health Organisation (WHO) 2010 classification of the gastro-entero-pancreatic neuroendocrine neoplasms attributed the term carcinoid to G1 neuroendocrine neoplasms. The Polish Network of Neuroendocrine Tumours argues that the term ‘carcinoid’ should be relinquished, and substituted with the name ‘neuroendocrine tumour’ or ‘neuroendocrine neoplasm’ [2, 3, 5, 15, 16].

Over the last 30 years, the incidence of neuroendocrine neoplasms of the gastrointestinal tract has increased by 720%, and of the small intestine by 460%. In this period there has also been an increase in the ileum neuroendocrine neoplasm rate within the small intestine, from 52% to 63.6%. This is very important because neoplasms are malignant in this area in 58% of cases, whereas this group of tumours constitutes no more than 35% of cases within the whole small intestine. A higher prevalence has been observed in African-Americans

and in females, compared to Caucasians and males. Although the increase in the diagnosis of gastric and rectal NENs can be partially explained by the development of endoscopic techniques, such an explanation does not apply to the higher incidence of small intestinal NENs [2, 3, 5, 17, 18]. According to experts from the Polish Network of Neuroendocrine Tumours, endoscopic tests of the large intestine, including screening colonoscopy (over about a 20 year period) increased the detection of small intestinal NENs. The person performing colonoscopy in most cases assesses not only the large intestine, but also the terminal part of the small intestine, where small intestinal NENs are found most frequently [19, 20].

Most tumours are located in the terminal part of the ileum, in close proximity to the ileocaecal valve. They often involve metastases to the regional lymph nodes, and then to the liver. The prognosis in these cases is usually poor and depends on the TNM staging assessment and Ki-67 grading [3, 16]. The five-year survival rate is 100% for patients with stages I and II small intestinal NENs, 97.1% for patients with stage III, and 84.8% for patients with stage IV. Based on the level of tumour differentiation, the five-year survival rate is 93.8% for G1, 83% for G2, and 50% for G3 [3, 21]. Other studies have reported the five-year survival rate to be 72% in patients with local tumours, and 55% in patients with distant metastases [3, 22]. According to alternative European data, the five-year survival rate is 59–74% in patients with NENs of the small intestine and appendix [3, 9, 23]. Previous observations demonstrated a ten-year survival rate of 60% in patients without liver metastases at the diagnosis, and 15–25% in metastatic patients. Multifactorial analyses suggest that tumour metastases to the lymph nodes, hepatic involvement, and distant metastases outside the abdominal cavity are independently related to the survival rates. Moreover, the prognosis may improve if the primary tumour is removed [3].

2. Clinical characteristics

2.1. Symptoms of the hormonally active NETs of the small intestine — carcinoid syndrome

Carcinoid syndrome occurs in approximately 20–30% of patients suffering from small intestinal NETs with distant metastases. Carcinoid syndrome comprises symptoms resulting from an excessive secretion of serotonin and other biologically active compounds by the tumour (including kinins, prostaglandins, and histamine). Serotonin secreted to the portal venous system is metabolised in the liver and does not cause any clinical symptoms. The symptoms occur if serotonin and other biogenic amines are secreted directly to the systemic circulation; therefore, the carcinoid syndrome symptoms occur most often with hepatic metastases from NETs (approximately 95% of cases) [1,3].

Clinical symptoms of carcinoid syndrome include: (a) symptoms affecting the skin (flushing, telangiectasis, pellagra — skin inflammation caused by vitamin PP deficiency, resulting from the use of tryptophan for excessive serotonin production by the neoplasm); (b) symptoms affecting the gastrointestinal tract (secretory diarrhoea, non-specific or colic abdominal pains); (c) symptoms affecting the cardiovascular system (tricuspid valve disorders, diseases of the pulmonary trunk, rarely mitral valve and aorta disorders); (d) symptoms affecting the respiratory system (bronchial asthma); and e) symptoms affecting the musculoskeletal system (osteoarticular pains, myopathies) [3, 24]. Carcinoid syndrome significantly reduces the quality of life in patients with small intestinal NETs [25].

Flushing is one of the main symptoms of carcinoid syndrome (60–85% of patients). The flushing that accompanies serotonin secreting NETs of the small intestine (classical carcinoid syndrome) is pale-pink to red, affecting the face and upper chest, and lasting up to 30 minutes. Triggering factors include alcohol, spicy foods, emotional stress, and medications (serotonin reuptake inhibitors). Flushing in the case of foregut NETs (atypical form of carcinoid syndrome) is more intensive, with a crimson shade, and lasts longer (as long as several days) [3, 26].

The main causes of death in patients with carcinoid syndrome are heart diseases — referred to as carcinoid heart disease (CHD) or Hedinger's syndrome, which may affect 25–50% of patients. CHD is mainly characterised by plaques of fibrous tissue on the valves of the right heart, leading to tricuspid valve regurgitation/stenosis (the most common defect) and stenosis/regurgitation of the pulmonary valve. Initially the clinical symptoms of CHD are weakly pronounced; later the symptoms of right ventricular heart failure progress. The prognosis for patients with CHD and severe heart failure (NYHA classes III and IV) is unfavourable; the median survival rate for patients without cardio-surgical treatment is 11 months. The gold standard in CHD diagnosis is echocardiography, which should be performed in all patients with carcinoid syndrome. Possible NET metastases to the pericardium should also be considered [3, 27–29].

Carcinoid crisis is a rare, life-threatening complication caused by a sudden release of biologically active substances to the systemic circulation. The symptoms include: prolonged skin redness, intense diarrhoea or vomiting, wheezing, blood pressure fluctuations, arrhythmia, disturbed nervous system function, dehydration, shock, acute renal failure, or hypercalcaemia. The crisis may occur independently, during infection, or as a result of medical procedures: general anaesthesia, endoscopy, tumour biopsy, surgery, embolisation, radioisotope therapy,

or chemotherapy [3, 30]. Therefore, it is recommended that somatostatin analogues are used in the pre-operative period or during surgery on NEN patients [3].

2.2. Symptoms of hormonally non-active NENs of the small intestine

The clinical picture of hormonally non-active NENs of the small intestine relates to the local symptoms. Small tumours are usually asymptomatic; they are found while identifying the source of metastases, or accidentally during colonoscopy in the ileocaecal region. Larger tumours, of more than 1 cm, are usually malignant and metastatic. The most common symptoms reported by patients are non-specific and include transient abdominal pains and discomfort (lasting for years, and often misinterpreted as irritable bowel syndrome), weight loss, and weakness. Over time, the symptoms worsen and may result in transient obstructions of the small intestine caused by the presence of the tumour mass, or by the desmoplastic reaction of the mesentery. Moreover, the desmoplastic reaction can impair the blood supply in the intestines, in severe cases leading to necrosis. A desmoplastic reaction rarely results in retroperitoneal fibrosis or hydronephrosis. Severe gastrointestinal bleeding is a rare symptom of small intestine NENs [3, 4, 31].

2.3. Symptoms of NENs of the appendix (aNENs)

Appendicitis is usually the first manifestation of carcinoid in this location. Over half of the neuroendocrine neoplasms of the appendix are discovered accidentally following appendectomy. Most NENs of the appendix are diagnosed at the early stages. This contributes to a high survival rate in patients with tumours in this location, which is particularly visible in children, where over 80% of the diagnosed tumours are smaller than 1 cm. The size of the tumour is of crucial importance for the occurrence of metastases: for tumours smaller than 1 cm in diameter, metastases occur in 2%; for tumours of 1–2 cm in diameter, it is 50%; and for tumours larger than 2 cm, it is 80–90% of patients [3, 32]. Based on the data analysis from the SEER database, 10-year survival was observed in 100% of aNEN patients without lymph node metastases, and over 90% in metastatic patients, regardless of the size of the original tumour [33].

3. Diagnostics

3.1. Laboratory diagnostics

In the biochemical diagnostics of NEN of the small intestine and appendix, it is useful to determine the concentration of chromogranin A (CgA) — a sensitive although not highly specific marker (*the determination*

and interpretation of results are described in the section on general diagnostics of gastro-entero-pancreatic neuroendocrine tumours). A significantly increased CgA concentration may be treated as an indicator of poor prognosis [3, 34–36].

The assessment of 5-hydroxyindoleacetic acid (5-HIAA) excretion in urine is a sensitive tumour indicator, useful for the diagnosis and monitoring of disease progression or treatment in patients with carcinoid syndrome. The sensitivity and specificity of 5-HIAA determination in order to confirm carcinoid syndrome are 70–100% and 85–90%, respectively [3]. The determination of blood serotonin levels is not presently recommended in the diagnostics of carcinoid syndrome [34, 37].

In the diagnostics and assessment of the severity of carcinoid heart disease, the determination of 5-HIAA and NT-proBNP (N-terminal-pro-B-type natriuretic peptide) may be useful [3, 34, 38].

Tests on the use of new biomarkers indicate that molecular tests could be used in the diagnostics and monitoring of NENs. Once validated, they would most probably be implemented in clinical practice [39, 40].

Minimal consensus statement on biochemical tests:

- CgA and 5-HIAA in all patients diagnosed with NEN of the small intestine before treatment and during monitoring (*evidence level 3);
- 5-HIAA — in patients with suspected carcinoid syndrome (*evidence level 3);
- NT-proBNP — in the case of carcinoid heart disease (*evidence level 4).

3.2. Imaging and endoscopic diagnostics

3.2.1 Primary tumour location

The diagnostics of small intestine diseases may include computed tomography (CT) enterography/enteroclysis or magnetic resonance imaging (MRI) enterography/enteroclysis, which locate the primary focus in the small intestine in approximately 90–97% of patients [41–43]. For the follow-up concerning small intestine diseases, CT or MRI enterography should be applied. MRI enteroclysis should be performed in patients with a clinically suspected pathology of the small intestine and with negative MRI/CT enterography results [3, 5, 44, 45].

Ultrasonography (US) is of limited use in detecting the primary tumour site. It is a subjective test, where the results depend on the quality of the equipment. In individual cases a transabdominal US of the small intestine, using high frequency probes, may enable the detection of the primary tumour site. However, possible secondary lesions in the mesentery should be consid-

*evidence level according to OCEBM [109]

ered, such as enlarged, hypoechogenic lymph nodes, or fibrosis/thickening of the mesentery, which may be more visible than a small primary tumour site hidden in the intestinal wall. It may be of use in the preliminary diagnostics of patients with suspected NENs [46].

Endoscopic diagnostics of the small intestine is usually undertaken to identify the primary tumour site in the case of metastases of unknown origin (often significantly larger than the primary tumour), in the case of non-specific abdominal symptoms, or to find the cause of gastrointestinal bleeding [3, 47]. The common use of colonoscopy, including screening colonoscopy, enables early detection of small intestinal lesions. The direct presentation of a NEN located in the small intestine is possible during a colonoscopy, when the tumour protrudes through the ileocaecal valve into the caecum lumen (such cases are very rare), but primarily takes place during routine assessment of the distal section of the small intestine. Colonoscopy is also important to exclude a concomitant neoplastic disease, and it enables endoscopic treatment [48]. Endoscopic ultrasonography (EUS), unlike for other locations of GEP NEN lesions, is of no use in the diagnostics of small intestine tumours [3].

Video capsule endoscopy (VCE) and balloon or spiral enteroscopy can be used for direct assessment of the jejunum and ileum mucosa, but these methods are not commonly used. A complete assessment of the small intestine is achieved in approximately 80% of patients, and the overall diagnostic efficiency of the test is about 55% [3, 49–53]. VCE sensitivity in the diagnosis of neuroendocrine tumours is relatively low, and compared to CT enterography is 29–37.5% vs. 50–92% [3, 54]. It is worth emphasising that neuroendocrine neoplasms of the small intestine, due to secreted growth factors resulting in desmoplastic reactions of the mesentery, often cause significant narrowing of the intestine, which is an absolute contraindication for video capsule endoscopy, because of the risk of capsule incarceration [55]. Another disadvantage of VCE is the inability to locate the tumour precisely [3, 56–58]. Balloon enteroscopy or spiral enteroscopy are not associated with this shortcoming, but their diagnostic efficiency is not very high [3, 59–62]. Enteroscopy enables not only the detection of small intestinal lesions, but also of endoscopic treatment [63].

Radioisotope diagnostics with the use of radioisotope-labelled somatostatin analogues (somatostatin receptor imaging, SRI) is a more sensitive method than radiological tests. The sensitivity of SRI is approximately 80% for the identification of the primary tumour site [64, 65]. Examinations using positron tracers (e.g. ^{68}Ga) are the preferred imaging method, particularly if the

lesions are < 1 cm [66]. To locate the primary tumour site and assess the disease stage, SRI in correlation with multiphase CT/MRI is recommended. In the case of incomplete surgery of the NEN of the appendix or if distant metastases are suspected, SRI should be performed [67].

3.2.2. Evaluation of the stage of advancement and response to treatment

Multiphase, mostly three-phase, CT or MRI examinations after intravenous administration of the contrast agent and filling the intestinal lumen with a negative contrast agent, as well as SRI, are methods that enable the monitoring of the disease and assessment of the response to therapy [p. 79–110].

Minimal consensus statement on imaging and endoscopic examinations:

*To locate the primary tumour site and assess the stage of advancement, SRI in correlation with multiphase CT/MRI is recommended (*evidence level 3)*

— *CT/MRI enterography, CT/MRI enteroclysis, or endoscopic techniques may be required to locate the primary tumour site (*evidence level 3).*

— *Colonoscopy and assessment of the terminal section of the ileum to detect the primary lesion and to exclude a concomitant neoplastic disease (colon cancer) (*evidence level 4).*

3.3. Pathomorphological diagnostics

3.3.1. NENs of the small intestine

Neuroendocrine tumours of the small intestine differ from other gastro-entero-pancreatic NETs, as they originate exclusively from serotonin-producing cells. Most are well-differentiated and demonstrate low proliferative activity. Therefore, their growth is slow and associated with slowly increasing, non-specific clinical symptoms. Thus, most of them are diagnosed as a regional, advanced disease. The diagnostics of small intestine NENs, due to their specific clinical course, is frequently based on the assessment of the material from a large-core needle biopsy of the tumour (or its hepatic metastases), which is often the first clinical symptom, or examination of the small intestine material removed due to obstruction, along with the previously undiagnosed tumour.

3.3.1.1. Diagnostic algorithm

Histopathological reporting is still the basis for the diagnosis of neuroendocrine tumours, as well as for other solid neoplasms. Histopathological type and stage of advancement according to the current standards enable the application of therapeutic management according to the current state of knowledge [4].

*evidence level according to OCEBM [109]

Macroscopic assessment of small intestinal NENs in post-surgical material

Procedures included in the Standards of the Polish Society of Pathologists should be followed during preparation of the post-surgical material from the removed small intestinal tumour [68].

1. The tumour location, considering the length of the intestinal section obtained for examination, the tumour relation to the intestine resection margins, and the width of the removed intestinal mesentery.
2. Tumour size, preferably in three dimensions. In the case of numerous lesions, their size, mutual relation, and resection margins should be provided. Relation of the tumour(s) to the layers of the intestinal and mesenteric wall.
3. Presence and size of the mesenteric lymph nodes.
4. Other pathological lesions in the assessed material.

Microscopic assessment on NENs:

The histopathological assessment is based on the WHO 2017 [69] classification and [69] ENETS 2016 guidelines [4,32] together with the AJCC 8th edition from 2017 [70]. As in other sections of the gastrointestinal tract, NENs are classified as neuroendocrine well-differentiated neoplasms: NETs G1 with Ki-67 index below 3% and NETs G2 with Ki-67 between 3% and 20%, and NEC, which include NETs G3 and neuroendocrine carcinomas: large- or small-cell NEC, and MiNEN (mixed endocrine non-endocrine neoplasms). The diagnostic criteria are discussed in *Diagnostic and therapeutic guidelines for gastro-entero-pancreatic neuroendocrine neoplasms* (p. 79–110). Histopathological assessment should include:

1. Histopathological type of the NEN according to the WHO 2017 classification, completed with Chapter 2.2 and Table VII.
2. The histological grading (G) according to ENETS/WHO 2017.
3. Assessment of the immunohistochemical expression of neuroendocrine markers: chromogranin A and synaptophysin, as well as Ki-67/MIB1 proliferative activity (as described below) according to the procedure described in the general section – obligatory [32, 71, 72].
4. Pathomorphological pTNM staging according to ENETS and AJCC/UICC — obligatory — Table I. Assessment of clinical staging conditional — Table II [4].
5. Assessment of other immunohistochemical markers, such as NSE, CD56, CDX2, serotonin, somatostatin receptors — conditional [4].

A minimal histopathological report on small intestinal NEN should include:

- Histological type of the neoplasm according to the WHO classification, considering the division into

Table I. TNM UICC/AJCC and ENETS classification systems for NENs of the small intestine [32, 71, 72].

Feature T – primary tumour x	Comment
TX	The tumour has not been assessed
T0	No evidence of a primary tumour
T1	Tumour invades the lamina propria or submucosa and is ≤ 1 cm
T2	Tumour invades the muscularis propria and/or is > 1 cm
T3	Tumour penetrates the muscularis propria and invades the subserosal tissue, without serosal invasion
T4	Tumour invades the peritoneum, other organs, or adjacent structures
N — regional lymph nodes	comment
NX	Lymph nodes have not been assessed
N0	No regional lymph node metastases
N1	Regional lymph node metastases
M — distant metastases	comment
MX	Distant metastases cannot be assessed
M0	No distant metastases
M1	Distant metastases

x If more than one tumour is present, we add “m” to the letter T, regardless of the size. xx If there is evidence of distant metastasis, the anatomical site should be specified in the brackets as follows: PUL for pulmonary, HEP for hepatic, and OSS for osseous.

well-differentiated neuroendocrine neoplasms (NETs G1 and NETs G2) with Ki-67 index below 20%, and NETs G3 and neuroendocrine carcinomas (NECs) with Ki-67 index above 20% or mixed neoplasms (MiNEN).

- Histological G grading, referring to well-differentiated neoplasms (NETs G1, NETs G2, NETs G3).
- pTNM histopathological staging according to ENETS and AJCC/UICC classifications (it is important to provide the affiliation of the classification in each case);
- Assessment of surgical margins.
- The histopathological diagnosis of NEN must be confirmed by immunohistochemical tests assessing the expression of the neuroendocrine markers: synaptophysin and chromogranin A, as well as Ki-67 proliferative activity using the MIB1 antigen.

Recent TNM UICC 2017 classification [72] divides metastases to lymph nodes into N1: metastases present in less than 12 lymph nodes, of ≤ 2 cm, and N2: metastases present in 12 or more lymph nodes and/or presence of a metastases of > 2 cm.

The classification of distant metastases also changes. Metastases (feature M1) is divided into three groups.

Table II. *Small intestinal NENs staging [4]*

Stage	T feature	N feature	M feature	Advancement
0	Tis	N0	M0	Local neoplasm
I	T1	N0	M0	Local neoplasm
IIA	T2	N0	M0	Local neoplasm
IIB	T3	N0	M0	Local neoplasm
IIIA	T4	N0	M0	Local neoplasm
IIIB	T1-T4	N1	M0	Regional neoplasm
IV	T1-T4	any	M1	Generalised neoplasm

M1a Only hepatic metastases,

M1b Extra-hepatic metastases,

M1c Both hepatic and extra-hepatic metastases.

Clinical staging of NENs of the small intestine according to ENETS is presented in Table II [4]

A slightly less developed clinical staging according to AJCC/UICC 2017 is presented for comparison [71, 72] (Table III).

3.3.2. Neuroendocrine neoplasms of the appendix Pathogenesis

Most NENs of the appendix are detected during surgery due to acute inflammation of the organ.

Well-differentiated NENs are mostly found in the terminal part of the appendix (75%), less frequently in the middle part (15%) and in the proximal margin (10%). Macroscopically, they form hard, whitish-yellow, not encapsulated nodules, with an expanding growth margin, whereas MiNEN tumours, including goblet cell carcinoid, are white, sometimes mucous, of 1–5 cm in diameter (mean diameter of 2 cm), and show an infiltrative growth pattern. These neoplasms are malignant; they are classified and treated like classical adenocarcinomas of the appendix [3].

3.3.2.1. Diagnostic algorithm

Contrary to the NENs of the jejunum and ileum, for which a similar consensus was developed regarding the assessment of the T-staging, two classifications are recommended for the NENs of the appendix: one by the European Neuroendocrine Tumour Society (ENETS) and the other by the American associations: American Joint Committee on Cancer/*Union for International Cancer Control* (AJCC/UICC). It is recommended that both classifications are used. Firstly, because presently there is no evidence in favour of the usefulness of either of them, and secondly, because in cases raising doubts as to the scope of therapeutic management on the basis of one classification, the use of the other one could resolve the doubts [3].

Table III. *AJCC/UICC 2017 staging classification for NENs [71, 72]*

Clinical stage	T feature	N feature	M feature
Stage I	T1	N0	M0
Stage II	T2, T3	N0	M0
Stage III	T4	Any N	M0
	Any T	N1, N2	M0
Stage IV	Any T	Any N	M1

Macroscopic assessment of NENs of the appendix.

A relatively low incidence of NENs of the appendix should always be a reason for very careful macroscopic examination and careful sample collection. Procedures included in the Standards of the Polish Society of Pathologists should be followed during the preparation of the post-surgical material from the removed small intestinal tumour [68]. The samples should be collected from the end of the appendix, its middle part, and base (the proximal colonic margin), and the size of the tumour should be stated.

The macroscopic description should include the following:

The length of the appendix obtained for examination, with a description of the tumour location relative to the resection margin.

— Tumour assessment: the size in three dimensions, and cross-section appearance.

— Condition of the serosa and mesoappendix at the tumour site — it is necessary to collect numerous samples.

Microscopic assessment of NENs of the appendix:

1. Histological type of NEN according to the 2017 WHO classification [3, 69] completed with information from Chapter 2.2 and Table VII.
2. The histological grading (G) according to ENETS [3, 32].
3. Assessment of immunohistochemical expression of neuroendocrine markers: chromogranin A and synaptophysin, as well the Ki-67/MIB1 proliferative activity, is obligatory. Immunohistochemical assessment of NSE, CD56, CDX2 markers, and serotonin is recommended conditionally, in the case of metastatic differentiation, especially if the original site of the neoplasm is unknown. A positive reaction with CDX2 and/or serotonin indicates an intestinal, particularly ileocaecal, origin of the neoplasm [3].
4. The ENETS [32] and AJCC/UICC [71, 72] histopathological staging regarding the T-feature of NENs of the appendix is presented in Table IV [32, 71, 72].

Table IV. *pTNM classification for NENs of the appendix according to ENETS [32] and AJCC / UICC 8th edition 2017 [71, 72]*

T feature	ENETS	AJCC/UICC
x	The tumour has not been assessed	
0	No evidence of a primary tumour	
T1	Tumour of the largest diameter of ≤ 1 cm invading the submucosa and muscularis propria	Tumour of the largest diameter ≤ 2 cm
T2	Tumour ≤ 2 cm and/or minimally (up to 3 mm) invading the submucosa, muscularis propria, and/or invading the subserosa and/or mesoappendix	Tumour > 2 cm and < 4 cm
T3	Tumour > 2 cm and/or invading the subserosa/mesoappendix to a depth greater than 3 mm	Tumour of > 4 cm or tumour invading the subserosa or invading mesoappendix
T4	Tumour invading the serosa or adjacent organs	Tumour invading the peritoneum or other adjacent organs or structures (except direct intramural infiltration of the adjacent serosa or the intestinal wall)
N feature		
Nx	Lymph nodes could not be assessed histopathologically	
N0	No metastases in the regional lymph nodes	
N1	Metastases or metastases to the regional lymph nodes	
M feature		
Mx	Distant metastases could not be assessed histopathologically	
M0	No distant metastases	
M1	Metastases or distant metastases	

Prognostic factors for NENs of the appendix

Tumour size and infiltration of the mesoappendix are important risk factors of NENs of the appendix. According to European and American guidelines, they form the criteria for division into pTNM classification stages. According to a report by the College of American Pathologists, cases in which the diameter of the tumour is above 1 cm and below 2 cm, where infiltration of the mesoappendix is present, should be treated as those having an uncertain prognosis. Potentially benign tumours are smaller than 1 cm and do not invade the mesoappendix. It is worth emphasising that, according to the pTNM 2010 classification, NECs of the appendix and MANECs composed of classical and neuroendocrine carcinoma components, as well as goblet-cell carcinoids, are diagnosed following the criteria for classical carcinomas, and not those for NENs.

Apart from the above features, the histopathological report should include the assessment of margins: proximal, distal, mesoappendiceal, and radial, as well as the angioinvasion of blood vessels. It should be noted that it is necessary to examine the colonic proximal margin because invasion of the caecum/colon determines the treatment method. During the assessment of the slides, particular attention should also be paid to any small periserosal vessels, which could be ignored, especially if the samples from the periphery of the tumour were inadequately collected [3].

UICC 2017 classification system, as was the case with the small intestine, differentiates metastases (M1) from the appendix in the following manner:

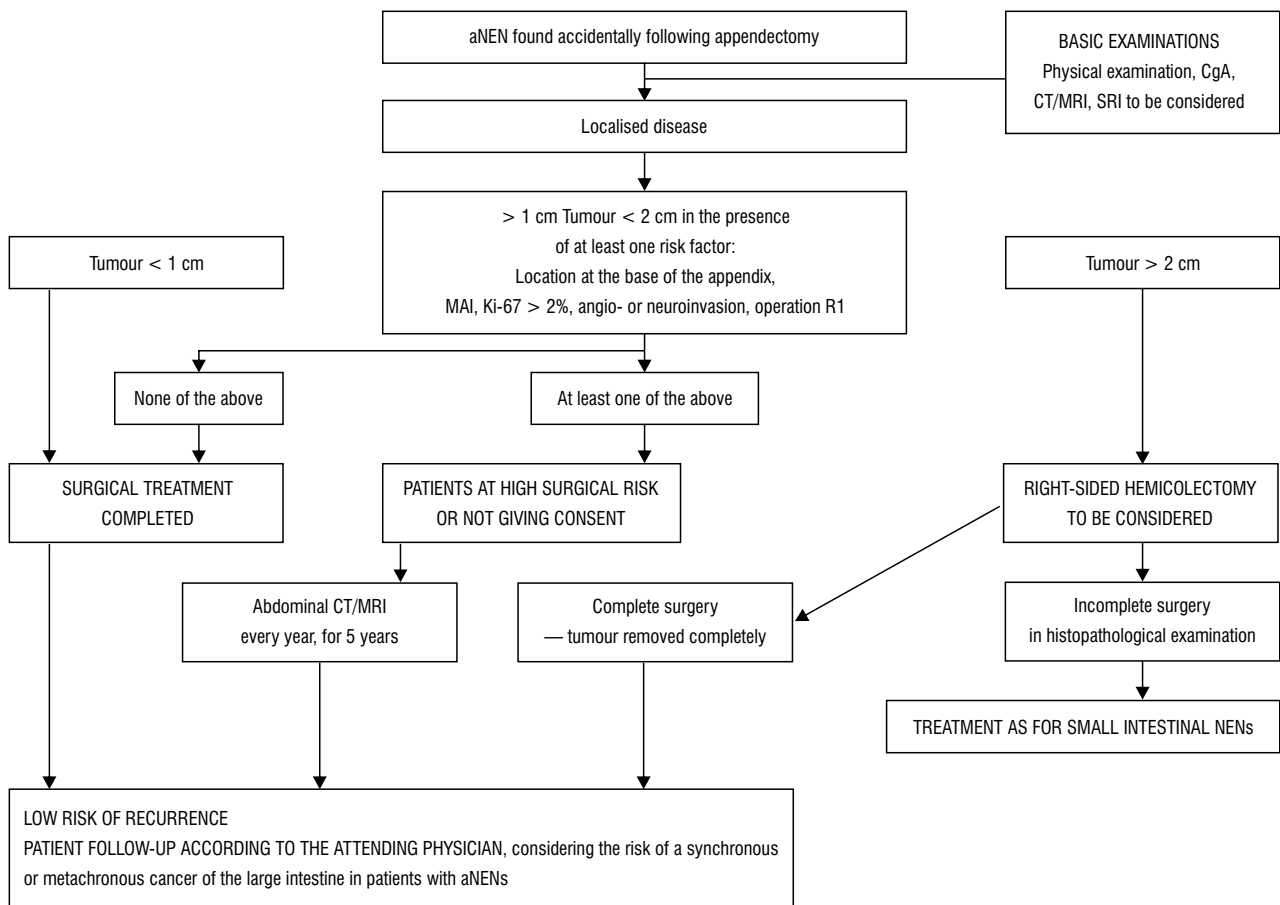
- M1a Only hepatic metastases,
- M1b Extra-hepatic metastases,
- M1c Both hepatic and extra-hepatic metastases.

Clinical advancement stage according to the same classification system for the appendix is almost identical as for the small intestine. The only difference regards features N1 and N2, dependant on the number and weight of the metastases, which are not considered during the assessment of lymph node metastases, but only the presence of N1 metastasis is reported [72].

Minimal consensus statement on pathomorphological examination:

— *Minimal histopathological report on NENs of the small intestine and the appendix should include:*

- *Histological type of the neoplasm according to the WHO classification, considering the division into well-differentiated neuroendocrine neoplasms (NEN) and neuroendocrine carcinomas (NEC) or mixed neoplasms (MiNEN);*
- *Histological G grading referring to well-differentiated neoplasms (NEN G1, NEN G2);*
- *pTNM histopathological staging according to ENETS and AJCC/UICC classifications (it is important to provide affiliation of the classification in each case);*



*Performance of SRI depends on the experience and choice of the treating centre; there is no evidence of the effectiveness or necessity for this diagnostic management

**Patients who cannot be operated on due to concurrent diseases, or who do not give consent to a surgical treatment

Figure 1. Algorithm of therapeutic management and monitoring of neuroendocrine tumours of the appendix found accidentally during appendectomy due to acute appendicitis or another gynaecological or surgical procedure in the abdominal cavity [75] aNENs — neuroendocrine neoplasm of the appendix; MAI — mesoappendiceal infiltration; MRI — magnetic resonance; NEN — neuroendocrine neoplasm; SRI — somatostatin receptor imaging; US — ultrasonography

- Assessment of surgical margins.

— The histopathological diagnosis of NEN must be confirmed by immunohistochemical tests assessing expression of the neuroendocrine markers: synaptophysin and chromogranin A, as well as Ki-67 proliferative activity using the MIB1 antigen.

4. Treatment

4.1. Surgical treatment

NENs of the midgut are usually located in the distal part of the small intestine or in the appendix. They frequently present in a multi-focal form, with concurrent hepatic metastases [3, 73]. The preferred treatment of intestinal NENs is partial or multiple resection with lymphadenectomy, as a radical treatment, or palliative, cytoreductive surgery reducing the tumour mass by approximately 90% [3]. If possible, the primary tumour site should be removed, even if the disease is generalised,

with concurrent resection or enucleation of the hepatic metastatic lesions [74].

Treatment of aNENs depends primarily on the tumour size and the intensity of infiltration of the primary tumour [75–77]. The indications for right-sided hemicolectomy are the following tumour features:

1. Diameter of more than 2 cm, aNEN G1/G2 (NET classified as at least T3 (ENETS) or T2 (UICC/AJCC) [5, 13, 78–82];
2. Location at the base of the appendix (although there is no evidence for a poorer prognosis, and in such cases a higher incidence of complications should always be considered, compared to simple appendectomy) [79, 83–86];
3. Mesoappendiceal invasion, MAI (there is no evidence of a correlation between the tumour size and MAI, which questions the ENETS arbitrary infiltration depth of 3 mm as a border between T2 < 3 mm and T3 > 3 mm) [5];

4. Presence in the R1 resection margin, inability to assess the completeness of tumour resection, or doubts as to the completeness of tumour resection [5, 80, 81, 86];
5. G2 feature according to WHO [87];
6. V1 neuro- and angioinvasion, L1 infiltration of lymph nodes — increase the risk of metastases to the lymph nodes [82];
7. Goblet cell carcinoid, MiNEN and NEC G3 are not classified as NEN; they should be treated according to the recommendations regarding adenocarcinoma [5, 32, 71, 76];
8. In NENs of the appendix with hepatic metastases, the recommended management is right-sided hemicolectomy including removal of the metastases (anatomical and non-anatomical resections) [74].

In the case of multiple metastases, a palliative surgery removing the metastases should be considered (resection, thermoablation, chemoembolisation) [5, 32] (Fig. 1).

Minimal consensus statement on surgical treatment:

- Surgical treatment of the midgut tumours involves the complete removal of the tumour within the healthy tissue, together with the lymph nodes (*evidence level 3).
- In palliative treatment, cytoreductive management should be considered (*evidence level 3).
- In tumours of the appendix of < 2 cm, without any risk factors, appendectomy should be performed.
- In tumours of > 2 cm and more advanced tumours, right-sided hemicolectomy should be performed (*evidence level 3).

4.2. Symptomatic pharmacological treatment

4.2.1. Symptomatic treatment in carcinoid syndrome

- Long-acting somatostatin analogues: octreotide LAR (10–30 mg i.m. every four weeks, but the lowest dose is rarely used), lanreotide Autogel (60–120 mg s.c. every 4–6 weeks, but the lowest dose is rarely used) are the gold standards in the treatment of carcinoid syndrome (see p. 79–110) [88, 89, 90, 91]. Radioisotope imaging of somatostatin receptors is not required before the SSA treatment.
- If the symptom control is not satisfactory during standard treatment with long-acting somatostatin analogues, the following should be considered: reducing the interval between injections, increasing the dose of SSA, and/or adding a short-acting SSA (octreotide, solution for injections 100 µg/amp).
- In the case of resistance to SSA, in some patients a new SSA (pasireotide) is found to be effective [92]. Moreover, a new drug inhibiting the biosynthesis of serotonin, telotristat (LX1032), is presently being

studied in clinical trials in patients with carcinoid syndrome [93, 94].

- The symptomatic treatment of patients with carcinoid syndrome also involves loperamide, ondansetron, and pancreatic enzymes, or group B vitamins in case of deficiency [23].
- Patients with carcinoid heart disease require care in referential cardiological and cardiosurgical centres [27]

4.2.2. Carcinoid crisis treatment

- There are no clear EBM recommendations for the management of carcinoid crisis [3].
- The soonest possible introduction of somatostatin analogue therapy is of the greatest importance; a short-acting SSA in high doses is usually administered intravenously (octreotide: 25–500 µg/h IV; on average 100–200 µg/h IV) [30]. In carcinoid crisis (particularly in NENs of the foregut), the administration of glucocorticoids and antihistamines may be considered.
- It is necessary to introduce intensive symptomatic treatment of dehydration, acute renal failure, hypercalcaemia, arterial hypertension or hypotonia, cardiac failure, and infection [3].

4.2.3. Preparation of patients with NETs of the small intestine and the appendix for surgery

- There are no clear recommendations for the preparation of patients with NENs of the small intestine and appendix for surgery [95].
- In patients with carcinoid syndrome, pre-operative administration of short-acting SSA should be considered, regardless of the long-acting SSA therapy (e.g. octreotide 200–300 µg s.c. before the surgery and/or continuous infusion of 50–100 µg/hour intraoperatively and/or 24–48 hours after the surgery) [3]. Cardiological consultation should be considered before the surgery.
- In patients with hormonally non-active NENs, it is recommended that a short-acting SSA should be available during the operation, and administered in the case of an unstable haemodynamic condition [3].

4.3. Systemic treatment of small intestinal NENs in the generalised period

4.3.1. Long-acting somatostatin analogues

- Long-acting somatostatin analogues: octreotide LAR (30 mg i.m. every four weeks), lanreotide Autogel (120 mg s.c. every four weeks) are first-line therapies to stabilise neoplastic disease in patients

*evidence level according to OCEBM [109]

with well-differentiated NETs of the small intestine in the generalised period (*see* p. 79–110) [96, 97].

4.3.2. Peptide Receptor Radionuclide Therapy with radioisotope-labelled somatostatin analogues (PRRT)

- In patients with metastatic NETs of the small intestine with a high expression of somatostatin receptors, in progression during the SSA treatment, therapy with radioisotope-labelled somatostatin analogues should be considered as the first-line treatment [98]. Qualification and treatment should follow the principles described in "Diagnostic and therapeutic guidelines for gastro-entero-pancreatic neuroendocrine neoplasms" (p. 79–110).
- In patients with negative receptor scintigraphy and evidence of ¹³¹I-MIBG accumulation in the tumour or metastases, therapy with ¹³¹I-MIBG may be considered [99].

4.3.3. Targeted therapies — everolimus

Everolimus therapy is effective in patients with hormonally non-active, well-differentiated gastro-entero-pancreatic NETs, including small intestinal NETs, in the generalised period [100]. Everolimus may be considered in patients with generalised progressing NETs of the small intestine following ineffective SSA treatment, and when other treatment methods (including PRRT) are ineffective or cannot be applied. In Poland everolimus therapy for this indication is non-refundable.

4.3.4. Chemotherapy

Due to limited effectiveness, chemotherapy is not recommended as the first-line treatment in patients with well-differentiated, metastatic neuroendocrine tumours of the small intestine. It is used exclusively in advanced small intestinal NETs, when other treatment methods appear ineffective. CAPTEM (temozolomide + capecitabine) may be considered, on the basis of small, prospective, phase II studies involving small groups of patients [101–103]. The principles of chemotherapy have been described in "Diagnostic and therapeutic guidelines for gastro-entero-pancreatic neuroendocrine neoplasms" (p. 79–110).

Goblet cell carcinoma (GCC)

Goblet cell carcinoids of the appendix constitute a specific form of neuroendocrine neoplasms of the appendix. These rare and aggressive neoplasms comprise both glandular and neuroendocrine components, and their course is aggressive [104, 105].

Adjuvant chemotherapy – qualification according to the same principles as in cancer of the large intestine: FOLFOX is recommended in stage III (pT3, pT4, N+),

although there are no reports from randomised studies, only scientific reports from individual centres [5, 106].

In the case of a diffused neoplasm, or recurrence after a radical treatment, due to a similar course of disease to glandular cancer of the large intestine, the same chemotherapy regimens are recommended (FOLFOX, FOLFIRI). Hyperthermic intraperitoneal chemoperfusion using mitomycin (HIPEC) and systemic chemotherapy, as well as surgical cytoreduction, may improve the prognosis in patients with diffused or recurrent GCC in the peritoneum [107, 108].

Minimal consensus statement on pharmacological and radioisotope treatment of NENs of the small intestine and the appendix

Long-acting SSA are the treatment of choice in case of hormonally active small intestinal NETs (carcinoid syndrome and carcinoid crisis) (evidence level 1) [109].

*In the case of small intestinal NETs in the generalised period (hormonally active and non-active), long-acting SSA should be used (antiproliferative effect) (*evidence level 1).*

*In patients with generalised NENs of the small intestine in progression during the SSA treatment, and with a good expression of somatostatin receptors, radioisotope therapy should be the first-line treatment (*evidence level 1), and targeted therapies should be considered afterwards — everolimus (*evidence level 1). In patients with a low expression of somatostatin receptors, targeted therapy is indicated.*

*When the above therapies are exhausted, in certain cases chemotherapy may be considered (*evidence level 4).*

5. Monitoring

Determination of CgA and 5-HIAA may be useful for the assessment of treatment and its effectiveness in patients with carcinoid symptoms. In patients treated with SSA, lower excretion of 5-HIAA and decreased levels of chromogranin A are associated with reduced intensity and frequency of clinical symptoms (flushing, diarrhoea). However, it is believed that 5-HIAA excretion does not reflect the progression or the response to treatment as precisely as the monitoring of CgA concentration. A high association (80%) between changes in the tumour size and concentration of chromogranin A has been observed. An even higher association (88%) was found in a group of patients with non-secreting tumours, in whom other markers could not be used [2, 3, 34]. However, in certain patients a very good clinical response to the treatment of carcinoid syndrome with SSA was observed, without reduced CgA levels [3].

The frequency of follow-up examinations depends on NEN differentiation and staging, as well as on the introduced treatment (*see* p. 79–110). The physical

*evidence level according to OCEBM [109]

examination and additional tests (three-phase CT scanning of the abdominal cavity and radioisotope imaging of somatostatin receptors SRI), as well as biochemical indicators (CgA and 5-HIAA), should be monitored. After a radical surgery: in patients with NET G1 and G2 every 6–12 months. In the case of a residual tumour or metastases: in patients with NET G1-G2, every 3–6 months. In G3, NEC: every 2–3 months [110].

In patients with carcinoid heart disease, echocardiographic examination and NT-proBNP assessment should be repeated at least every 12 months. If the disease progresses, follow-up imaging and biochemical tests need to be conducted more frequently — every three months [38, 110].

Minimal consensus statement on follow-up:

Monitoring of the disease and treatment should be planned individually for each patient, considering the clinical picture, grading, and staging of the disease, and its treatment.

In well-differentiated aNETs with a maximum tumour size < 1 cm and resection status (R0), further follow-up is not required. Patients with NET-G1 should be assessed every 6–12 months, with NET-G2, every 3–6 months, and with NEN-G3, every 3 months.

minimal examination includes: CgA, 5-HIAA (in certain cases) and triphasic CT, as well as radioisotopes somatostatin receptor imaging (SRI);

echocardiographic examination and NT-proBNP every 6–12 months in patients with carcinoid heart disease.

References

- Kaltsas GA, Besser GM, Grossman AB. The diagnosis and medical management of advanced neuroendocrine tumors. *Endocr Rev.* 2004; 25(3): 458–511, doi: [10.1210/er.2003-0014](https://doi.org/10.1210/er.2003-0014), indexed in Pubmed: [15180952](https://pubmed.ncbi.nlm.nih.gov/15180952/).
- Plöckinger U, Rindi G, Arnold R, et al. Guidelines for the diagnosis and treatment of neuroendocrine gastrointestinal tumours. *Neuroendocrinology.* 2004; 80: 394–424.
- Bolanowski M, Bednarczuk T, Bobek-Billewicz B, et al. Consensus Conference, Polish Network of Neuroendocrine Tumours. Neuroendocrine neoplasms of the small intestine and the appendix - management guidelines (recommended by the Polish Network of Neuroendocrine Tumours). *Endokrynol Pol.* 2013; 64(6): 480–493, doi: [10.5603/EP.2013.0029](https://doi.org/10.5603/EP.2013.0029), indexed in Pubmed: [24431119](https://pubmed.ncbi.nlm.nih.gov/24431119/).
- Niederle B, Pape UF, Costa F, et al. Vienna Consensus Conference participants. ENETS Consensus Guidelines Update for Neuroendocrine Neoplasms of the Jejunum and Ileum. *Neuroendocrinology.* 2016; 103(2): 125–138, doi: [10.1159/000443170](https://doi.org/10.1159/000443170), indexed in Pubmed: [26758972](https://pubmed.ncbi.nlm.nih.gov/26758972/).
- Pape UF, Perren A, Niederle B, et al. Barcelona Consensus Conference participants. ENETS Consensus Guidelines for the management of patients with neuroendocrine neoplasms from the jejuno-ileum and the appendix including goblet cell carcinomas. *Neuroendocrinology.* 2012; 95(2): 135–156, doi: [10.1159/000335629](https://doi.org/10.1159/000335629), indexed in Pubmed: [22262080](https://pubmed.ncbi.nlm.nih.gov/22262080/).
- Ellis L, Shale MJ, Coleman MP. Carcinoid tumors of the gastrointestinal tract: trends in incidence in England since 1971. *Am J Gastroenterol.* 2010; 105(12): 2563–2569, doi: [10.1038/ajg.2010.341](https://doi.org/10.1038/ajg.2010.341), indexed in Pubmed: [20823835](https://pubmed.ncbi.nlm.nih.gov/20823835/).
- Yao JC, Hassan M, Phan A, et al. One hundred years after. *J Clin Oncol.* 2008; 26(18): 3063–3072, doi: [10.1200/JCO.2007.15.4377](https://doi.org/10.1200/JCO.2007.15.4377), indexed in Pubmed: [18565894](https://pubmed.ncbi.nlm.nih.gov/18565894/).
- Ito T, Sasano H, Tanaka M, et al. Epidemiological study of gastroenteropancreatic neuroendocrine tumors in Japan. *J Gastroenterol.* 2010; 45(2): 234–243, doi: [10.1007/s00535-009-0194-8](https://doi.org/10.1007/s00535-009-0194-8), indexed in Pubmed: [20058030](https://pubmed.ncbi.nlm.nih.gov/20058030/).
- Hauso O, Gustafsson BI, Kidd M, et al. Neuroendocrine tumor epidemiology: contrasting Norway and North America. *Cancer.* 2008; 113(10): 2655–2664, doi: [10.1002/cncr.23883](https://doi.org/10.1002/cncr.23883), indexed in Pubmed: [18853416](https://pubmed.ncbi.nlm.nih.gov/18853416/).
- Landerholm K, Falkmer S, Järhult J. Epidemiology of small bowel carcinoids in a defined population. *World J Surg.* 2010; 34(7): 1500–1505, doi: [10.1007/s00268-010-0519-z](https://doi.org/10.1007/s00268-010-0519-z), indexed in Pubmed: [20237925](https://pubmed.ncbi.nlm.nih.gov/20237925/).
- Niederle MB, Hackl M, Kaserer K, et al. Gastroenteropancreatic neuroendocrine tumours: the current incidence and staging based on the WHO and European Neuroendocrine Tumour Society classification: an analysis based on prospectively collected parameters. *Endocr Relat Cancer.* 2010; 17(4): 909–918, doi: [10.1677/ERC-10-0152](https://doi.org/10.1677/ERC-10-0152), indexed in Pubmed: [20702725](https://pubmed.ncbi.nlm.nih.gov/20702725/).
- Berge T, Linell F. Carcinoid tumours. Frequency in a defined population during a 12-year period. *Acta Pathol Microbiol Scand A.* 1976; 84(4): 322–330, indexed in Pubmed: [961424](https://pubmed.ncbi.nlm.nih.gov/961424/).
- Boxberger N, Redlich A, Böger C, et al. Neuroendocrine tumors of the appendix in children and adolescents. *Pediatr Blood Cancer.* 2013; 60(1): 65–70, doi: [10.1002/pbc.24267](https://doi.org/10.1002/pbc.24267), indexed in Pubmed: [22887869](https://pubmed.ncbi.nlm.nih.gov/22887869/).
- Wu H, Chintagumpala M, Hicks J, et al. Neuroendocrine Tumor of the Appendix in Children. *J Pediatr Hematol Oncol.* 2017; 39(2): 97–102, doi: [10.1097/MPH.0000000000000598](https://doi.org/10.1097/MPH.0000000000000598), indexed in Pubmed: [27306228](https://pubmed.ncbi.nlm.nih.gov/27306228/).
- Oberdorfer S. Karzinoide Tumoren des Dunndarms. *Frankf Z Pathol.* 1907; 1: 426–429.
- Klimstra DS, Modlin IR, Adsay NV, et al. Pathology reporting of neuroendocrine tumors: application of the Delphic consensus process to the development of a minimum pathology data set. *Am J Surg Pathol.* 2010; 34(3): 300–313, doi: [10.1097/PAS.0b013e3181ce1447](https://doi.org/10.1097/PAS.0b013e3181ce1447), indexed in Pubmed: [20118772](https://pubmed.ncbi.nlm.nih.gov/20118772/).
- Lawrence B, Gustafsson BI, Chan A, et al. The epidemiology of gastroenteropancreatic neuroendocrine tumors. *Endocrinol Metab Clin North Am.* 2011; 40(1): 1–18, vii, doi: [10.1016/j.ecl.2010.12.005](https://doi.org/10.1016/j.ecl.2010.12.005), indexed in Pubmed: [21349409](https://pubmed.ncbi.nlm.nih.gov/21349409/).
- Fraenkel M, Kim M, Faggiano A, et al. Knowledge Network. Incidence of gastroenteropancreatic neuroendocrine tumors: a systematic review of the literature. *Endocr Relat Cancer.* 2014; 21(3): R153–R163, doi: [10.1530/ERC-13-0125](https://doi.org/10.1530/ERC-13-0125), indexed in Pubmed: [24322304](https://pubmed.ncbi.nlm.nih.gov/24322304/).
- Ten Cate EM, Wong LA, Groff WL, et al. Post-surgical surveillance of locally advanced ileal carcinoids found by routine ileal intubation during screening colonoscopy: a case series. *J Med Case Rep.* 2014; 8: 444, doi: [10.1186/1752-1947-8-444](https://doi.org/10.1186/1752-1947-8-444), indexed in Pubmed: [25524370](https://pubmed.ncbi.nlm.nih.gov/25524370/).
- Yarze JC, Herlihy KJ, Coombes JM, et al. Detection of asymptomatic ileal carcinoid tumors during ileal intubation at screening colonoscopy: a case series. *Am J Gastroenterol.* 2009; 104(12): 3114–3115, doi: [10.1038/ajg.2009.472](https://doi.org/10.1038/ajg.2009.472), indexed in Pubmed: [19956144](https://pubmed.ncbi.nlm.nih.gov/19956144/).
- Jann H, Roll S, Couvelard A, et al. Neuroendocrine tumors of midgut and hindgut origin: tumor-node-metastasis classification determines clinical outcome. *Cancer.* 2011; 117(15): 3332–3341, doi: [10.1002/cncr.25855](https://doi.org/10.1002/cncr.25855), indexed in Pubmed: [21246527](https://pubmed.ncbi.nlm.nih.gov/21246527/).
- Bordeaux JP, Klimstra DS, Hassan MM, et al. The NANETS consensus guideline for the diagnosis and management of neuroendocrine tumors: well-differentiated neuroendocrine tumors of the jejunum, ileum, appendix, and caecum. *Pancreas.* 2010; 39: 753–766.
- Ramage JK, Ahmed A, Ardill J, et al. UK and Ireland Neuroendocrine Tumour Society. Guidelines for the management of gastroenteropancreatic neuroendocrine (including carcinoid) tumours (NETs). *Gut.* 2012; 61(1): 6–32, doi: [10.1136/gutjnl-2011-300831](https://doi.org/10.1136/gutjnl-2011-300831), indexed in Pubmed: [22052063](https://pubmed.ncbi.nlm.nih.gov/22052063/).
- Kaczmarek-Lurek D, Pryc M, Kuś A, et al. Pitfalls in the diagnosis of carcinoid syndrome. *Fam Med Prim Care Rev.* 2016; 18: 109–113.
- Pearman TP, Beaumont JL, Cella D, et al. Health-related quality of life in patients with neuroendocrine tumors: an investigation of treatment type, disease status, and symptom burden. *Support Care Cancer.* 2016; 24(9): 3695–3703, doi: [10.1007/s00520-016-3189-z](https://doi.org/10.1007/s00520-016-3189-z), indexed in Pubmed: [27029477](https://pubmed.ncbi.nlm.nih.gov/27029477/).
- Hannah-Shmouni F, Stratakis CA, Koch CA. Flushing in (neuro)endocrinology. *Rev Endocr Metab Disord.* 2016; 17(3): 373–380, doi: [10.1007/s11154-016-9394-8](https://doi.org/10.1007/s11154-016-9394-8), indexed in Pubmed: [27873108](https://pubmed.ncbi.nlm.nih.gov/27873108/).
- Luis SA, Pellikka PA. Carcinoid heart disease: Diagnosis and management. *Best Pract Res Clin Endocrinol Metab.* 2016; 30(1): 149–158, doi: [10.1016/j.beem.2015.09.005](https://doi.org/10.1016/j.beem.2015.09.005), indexed in Pubmed: [26971851](https://pubmed.ncbi.nlm.nih.gov/26971851/).
- Silaschi M, Barr J, Chaubey S, et al. Optimized Outcomes Using a Standardized Approach for Treatment of Patients with Carcinoid Heart Disease. *Neuroendocrinology.* [in press]
- Łępska L, Pisiak S, Dudziak M. A case of carcinoid pericardial metastases and massive effusion. *Kardiol Pol.* 2013; 71(8): 881, doi: [10.5603/KP.2013.0208](https://doi.org/10.5603/KP.2013.0208), indexed in Pubmed: [24049036](https://pubmed.ncbi.nlm.nih.gov/24049036/).
- Bednarczuk T, Dębski M, Chojnowski K, et al. Carcinoid crisis. *Med Prakt.* 2009; 2: 164–169.
- Liu EH, Solorzano CC, Katznelson L, et al. AACE Endocrine Surgery Scientific Committee, AACE Endocrine Surgery Scientific Committee-Neuroendocrine Carcinoid Subgroup. AACE/ACE disease state clinical review: diagnosis and management of midgut carcinoids. *Endocr Pract.* 2015; 21(5): 534–545, doi: [10.4158/EP14464.DSC](https://doi.org/10.4158/EP14464.DSC), indexed in Pubmed: [25962092](https://pubmed.ncbi.nlm.nih.gov/25962092/).
- Pape UF, Niederle B, Costa F, et al. Vienna Consensus Conference participants. ENETS Consensus Guidelines for Neuroendocrine Neoplasms of the Appendix (Excluding Goblet Cell Carcinomas). *Neuroendocrinology.* 2016; 103(2): 144–152, doi: [10.1159/000443165](https://doi.org/10.1159/000443165), indexed in Pubmed: [26730583](https://pubmed.ncbi.nlm.nih.gov/26730583/).

33. Mullen JT, Savarese DMF. Carcinoid tumors of the appendix: a population-based study. *J Surg Oncol*. 2011; 104(1): 41–44, doi: [10.1002/jso.21888](https://doi.org/10.1002/jso.21888), indexed in Pubmed: [21294132](https://pubmed.ncbi.nlm.nih.gov/21294132/).
34. Kanakis G, Kaltsas G. Biochemical markers for gastroenteropancreatic neuroendocrine tumours (GEP-NETs). *Best Pract Res Clin Gastroenterol*. 2012; 26: 791–802.
35. Bolanowski M, Kos-Kudła B, Rzeszutko M, et al. [Five year remission of GHRH secreting bronchial neuroendocrine tumor with symptoms of acromegaly. Utility of chromogranin A in the monitoring of the disease]. *Endokrynol Pol*. 2006; 57(1): 32–36, indexed in Pubmed: [16575760](https://pubmed.ncbi.nlm.nih.gov/16575760/).
36. Tian T, Gao J, Li N, et al. Circulating Chromogranin A as A Marker for Monitoring Clinical Re-sponse in Advanced Gastroenteropancreatic Neuroendocrine Tumors. *PLoS One*. 2016; 11: e0154679.
37. Zandee WT, Kamp K, van Adrichem RCS, et al. Limited value for urinary 5-HIAA excretion as prognostic marker in gastrointestinal neuroendocrine tumours. *Eur J Endocrinol*. 2016; 175(5): 361–366, doi: [10.1530/EJE-16-0392](https://doi.org/10.1530/EJE-16-0392), indexed in Pubmed: [27491374](https://pubmed.ncbi.nlm.nih.gov/27491374/).
38. Dobson R, Burgess MI, Banks M, et al. The association of a panel of biomarkers with the presence and severity of carcinoid heart disease: a cross-sectional study. *PLoS One*. 2013; 8(9): e73679, doi: [10.1371/journal.pone.0073679](https://doi.org/10.1371/journal.pone.0073679), indexed in Pubmed: [24069222](https://pubmed.ncbi.nlm.nih.gov/24069222/).
39. Cwikła JB, Bodei L, Kolasinska-Cwikła A, et al. Circulating Transcript Analysis (NETest) in GEP-NETs Treated With Somatostatin Analogs Defines Therapy. *J Clin Endocrinol Metab*. 2015; 100(11): E1437–E1445, doi: [10.1210/jc.2015-2792](https://doi.org/10.1210/jc.2015-2792), indexed in Pubmed: [26348352](https://pubmed.ncbi.nlm.nih.gov/26348352/).
40. Miller HC, Frampton AE, Malczewska A, et al. MicroRNAs associated with small bowel neuroendocrine tumours and their metastases. *Endocr Relat Cancer*. 2016; 23(9): 711–726, doi: [10.1530/ERC-16-0044](https://doi.org/10.1530/ERC-16-0044), indexed in Pubmed: [27353039](https://pubmed.ncbi.nlm.nih.gov/27353039/).
41. Soyer P, Aout M, Hoeffel C, et al. Helical CT-enteroclysis in the detection of small-bowel tumours: a meta-analysis. *Eur Radiol*. 2013; 23(2): 388–399, doi: [10.1007/s00330-012-2595-y](https://doi.org/10.1007/s00330-012-2595-y), indexed in Pubmed: [22865269](https://pubmed.ncbi.nlm.nih.gov/22865269/).
42. Bonekamp D, Raman SP, Horton KM, et al. Role of computed tomography angiography in detection and staging of small bowel carcinoid tumors. *World J Radiol*. 2015; 7(9): 220–235, doi: [10.4329/wjrv.7.9.220](https://doi.org/10.4329/wjrv.7.9.220), indexed in Pubmed: [26435774](https://pubmed.ncbi.nlm.nih.gov/26435774/).
43. Ganeshan D, Bhosale P, Yang T, et al. Imaging features of carcinoid tumors of the gastrointestinal tract. *AJR Am J Roentgenol*. 2013; 201(4): 773–786, doi: [10.2214/AJR.12.9758](https://doi.org/10.2214/AJR.12.9758), indexed in Pubmed: [24059366](https://pubmed.ncbi.nlm.nih.gov/24059366/).
44. Faggian A, Fracella MR, D'Alesio G, et al. Small-Bowel Neoplasms: Role of MRI Enteroclysis. *Gastroenterol Res Pract*. 2016; 2016: 9686815, doi: [10.1155/2016/9686815](https://doi.org/10.1155/2016/9686815), indexed in Pubmed: [26819616](https://pubmed.ncbi.nlm.nih.gov/26819616/).
45. Casciani E, Poletтини E, Laghi F, et al. Magnetic resonance imaging of small bowel neoplasms. *Cancer Imaging*. 2013; 13(1): 92–99.
46. Smereczyński A, Starzyńska T, Kołaczek K. Mesenteric changes in an ultrasound examination can facilitate the diagnosis of neuroendocrine tumors of the small intestine. *J Ultrason*. 2015; 15(62): 274–282, doi: [10.15557/JoU.2015.0024](https://doi.org/10.15557/JoU.2015.0024), indexed in Pubmed: [26673610](https://pubmed.ncbi.nlm.nih.gov/26673610/).
47. Leszczyński S, Pilch-Kowalczyk J, eds. Imaging diagnostics. Digestive system. : PZWL.
48. Iacopini F, Saito Y, Gotoda T, et al. Endoscopic submucosal dissection of a nonpolypoid superficial neoplasm of the terminal ileum. *Endoscopy*. 2016; 48 Suppl 1 UCTN: E57–E58, doi: [10.1055/s-0042-101760](https://doi.org/10.1055/s-0042-101760), indexed in Pubmed: [26890542](https://pubmed.ncbi.nlm.nih.gov/26890542/).
49. van Tuyl SAC, van Noordden JT, Timmer R, et al. Detection of small-bowel neuroendocrine tumors by video capsule endoscopy. *Gastrointest Endosc*. 2006; 64(1): 66–72, doi: [10.1016/j.gie.2006.01.054](https://doi.org/10.1016/j.gie.2006.01.054), indexed in Pubmed: [16813805](https://pubmed.ncbi.nlm.nih.gov/16813805/).
50. Bailey AA, Debinski HS, Appleyard MN, et al. Diagnosis and outcome of small bowel tumors found by capsule endoscopy: a three-center Australian experience. *Am J Gastroenterol*. 2006; 101(10): 2237–2243, doi: [10.1111/j.1572-0241.2006.00749.x](https://doi.org/10.1111/j.1572-0241.2006.00749.x), indexed in Pubmed: [17032187](https://pubmed.ncbi.nlm.nih.gov/17032187/).
51. Bellutti M, Fry LC, Schmitt J, et al. Detection of neuroendocrine tumors of the small bowel by double balloon enteroscopy. *Dig Dis Sci*. 2009; 54(5): 1050–1058, doi: [10.1007/s10620-008-0456-y](https://doi.org/10.1007/s10620-008-0456-y), indexed in Pubmed: [18770038](https://pubmed.ncbi.nlm.nih.gov/18770038/).
52. Ricke J, Klose KJ, Mignon M, et al. Standardisation of imaging in neuroendocrine tumours: results of a European delphi process. *Eur J Radiol*. 2001; 37(1): 8–17, indexed in Pubmed: [11274833](https://pubmed.ncbi.nlm.nih.gov/11274833/).
53. Hakim FA, Alexander JA, Huprich JE, et al. CT-enterography may identify small bowel tumors not detected by capsule endoscopy: eight years experience at Mayo Clinic Rochester. *Dig Dis Sci*. 2011; 56(10): 2914–2919, doi: [10.1007/s10620-011-1773-0](https://doi.org/10.1007/s10620-011-1773-0), indexed in Pubmed: [21735085](https://pubmed.ncbi.nlm.nih.gov/21735085/).
54. Frilling A, Smith G, Clift AK, et al. Capsule endoscopy to detect primary tumour site in metastatic neuroendocrine tumours. *Dig Liver Dis*. 2014; 46(11): 1038–1042, doi: [10.1016/j.dld.2014.07.004](https://doi.org/10.1016/j.dld.2014.07.004), indexed in Pubmed: [25086997](https://pubmed.ncbi.nlm.nih.gov/25086997/).
55. Strosberg JR, Shibata D, Kvols LK. Intermittent bowel obstruction due to a retained wireless capsule endoscope in a patient with a small bowel carcinoid tumour. *Can J Gastroenterol*. 2007; 21(2): 113–115, indexed in Pubmed: [17299616](https://pubmed.ncbi.nlm.nih.gov/17299616/).
56. Johanssen S, Boivin M, Lochs H, et al. The yield of wireless capsule endoscopy in the detection of neuroendocrine tumors in comparison with CT enteroclysis. *Gastrointest Endosc*. 2006; 63(4): 660–665, doi: [10.1016/j.gie.2005.11.055](https://doi.org/10.1016/j.gie.2005.11.055), indexed in Pubmed: [16564869](https://pubmed.ncbi.nlm.nih.gov/16564869/).
57. Rondonotti E, Pennazio M, Toth E, et al. European Capsule Endoscopy Group, Italian Club for Capsule Endoscopy (CICE), Iberian Group for Capsule Endoscopy. Small-bowel neoplasms in patients undergoing video capsule endoscopy: a multicenter European study. *Endoscopy*. 2008; 40(6): 488–495, doi: [10.1055/s-2007-995783](https://doi.org/10.1055/s-2007-995783), indexed in Pubmed: [18464193](https://pubmed.ncbi.nlm.nih.gov/18464193/).
58. Yamamoto H, Kita H, Sunada K, et al. Clinical outcomes of double-balloon endoscopy for the diagnosis and treatment of small-intestinal disease. *Clin Gastroenterol Hepatol*. 2004; 2: 1010–1016.
59. Pasha SE, Leighton JA, Das A, et al. Double-balloon enteroscopy and capsule endoscopy have comparable diagnostic yield in small-bowel disease: a meta-analysis. *Clin Gastroenterol Hepatol*. 2008; 6(6): 671–676, doi: [10.1016/j.cgh.2008.01.005](https://doi.org/10.1016/j.cgh.2008.01.005), indexed in Pubmed: [18356113](https://pubmed.ncbi.nlm.nih.gov/18356113/).
60. Chen J, Zhang L, Zhang W, et al. A Case of Neuroendocrine Malignant Tumor with Capsule Retention Diagnosed by Double-Balloon Enteroscopy. *Case Rep Gastroenterol*. 2010; 4(1): 52–56, doi: [10.1159/000264644](https://doi.org/10.1159/000264644), indexed in Pubmed: [21103228](https://pubmed.ncbi.nlm.nih.gov/21103228/).
61. Ethun CG, Postlewait LM, Baptiste GG, et al. Small bowel neuroendocrine tumors: A critical analysis of diagnostic work-up and operative approach. *J Surg Oncol*. 2016; 114(6): 671–676, doi: [10.1002/jso.24390](https://doi.org/10.1002/jso.24390), indexed in Pubmed: [27511436](https://pubmed.ncbi.nlm.nih.gov/27511436/).
62. Sulbaran M, de Moura E, Bernardo W, et al. Overtube-assisted enteroscopy and capsule endoscopy for the diagnosis of small-bowel polyps and tumors: a systematic review and meta-analysis. *Endosc Int Open*. 2016; 4(2): E151–E163, doi: [10.1055/s-0041-108261](https://doi.org/10.1055/s-0041-108261), indexed in Pubmed: [26878042](https://pubmed.ncbi.nlm.nih.gov/26878042/).
63. Elena RM, Riccardo U, Rossella C, et al. Current status of device-assisted enteroscopy: Technical matters, indication, limits and complications. *World J Gastrointest Endosc*. 2012; 4(10): 453–461, doi: [10.4253/wjge.v4.i10.453](https://doi.org/10.4253/wjge.v4.i10.453), indexed in Pubmed: [23189216](https://pubmed.ncbi.nlm.nih.gov/23189216/).
64. Krenning EP, Kwekkeboom DJ, Oei HY, et al. Somatostatin-receptor scintigraphy in gastroenteropancreatic tumors. An overview of European results. *Ann N Y Acad Sci*. 1994; 733: 416–424, indexed in Pubmed: [7978890](https://pubmed.ncbi.nlm.nih.gov/7978890/).
65. Krenning EP, Kwekkeboom DJ, Bakker WH, et al. Somatostatin receptor scintigraphy with [111In-DTPA-D-Phe1]- and [123I-Tyr3]-octreotide: the Rotterdam experience with more than 1000 patients. *Eur J Nucl Med*. 1993; 20(8): 716–731, indexed in Pubmed: [8404961](https://pubmed.ncbi.nlm.nih.gov/8404961/).
66. Schreiter NF, Bartels AM, Froeling V, et al. Searching for primaries in patients with neuroendocrine tumors (NET) of unknown primary and clinically suspected NET: Evaluation of Ga-68 DOTATOC PET/CT and In-111 DTPA octreotide SPECT/CT. *Radiol Oncol*. 2014; 48(4): 339–347, doi: [10.2478/raon-2014-0018](https://doi.org/10.2478/raon-2014-0018), indexed in Pubmed: [25435846](https://pubmed.ncbi.nlm.nih.gov/25435846/).
67. Virgone C, Cecchetto G, Besutti V, et al. Appendiceal neuroendocrine tumours in childhood: Italian TREP project. *J Pediatr Gastroenterol Nutr*. 2014; 58(3): 333–338, doi: [10.1097/MPG.0000000000000217](https://doi.org/10.1097/MPG.0000000000000217), indexed in Pubmed: [24145622](https://pubmed.ncbi.nlm.nih.gov/24145622/).
68. Karpińska K, Nasierowska-Guttmejer A. Standardy Oceny Makroskopowej Materiału Biopsyjnego i Operacyjnego U Chorych na Nowotwory Złośliwe. *Polish Journal of Pathology*. 2015; 66(supplement 1): 11–13.
69. WHO Classification of Tumours of the Digestive System. IARC: 2017 (in press)
70. Garcia-Carbonero R, Sorbye H, Baudin E, et al. ENETS Consensus Guidelines for High-Grade Gastroenteropancreatic Neuroendocrine Carcinoma. *Neuroendocrinology*. 2016; 103: 186–194.
71. Woltering EA, Bergsland EK, Beyer DT, et al. Neuroendocrine Tumors of the Appendix. American Joint Committee on Cancer 2017. In: Amin M. B. (eds) *AJCC Cancer Staging Manual*. Eight Edition Springer 2017; 389–394 DOI 10.1007/978-3-319-40618-3; 30, doi: [10.1007/978-3-319-40618-3_30](https://doi.org/10.1007/978-3-319-40618-3_30).
72. Brierley JD, Gospodarowicz MK, Wittekind C, et al. eds. UICC TNM Classification of Malignant Tumours. Eight Edition. Wiley Blackwell. 2016; 201: 99–101.
73. Bertani E, Falconi M, Grana C, et al. Small intestinal neuroendocrine tumors with liver metastases and resection of the primary: Prognostic factors for decision making. *Int J Surg*. 2015; 20: 58–64, doi: [10.1016/j.ijsu.2015.06.019](https://doi.org/10.1016/j.ijsu.2015.06.019), indexed in Pubmed: [26074290](https://pubmed.ncbi.nlm.nih.gov/26074290/).
74. Maxwell JE, Sherman SK, O'Dorisio TM, et al. Liver-directed surgery of neuroendocrine metastases: What is the optimal strategy? *Surgery*. 2016; 159(1): 320–333, doi: [10.1016/j.surg.2015.05.040](https://doi.org/10.1016/j.surg.2015.05.040), indexed in Pubmed: [26454679](https://pubmed.ncbi.nlm.nih.gov/26454679/).
75. Alexandraki KI, Kaltsas GA, Grozinsky-Glasberg S, et al. Appendiceal neuroendocrine neoplasms: diagnosis and management. *Endocr Relat Cancer*. 2016; 23(1): R27–R41, doi: [10.1530/ERC-15-0310](https://doi.org/10.1530/ERC-15-0310), indexed in Pubmed: [26483424](https://pubmed.ncbi.nlm.nih.gov/26483424/).
76. Jiang Y, Long Hu, Wang W, et al. Clinicopathological features and immunexpression profiles of goblet cell carcinoid and typical carcinoid of the appendix. *Pathol Oncol Res*. 2011; 17(1): 127–132, doi: [10.1007/s12253-010-9291-5](https://doi.org/10.1007/s12253-010-9291-5), indexed in Pubmed: [20640606](https://pubmed.ncbi.nlm.nih.gov/20640606/).
77. Chetty R, Klimstra DS, Henson DE, et al. Combined classical carcinoid and goblet cell carcinoid tumor: a new morphologic variant of carcinoid tumor of the appendix. *Am J Surg Pathol*. 2010; 34(8): 1163–1167, doi: [10.1097/PAS.0b013e3181e52916](https://doi.org/10.1097/PAS.0b013e3181e52916), indexed in Pubmed: [20631606](https://pubmed.ncbi.nlm.nih.gov/20631606/).

78. Groth SS, Virnig BA, Al-Refaie WB, et al. Appendiceal carcinoid tumors: Predictors of lymph node metastasis and the impact of right hemicolectomy on survival. *J Surg Oncol*. 2011; 103(1): 39–45, doi: [10.1002/jso.21764](https://doi.org/10.1002/jso.21764), indexed in Pubmed: [21031414](https://pubmed.ncbi.nlm.nih.gov/21031414/).
79. Alexandraki KI, Griniatsos J, Bramis KI, et al. Clinical value of right hemicolectomy for appendiceal carcinoids using pathologic criteria. *J Endocrinol Invest*. 2011; 34(4): 255–259, doi: [10.1007/BF03347081](https://doi.org/10.1007/BF03347081), indexed in Pubmed: [20935447](https://pubmed.ncbi.nlm.nih.gov/20935447/).
80. Bamboat ZM, Berger DL. Is right hemicolectomy for 2.0-cm appendiceal carcinoids justified? *Arch Surg*. 2006; 141(4): 349–52; discussion 352, doi: [10.1001/archsurg.141.4.349](https://doi.org/10.1001/archsurg.141.4.349), indexed in Pubmed: [16618891](https://pubmed.ncbi.nlm.nih.gov/16618891/).
81. Mullen JT, Savarese DMF. Carcinoid tumors of the appendix: a population-based study. *J Surg Oncol*. 2011; 104(1): 41–44, doi: [10.1002/jso.21888](https://doi.org/10.1002/jso.21888), indexed in Pubmed: [21294132](https://pubmed.ncbi.nlm.nih.gov/21294132/).
82. Grozinsky-Glasberg S, Alexandraki KI, Barak D, et al. Current size criteria for the management of neuroendocrine tumors of the appendix: are they valid? Clinical experience and review of the literature. *Neuroendocrinology*. 2013; 98(1): 31–37, doi: [10.1159/000343801](https://doi.org/10.1159/000343801), indexed in Pubmed: [23051855](https://pubmed.ncbi.nlm.nih.gov/23051855/).
83. In't Hof KH, van der Wal HC, Kazemier G, et al. Carcinoid tumour of the appendix: an analysis of 1,485 consecutive emergency appendectomies. *J Gastrointest Surg*. 2008; 12(8): 1436–1438, doi: [10.1007/s11605-008-0545-4](https://doi.org/10.1007/s11605-008-0545-4), indexed in Pubmed: [18521695](https://pubmed.ncbi.nlm.nih.gov/18521695/).
84. Hsu C, Rashid A, Xing Y, et al. Varying malignant potential of appendiceal neuroendocrine tumors: importance of histologic subtype. *J Surg Oncol*. 2013; 107(2): 136–143, doi: [10.1002/jso.23205](https://doi.org/10.1002/jso.23205), indexed in Pubmed: [22767417](https://pubmed.ncbi.nlm.nih.gov/22767417/).
85. Volante M, Daniele L, Asioli F, et al. Tumor staging but not grading is associated with adverse clinical outcome in neuroendocrine tumors of the appendix. *Am J Surg Pathol*. 2013; 37: 606–612.
86. Shapiro R, Eldar S, Sadot E, et al. Appendiceal carcinoid at a large tertiary center: pathologic findings and long-term follow-up evaluation. *Am J Surg*. 2011; 201(6): 805–808, doi: [10.1016/j.amjsurg.2010.04.016](https://doi.org/10.1016/j.amjsurg.2010.04.016), indexed in Pubmed: [21741512](https://pubmed.ncbi.nlm.nih.gov/21741512/).
87. Liu E, Telem DA, Hwang J, et al. The clinical utility of Ki-67 in assessing tumor biology and aggressiveness in patients with appendiceal carcinoids. *J Surg Oncol*. 2010; 102(4): 338–341, doi: [10.1002/jso.21634](https://doi.org/10.1002/jso.21634), indexed in Pubmed: [20607756](https://pubmed.ncbi.nlm.nih.gov/20607756/).
88. O'Toole D, Ducreux M, Bommelaer G, et al. Treatment of carcinoid syndrome: a prospective crossover evaluation of lanreotide versus octreotide in terms of efficacy, patient acceptability, and tolerance. *Cancer*. 2000; 88(4): 770–776, indexed in Pubmed: [10679645](https://pubmed.ncbi.nlm.nih.gov/10679645/).
89. Vinik AI, Wolin EM, Liyanage N, et al. ELECT Study Group*. Evaluation of lanreotide depot/autogel efficacy and safety as a carcinoid syndrome treatment (elect): a randomized, double-blind, placebo-controlled trial. *Endocr Pract*. 2016; 22(9): 1068–1080, doi: [10.4158/EP151172.OR](https://doi.org/10.4158/EP151172.OR), indexed in Pubmed: [27214300](https://pubmed.ncbi.nlm.nih.gov/27214300/).
90. Ruszniewski P, Valle JW, Lombard-Bohas C, et al. SYMNET study group. Patient-reported outcomes with lanreotide Autogel/Depot for carcinoid syndrome: An international observational study. *Dig Liver Dis*. 2016; 48(5): 552–558, doi: [10.1016/j.dld.2015.12.013](https://doi.org/10.1016/j.dld.2015.12.013), indexed in Pubmed: [26917486](https://pubmed.ncbi.nlm.nih.gov/26917486/).
91. Orlewska E, Bednarczuk T, Kaminski G, et al. LanroNET study group*. LanroNET, a non-interventional, prospective study to assess the resource utilization and cost of lanreotide autogel 120 mg in Polish patients with neuroendocrine tumors - results of interim analysis. *Contemp Oncol (Pozn)*. 2014; 18(6): 442–447, doi: [10.5114/wo.2014.47908](https://doi.org/10.5114/wo.2014.47908), indexed in Pubmed: [25784845](https://pubmed.ncbi.nlm.nih.gov/25784845/).
92. Wolin EM, Jarzab B, Eriksson B, et al. Phase III study of pasireotide long-acting release in patients with metastatic neuroendocrine tumors and carcinoid symptoms refractory to available somatostatin analogues. *Drug Des Devel Ther*. 2015; 9: 5075–5086, doi: [10.2147/DDDT.S84177](https://doi.org/10.2147/DDDT.S84177), indexed in Pubmed: [26366058](https://pubmed.ncbi.nlm.nih.gov/26366058/).
93. Pavel M, Hörsch D, Caplin M, et al. Telotristat etiprate for carcinoid syndrome: a single-arm, multicenter trial. *J Clin Endocrinol Metab*. 2015; 100(4): 1511–1519, doi: [10.1210/jc.2014-2247](https://doi.org/10.1210/jc.2014-2247), indexed in Pubmed: [25636046](https://pubmed.ncbi.nlm.nih.gov/25636046/).
94. Kulke MH, O'Doriso T, Phan A, et al. Telotristat etiprate, a novel serotonin synthesis inhibitor, in patients with carcinoid syndrome and diarrhea not adequately controlled by octreotide. *Endocr Relat Cancer*. 2014; 21(5): 705–714, doi: [10.1530/ERC-14-0173](https://doi.org/10.1530/ERC-14-0173), indexed in Pubmed: [25012985](https://pubmed.ncbi.nlm.nih.gov/25012985/).
95. Massimino K, Harrskog O, Pommier S, et al. Octreotide LAR and bolus octreotide are insufficient for preventing intraoperative complications in carcinoid patients. *J Surg Oncol*. 2013; 107(8): 842–846, doi: [10.1002/jso.23323](https://doi.org/10.1002/jso.23323), indexed in Pubmed: [23592524](https://pubmed.ncbi.nlm.nih.gov/23592524/).
96. Rinke A, Wittenberg M, Schade-Brittinger C, et al. PROMID Study Group. Placebo-Controlled, Double-Blind, Prospective, Randomized Study on the Effect of Octreotide LAR in the Control of Tumor Growth in Patients with Metastatic Neuroendocrine Midgut Tumors (PROMID): Results of Long-Term Survival. *Neuroendocrinology*. 2017; 104(1): 26–32, doi: [10.1159/000443612](https://doi.org/10.1159/000443612), indexed in Pubmed: [26731483](https://pubmed.ncbi.nlm.nih.gov/26731483/).
97. Caplin ME, Pavel M, Ćwikła JB, et al. CLARINET Investigators. Anti-tumour effects of lanreotide for pancreatic and intestinal neuroendocrine tumours: the CLARINET open-label extension study. *Endocr Relat Cancer*. 2016; 23(3): 191–199, doi: [10.1530/ERC-15-0490](https://doi.org/10.1530/ERC-15-0490), indexed in Pubmed: [26743120](https://pubmed.ncbi.nlm.nih.gov/26743120/).
98. Strosberg J, El-Haddad G, Wolin E, et al. NETTER-1 Trial Investigators. Phase 3 Trial of (177)Lu-Dotatate for Midgut Neuroendocrine Tumors. *N Engl J Med*. 2017; 376(2): 125–135, doi: [10.1056/NEJMoa1607427](https://doi.org/10.1056/NEJMoa1607427), indexed in Pubmed: [28076709](https://pubmed.ncbi.nlm.nih.gov/28076709/).
99. Buscombe JR, Ćwikła JB, Caplin ME, et al. Long-term efficacy of low activity meta-[131I]iodobenzylguanidine therapy in patients with disseminated neuroendocrine tumours depends on initial response. *Nucl Med Commun*. 2005; 26(11): 969–976, indexed in Pubmed: [16208174](https://pubmed.ncbi.nlm.nih.gov/16208174/).
100. Yao JC, Fazio N, Singh S, et al. RAD001 in Advanced Neuroendocrine Tumours, Fourth Trial (RADIANT-4) Study Group. Everolimus for the treatment of advanced, non-functional neuroendocrine tumours of the lung or gastrointestinal tract (RADIANT-4): a randomised, placebo-controlled, phase 3 study. *Lancet*. 2016; 387(10022): 968–977, doi: [10.1016/S0140-6736\(15\)00817-X](https://doi.org/10.1016/S0140-6736(15)00817-X), indexed in Pubmed: [26703889](https://pubmed.ncbi.nlm.nih.gov/26703889/).
101. Fine RL, Gulati AP, Krantz BA, et al. Capecitabine and temozolomide (CAPTEM) for metastatic, well-differentiated neuroendocrine cancers: The Pancreas Center at Columbia University experience. *Cancer Chemother Pharmacol*. 2013; 71(3): 663–670, doi: [10.1007/s00280-012-2055-z](https://doi.org/10.1007/s00280-012-2055-z), indexed in Pubmed: [23370660](https://pubmed.ncbi.nlm.nih.gov/23370660/).
102. Berruti A, Fazio N, Ferrero A, et al. Bevacizumab plus octreotide and metronomic capecitabine in patients with metastatic well-to-moderately differentiated neuroendocrine tumors: the XELBEVOCT study. *BMC Cancer*. 2014; 14: 184, doi: [10.1186/1471-2407-14-184](https://doi.org/10.1186/1471-2407-14-184), indexed in Pubmed: [24628963](https://pubmed.ncbi.nlm.nih.gov/24628963/).
103. Koumariou A, Katsas G, Kulke MH, et al. Temozolomide in Advanced Neuroendocrine Neoplasms: Pharmacological and Clinical Aspects. *Neuroendocrinology*. 2015; 101(4): 274–288, doi: [10.1159/000430816](https://doi.org/10.1159/000430816), indexed in Pubmed: [25924937](https://pubmed.ncbi.nlm.nih.gov/25924937/).
104. McCusker ME, Coté TR, Clegg LX, et al. Primary malignant neoplasms of the appendix: a population-based study from the surveillance, epidemiology and end-results program, 1973–1998. *Cancer*. 2002; 94(12): 3307–3312, doi: [10.1002/cncr.10589](https://doi.org/10.1002/cncr.10589), indexed in Pubmed: [12115365](https://pubmed.ncbi.nlm.nih.gov/12115365/).
105. McGory ML, Maggard MA, Kang H, et al. Malignancies of the appendix: beyond case series reports. *Dis Colon Rectum*. 2005; 48(12): 2264–2271, doi: [10.1007/s10350-005-0196-4](https://doi.org/10.1007/s10350-005-0196-4), indexed in Pubmed: [16258711](https://pubmed.ncbi.nlm.nih.gov/16258711/).
106. Taggart MW, Abraham SC, Overman MJ, et al. Goblet cell carcinoid tumor, mixed goblet cell carcinoid-adenocarcinoma, and adenocarcinoma of the appendix: comparison of clinicopathologic features and prognosis. *Arch Pathol Lab Med*. 2015; 139(6): 782–790, doi: [10.5858/arpa.2013-0047-OA](https://doi.org/10.5858/arpa.2013-0047-OA), indexed in Pubmed: [26030247](https://pubmed.ncbi.nlm.nih.gov/26030247/).
107. Mahteme H, Sugarbaker PH. Treatment of peritoneal carcinomatosis from adenocarcinoid of appendiceal origin. *Br J Surg*. 2004; 91(9): 1168–1173, doi: [10.1002/bjs.4609](https://doi.org/10.1002/bjs.4609), indexed in Pubmed: [15449269](https://pubmed.ncbi.nlm.nih.gov/15449269/).
108. McConnell YJ, Mack LA, Gui X, et al. Cytoreductive surgery with hyperthermic intraperitoneal chemotherapy: an emerging treatment option for advanced goblet cell tumors of the appendix. *Ann Surg Oncol*. 2014; 21(6): 1975–1982, doi: [10.1245/s10434-013-3469-5](https://doi.org/10.1245/s10434-013-3469-5), indexed in Pubmed: [24398544](https://pubmed.ncbi.nlm.nih.gov/24398544/).
109. OCEBM Levels of Evidence Working Group*. “The Oxford 2011 Levels of Evidence”. Oxford Centre for Evidence-Based Medicine. <http://www.cebm.net/index.aspx?o=5653>
110. Knigge U, Capdevila J, Bartsch DK et al. ENETS Consensus recommendations for standards of care in neuroendocrine neoplasms: follow-up and documentation. *Neuroendocrinology* 2017: (in press)