



# Occurrence of pheochromocytoma tumours in RET mutation carriers — a single-centre study

Obraz kliniczny guzów chromochłonnych u nosicieli mutacji protoonkogenu RET — badanie jednośrodkowe

**Agnieszka Kotecka-Blicharz, Kornelia Hasse-Lazar, Beata Jurecka-Lubieniecka, Agnieszka Pawlaczek, Małgorzata Oczko-Wojciechowska, Beata Bugajska, Aleksandra Ledwon, Aleksandra Król, Barbara Michalik, Barbara Jarząb**

*Department of Nuclear Medicine and Endocrine Oncology, Maria Skłodowska-Curie Memorial Cancer Centre and Institute of Oncology, Gliwice Branch*

## Abstract

**Introduction:** Multiple endocrine neoplasia type 2 (MEN 2) is an autosomal dominant genetic syndrome caused by germline mutation in *RET* proto-oncogene. The most common mutations are in a cysteine rich domain. Pheochromocytoma will develop in approximately 50% of *RET* proto-oncogene carriers.

**Material and methods:** The studied population consisted of 228 *RET* proto-oncogene mutation carriers. Monitoring for the diagnosis of pheochromocytoma was carried out in all patients with established genetic status. Mean time of follow up was 138 months. Surveillance consisted of periodically performed clinical evaluation, 24-hour urinary determinations of total metanephrines complementary with imaging (CT, MR, MIBG scintigraphy).

**Results:** Pheochromocytoma developed in 41 patients (18% of all *RET* proto-oncogene mutations carriers). The mean age of diagnosis for the whole cohort was 43 years. In eight cases pheochromocytoma was the first manifestation of the MEN 2 syndrome. Only eight (20%) patients were symptomatic at diagnosis of pheochromocytoma. The mean size of the tumour was 4.3 cm. There was no extra-adrenal localisation. We observed one case of malignant pheochromocytoma.

**Conclusions:** In patients with MEN 2 syndrome pheochromocytomas are usually benign adrenal tumours with high risk of bilateral development. Taking to account the latter risk and non-specific clinical manifestation of the neoplasm it is mandatory to screen all *RET* proto-oncogene mutations carriers for pheochromocytoma. (*Endokrynol Pol* 2016; 67 (1): 54–58)

**Key words:** pheochromocytoma; MEN 2A; *RET* genetic testing

## Streszczenie

**Wstęp:** Zespół mnogich nowotworów gruczołów dokrewnych typu 2 (MEN 2) jest schorzeniem uwarunkowanym genetycznie, dziedziczonym w sposób autosomalny dominujący, spowodowanym mutacją germinálną protoonkogenu *RET*. W 80% przypadków mutacje zlokalizowane są w kodonie 634. Guz chromochłonny rozwinię się u 50% pacjentów z zidentyfikowaną mutacją w protoonkogenie *RET*.

**Materiał i metody:** 228 nosicieli mutacji w protoonkogenie *RET* poddano monitorowaniu w kierunku rozwoju guza chromochłonnego. Nadzór obejmował okresowo wykonywane ocenę stanu klinicznego, wydalania metoksykatecholamin w dobowej zbiórce moczu komplementarnie z diagnostyką obrazową (CT, MR, scyntygrafia MIBG).

**Wyniki:** Guz chromochłonny rozwinął się u 41 pacjentów (18% wszystkich pacjentów z ustaloną mutacją w protoonkogenie *RET*). Średni wiek rozpoznania wyniósł 43 lata. W 8 przypadkach guz chromochłonny był pierwszą kliniczną manifestacją MEN 2. Tylko u 8 pacjentów (20%) w chwili rozpoznania obserwowano objawy kliniczne typowe dla guza chromochłonnego. Średnia wielkość guza wynosiła 4,3 cm. Nie stwierdzono poza nadnerczowej lokalizacji. W obserwacji autorów potwierdzono tylko jeden przypadek złośliwego guza chromochłonnego.

**Wnioski:** Guzy wywodzące się z tkanki chromochłonnej rozwijające się w przebiegu zespołu MEN 2 mają zwykle nadnerczową lokalizację i łagodny charakter jednak z dużą częstością zmian obustronnych. Biorąc pod uwagę powyższe ryzyko, a także niespecyficzny obraz kliniczny istotnym jest monitorowanie wszystkich pacjentów z potwierdzoną mutacją w protoonkogenie *RET* w kierunku rozwoju guza chromochłonnego. (*Endokrynol Pol* 2016; 67 (1): 54–58)

**Słowa kluczowe:** guz chromochłonny; MEN 2; analiza protoonkogenu *RET*

*This research was supported by Polish National Science Centre grant no. NN401410639.*

## Introduction

Multiple endocrine neoplasia type 2 (MEN 2) is an autosomal dominant genetic syndrome, caused by germline mutation in *RET* proto-oncogene, which encodes

a tyrosine kinase receptor. The *RET* proto-oncogene is located on chromosome 10 and consists of 21 exons. *RET* receptor forms together with the co-receptor, which is glial cell-derived neurotrophic factor family receptor- $\alpha$ -1 (GFR $\alpha$ 1), the binary complex. The *RET*/GFR $\alpha$ 1 complex



Agnieszka Kotecka-Blicharz M.D., Department of Nuclear Medicine and Endocrine Oncology, Maria Skłodowska-Curie Memorial Cancer Centre and Institute of Oncology, Gliwice Branch, Wybrzeża Armii Krajowej 15, Gliwice, Poland, phone. 32 278 99 32, e-mail: agnbli@wp.pl

is activated by the ligand called glial cell-derived neurotrophic factor (GDNF) [1].

RET activation is required in the early embryos for the development of neural crest-derived cell types and the kidneys [2]. It also plays a role in growth stimulatory and anti-apoptotic functions. Single amino acid substitutions in the extracellular or intracellular domains of the receptor, which are the result of germline point mutations of *RET*, cause ligand-independent activation as a dimer or homodimer [3]. The most common mutations are present in a cysteine-rich domain [1].

Different *RET* mutations are associated with different clinical phenotype. MEN 2 syndromes may be classified into three subtypes based on their occurrence. Medullary thyroid cancer (MTC) is characteristic for familial medullary thyroid cancer (FMTC), MEN 2A and MEN 2B syndromes, while hyperparathyroidism occurs only in MEN 2A subtype, with penetrance of 15–20% [1]. Pheochromocytoma is observed in 50% of MEN 2A and MEN 2B cases [1]. In patients with MEN 2, pheochromocytomas are usually benign, but the consequences of abrupt secretion of catecholamines from the tumour may be lethal [4]. Taking in to account the latter risk and nonspecific clinical manifestation of the neoplasm and the fact that it develops usually after the diagnosis of medullary thyroid cancer, it is mandatory to screen all *RET* proto-oncogene mutations carriers for pheochromocytoma.

## Material and methods

We studied 228 patients with proto-oncogene *RET* mutations, registered in the Department of Nuclear Medicine and Endocrine Oncology, Maria Skłodowska-Curie Memorial Cancer Centre and Institute of Oncology, Gliwice Branch.

Genetic analysis of *RET* proto-oncogene was performed in each patient with confirmed medullary thyroid cancer, pheochromocytoma, and positive family history of MEN 2.

The monitoring for the diagnosis of pheochromocytoma was carried out in all patients with established genetic status. Mean time of follow up was 138 months. Surveillance consisted of periodically performed clinical evaluation, 24-hour urinary determinations of total metanephrines complementary with imaging (CT, MR, MIBG scintigraphy). To locate pheochromocytoma, CT and MR were used without distinguishing between the effectiveness of these modalities. The size of the tumour was assessed using imaging modalities. The diagnosis of pheochromocytoma each time was confirmed by histopathological analysis after adrenalectomy. All patients after surgery were under surveillance toward the recurrence or contralateral pheochromocytoma.

## Results

The studied population consisted of 228 *RET* proto-oncogene mutation carriers. The following distribution of *RET* mutations were observed in the cohort: 84 patients with codon 634 mutation (37%), 48 patients with codon 791 mutation (21%), 22 patients with codon 918 mutation (10%), 19 patients with codon 618 mutation (8%), 15 patients with codon 620 mutation (6%), and the remaining 18% consisted of patients with mutations in codon 611, 768, 790, 804, 844, and 891.

Pheochromocytoma developed in 41 patients (18% of all *RET* proto-oncogene mutation carriers), in 26 patients with codon 634 mutation (31%), in 6 patients with codon 918 mutation (27%), in 4 patients with codon 620 mutation (27%), in 2 patients with codon 618 mutation (10.5%), in 2 patients with codon 791 mutation (4%), in 1 patient with codon 611 mutation (25%).

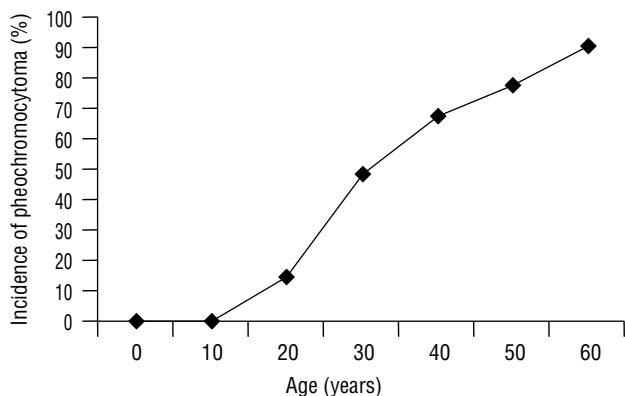
The codon-specific penetrance of pheochromocytoma is illustrated in Table I.

The mean age of diagnosis for the whole cohort was 43 years. The age-related occurrence of pheochromocytoma is illustrated in Figure 1. The lowest age of diagnosis was observed in a 15-year-old patient with codon 918 mutation. The lowest age of diagnosis for the remaining codons were respectively: 20 years for codon 634, 29 years for codon 620, 30 years for codon 791, 45 years for codon 618, and 54 years for codon 611. In eight cases pheochromocytoma was the first manifestation of MEN 2 syndrome, in 4 patients with codon 634 mutation, in 2 patients with codon 791 mutation, in 1 patient with codon 918 mutation, and in 1 with codon 620 mutation. Codon-related occurrence of pheochromocytoma and medullary thyroid cancer in MEN 2 syndrome is illustrated in Figure 2.

**Table I.** Codon-specific expression of pheochromocytoma in MEN 2

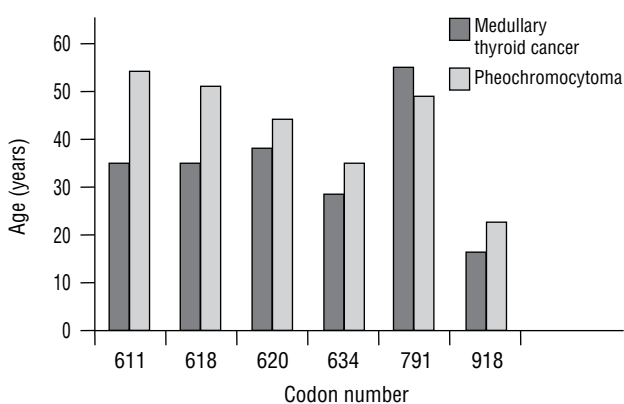
**Tabela I.** Penetracja guza chromochłonnego w zespole MEN 2 w zależności od lokalizacji mutacji

Codon	Positive incidence	Total
611	1 (25.0%)	4
618	2 (10.5%)	19
620	4 (27.0%)	15
634	26 (31.0%)	84
768	0 (0.0%)	1
790	0 (0.0%)	9
791	2 (4.0%)	48
804	0 (0.0%)	17
844	0 (0.0%)	8
891	0 (0.0%)	1
918	6 (27.0%)	22



**Figure 1.** Age-related occurrence of pheochromocytoma in MEN 2

**Rycina 1.** Penetracja guza chromochłonnego w zespole MEN 2 w zależności od wieku



**Figure 2.** Codon-related mean occurrence age of medullary thyroid cancer and pheochromocytoma in MEN 2

**Rycina 2.** Średni wiek ujawnienia raka rdzeniastego tarczycy i guza chromochłonnego w zespole MEN 2 w zależności od lokalizacji mutacji w poszczególnych kodonach

Only 8 (20%) patients were symptomatic at diagnosis of pheochromocytoma. The mean size of the tumour was 4.3 cm. There was no extra-adrenal localisation. We observed one case of malignant pheochromocytoma with metastases to lymph nodes in the female

patient with mutation in codon 791. The 10-cm tumour was revealed at the age of 30 years, and the metastases occurred after nine years of observation.

Of the 41 patients with pheochromocytoma, 11 (25%) had bilateral involvement at the time of diagnosis, and 14 (34%) revealed contralateral tumour throughout the follow-up period. From the whole group of patients with bilateral tumours, most (84%) had total bilateral adrenalectomy, which resulted in the development of adrenal insufficiency. Only four patients (16%) had adrenal-sparing surgery, of which only one did not require substitution of hydrocortisone.

The clinical traits of pheochromocytoma in MEN 2 syndrome are shown in Table II.

## Discussion

In our series pheochromocytoma developed in patients with mutations at codons 611, 618, 620, 634, and 918 of *RET* gene. Other studies observed pheochromocytoma in subjects with mutations at codon: 609, 618, 620, 634, 666, 791, 804, 883, and 918 of *RET* gene [7–11].

The expected frequency of pheochromocytoma in MEN 2 syndrome is up to 50% [6]. But its penetrance is highly dependent on the *RET* codon mutations [7, 8].

In our study in the whole cohort of *RET* proto-oncogene mutation carriers the overall rate of pheochromocytoma was 18%, which is similar to that reported by Nguyen et al. [9]. However, we observed higher frequency of the neoplasm (respectively, 31% and 27%) in patients with mutations at codon 634 and 918, which is very close to that reported by Machens et al. [8].

In the study by Rodriguez et al. they registered a 32% frequency of pheochromocytoma in a cohort of 54 patients, among which 52 had mutation located in codon 634 [10].

Quayle et al. reported an overall rate of pheochromocytoma of 32%, with the greatest expression in codon 634 (50% positive incidence of pheochromocytoma) [7].

**Table II.** Clinical characteristics of pheochromocytoma (PC) in MEN 2

**Tabela II.** Kliniczna charakterystyka guza chromochłonnego w zespole MEN 2

RET codon	Total patient no.	Mean age at diagnosis (range) (year)	PC as the first tumour	Typical clinical symptoms	Mean size of the tumour [cm]	Bilateral tumour	Contralateral tumour during follow up	Metastases
611	1	54 (54–54)	0	0	3.1	1	0	0
618	2	51 (45–58)	0	0	2.3	2	0	0
620	3	44 (29–61)	1	1	3.6	1	1	0
634	24	36 (20–54)	4	2	2.7	6	9	0
791	2	49 (30–68)	2	2	8.0	0	0	1
918	6	23 (15–32)	1	1	6.2	1	4	0

The low penetrance of pheochromocytoma in our group of patients may be due to the fact that we still have under surveillance 66 patients (29%) below the age of thirty years. Taking into account that the peak age for revealing the pheochromocytoma in MEN 2 syndrome is estimated around 40 years [1], we expect that more cases of pheochromocytoma will occur in our population.

The earliest manifestation of pheochromocytoma in our study was in a 15-year-old patient with mutation in codon 918, while mean age of diagnosis was assessed as 43 years for the whole cohort of *RET* proto-oncogene mutations carriers. The youngest age at diagnosis of pheochromocytoma reported in literature was 12 years, also in a codon 918 mutation carrier [9]. But others observed early manifestation at the age of 12 years in the case of a patient with mutation in codon 634 [12]. The youngest patient age ever reported with disclosed pheochromocytoma determines the moment of implementation of screening protocol. According to the guidelines for diagnosis and therapy of MEN 2 published in 2001 the screening for pheochromocytoma should be implemented by the age of 5–7 years in high- and highest-risk codon (630, 634, 883, 918 *RET* mutation carriers). In families with mutation in lower-risk codons screening may be initiated at a later age. The familial pattern of pheochromocytoma should be considered during the development of a screening plan [13]. The American Thyroid Association also stratifies the risk of pheochromocytoma by *RET* genotype and recommends commencement of pheochromocytoma screening by age of 8 years for mutated *RET* codons 630, 634, and 918 and by age 20 years for the remainder [14].

The oldest patient in whom pheochromocytoma was detected was 61 years old, a *RET* proto-oncogene mutation carrier in codon 620. In other studies the oldest age was 73 years [7]. However, it must be emphasised that age at detection does not necessarily reflect the age of onset.

Thanks to the growth of availability of genetic screening, most patients under a follow-up regimen because of detected mutation in *RET* proto-oncogene are asymptomatic at the time of pheochromocytoma diagnosis.

In this study only 20% of patients presented typical symptoms. In the literature it is also emphasised that patients with MEN 2-related pheochromocytoma often lack sustained hypertension or other symptoms [1]. But the incidence of asymptomatic patients reported in other studies is lower than that observed in our cohort, and ranges between 36 and 52% [7–10, 15]. Nguyen et al. reported that none of the patients in his series expressed all of the classical symptoms (hypertension, postural hypotension, palpitations, headaches, exces-

sive sweating) [9]. We took into consideration that the clinical evaluation in our study might be imperfect due to the retrospective character of analysis with a lack of some information in available medical records, and due to known difficulties in assessing symptoms of pheochromocytoma sometimes mimicking other entities. Likewise, the extensive genetic screening in family members of *RET* mutations carriers may impact the low incidence of symptomatic cases acquired in this report.

In eight patients (20%) pheochromocytoma was the first manifestation of multiple endocrine neoplasia type 2, which is comparable with data that pheochromocytoma may be diagnosed before medullary thyroid cancer in 9–27% [16–18]. However, Nguyen et al. reported no pheochromocytoma preceding MTC [9].

In our study all tumours were localised in adrenals. These results are in agreement with literature data. In a multicentre analysis of 563 MEN 2 patients with pheochromocytoma extra-adrenal tumours occurred only in five patients [19]. Localisation of the tumour together with biochemical phenotype may be helpful in ordering proper genetic testing [20]. In our analysis results of 24-hour urinary fractionated metanephrines, unlike the total metanephrines, were available only in some cases due to limited availability of this modality in patients who were diagnosed a few years ago and outside the clinical centres. According to the algorithm proposed by the Endocrine Society, adrenal localisations of pheochromocytoma together with significant productions of metanephrine relative to combined production of all three catecholamine metabolites, in the absence of a syndromic or familial presentation, guide selection of *RET* proto-oncogene as a first step in genetic analysis [20].

Bilateral pheochromocytomas at the time of diagnosis were observed in 25% of patients in this cohort, and 34% revealed contralateral tumour throughout the follow-up period. The reported frequency of bilateralism is variable in published reports, ranging between 35% and 80% [7, 8, 21, 22] and is higher in comparison to sporadic cases, which is estimated at 3% [13]. According to that fact, patients with MEN 2 are at high risk for bilateral adrenalectomy and lifelong steroid dependence. In our data only four patients had adrenal-sparing surgery that enables assessment of the outcomes of such a procedure. Castinetti et al. in a multicentre study showed that adrenal insufficiency is greatly reduced in adrenal-sparing operations compared with total adrenalectomies [19]. It is known that one third to one half of an adrenal gland is needed to preserve cortical function [20]. On the other hand, leaving some adrenal medullary tissue during non-radical surgery may be the cause of pheochromocytoma recurrence. The cumulative recurrence rate for MEN 2 patients after adrenal-

sparing surgery at 10 years is 38.5% [20]. Nonetheless, Castinetti et al. have shown no significant difference in recurrences between those operated on with adrenal-sparing surgery or with adrenalectomy. In material from the Department of General, Vascular, and Transplant Surgery, Medical University of Warsaw, Poland, in the case of pheochromocytoma as a part of MEN 2, the lesions in adrenals have always been multiple [23]. The authors of the analysis emphasise the importance of precise assessment of the lesions with use of 3D CT in patients qualified for a sparing surgery [23].

In our study there was only one case (2%) of malignant pheochromocytoma, which corresponds with the opinion that MEN 2-associated pheochromocytomas are almost exclusively benign [1, 19].

## Conclusions

It is mandatory to screen all *RET* proto-oncogene mutations carriers for pheochromocytoma.

In patients with MEN 2 syndrome pheochromocytomas are usually benign adrenal tumours with high risk of bilateral development. Patients who present unilateral pheochromocytoma should be monitored for early diagnosis of contralateral tumour.

Taking into account that medullary thyroid carcinoma is the first manifestation of MEN 2 syndrome in most cases, it is recommended mandatory genetic study of *RET* proto-oncogene after diagnosis of MTC. Patients with confirmed germline *RET* mutation need careful screening for pheochromocytoma before thyroid resection.

## References

- Pacak K, Timmers H, Eisenhofer G. Pheochromocytoma. In: Jameson JL, De Groot LJ. *Endocrinology*. Saunders Elsevier, Philadelphia 2010; 1990–2018.
- Schuchardt A, D'Agati V, Larsson-Blomberg L et al. Defects in the kidney and enteric nervous system of mice lacking the tyrosine kinase receptor Ret. *Nature* 1994; 367: 380–383.
- Arighi E, Borrello MG, Sariola H. RET tyrosine kinase signaling in development and cancer. *Cytokine Growth Factor Rev* 2005; 16: 441–467.
- Eng C, Clayton D, Schuffenecker I et al. The relationship between RET proto-oncogene mutations and disease phenotype in multiple endocrine neoplasia type 2. International RET Mutations Consortium analysis. *JAMA* 1996; 276: 1575–1579.
- Lenders JW, Eisenhofer G, Mannelli M et al. Pheochromocytoma. *Lancet* 2005; 366: 665–675.
- Wells SA, Pacini F, Robinson BG et al. Multiple endocrine neoplasia type 2 and familial medullary thyroid carcinoma: an update. *J Clin Endocrinol Metab* 2013; 98: 3149–3146. doi:10.1210/jc.2013-1204
- Quayle FJ, Fialkowski EA, Benveniste R et al. Pheochromocytoma penetrances varies by RET mutation in MEN 2A. *Surgery* 2007; 142: 800–805.
- Machens A, Brauckhoff M, Holzhausen HJ et al. Codon-specific development of pheochromocytoma in multiple endocrine neoplasia type 2. *J Clin Endocrinol Metab* 2005; 90: 3999–4003.
- Nguyen L, Niccoli-Sire P, Caron P et al. Pheochromocytoma in multiple endocrine neoplasia type 2: a prospective study. *Eur J Endocrinol* 2001; 144: 37–44.
- Rodriguez JM, Balsalobre M, Ponce JL et al. Pheochromocytoma in MEN 2A syndrome. Study of 54 patients. *World J Surg* 2008; 32: 2520–2526. doi: 10.1007/s00268-008-9734-2
- Thosani S, Ayala-Ramirez M, Palmer L et al. The characterization of pheochromocytoma and its impact on overall survival in multiple endocrine neoplasia type 2. *J Clin Endocrinol Metab* 2013; 98: 1813–1819. doi: 10.1210/jc.2013-1653
- Machens A, Niccoli-Sire P, Hoegel J et al. Early malignant progression of hereditary medullary thyroid cancer. *N Engl J Med* 2003; 349: 1517–1525.
- Brandi ML, Gagel RF, Angeli A et al. Guidelines for diagnosis and therapy of MEN type 1 and type 2. *J Clin Endocrinol Metab* 2001; 86: 5658–5671.
- Kloos RT, Eng C, Evans DB et al. Medullary Thyroid Cancer: management guidelines of the American Thyroid Association. *Thyroid* 2009; 19: 565–612. doi: 10.1089/thy.2008.0403
- Myśliwiec J, Siewko K, Zukowski L et al. Pheochromocytoma — analysis of 15 consecutive cases from one center. *Endokrynol Pol* 2013; 64:192–196.
- Casanova S, Rosenberg-Bourgin M, Farkas D et al. Pheochromocytoma in multiple endocrine neoplasia type 2A: survey of 100 cases. *Clin Endocrinol* 1993; 38: 531–537.
- Inabnet WB, Caragliano P, Pertsemliadis D. Pheochromocytoma: inherited associations, bilaterality and cortex preservation. *Surgery* 2000; 128: 1007–1011.
- Neumann HP, Berger DP, Sigmund G et al. Pheochromocytomas, multiple endocrine neoplasia type 2 and von Hippel-Lindau disease. *N Engl J Med* 1993; 329: 1531–1538
- Castinetti F, Qi XP, Walz MK et al. Outcomes of adrenal-sparing surgery or total adrenalectomy in pheochromocytoma associated with multiple endocrine neoplasia type 2: an international retrospective population-based study. *Lancet Oncol* 2014; 15: 648–655. doi: 10.1016/S1470-2045(14)70154-8
- Lenders JW, Duh QY, Eisenhofer G et al. Pheochromocytoma and paraganglioma: An Endocrine Society clinical practice guideline. *J Clin Endocrinol Metab* 2014; 99: 1915–1942. doi: 10.1210/jc.2014-1498
- Modigliani E, Vasen HM, Rue K et al. Pheochromocytoma in multiple endocrine neoplasia type 2A: European study. The Euromen Study Group. *I Intern Med* 1995; 238: 363–367.
- Howe JR, Norton JA, Wells SA. Prevalence of pheochromocytoma and hyperparathyroidism in multiple neoplasia type 2A: results of long term follow up. *Surgery* 1993; 114: 1070–1077.
- Otto M, Dzwonkowski J. Adrenal-preserving surgery of adrenal tumors. *Endokrynol Pol* 2015; 66: 80–96. doi: 10.5603/EP.2015.0012