



Possibilities of surgical correction of vocal cord palsy after thyroid gland operations

Możliwości naprawcze porażenia fałdów głosowych w wyniku operacji gruczołu tarczowego

Grażyna Lisowska¹, Paweł Sowa¹, Hanna Misiotek², Wojciech Ścierański¹, Maciej Misiotek¹

¹ENT Department, Medical University of Silesia, Zabrze, Poland

²Department of Anaesthesiology, Medical University of Silesia, Zabrze, Poland

Abstract

Introduction: Surgery of the thyroid gland remains the main cause of bilateral vocal cord palsy (VCP). Ventilation problem is the main problem in such situations. There are a couple of corrective surgical procedures in the case of VCP. The aim of our study was to show the possibility of widening of the glottis, and to evaluate the techniques and effects of surgical treatments due to bilateral VCP resulting from thyroid gland surgery.

Material and methods: Five methods of surgical treatment were used: laser-assisted posterior cordectomy, according to Denis and Kashima; laser-assisted bilateral medial arytenoidectomy, as proposed by Crumley; laser-assisted posterior ventriculocordectomy, as described by Pia; laser-assisted total arytenoidectomy with posterior cordectomy, as presented by Ossoff; and laterofixation, according to Lichtenberger. The postoperative patient's subjective improvement was assessed using visual analogue scale.

Results: Between 1998 and 2014 we operated on 270 patients with bilateral VCP. Paresis occurred as the result of the iatrogenic effect of thyroid gland surgery in 255 patients (94.4%) vs. 15 (7.6%) from other causes. The majority of our patients (77.6%) had undergone laser arytenoidectomy with posterior partial cordectomy, and in 13.7% of them Lichtenberger laterofixation had been performed. Ossoff's surgery gives good ventilation results: successful decannulation (62.9% after first surgery; 97.6% final rate) and significant subjective ventilation improvement in 96% of patients.

Conclusions: Ossoff's laser arytenoidectomy with posterior cordectomy is a safe procedure that gives acceptable ventilation improvement. Patients report satisfactory quality of life and the possibility of returning to active professional life. Laterofixation should be considered as an alternative for tracheotomy rather than permanent procedure. (*Endokrynol Pol* 2015; 66 (5): 412–416)

Key words: vocal cord palsy; vocal cord paralysis; arytenoidectomy; laterofixation; thyroid gland surgery complication

Streszczenie

Wstęp: Powikłania po zabiegach chirurgicznych gruczołu tarczowego są stale najczęstszą przyczyną obustronnego porażenia fałdów głosowych, a zaburzenia oddychania są głównym problemem w tych sytuacjach. Istnieje wiele procedur operacyjnych poszerzenia szpary głośni w przypadku obustronnego porażenia fałdów głosowych. Celem pracy była prezentacja możliwości poszerzenia szpary głośni, ocena wykonywanych technik operacyjnych oraz wyników leczenia w przypadku porażenia fałdów głosowych po zabiegach operacyjnych tarczycy.

Materiał i metody: W badaniu oceniono pięć technik operacyjnych: laserowa tylna chordektomia według Denisa i Kashimy, laserowa obustronna arytenoidektomia przyśrodkowa według Crumlaya, laserowa tylna wentrykulo-chordektomia według Pia, laserowa całkowita arytenoidektomia z chordektomią tylną według Ossoffa oraz laterofiksacja według Lichtenbergera. Subiektywnej oceny poprawy wentylacyjnej dokonywano przy użyciu skali VAS.

Wyniki: W latach 1998–2014 autorzy zoperowali 270 pacjentów z obustronnym porażeniem fałdów głosowych, z czego 255 (94,4%) przypadków jatrogennych po operacjach tarczycy, a 15 (7,6%) z innych przyczyn. U znacznej większości pacjentów — 77,6%, zastosowano laserową całkowitą arytenoidektomię z chordektomią tylną, a u 13,7% laterofiksację metodą Lichtenbergera. Zabieg operacyjny według Ossoffa pozwala na osiągnięcie dobrych wyników wentylacyjnych: udana dekaniulacja (62,9% po pierwszym zabiegu, 97,6% jako ostateczny odsetek) oraz znaczna lub istotna stopnia subiektywna poprawa wydolności oddechowej u 96% pacjentów.

Wnioski: Arytenoidektomia według Ossoffa jest bezpieczną procedurą dającą zadowalające wyniki wentylacyjne. Pacjenci relacjonują satysfakcjonującą jakość życia oraz możliwość powrotu do życia zawodowego. Zdaniem autorów pracy, laterofiksacja powinna pozostać jako alternatywa dla czasowej tracheotomii raczej niż zabieg zasadniczy. (*Endokrynol Pol* 2015; 66 (5): 412–416)

Słowa kluczowe: porażenie fałdów głosowych; arytenoidektomia; laterofiksacja; powikłania operacji tarczycy

Introduction

Bilateral vocal fold palsy (VCP) is a life-threatening condition usually requiring immediate aid. There are several causes of VCP, different for unilateral and bilateral failure.

The most common cause of unilateral palsy has changed in recent years from non-laryngeal malignancies to non-thyroid surgery; however, the major cause of bilateral VCP remains the same: iatrogenic effect after thyroid gland surgery, being as much as 80% [1–4].

✉ Paweł Sowa M.D., ENT Department, Medical University of Silesia, Curie-Skłodowskiej St. 10, 41–800 Zabrze, Poland, phone: +48 32 373 23 95, e-mail: paw.sowa@gmail.com

Operative techniques (i.e. recurrent laryngeal nerve — RLN identifying, endoscopic approach) or new equipment (intraoperative neuronal monitoring) are very helpful in preserving the safety of RLN during surgery, but the damage rate remains at about 5%. Of course the chance of harming the RLN is significantly greater in the case of malignant tumour surgery or re-operation [5]. The majority of RLN injuries concern unilateral palsy, carrying a small risk; however, one third of those complications are bilateral [5–7]. Therefore, laryngoscopy should be a routine examination prior to thyroid gland surgery [8]. Although there are some new ideas about the methods of vocal fold examination [9], they are still more expensive and hazardous compared with traditional laryngoscopy. It is worth noting that the majority of vocal cord immobility cases are unilateral and temporary, so patients usually return to good health within a few weeks or up to maximum of a few months.

Although the dyspnoea always accompanies bilateral vocal cord palsy, depending on the degree of respiratory problems tracheotomy may be or may not be required. Since it is not possible to easily distinguish the paresis from paralysis right away, an observation time of 6–12 months is needed before the laryngeal corrective surgery can be performed [10]. Numerous different techniques of surgery in the case of the bilateral vocal cord palsy have been proposed [11, 12]. Every technique has its supporters and opponents. So it seems that none of them is perfect and, as usual, the patient's decision, surgeon's preferences, and centre's capabilities are crucial in choosing the optimal method of therapy.

The long-term ventilation results of the surgery depend on the postoperative side effects, mostly local ones. Some time ago mitomycin-C, a chemotherapy drug, was proposed as having a potentially positive impact on local healing and scar formation with lower risk of fibrosis. This effect seems to be long lasting and was supported by both *in vitro* and *in vivo* studies [13, 14].

The aim of our study was to show the possibility of widening of the glottis lumen, and to evaluate the techniques and effects of surgical treatment due to bilateral VCP resulting from thyroid gland surgery in patients treated in the ENT Department in Zabrze, Medical University of Silesia.

Material and methods

Our retrospective study included 270 patients who underwent surgical treatment because of bilateral VCP, in the ENT Department in Zabrze, Medical University of Silesia, in the years 1998–2014. Paresis occurred as the result of the iatrogenic effect of thyroid gland surgery

in 255 patients (94.4%) *vs.* 15 (7.6%) from other causes (idiopathic, thyroid pathologies, cardiologic operations, mediastinal illnesses). Further analysis included only those 255 patients after thyroid surgery (197 females and 58 males; average age 56.9 ± 13.9 years, range 24–83 years).

Five methods of surgical treatment in bilateral VCP used in the ENT Department in Zabrze were considered in our study:

- laser-assisted posterior cordectomy according to Denis and Kashima [15] — unilateral or bilateral V-shape excision of the posterior part of the vocal fold
- laser-assisted bilateral medial arytenoidectomy with preservation of the lateral aspect of the arytenoid, proposed by Crumley [16]
- laser-assisted posterior ventriculocordectomy, described by Pia et al. [17]
- laser-assisted total arytenoidectomy with posterior cordectomy, presented by Ossoff et al. [18, 19] (Fig. 1)
- laterofixation — vocal fold transposition according to Lichtenberger [20] (Fig. 1).

All procedures were carried out using surgical microscope and Kleinsasser's set under full anaesthesia. In laser-assisted procedures a CO₂ laser with maximal power of the beam at the level 7–12 W was used. Laterofixations were made using Lichtenberger's set.

Mitomycin-C (Nordic Pharma, Paris, France) was applied during the surgery immediately after laser removal of proper tissue by local adhibition for two minutes.

The postoperative patient's subjective improvement was assessed using the visual analogue scale — VAS. Patients were asked to report their pre- and postoperative breathing problems on VAS rulers. The difference between pre- and postoperative score was taken as the result. For the purpose of evaluating self-reported improvement we divided the VAS results into three clusters: > 5 VAS points — substantial improvement; 5–3 VAS points — average improvement, and < 3 VAS points — negligible improvement. The VAS assessment was performed on the day of surgery and two weeks after the surgery.

We adopted the scheme of post-operative follow-up visits: one week, two weeks, one month, three months, six months, one year, and every year. All visits were supported by ENT examination and videolaryngoscopy.

Statistical analyses were performed using Microsoft Office Excel 2010 and Statistica 7.0 PL. The parametric *t*-Student test and non-parametric U Man-Whitney, χ^2 , and Wilcoxon tests were used for the analysis. The values were presented as mean \pm standard deviation (SD). Values of $p < 0.05$ were accepted as statistically significant.

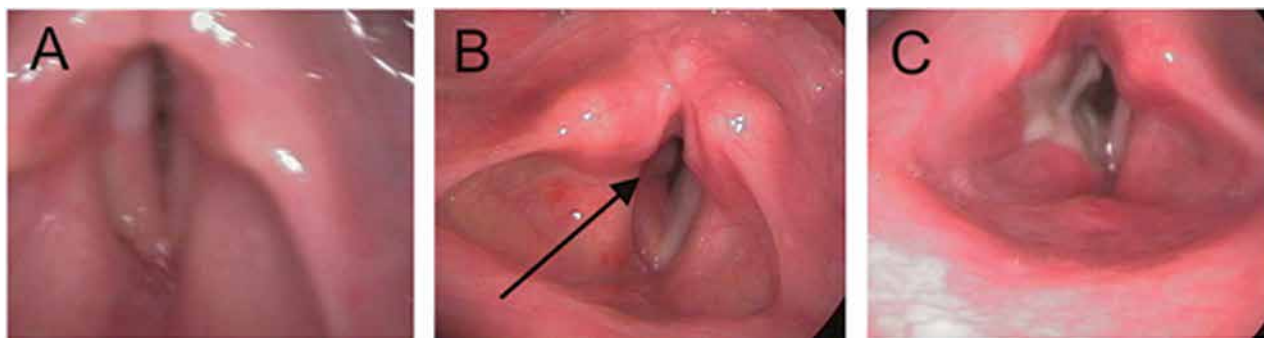


Figure 1. Videolaryngoscopy — laryngeal view: **A.** bilateral vocal cord palsy; **B.** picture of the larynx 7 days after laterofixation (the thread is indicated by the arrow); **C.** picture of the larynx 10 days after laser-assisted total arytenoidectomy with posterior cordectomy presented by Ossoff et al. (the fibrin can be seen)

Rycina 1. Obraz wideolaryngoskopowy krtani: **A.** obustronne porażenie fałdów głosowych; **B.** obraz krtani 7 dni po zabiegu laterofiksacji (strzałką oznaczono nić); **C.** obraz krtani 10 dni po laserowym zabiegu arytenoidektomii z chordektomią tylną wg Ossofa i wsp. (widoczny włóknik)

Results

In the years 1998–2014 a total of 255 patients with bilateral VCP after thyroid surgery were treated in the ENT Department in Zabrze, Medical University of Silesia. Previously performed tracheotomy was observed in 170 patients (66.7%), while the remaining 85 (33.3%) did not require immediate respiratory aid. Among the patients with tracheotomy, 107 (62.9%) of them were successfully decannulated after first laryngeal surgery. The remaining 63 patients (37.1%) needed multiple procedures before final decannulation ($n = 59$, 34.7%) or required a sustained tracheotomy ($n = 4$, 2.4%).

The majority of patients underwent laser arytenoidectomy with posterior partial cordectomy according to Ossoff et al. — 198 (77.6%), and in 35 (13.7%) of them the Lichtenberger laterofixation was performed. In 22 patients (8.6%) other laser treatment was chosen in accordance with the patient and surgeon's choice (Table I). Because the group sizes were extremely different depending on the kind of surgery, further results were not compared between groups but are presented in the most numerous groups, particularly in the Ossoff's surgery group.

Granulation requiring additional procedure occurred in 15 patients after laser arytenoidectomy with posterior partial cordectomy (7.6%). Although our mitomycin-C patient group are still under observation (43 patients) and the precise results must be presented after sufficient follow-up, it can already be seen that the adhibition of the drug has a favourable impact on healing (data not presented—further follow-up needed).

Minor or major side effects appeared in 16 of 35 (45.7%) patients after Lichtenberger's laterofixation. The events concerned the following: inflammation/

Table I. The characterisation of patients operated because of bilateral vocal cord palsy in the ENT Department in Zabrze, Medical University of Silesia in the years 2002–2014

Tabela I. Charakterystyka pacjentów operowanych z powodu obustronnego porażenia fałdów głosowych w Klinice i Oddziale Klinicznym Otorynolaryngologii i Onkologii Laryngologicznej w Zabrzu, Śląskiego Uniwersytetu Medycznego, w latach 2002–2014

Surgical protocol	Number of patients (n = 255)	Percentage of total patients (n = 255)
m. Ossoff	198	77.6%
m. Lichtenberger	35	13.7%
m. Denis & Kashima	15	5.9%
m. Crumley	4	1.6%
m. Pia	3	1.2%

/allergic process in the spot of the thread attachment — 9, vocal fold intersection by the thread — 4, thread rupture — 2, and laryngeal oedema — 1. While minor complications (inflammation) occurred in the early postoperative period (1–14 days after procedure), the major ones (thread rupture, vocal fold intersection) occurred in the late postoperative period (two to several weeks) and required immediate action.

The patient's subjective self-assessment of the respiration improvement after Ossoff's surgery was performed using the VAS scoring mentioned before. Substantial improvement was reported by 102 patients (51.5%), average by 88 patients (44.4%), and 8 patients (4%) reported negligible improvement (Fig. 2).

In the next step of our study we tried to estimate factors like surgeon's experience, mitomycin-C application, and the accessibility of modern anaesthesiological or surgical equipment affecting the results of our operations.

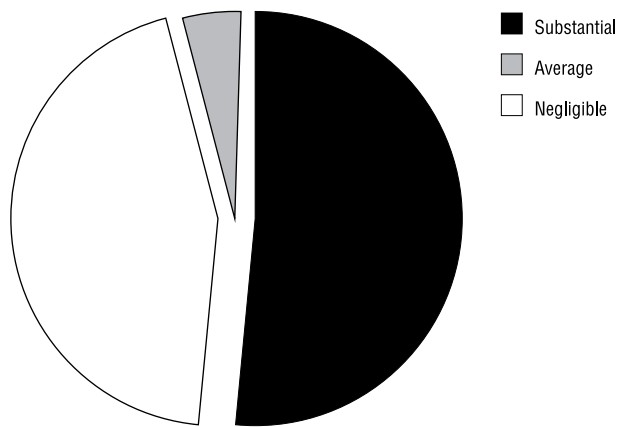


Figure 2. Graphical presentation of patient's subjective self-assessment of the respiration improvement using the VAS scoring
Rycina 2. Subiektywna samoocena poprawy oddechowej pacjentów przy użyciu punktacji VAS — prezentacja graficzna

Although there was no statistical significance, it could be seen that operator's experience and new technique application (i.e. mitomycin-C, JET ventilation) had a favourable impact in the results of the treatment as well as in the improvement in complication rate (data not shown).

Discussion

Regardless of the progress in current operative techniques and available equipment in the surgery of the thyroid gland being supported by more and more accurate anatomical studies [21–23], iatrogenic injury of RLN during such operations remains the main cause of bilateral vocal fold palsy [1, 2]. More than 94% of our patients suffered from bilateral vocal cord paralysis as a post-thyroidectomy complication, supporting this occurrence again [24].

The majority of our patients (66.7%) had had tracheotomy performed previously. An excellent alternative for tracheotomy seems to be the technique of laterofixation after Lichtenberger et al. [10, 20]. The technique is simple, fast, and inexpensive and most importantly of all — reversible. However, our experience shows a high complication rate for this surgical treatment. Most of the side effects were minor and appeared in the early follow-up (within two weeks) and therefore were easy to handle (inflammation/allergic process on the skin).

On the other hand, the most hazardous complications (vocal fold intersection by the thread, thread rupture, or laryngeal oedema) were seen a few weeks after the surgery and hence carried with them additional potential risk. Taken together, we still believe that laterofixation is be a good option for more traumatic tracheotomy, but it requires attentive follow-up. However, other authors consider this technique to be more

valuable [25]. The weakness of our laterofixation efforts may be that we were able to try only a limited number of materials like threads etc. It has to be mentioned that the use of other, perhaps dedicated, materials could decrease the complication rate of this technique. Last year onabotulinum toxin A injection into the cricothyroid muscles was proposed for bilateral VCP treatment as an alternative for surgery [26]. The idea seems to be interesting but controversial and requires further investigation.

Between the years 1998 and 2014 we used four laser-assisted techniques of laryngeal widening in the case of bilateral vocal cord paralysis: according to Denis and Kashima [15]; Crumley [16]; Pia et al. [17]; and Ossoff et al. [18, 19]. In our results, it can be seen that laser-assisted total arytenoidectomy with posterior cordectomy presented by Ossoff et al. is the most accepted surgical technique by our team. Two thirds of our studied group underwent this kind of surgery. The operation gives good ventilation results, presented as the percentage of successful decannulation in tracheotomised patients (62.9% after first surgery; 97.6% final rate) and substantial or average subjective ventilation improvement assessed in 96% of patients (51.5% and 44.4%, respectively). Most of our patients reported acceptable quality of life and many of them carried on with their intellectual work. These results agree with those previously presented both by our team [24, 27, 28] and other authors [10, 29]. Moreover, Ossoff's surgery appeared to be a reasonably safe technique with only about 7% of minor unwanted effects (mainly granulation) [30]. Furthermore, the results of mitomycin-C application are very promising, although our studied group needs further investigation. The protective role in laryngeal wound healing was described previously [14].

Although we did not manage to present significant results concerning the impact of surgeon's experience or the accessibility of modern anaesthesiological or surgical equipment on the results of our operations, a clear trend could be seen. Surgeon's experience seemed to play the most important role in the success of the treatment, yet the accessibility of modern anaesthesiological equipment (i.e. jet ventilation, mitomycin-C) or modernised surgical instruments improved both surgical and follow-up patients' safety. These results seem to be obvious nowadays.

Conclusions

Surgery of the thyroid gland remains the main cause of bilateral VCP. However, there are surgical procedures allowing the correction of the glottis. One of them is laser-assisted total arytenoidectomy with posterior cor-

dectomy. The procedure is safe and provides acceptable ventilation improvement that gives patients satisfactory quality of life and the possibility of returning to active professional life. In our opinion, laterofixation should be considered as an alternative for temporary tracheotomy rather than permanent procedure.

References

1. Benninger MS, Gillen JB, Altman JS. Changing etiology of vocal fold immobility. *Laryngoscope* 1998; 108: 1346–1350.
2. Rosenthal LH, Benninger MS, Deeb RH. Vocal fold immobility: a longitudinal analysis of etiology over 20 years. *Laryngoscope* 2007; 117: 1864–70.
3. Reiter R, Pickhard A, Smith E et al. Vocal cord paralysis-analysis of a cohort of 400 patients. *Laryngorhinootologie* 2015; 94: 91–96.
4. Seyed Toutounchi SJ, Eydi M, Golzari SE et al. Vocal cord paralysis and its etiologies: a prospective study. *J Cardiovasc Thorac Res* 2014; 6: 47–50.
5. Misiolek M, Waler J, Namyslowski G et al. Recurrent laryngeal nerve palsy after thyroid cancer surgery: a laryngological and surgical problem. *Eur Arch Otorhinolaryngol* 2001; 258: 460–462.
6. Chiang FY, Wang LF, Huang YF et al. Recurrent laryngeal nerve palsy after thyroidectomy with routine identification of the recurrent laryngeal nerve. *Surgery* 2005; 137: 342–347.
7. Cho MJ, Park KS, Cho MJ et al. A comparative analysis of endoscopic thyroidectomy versus conventional thyroidectomy in clinically lymph node negative thyroid cancer. *Ann Surg Treat Res* 2015; 88: 69–76.
8. Franch-Arcas G, González-Sánchez C, Aguilera-Molina YY et al. Is there a case for selective, rather than routine, preoperative laryngoscopy in thyroid surgery? *Gland Surg* 2015; 4: 8–18.
9. Ruane LE, Lau KK, Low K et al. Dynamic 320-slice CT larynx for detection and management of idiopathic bilateral vocal cord paralysis. *Respirol Case Rep* 2014; 2: 24–6.
10. Chen X, Wan P, Yu Y et al. Types and timing of therapy for vocal fold paresis/paralysis after thyroidectomy: a systematic review and meta-analysis. *J Voice* 2014; 28: 799–808.
11. Misiolek M, Cecherz K, Namyslowski G et al. Evolution in the surgical treatment of bilateral vocal cord paralysis. *Otornolaryngol* 2006; 5: 107–111.
12. Misiolek M, Stelmanska K, Twardokes M et al. Postoperative impairment of the laryngeal nerves. *Pol Przegl Otolaryngol* 2014; 3: 15–19.
13. Li NY, Chen F, Dikkers FG et al. Dose-dependent effect of mitomycin C on human vocal fold fibroblasts. *Head Neck* 2014; 36: 401–410.
14. Roediger FC, Orloff LA, Courey MS. Adult subglottic stenosis: management with laser incisions and mitomycin-C. *Laryngoscope* 2008; 118: 1542–1546.
15. Dennis DP, Kashima H. Carvon dioxide laser posterior cordotomy for treatment of bilateral vocal cord paralysis. *Ann Otol Rhinol Laryngol* 1989; 98: 930–934.
16. Crumley RL. Endoscopic laser medial arytenoidectomy for airway management in bilateral laryngeal paralysis. *Ann Otol Rhinol Laryngol* 1993; 102: 81–84.
17. Pia F, Pisani P, Aluffi P. CO₂ laser posterior ventriculocordectomy for the treatment of bilateral vocal cord paralysis. *Eur Arch Otorhinolaryngol* 1999; 256: 403–406.
18. Ossoff RH, Sisson GA, Duncavage JA et al. Endoscopic laser arytenoidectomy for the treatment of bilateral vocal cord paralysis. *Laryngoscope* 1984; 94: 1293–1297.
19. Ossoff RH, Duncavage JA, Shapshay SM et al. Endoscopic laser arytenoidectomy revisited. *Ann Otol Rhinol Laryngol* 1990; 99: 764–771.
20. Lichtenberger G. Reversible immediate and definitive lateralization of paralyzed vocal cords. *Eur Arch Otorhinolaryngol* 1999; 256: 407–411.
21. Assadi M, Yarani M, Zakavi SR et al. Sentinel node mapping in papillary thyroid carcinoma using combined radiotracer and blue dye methods. *Endokrynol Pol* 2014; 65 (4): 281–286.
22. Woliński K, Rewaj-Łosyk M, Ruchala M. Sonographic features of medullary thyroid carcinomas—a systematic review and meta-analysis. *Endokrynol Pol* 2014; 65: 314–318.
23. Serpell JW, Lee JC, Yeung MJ et al. Differential recurrent laryngeal nerve palsy rates after thyroidectomy. *Surgery* 2014; 156: 1157–1166.
24. Misiolek M, Klebukowski L, Lisowska G et al. Usefulness of laser arytenoidectomy and laterofixation in treatment of bilateral vocal cord paralysis. *Otolaryngol Pol* 2012; 66: 109–116.
25. Korkmaz MH, Bayır Ö, Çadallı Tatar E et al. Glottic airway gain after 'suture arytenoid laterofixation' in bilateral vocal cord paralysis. *Acta Otolaryngol* 2015; 30: 1–6.
26. Daniel SJ, Cardona I. Cricothyroid onabotulinum toxin A injection to avert tracheostomy in bilateral vocal fold paralysis. *JAMA Otolaryngol Head Neck Surg* 2014; 140: 867–869.
27. Misiolek M, Namyslowski G, Warmuzinski K et al. The influence of laser arytenoidectomy on ventilation parameters in patients with bilateral vocal cord paralysis. *Eur Arch Otorhinolaryngol* 2003; 260: 381–385.
28. Misiolek M, Ziora D, Namyslowski G et al. Long-term results in patients after combined laser total arytenoidectomy with posterior cordectomy for bilateral vocal cord paralysis. *Eur Arch Otorhinolaryngol* 2007; 264: 895–900.
29. Testa D, Guerra G, Landolfo PG et al. Current therapeutic prospectives in the functional rehabilitation of vocal fold paralysis after thyroidectomy: CO₂ laser arytenoidectomy. 2014; 12: S48–51.
30. Misiolek M, Namyslowski G, Nozynski J et al. Local complications after laser arytenoidectomy due to bilateral vocal cord paralysis. *Med Laser Appl* 2004; 19: 109–113.