



# Hyperthyroidism during pregnancy — the role of measuring maternal TSH receptor antibodies and foetal ultrasound monitoring

Nadczynność tarczycy w ciąży — rola oznaczania przeciwciał przeciwko receptorowi TSH i ultrasonograficznego monitorowania płodu

Małgorzata Gietka-Czernel<sup>1</sup>, Marzena Dębska<sup>2</sup>, Piotr Kretowicz<sup>2</sup>, Wojciech Zgliczyński<sup>1</sup>, Mariusz Ołtarzewski<sup>3</sup>

<sup>1</sup>Department of Endocrinology, Medical Centre of Postgraduate Education, Warsaw, Poland

<sup>2</sup>Department of Obstetrics and Gynaecology, Medical Centre of Postgraduate Education, Warsaw, Poland

<sup>3</sup>Institute of Mother's and Child's Health, Warsaw, Poland

## Abstract

**Introduction:** To evaluate the usefulness of measuring maternal anti-TSH receptor antibodies (TRAbs) and foetal ultrasound (US) monitoring in cases of current or past maternal hyperthyroidism.

**Material and methods:** 77 pregnant women suffering from hyperthyroidism or with a history of Graves' hyperthyroidism were observed prospectively. Maternal serum TSH, fT4, fT3, TRAbs, and foetal US were performed at baseline and repeated every 2–4 weeks when needed. Neonatal thyroid status was assessed based on serum TSH, fT4 and fT3 obtained in the first days of life.

**Results:** 35 women were diagnosed with gestational hyperthyroidism and 42 with Graves' disease; among them 26 had current and 16 past hyperthyroidism. Foetal and neonatal thyroid dysfunction occurred only in cases of maternal Graves' disease: nine (21%) and three (7%), respectively. Active maternal Graves' hyperthyroidism and TRAbs elevated at least five times above the upper normal limit predisposed to foetal hyperthyroidism. Maternal anti-thyroid drug therapy (ATD) and low TRAbs and fT4 were the risk factors of foetal hypothyroidism. Abnormal foetal thyroid sonogram was the only sign of foetal thyroid dysfunction. Four patients (9.5%) had high TRAbs in the 3<sup>rd</sup> trimester (10.8–29.9 IU/mL), but neither foetal nor neonatal thyroid dysfunctions were noted.

**Conclusions:** In the cases of maternal Graves' disease, foetal thyroid dysfunction occurs more often than commonly assumed. Foetal thyroid US is a valuable tool in early diagnosis and monitoring of the foetal thyroid status in pregnancy complicated by maternal Graves' disease. The evaluation of biological activity of maternal TRAbs may be helpful in prenatal diagnosis in some cases. (Endokrynol Pol 2014; 65 (4): 259–268)

**Key words:** maternal Graves' disease; pregnancy; TRAb; foetal ultrasonography

## Streszczenie

**Wstęp:** Ocena przydatności oznaczania matczynych przeciwciał przeciwko receptorowi TSH (TRAb) i ultrasonograficznego (US) monitorowania płodu u ciężarnej z aktywną lub przebytą nadczynnością tarczycy

**Materiał i metody:** 77 ciężarnych z aktualną nadczynnością tarczycy lub chorobą Gravesa i Basedowa (MGB) w wywiadach było obserwowanych prospektywnie. Oceniano matczyne stężenie TSH, fT4, fT3, TRAb oraz US płodu wstępnie oraz co 2–4 tygodnie w zależności od potrzeb. U noworodka badano TSH, fT4, fT3 w pierwszych dniach życia.

**Wyniki:** U 35 badanych rozpoznano tyreotoksykozę ciężarnych a u 42 MGB: wśród nich 26 miało aktualną a 16 przebytą nadczynność tarczycy. Płodowa i noworodkowa dysfunkcja tarczycy występowała wyłącznie w przypadkach matczynej MGB: odpowiednio u 9 (21%) i 3 (7%) dzieci. Matczyzna aktywna nadczynność tarczycy i podwyższone przynajmniej 5-krotnie TRAb predysponowały do nadczynności tarczycy u dziecka. Leczenie tyreostatyczne matki, niskie stężenie TRAb i fT4 były czynnikami ryzyka dziecięcej hipotyreozy. Nieprawidłowy obraz US tarczycy u dziecka był jedynym objawem płodowej dysfunkcji tarczycy. W 4 przypadkach (9,5%) wysokich TRAb u matki (10,8–29,9 IU/mL) stwierdzanych w III trymestrze ciąży nie obserwowano zaburzeń czynności tarczycy u dziecka.

**Wnioski:** W przypadku ciąży u kobiety z MGB płodowe zaburzenia czynności tarczycy występują częściej niż się powszechnie przyjmuje. Monitorowanie ultrasonograficzne tarczycy płodu jest czułą i wartościową metodą oceny stanu czynnościowego tarczycy u dziecka. Ocena biologicznej aktywności matczynych TRAb może być przydatna w niektórych przypadkach diagnostyki prenatalnej. (Endokrynol Pol 2014; 65 (4): 259–268)

**Słowa kluczowe:** matczyzna choroba Gravesa i Basedowa; ciąża; TRAb; ultrasonografia płodu



## Introduction

The impact of maternal thyroid status during pregnancy on the development of progeny has been studied extensively [1–6]. Both maternal hyper- and hypothyroidism can impair somatic and especially neurological status of the offspring [7–18]. Even isolated maternal hypothyroxinemia with free thyroxin (fT4) values below the 5<sup>th</sup>–10<sup>th</sup> percentiles and normal TSH concentrations during the first half of gestation have been reported to be a risk factor for cognitive and motor delay in early childhood [19–24]. Maternal Graves' disease, affecting 0.1–0.4% of pregnancies, and anti-thyroid drug (ATD) therapy during gestation, pose a great therapeutic challenge. Maternal thyroid stimulating antibodies (TSABs) that freely cross the placenta can overstimulate foetal thyroid after the 20<sup>th</sup> week of gestation (WG), when foetal TSH receptors become responsive to TSH and TSH receptor antibodies. On the other hand, transplacental passage of ATD, which influences foetal thyroid much more than the maternal gland, can cause foetal hypothyroidism. The progress in prenatal ultrasonography (US) enabled early diagnosis of foetal thyroid dysfunction without the need to perform invasive procedures such as foetal blood sampling. The symptoms of foetal hyperthyroidism that can be registered ultrasonographically include goitre, tachycardia, cardiomegaly, hydrops, advanced bone maturation, craniosyntostosis, and growth retardation. Foetal hypothyroidism can manifest with goitre, bradycardia, delayed bone maturation, and growth retardation. Foetal goitre can be a cause of foetal head hyperextension, respiratory and swallowing obstruction, and polyhydramnios [25, 26]. According to all current guidelines [25–28], foetal US monitoring should be performed after the 18<sup>th</sup>–22<sup>nd</sup> weeks of gestation (WG) in case of either ATD therapy or maternal Graves' disease with elevated TSH receptor antibodies (TRAb), irrespective of whether hyperthyroidism is active or ablative therapy has been carried out. Cordocentesis should be restricted to cases of confounding clinical data, when laboratory results can influence therapy, especially when an intra-amniotic thyroxin injection is considered. The aim of our study was to investigate the usefulness of maternal TRAb measurements and foetal US monitoring in maternal hyperthyroidism or previous history of Graves' disease. We also intended to verify the previously established foetal thyroid nomograms for the Polish population.

## Material and methods

A prospective study of pregnant women with current hyperthyroidism, irrespective of its cause or history of Graves' disease, was conducted between 2009 and 2012.

Patients were referred to the outpatient endocrinology department of Bielański Hospital in Warsaw by either their obstetricians or endocrinologists. Seventy seven pregnant women at the 6<sup>th</sup>–38<sup>th</sup> WG were enrolled into the study.

Graves' disease was diagnosed based on the patients' history and previous medical reports, and presence of diffuse hypervascular goitre, orbitopathy, dermopathy, and elevated serum TRAb concentration observed at least once. Gestational hyperthyroidism was diagnosed when the clinical symptoms of Graves' disease were absent and serum TRAbs were negative. Diagnosis of toxic nodular goiter was established when thyroid nodules with increased central or peripheral blood flow were visualised on power-Doppler examination, no clinical symptoms of Graves' disease were found, serum TRAbs were negative, and hyperthyroidism continued throughout the gestation and after delivery. The assessment of thyroid status was based on clinical and laboratory data. ATD therapy was provided according to the current guidelines [25–28]; until the end of 2011, propylthiouracil (PTU) was preferred over methimazole (MMI) in order to avoid MMI embryopathy. Since 2012, PTU use has been limited to the first trimester due to its potential hepatotoxicity, and MMI has been implemented. Baseline values of serum thyrotropin (TSH), free T3 (fT3), free T4 (fT4), thyroid-peroxidase antibodies (TPOAbs), thyroglobulin antibodies (TGABs) and TRAb concentration were determined in each patient, and thyroid US was performed. Subsequently, the TSH, fT4 and fT3 tests were repeated every 2–4 weeks. In patients with Graves' disease, serum TRAbs were additionally determined after the 20<sup>th</sup> WG and repeated monthly several times. Baseline foetal US was carried out in each case. In pregnant women with elevated TRAbs or treated with ATD, foetal US was repeated every 2–4 weeks, starting at the 20<sup>th</sup> WG. In other cases, routine US examinations were performed in the 18<sup>th</sup>–23<sup>rd</sup> and the 30<sup>th</sup>–33<sup>rd</sup> WG. Foetal sonograms were obtained using an Accuvix XQ Medison scanner with an abdominal convex 3–7 MHz transducer. An evaluation of gestational age, amniotic fluid volume, foetal anatomy, growth parameters, viability, thyroid size, heart rate, and bone maturation was carried out. Foetal thyroid diameter, circumference, and area were measured via transverse axial view through the foetal neck as described earlier [29, 30]; the results were compared with the reference values for the Polish population [31]. Foetal thyroid measurements above the 95<sup>th</sup> percentile were indicative of foetal goitre. In line with previous reports, colour Doppler ultrasonography was also used to assess foetal thyroid vascularisation [32, 33].

In evaluating foetal bone maturation, the distal femoral epiphysis ossification centre was assessed: its

presence before the 31<sup>st</sup> WG was indicative of accelerated bone maturation due to foetal hyperthyroidism, and its absence after the 33<sup>rd</sup> WG was characteristic of delayed bone maturation resulting from foetal hypothyroidism [34, 35]. Foetal tachycardia was defined as foetal heart rate over 160 beats/min and foetal bradycardia as foetal heart rate below 120 beats/min. In two cases, foetal blood sampling was performed in an attempt to measure foetal TSH, fT4, and fT3 concentrations.

To evaluate neonatal thyroid status, TSH results from dried-spot tests, performed after the first 48 hours of life, were obtained in each case. In the cases of elevated maternal TRAbs, ATD treatment or foetal US signs of abnormal thyroid function, TSH, fT4 and fT3 concentrations were determined after delivery in cord blood or between the 1<sup>st</sup> and 3<sup>rd</sup> days of life, and several times thereafter.

Quantitative analyses of TSH, fT3, fT4, TPOAbs, and TGABs were performed by chemiluminescent immunoassays (EURO/DPC, United Kingdom), using an Immulite 2000 automatic analyser. TRAbs were determined by the competitive electrochemiluminescent method, using soluble porcine TSH receptor and human monoclonal TSH receptor stimulating antibody, M22 (Roche Diagnostics GmbH, Mannheim, Germany). An Elecsys 2010 analyser was used to determine serum TRAbs. Reference ranges for the analysed parameters were as follows: TSH 0.4–4.0 mIU/mL, fT4 10.4–24.4 pmol/L, fT3 1.8–4.2 pg/mL, TPOAbs < 35 IU/mL, TGABs < 40 IU/mL, TRAbs < 1.8 IU/mL. Normal foetal values for TSH, fT4, fT3, according to gestational age, were described by Hume and Guibourdenche [36, 37]. Neonatal TSH values for the Polish population, obtained in dried-spot tests, were as follows: median TSH concentration 1.45 mIU/L, 23.5% TSH results  $\leq$  0.5 mIU/L, 95% TSH results  $\leq$  5 mIU/L, and 0.2% abnormal measurements > 12.0 mIU/L [38]. In our study, the obtained neonatal TSH results in dried-spot tests were compared to the control group, consisting of 68 neonates born to mothers with normal thyroid function [39].

The *t*-Student test was used to compare parametric data and chi-squared test to compare non-parametric data on statistical analysis. Neonatal TSH distributions obtained in dried-spot tests were compared using a non-parametric Mann-Whitney test.  $P < 0.05$  was considered significant.

This study was approved by the Ethics Committee of the Medical Centre of Postgraduate Education, and informed consent was obtained from all the participants.

## Results

The mean age of the studied group of 77 pregnant women was 30.9 years (range: 22–38). Sixty one patients

presented with hyperthyroidism: gestational hyperthyroidism ( $n = 35$ ) or Graves' disease ( $n = 26$ ). There were no cases of toxic nodular goitre. Sixteen patients had a history of hyperthyroidism due to Graves' disease. The baseline characteristics of the group are presented in Figure 1.

### *Patients with gestational hyperthyroidism*

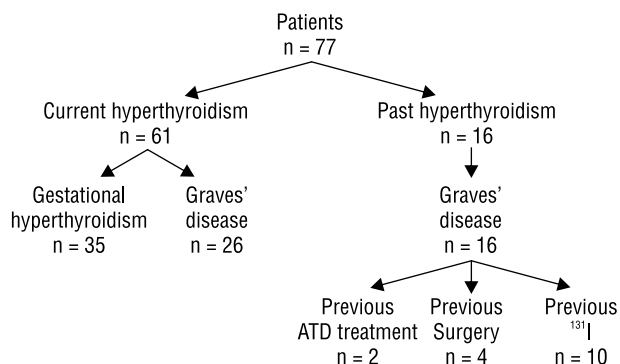
In 35 pregnant women with gestational hyperthyroidism, suppressed serum TSH concentration ( $< 0.1$  mIU/L) was observed between the 6<sup>th</sup> and 38<sup>th</sup> WG (mean  $20 \pm 8.3$  WG). Additionally, 19 patients (54%) had elevated serum fT3 or fT4 concentrations. In 12 of them, short-term ATD therapy was prescribed due to concomitant hyperemesis gravidarum or unclear underlying cause of hyperthyroidism (Table I). Hyperthyroidism was recurrent in three patients: two of them had previous episodes of gestational thyrotoxicosis, and one a history of silent thyroiditis. In the postpartum period, hyperthyroidism occurred in three women with elevated TPOAb during pregnancy: postpartum thyroiditis was recognised in two cases, and one patient developed Graves' disease with severe hyperthyroidism and elevated serum TRAbs (40 IU/mL). This patient had been treated with ATD for one year and radioiodine therapy was instituted after lactation was completed.

### *Patients with Graves' disease*

Graves' disease was diagnosed in 26 pregnant women with current hyperthyroidism and in 16 patients with previous episodes of hyperthyroidism (Table II).

As many as 21 out of 26 patients with current hyperthyroidism (81%) experienced the first episode of the disease, while the other five (19%) had recurrent hyperthyroidism. Sixteen women (61.5%) became pregnant while on ATD treatment (duration 2–36 months, mean 13.6 months). In ten out of 26 cases (38%) remission of hyperthyroidism was achieved in the 2<sup>nd</sup> and 3<sup>rd</sup> trimester, and ATD treatment was withdrawn. Eight patients from the group with remission had low serum TRAb levels: 0.2–2.2 IU/mL (mean  $0.78 \pm 0.6$  IU/mL). Serum TRAb levels remained high (15.2 IU/mL and 26.2 IU/mL) in the other two cases of hyperthyroidism remission; one of these patients was treated with <sup>131</sup>I before pregnancy.

One patient (T.K., gravida 3, para 2) underwent thyroidectomy during gestation. Her hyperthyroidism exacerbated severely (fT3 30 pg/mL, fT4 39.5 pmol/L) in the 1<sup>st</sup> trimester. The goitre volume was nearly 80 mL; the patient needed high ATD doses to control hyperthyroidism and was not compliant with therapy. Total thyroidectomy was performed during the 2<sup>nd</sup> trimester; the surgery was complicated with



**Figure 1.** Baseline characteristics of 77 pregnant women with current or past hyperthyroidism

**Rycina 1.** Wstępna charakterystyka 77 kobiet ciężarnych z aktywną lub przebytą nadczynnością tarczycy

**Table I.** Characteristics of 35 pregnant women with gestational hyperthyroidism

**Tabela I.** Charakterystyka 35 kobiet ciężarnych z tyreotoksykozą ciężarnych

Characteristic	N (%)
Previous history of hyperthyroidism	3/35 (8.5)
Twin pregnancy	5/35 (14)
Hyperemesis gravidarum	10/35 (28)
↑TPOAb or ↑TGAb	6/33 (18)
Abnormal thyroid US	20/34 (58)
— Nodularity	11/34 (32)
— Hypoechoogenicity	4/34 (12)
— Increased blood flow in thyroid parenchyma	5/34 (14)

**Table II.** Characteristics of 42 pregnant women with Graves' disease and current or past hyperthyroidism

**Tabela II.** Charakterystyka 42 kobiet ciężarnych z aktywną lub przebytą nadczynnością tarczycy w przebiegu choroby Gravesa i Basedowa

Characteristic	Graves' hyperthyroidism		p
	Current n = 26 n (%)	Past n = 16 n (%)	
Previous history of hyperthyroidism	5/26 (19)	16/16 (100)	
Twin pregnancy	0	0	
Hyperemesis gravidarum	0	0	
↑TRAb	11/26 (42)	5/16 (31)	NS
Serum TRAb mean ± SD, range [IU/mL]	7.01 ± 11.21 0.2-40	3.09 ± 8.07 0.2- 40	NS
↑TPOAb or ↑TGAb	19/26 (73)	8/16 (50)	NS
Abnormal thyroid US	24/26 (92)	16/16 (100)	NS
Nodularity	8/26 (31)	4/16 (25)	NS
Hypoechoogenicity	21/26 (81)	9/16 (55)	NS
Increased blood flow in thyroid parenchyma	23/26 (88)	6/16 (37.5)	0.001
ATD when became pregnant	16/26 (61.5)	0/16	
L-T4 when became pregnant	0/26	15/16 (87.5)	
Previous surgery	0/26	4/16 (25)	0.03
Previous 131-I	3/26 (11.5)	10/16 (62.5)	0.001

hypoparathyroidism. The patient was treated with L-thyroxin, alphacalcidol and calcium carbonate, and normal ranges of serum TSH, fT4 and calcium were maintained. Serum TRAb concentrations decreased from 30 IU/mL in the 2<sup>nd</sup> trimester to 10.8 IU/mL after surgery. There were no signs of foetal thyroid dysfunction on US monitoring. The only abnormal US finding was SGA (small for gestational age), which was probably related to maternal smoking. The patient had a normal labour and delivered a healthy male neonate weighing 2,210 g and with an Apgar score of 9. The newborn's TSH concentration determined on dried-

spot test was 1.98 mIU/mL; also the measurements taken one month later were normal (TSH 6.8 mIU/mL, fT4 20.2 pmol/L, fT3 2.78 pg/mL).

One case of hyperthyroidism recurrence was documented during observation in the group of 16 pregnant women with a history of hyperthyroidism due to Graves' disease. Patient A.S. (gravida 2, para1), who had undergone subtotal thyroidectomy 11 years earlier, was on L-thyroxin therapy from the time of surgery to the 3<sup>rd</sup> trimester. At the 35<sup>th</sup> WG, L-thyroxin was withdrawn due to TSH suppression. Two weeks later, maternal measurements



**Table III. Patterns of abnormal foetal US scan in foetal hyper- and hypothyroidism****Tabela III. Patologiczne wzorce ultrasonograficzne tarczycy płodu w zależności od rodzaju dysfunkcji tarczycy**

Foetal thyroid US scan	Foetal hyperthyroidism	Foetal hypothyroidism
Increased central blood flow, hypoechogenicity, normal size	N = 2	N = 0
Increased central blood flow, hypoechogenicity, goitre	N = 2	N = 1
Increased peripheral blood flow, hypoechogenicity, goitre	N = 0	N = 2
Goitre without increased vascularisation	N = 0	N = 2

were indicative of mild thyrotoxicosis and serum TRAb level was > 40 IU/mL. Foetal US revealed a goitre with increased central blood flow. Foetal hyperthyroidism was diagnosed, and the mother was treated with methimazole (10 mg daily). After delivery, hyperthyroidism was diagnosed, both in the mother and her newborn.

#### **Maternal current or past hyperthyroidism and thyroid status of the child**

US foetal monitoring revealed the signs of foetal thyroid dysfunction in nine cases of maternal Graves' disease (21%). Foetal thyroid performance was abnormal in each case: enlarged size and/or increased blood flow were documented while other signs of foetal thyroid dysfunction were absent. An intensive blood flow throughout the whole thyroid and its borderline large size (between the 90<sup>th</sup> and 95<sup>th</sup> percentiles) were observed in two cases. Enlarged thyroid size with (n = 5) or without (n = 2) concomitant hypervascularisation was documented in the other seven cases. The US patterns of foetal thyroid abnormalities, according to estimated foetal thyroid dysfunction, are presented in Table III.

Foetal thyroid status was estimated based on the course of maternal thyroid disease, maternal fT4, fT3 and TRAb concentrations, ATD doses, and foetal US monitoring. Foetal blood sampling was performed due to confounding clinical data in two cases; no complications related to the procedure were noted. Foetal hypothyroidism and foetal hyperthyroidism were diagnosed in five and four cases, respectively. Maternal aspects presumptive for foetal hypothyroidism included ATD treatment, and low serum TRAb and fT4 concentrations (within the lowest third of normal limit or below the normal range) in the 3<sup>rd</sup> trimester. Goitre without increased vascularisation or with increased peripheral blood flow represented foetal sign of hypothyroidism. The daily doses of ATD were rather low: 200 mg of PTU in one patient, and 25–50 mg of PTU in the others.

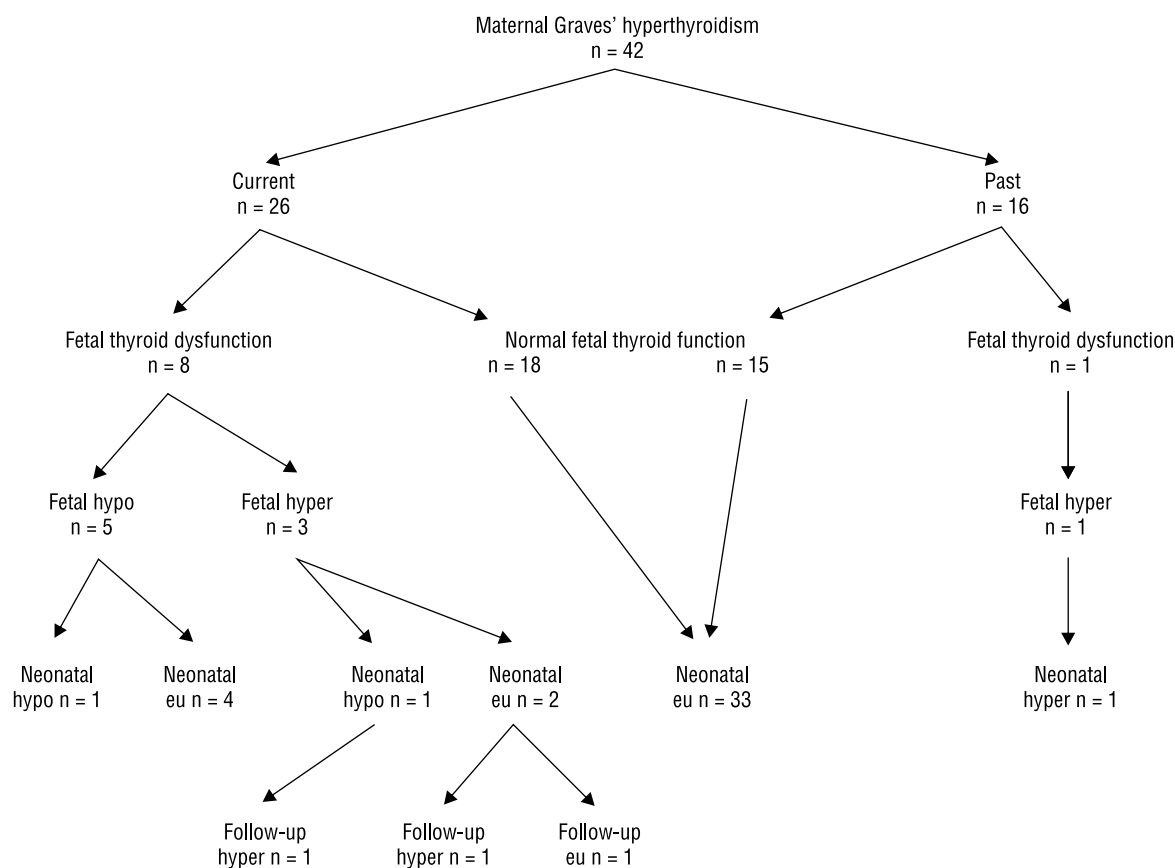
Maternal aspects presumptive for foetal hyperthyroidism included current hyperthyroidism and high

**Table IV. Foetal thyroid dysfunction according to maternal data****Tabela IV. Zaburzenia czynności tarczycy płodu a parametry matczyne**

Maternal data	Foetal hyperthyroidism n = 4	Foetal hypothyroidism n = 5	p
PTU dose [mg/d] mean ± SD, range	56.25 ± 71.8 0–150	70.0 ± 73.7 25–200	NS
fT4 [pmol/L] mean ± SD, range	19.20 ± 4.81 14.8–24.6	12.43 ± 2.07 9.2–14.46	0.02
fT3 [pg/mL] mean ± SD, range	8.65 ± 3.58 4.7–13.4	4.09 ± 0.89 2.7–5.0	0.02
TRAb [IU/mL] mean ± SD, range	31.12 ± 14.78 9.2–40	5.32 ± 8.76 0.2–20.9	0.01

serum TRAb levels in the 3<sup>rd</sup> trimester. Increased blood flow throughout the whole thyroid gland (central hypervascularisation), hypoechogenicity, goitre or thyroid size in the upper normal range (between the 90<sup>th</sup> and 95<sup>th</sup> percentiles) were foetal signs characteristic for hyperthyroidism. The observed maternal TRAb concentrations ranged between 9.2 and > 40 IU/mL, mean 31.1 ± 7.39 IU/mL (5- to 20-fold above the upper normal limit). Maternal fT4 and fT3 levels and ATD doses were quite low in two cases of foetal hyperthyroidism, probably as a result of previous radioiodine and surgical treatment (Table IV).

Maternal therapy was modified in each of the nine cases with foetal thyroid dysfunction. In cases of suspected foetal hypothyroidism, maternal ATD treatment was withdrawn or significantly diminished; a decrease in the foetal goitre size was observed in the majority of cases. In cases of suspected foetal hyperthyroidism, maternal ATD treatment was augmented or instituted *de novo*, resulting in the diminishment or disappearance of increased blood flow within foetal thyroid, and goitre size reduction. Eventually, maternal treatment modification was reflected by fewer cases of thyroid dysfunction observed in newborns (three out of 42 cases, 7%) (Fig. 2).



**Figure 2.** Maternal Graves' disease and foetal and neonatal outcomes

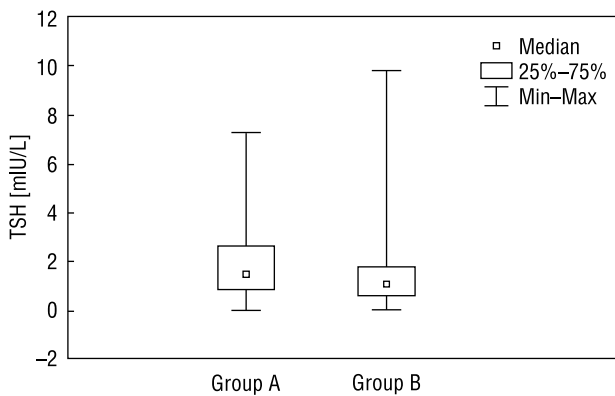
**Rycina 2.** Matczyna choroba Gravesa i Basedowa a stan czynnościowy tarczycy u płodu i noworodka

One of the cases of foetal and neonatal hypothyroidism was observed in a woman on prolonged ATD therapy, with negative TRAbs, who was enrolled into the study at the 38<sup>th</sup> WG. Her serum TSH and fT4 were 1.2 mIU/mL and 9.0 pmol/L, respectively. Foetal goitre with increased peripheral blood flow and head hyperextension was observed on US. ATD therapy was withdrawn and the patient delivered via caesarean section at the 39<sup>th</sup> WG. Transient neonatal hypothyroidism and small goitre were observed at birth, but disappeared quickly during further follow-up. Modification of the maternal treatment led to delivery of healthy euthyroid children in the other four cases of suspected foetal hypothyroidism.

Among the four cases of suspected foetal hyperthyroidism, only one neonate was euthyroid and remained healthy during the next three months of follow-up. The other one was diagnosed with hyperthyroidism on the first day of life. In the other two newborns, initially euthyroid or hypothyroid, hyperthyroidism relapsed within two weeks after birth. The mothers of the three neonates who developed hyperthyroidism were thyrotoxic during pregnancy and showed highly elevated TRAbs in the 3<sup>rd</sup> trimester (35.5, > 40, and > 40 IU/mL).

Four patients from the group of women with Graves' disease (9.5%) showed high TRAb levels in the 3<sup>rd</sup> trimester (range: 10.8–29.9 IU/mL, mean  $20.5 \pm 4.5$  IU/mL) but their children did not demonstrate any thyroid dysfunction during the foetal and neonatal period. Two of these patients were on L-thyroxin treatment after surgery and <sup>131</sup>I therapy. Remission of hyperthyroidism occurred in the 3<sup>rd</sup> trimester in another woman, and ATD was discontinued. The other patient showed suppressed serum TSH and normal fT4 and fT3 throughout the whole gestation, and was not treated with ATD. The possible explanation of this phenomenon is the lack of stimulating properties of TRAbs or the balance between stimulating and inhibiting anti-TSH receptor antibodies.

Neither foetal nor neonatal thyroid dysfunctions were observed in the group of patients with gestational hyperthyroidism. Neonates born to mothers with a history of gestational thyrotoxicosis did not differ from the controls in terms of TSH levels obtained in dried-spot tests: median TSH 1.010 mIU/mL (range: 0.01–9.7 mIU/mL) vs. 1.495 mIU/mL (range: 0.01–7.2 mIU/mL),  $P = \text{NS}$ . The comparison of the distributions of TSH levels in the two groups is presented on Figure 3.



**Figure 3.** Comparison of the distributions of TSH levels obtained in dried-spot tests in the neonates born to mothers with gestational hyperthyroidism and in the control group

Group A — controls ( $n = 68$ ), group B — studied group ( $n = 34$ )

**Rycina 3.** Porównanie rozkładu TSH badanego testem bibulowym u dzieci pochodzących od matek z tyreotoksykozą ciężarnych z grupą kontrolną

Grupa A — kontrolna ( $n = 68$ ), grupa B — badani ( $n = 34$ )

## Discussion

Maternal gestational hyperthyroidism, observed in 35 out of 61 patients (57%), was the most common cause of hyperthyroidism in pregnant women included in our study. An important discriminant for this group was the frequent occurrence of hyperemesis gravidarum (28%) and twin pregnancy (14%); this is consistent with the observations of other authors [40–43]. Although negative signs of Graves' disease and negative serum TRAbs were the main indicators for recognising gestational thyrotoxicosis, the diagnosis turned out to be challenging in several cases. One of the reasons was the high incidence of autoimmune thyroid disease: elevated TPOAbs or TgAbs (18%), decreased thyroid echogenicity (12%), and increased thyroid vascularisation (14%). Taking into account that TRAb assays based on porcine TSH receptor have slightly lower sensitivity compared to TRAb — human assays [44], and the fact that a few (up to 7%) of patients with Graves' disease remain TRAb negative even when 3<sup>rd</sup> generation TSH-receptor antibody assays are used [45, 46], a small degree of uncertainty towards the underlying cause of hyperthyroidism accompanied some of the cases.

In fact, one of our patients with gestational thyrotoxicosis, being TRAb negative and TPOAb positive during pregnancy, developed severe Graves' hyperthyroidism with high serum TRAbs in the postpartum period. Further diagnostic difficulties resulted from long-term persistence of TSH suppression (even until the 38<sup>th</sup> WG, mean 20<sup>th</sup> WG) and high incidence of nodular goitre (32%), which could lead to misdiagnosis of toxic

nodular goitre in some patients. In fact, only a spontaneous normalisation of TSH in the postpartum period allowed the differentiation between toxic nodular goitre and gestational hyperthyroidism in two women with nodular goitre and prolonged suppression of TSH. The abovementioned premises and high incidence of hyperemesis gravidarum contributed to a quite frequent use of ATD in this group (34%). Short-term ATD therapy limited to the 1<sup>st</sup> trimester resulted in normal foetal US performance observed in the 18<sup>th</sup>–23<sup>rd</sup> and the 30<sup>th</sup>–33<sup>rd</sup> WG. In view of the reports on the possible influence of maternal thyroid dysfunction during pregnancy on the pituitary-thyroid axis function in offspring [47], we compared the distribution of TSH levels obtained in dried-spot tests in children delivered by mothers with gestational hyperthyroidism and in the controls. No significant differences were noted between the two groups. However, this observation must be treated with caution, because the dried-spot test is not sensitive enough to estimate very low TSH levels.

Forty two of our patients had Graves' disease. This group included 16 individuals with a past history of hyperthyroidism; remission was achieved in 14 (87.5%) of these patients with either surgery (25%) or radioiodine therapy (62.5%). Women with past and current Graves' hyperthyroidism did not differ significantly in terms of TRAb positivity (31% *v.* 42%) and TRAb serum concentrations ( $3.09 \pm 8.07$  *v.*  $7.01 \pm 11.2$  IU/mL). These results were influenced mainly by the high percentage of women treated previously with radioiodine; it has long been recognised that <sup>131</sup>I therapy results in a rise in thyroid autoantibodies, with a peak at 3–6 months and elevated levels sustained for several years [48, 49]. However, in the group with past Graves' hyperthyroidism, the maternal and child outcome was disturbed in only one extraordinary case, in which hyperthyroidism with high serum TRAbs relapsed in the 3<sup>rd</sup> trimester, after 11 years of history of postoperative hypothyroidism.

Among 42 women with Graves' disease, there were 26 patients with current hyperthyroidism. In this group, 61.5% of women became pregnant while on ATD therapy, lasting 13.6 months on average (up to 38 months in some cases). This observation is surprising as the Polish Endocrine Society does not recommend conceiving during a course of anti-thyroid medication [27]. The guidelines of the American Thyroid Society (ATA) [26] strongly recommend pre-pregnancy counselling for all patients with hyperthyroidism or a history of hyperthyroidism, and reaching euthyroid state prior to conception. According to ATA guidelines, hyperthyroid women should be offered ablative (<sup>131</sup>I, surgery) or medical therapy, and conception is advised when the disease is controlled. Our results demonstrating higher incidences of foetal and neonatal thyroid dysfunction

in hyperthyroid mothers treated with ATD than in mothers who reached a remission after surgical or radioiodine treatment (31% and 11.5% *vs.* 6% and 6%, respectively;  $p < 0.001$ ) provide the rationale for offering ablative therapy prior to conception. Surgery should be elective in women with large goitres or high TRAb levels, while 131-I therapy seems optimal in other cases. Generally, 21% of children from the group of women with current or past Graves' hyperthyroidism demonstrated thyroid dysfunction during their foetal life, and 7% showed abnormal thyroid function during the neonatal period. The incidence of foetal thyroid dysfunction documented in our study was higher than the commonly reported 1–5% [3,27], but still consistent with the 19–25% documented by the authors who have performed US foetal monitoring [33, 35, 50]. The observed incidence of neonatal thyroid dysfunction was similar to the previously reported 1–16.5% [3, 25, 51, 52]. Our study confirmed the high sensitivity and value of foetal US monitoring in mothers affected by Graves' disease. Abnormal thyroid sonogram, namely, goitre with decreased echogenicity and increased vascularisation, turned out to be the most sensitive symptom of foetal thyroid dysfunction. It is of note that the same US abnormalities were observed in 85% of adult patients with Graves' disease [53]. We used the established foetal thyroid nomograms for the Polish population [31] in diagnosing foetal goitre. The nomograms differ slightly from those reported by other authors [30, 54, 55], probably due to mild iodine deficiency still observed in the population of Polish pregnant women [39, 56]. Decreased echogenicity and increased central blood flow in foetal thyroid were observed in each case of foetal hyperthyroidism. The size of foetal thyroid was within the upper normal limit (between the 90<sup>th</sup> and 95<sup>th</sup> percentiles) in 50% of cases, and thyroid enlargement was documented in the other 50%. Plausibly, intensive central blood flow in foetal thyroid was the earliest sign of foetal hyperthyroidism, preceding enlargement of the gland, but this observation should be confirmed in a larger study. Foetal goitre with various patterns of vascularisation, such as lack of increased blood flow (in two out of five patients, 40%), increased peripheral blood flow ( $n = 2$ , 40%) or increased central blood flow ( $n = 1$ , 20%), was observed in each case of foetal hypothyroidism. According to previous observations [26,35], foetal goitre seems to be the earliest and most accurate sign of foetal thyroid dysfunction resulting from maternal thyroid disease. Its sensitivity for foetal thyroid dysfunction was assessed at 92%, specificity at 100%, and PPV and NPV at 100% and 98%, respectively [35]. Increased central blood flow was observed in all cases of foetal hyperthyroidism and in 29% of cases of foetal hypothyroidism [35]. Goitre with increased

peripheral blood flow (57%) was the most characteristic US indication of foetal hypothyroidism. Abnormal foetal thyroid performance was the only US sign of foetal thyroid dysfunction in our material. According to other authors [35, 57], abnormal bone maturation and heart rate are both late and uncommon symptoms of foetal thyroid dysfunction, present in 36% and 14% of cases, respectively.

The lack of bone and heart abnormalities in the offspring of our patients might result from early recognition of foetal thyroid dysfunction. The high level of TRAbs, at least five-fold higher than the upper normal limit, and the presence of hyperthyroidism in the 3<sup>rd</sup> trimester, were the most characteristic maternal parameters that predisposed for foetal hyperthyroidism. The highly elevated maternal TRAbs were also noted in four (9.5%) cases of maternal Graves' disease that lacked maternal or foetal thyroid disturbances. This was probably associated with the well-known phenomenon of switching TSH receptor antibodies from stimulating to inhibiting activity [58, 59]. This finding points to the need to assess biological activity of the TSH receptor antibodies in some cases, especially in women who underwent ablative therapy. There is no correlation between maternal thyroid function and maternal serum TRAb concentration in such cases, and the impact of maternal TRAbs on the foetus is uncertain. Our opinion is consistent with other authors [60], who postulate performing TRAb and complementary thyroid stimulating immunoglobulin tests. Similar to previous studies [35], maternal ATD therapy, and low maternal serum TRAb and fT4 levels turned out to be the risk factors for foetal hypothyroidism in our material.

We are well aware that the lack of a uniform assessment of neonatal status by TSH, fT4 and fT3 measurements in cord blood constitutes a potential limitation of our study. Unfortunately, some of our patients delivered outside our unit and therefore neonatal thyroid function was assessed between the 1<sup>st</sup> and 3<sup>rd</sup> days of life. TSH concentration obtained in dried-blood spot testing protocols, performed after the first 48 hours of life as a screening for congenital hypothyroidism, was the only information about the neonatal thyroid status in some cases.

Nevertheless, our study did confirm the great value of foetal ultrasound monitoring in maternal Graves' disease with high serum TRAb levels and ATD therapy. This observation also certifies the value of our previously established age-dependent nomograms of foetal thyroid. Our experience emphasises the need for close interdisciplinary collaboration of endocrinologists, obstetricians, neonatologists and paediatricians in the management of pregnancies complicated by maternal Graves' disease.



## Conclusions

1. In cases of maternal Graves' disease, foetal thyroid dysfunction occurs more often than has been commonly assumed.
2. Foetal thyroid ultrasonography is a valuable tool in the early diagnosis and monitoring of the foetal thyroid status when a pregnancy is complicated by maternal Graves' disease.
3. The evaluation of biological activity of maternal TRAbs may be helpful in prenatal diagnosis in some cases, especially after previous ablative thyroid therapy.

## Acknowledgments

This study was supported by grants from the Scientific Committee of the Medical Centre of Postgraduate Education (no. 501-2-1-07-01/07 and no. 501-1-08-11/13).

## References

1. Kester MHA, Martinez de Mena R, Obregon MJ et al. Iodothyronine levels in the human developing brain: major regulatory roles of iodothyronine deiodinases in different areas. *J Clin Endocrinol Metab* 2004; 89: 3117–3128.
2. Orito Y, Oku H, Kubota S et al. Thyroid function in early pregnancy in Japanese healthy women: relation to urinary iodine excretion, emesis and fetal and child development. *J Clin Endocrinol Metab* 2009; 94: 1683–1688.
3. Krassas GE, Poppe K, Glinoe D. Thyroid function and human reproductive health. *Endocr Rev* 2010; 31: 702–755.
4. Karakosta P, Alegakis D, Georgiu V et al. Thyroid dysfunction and autoantibodies in early pregnancy are associated with increased risk of gestational diabetes and adverse birth outcomes. *J Clin Endocrinol Metab* 2012; 97: 4464–4472.
5. Medici M, de Rijke YB, Peeters RP et al. Maternal early pregnancy and newborn thyroid hormone parameters: the Generation R Study. *J Clin Endocrinol Metab* 2012; 97: 646–652.
6. Lazarus JH, Bestwick JP, Channon S et al. Antenatal thyroid screening and childhood cognitive function. *N Engl J Med* 2012; 366: 493–501.
7. Anselmo J, Cao D, Karrison T et al. Fetal loss associated with excess thyroid hormone exposure. *JAMA* 2004; 292: 691–695.
8. Lee YS, Loke KY, Ng SCY et al. Maternal thyrotoxicosis causing central hypothyroidism in infants. *J Paediatr Child Health* 2002; 38: 206–208.
9. Kempers MJE, van Trotsenburg ASP, van Rijn RR et al. Loss of integrity of thyroid morphology and function in children born to mothers with inadequately treated Graves' disease. *J Clin Endocrinol Metab* 2007; 92: 2984–2991.
10. Laurberg P, Bournaud C, Karmisholt J et al. Management of Graves' hyperthyroidism in pregnancy: focus on both maternal and foetal thyroid function, and caution against surgical thyroidectomy in pregnancy. *Europ J Endocrinol* 2009; 160: 1–8.
11. Clementi M, Di Gianantonio E, Cassina M et al. Treatment of hyperthyroidism in pregnancy and birth defects. *J Clin Endocrinol Metab* 2010; 95: E337–E341.
12. Stagnaro-Green A. Overt hyperthyroidism and hypothyroidism during pregnancy. *Clin Obstet Gynecol* 2011; 54: 478–487.
13. Haddow J, Palomaki GE, Allan WC et al. Maternal thyroid deficiency during pregnancy and subsequent neuropsychological development of the child. *N Engl J Med* 1999; 341: 549–554.
14. Männistö T, Väärasmäki M, Pouta A et al. Perinatal outcome of children born to mothers with thyroid dysfunction or antibodies: a prospective population-based cohort study. *J Clin Endocrinol Metab* 2009; 94: 772–779.
15. Su P-Y, Huang K, Hao I-H et al. Maternal thyroid function in the first twenty weeks of pregnancy and subsequent fetal and infant development: a prospective population-based cohort study in China. *J Clin Endocrinol Metab* 2011; 96:3234–3241.
16. Morreale de Escobar G, Obregón MJ, Escobar del Rey F. Is neuropsychological development related to maternal hypothyroidism or to maternal hypothyroxinemia? *J Clin Endocrinol Metab* 2000; 85: 3975–3987.
17. Morreale de Escobar G, Obregón MJ, Escobar del Rey F. Role of thyroid hormone during early brain development. *Europ J Endocrinol* 2004; 151: U25–U37.
18. Ausó E, Lavado-Autric R, Cuevas E et al. A moderate and transient deficiency of maternal thyroid function at the beginning of fetal neurogenesis alters neuronal migration. *J Clin Endocrinol Metab* 2004; 145: 4037–4047.
19. Glinoe D, Delange F. The potential repercussion of maternal, fetal, and neonatal hypothyroxinemia on the progeny. *Thyroid* 2000; 10: 871–887.
20. Pop VJ, Brouwers EP, Vader HL et al. Maternal hypothyroxinemia during early pregnancy and subsequent child development: a 3-year follow-up study. *Clin Endocrinol (Oxf)* 2003; 59: 282–288.
21. Kooistra L, Crawford S, van Baar AL et al. Neonatal effects of maternal hypothyroxinemia during early pregnancy. *Pediatrics* 2006; 117: 161–167.
22. Henrichs J, Bongers-Schokking JJ, Schenk JJ et al. Maternal thyroid function during early pregnancy and cognitive functioning in early childhood: the Generation R Study. *J Clin Endocrinol Metab* 2010; 95: 4227–4234.
23. Li Y, Shan Z, Teng W et al. Abnormalities of maternal thyroid function during pregnancy affect neuropsychological development of their children at 25–30 months. *Clin Endocrinol (Oxf)* 2010; 72: 825–829.
24. Finken MJJ, van Eijnsden M, Loomans EM et al. Maternal hypothyroxinemia in early pregnancy predicts reduced performance in reaction time tests in 5- to 6-year-old offspring. *J Clin Endocrinol Metab* 2013; 98: 1417–1426.
25. Abalovich M, Amino N, Barbour LA et al. Management of thyroid dysfunction during pregnancy and postpartum: an Endocrine Society Clinical Practice Guideline. *J Clin Endocrinol Metab* 2007; 92: S1–S47.
26. Stagnaro-Green A, Abalovich M, Alexander EK et al. Guidelines of the American Thyroid Association for the diagnosis and management of thyroid disease during pregnancy and postpartum. *Thyroid* 2011; 21: 1081–1125.
27. Hubalewska-Dydejczyk A, Lewiński A, Milewicz A et al. Management of thyroid diseases during pregnancy. *Endokrynol Pol* 2011; 62: 362–381.
28. De Groot L, Abalovich M, Alexander EK et al. Management of thyroid dysfunction during pregnancy and postpartum: an Endocrine Society clinical practice guideline. *J Clin Endocrinol Metab* 2012; 97: 2543–2565.
29. Bromley B, Frigoletto Jr FD, Cramer D et al. The fetal thyroid: normal and abnormal sonographic measurements. *J Ultrasound Med* 1992; 11: 25–28.
30. Achiron R, Rotstein Z, Lipitz S et al. The development of the foetal thyroid: in utero ultrasonographic measurements. *Clin Endocrinol* 1998; 48: 259–264.
31. Gietka-Czernel M, Dębska M, Kretowicz P et al. Fetal thyroid in two-dimensional ultrasonography: nomograms according to gestational age and biparietal diameter. *Europ J Obstet Gynecol Rep Biol* 2012; 162: 131–138.
32. Luton D, Fried D, Sibony O et al. Assessment of fetal thyroid function by colored Doppler echography. *Fetal Diagn Ther* 1997; 12: 24–27.
33. Volumenie JL, Polak M, Guibourdenche J et al. Management of fetal thyroid goiters: a report of 11 cases in a single perinatal unit. *Prenat Diagn* 2000; 20: 799–806.
34. Galan HJ, Pandipati S, Filly RA. Ultrasonograficzna ocena biometrii płodu oraz prawidłowy i nieprawidłowy wzrost płodu. W: Callen PW, Dębski A (ed.). *Ultrasonografia w położnictwie i ginekologii*. Elsevier, Urban and Partner, Wrocław 2010: 235–278.
35. Luton D, Le Gac I, Vuillard E et al. Management of Graves' disease during pregnancy: the key role of fetal thyroid monitoring. *J Clin Endocrinol Metab* 2005; 90: 6093–6098.
36. Hume R, Simpson J, Delahunty C et al. Human fetal and cord serum thyroid hormones: developmental trends and interrelationships. *J Clin Endocrinol Metab* 2004; 89: 4097–4103.
37. Guibourdenche J, Noël M, Chevenne D et al. Biochemical investigation of foetal and neonatal thyroid function using the ACS-180SE analyser: clinical application. *Ann Clin Biochem* 2001; 38: 520–526.
38. Ołtarzewski M, Szymborski J. Neonatal hypothyroid screening in monitoring of iodine deficiency and iodine supplementation in Poland. *J Endocrinol Invest* 2003; 26 (Suppl. 2): 27–31.
39. Gietka-Czernel M, Dębska M, Kretowicz P et al. Iodine status of pregnant women from central Poland ten years after introduction of iodine prophylaxis programme. *Endokrynol Pol* 2010; 61: 646–651.
40. Goodwin TM, Montoro M, Mestman JH et al. The role of chorionic gonadotropin in transient hyperthyroidism of hyperemesis gravidarum. *J Clin Endocrinol Metab* 1992; 75: 1333–1337.
41. Verberg ME, Gillott DJ, Al-Fardan N et al. Hyperemesis gravidarum, a literature review. *Hum Reprod Update* 2005; 11: 527–539.
42. Niebyl JR. Clinical practice. Nausea and vomiting in pregnancy. *N Engl J Med* 2010; 363: 1544–1550.
43. Grun JP, Meuris S, De Nayer P et al. The thyrotrophic role of human chorionic gonadotrophin (hCG) in the early stages of twin (versus single) pregnancies. *Clin Endocrinol (Oxf)* 1997; 46: 719–725.

44. Herman D, Domberg J, Graeber C et al. Comparison of a solid phase human-versus porcine-thyrotropin receptor-based immunoassay for the measurement of thyrotropin receptor antibodies in patients with thyroid diseases. *Exp Clin Endocrinol Diabetes* 2008; 116 (Suppl. 1): S59–S63.
45. Theodoraki A, Jones G, Parker J et al. Performance of a third-generation TSH-receptor antibody in a UK clinic. *Clin Endocrinol* 2011; 75: 127–133.
46. Diana T, Brown R, Bossowski A et al. Clinical relevance of thyroid-stimulating autoantibodies in pediatric Graves' disease — a multicenter study. *J Clin Endocrinol Metab* 2014; 11: jc20134026.
47. Pääkkilä E, Männistö T, Surcel HM et al. Maternal thyroid dysfunction during pregnancy and thyroid function of her child in adolescence. *J Clin Endocrinol Metab* 2013; 98: 965–972.
48. Laurberg P, Wallin G, Tallstedt L et al. TSH-receptor autoimmunity in Graves' disease after therapy with anti-thyroid drugs, surgery, or radioiodine: a 5-year prospective randomized study. *Eur J Endocrinol* 2008; 158: 69–75.
49. Chiappori A, Villalta D, Bossert I et al. Thyrotropin receptor autoantibody measurement following radiometabolic treatment of hyperthyroidism: comparison between different methods. *J Endocrinol Invest* 2010; 33: 197–201.
50. Cohen O, Pinhas-Hamiel O, Sivan E et al. Serial in utero ultrasonographic measurements of the fetal thyroid: a new complementary tool in the management of maternal hyperthyroidism in pregnancy. *Prenat Diagn* 2003; 23: 740–742.
51. Mitsuda N, Tamaki H, Amino N et al. Risk factors for developmental disorders in infants born to women with Graves' disease. *Obst Gynecol* 1992; 80: 359–364.
52. Syrenicz A. Nadczynność tarczycy. W: Syrenicz A. (ed.). *Endokrynopatie w ciąży*. Wydawnictwo Pomorskiego Uniwersytetu Medycznego w Szczecinie, Szczecin 2011: 138–145.
53. Szczepanek-Parulska E, Ruchała M, Sowiński J. *Choroba Gravesa-Basedowa*. W: Ruchała M. (ed.). *Atlas ultrasonografii tarczycy w aspekcie praktycznym*. Termedia Wydawnictwa Medyczne, Poznań 2012: 131–137.
54. Ranzini AC, Ananth CV, Smulian JC et al. Ultrasonography of the fetal thyroid. Nomograms based on biparietal diameter and gestational age. *J Ultrasound Med* 2001; 20: 613–617.
55. Bernardes LS, Ruano R, Sapienza AD et al. Nomograms of fetal thyroid measurements estimated by 2-dimensional sonography. *J Clin Ultrasound* 2008; 36: 193–199.
56. Milewicz T, Czyżewicz M, Stochmal E et al. Intake of iodine-containing multivitamin preparations by pregnant women from the Krakow region of Poland. *Endokrynol Pol* 2011; 62: 309–315.
57. Nachum Z, Rakower Y, Weiner E et al. Graves' disease in pregnancy: prospective evaluation of a selective invasive treatment protocol. *Am J Obstet Gynecol* 2003; 189: 159–65.
58. Kung AWC, Jones BM. A change from stimulatory to blocking antibody activity in Graves' disease during pregnancy. *J Clin Endocrinol Metab* 1998; 83: 514–518.
59. Kung AWC, Lau KS, Kohn LD. Epitope mapping of TSH receptor- blocking antibodies in Graves' disease that appear during pregnancy. *J Clin Endocrinol Metab* 2001; 86: 3647–3653.
60. Barbesino G, Tomer Y. Clinical utility of TSH receptor antibodies. *J Clin Endocrinol Metab* 2013; 98: 2247–2255.