



# Chromogranin A (CgA) in adrenal tumours

## Chromogranina A (CgA) w guzach nadnerczy

Piotr Glinicki, Wojciech Jeske, Lucyna Bednarek-Papierska, Anna Kasperlik-Zaluska, Elżbieta Rosłonowska, Małgorzata Gietka-Czernel, Wojciech Zgliczyński

Department of Endocrinology, The Centre of Postgraduate Medical Education, Warsaw, Poland

### Abstract

**Introduction:** Adrenal tumours can produce specific hormones and cause characteristic symptoms. The majority of adrenal incidentalomas are clinically silent, but some may be malignant or pose other potential threats to life.

Chromogranin A (CgA) is the main, nonspecific marker of neuroendocrine tumours (NET). In the adrenals, CgA is produced by chromaffin cells localised in the adrenal medulla. Therefore its measurement in blood might be used as a screening test for pheochromocytoma after the exclusion of other various causes of an increased CgA level.

The aim of our study was to investigate plasma CgA concentration in various adrenal tumours.

**Material and methods:** EDTA<sub>2</sub>K plasma samples were obtained from 195 patients with adrenal tumours and from 50 blood donors. CgA was measured in plasma-EDTA<sub>2</sub>K by immunoradiometric (IRMA) method.

**Results:** In the majority of patients with adrenal tumours not derived from neuroendocrine cells (chromaffin cells), except those with significant hypercortisolemia and some patients with adrenal carcinoma, the plasma CgA concentrations were below the cut-off value. In adrenal tumours derived from chromaffin cells (pheochromocytoma), CgA levels were markedly elevated.

**Conclusion:** In differential diagnosis of adrenal tumours, non-increased CgA level might be useful initial screening evidence for the exclusion of pheochromocytoma. (*Endokrynol Pol* 2013; 64 (5): 358–362)

**Key words:** adrenal tumours, CgA, chromogranin A, neuroendocrine tumours, NET, pheochromocytoma

### Streszczenie

**Wstęp:** Guzy nadnercza mogą produkować specyficzne hormony i powodować charakterystyczne objawy kliniczne, ale przeważająca część guzów, zwłaszcza typu incydentaloma, jest niema klinicznie, chociaż część z nich może mieć charakter złośliwy albo stanowić inne potencjalne zagrożenie dla życia. Chromogranina A (CgA) jest głównym, niespecyficznym markerem guzów neuroendokrynych (NET). Jest ona produkowana także między innymi przez komórki chromafinowe rdzenia nadnerczy i jej pomiar we krwi mógłby być użytecznym testem przesiewowym dla *pheochromocytoma* po wykluczeniu innych możliwych przyczyn podwyższonego stężenia CgA. Celem naszej pracy było zbadanie osoczowego stężenia CgA w różnych guzach nadnerczy.

**Materiał i metody:** Materiałem do badania były próbki osocza (EDTA K) pozyskane od 195 pacjentów skierowanych z powodu guza nadnercza oraz od 50 dawców krwi. Stężenie CgA oznaczono w osoczu EDTA K metodą immunoradiometryczną (IRMA).

**Wyniki:** Stężenie CgA w większości przypadków guzów nie wywodzących się z komórek neuroendokrynych nadnercza oraz w części przypadków raka nadnerczy, z wyjątkiem tych ze znaczącą hiperkortyzolemią, było poniżej wartości *cut-off*. W guzach wywodzących się z komórek chromafinowych nadnercza (*pheochromocytoma*) obserwowano znacząco podwyższone stężenia CgA.

**Wnioski:** We wstępnej diagnostyce różnicowej guzów nadnerczy, stwierdzenie prawidłowego stężenia CgA może być pomocnym markerem dla wykluczenia *pheochromocytoma*. (*Endokrynol Pol* 2013; 64 (5): 358–362)

**Słowa kluczowe:** CgA, chromogranina A, guzy nadnerczy, guzy neuroendokryne, NET, *pheochromocytoma*

This work was supported by The Centre of Postgraduate Medical Education grant n° 502-1-08-01-12 and 506-1-08-01-13.

### Introduction

Adrenal tumours can produce specific hormones and cause characteristic symptoms. The majority of incidentally found adrenal tumours are clinically silent, however some of them may be malignant or pose other potential threats to life [1–3].

Chromogranin A (CgA) is the main, nonspecific marker of neuroendocrine tumours (NET) [4, 5]. It is a hydrophilic glycoprotein belonging to the chromogranin/

/secretogranin family - acid secretory proteins which are co-stored in secretory granules and co-released with resident hormones from neuroendocrine cells [6]. In adrenals, CgA is produced by chromaffin cells localised in the adrenal medulla and released into the blood. Therefore its measurement might be used as a screening test for pheochromocytoma after the exclusion of other various causes of an increased CgA level [7, 8].

The aim of our study was to investigate plasma CgA concentration in various adrenal tumours.



Piotr Glinicki, M. Sc., Department of Endocrinology, The Centre of Postgraduate Medical Education, Bielański Hospital, Ceglowska St. 80, 01-809 Warsaw, Poland, tel.: +48 22 569 02 93, fax: +48 22 834 31 31, e-mail: glinicki@cmkp.edu.pl

## Material and methods

We investigated 195 patients (62 males and 133 females; mean  $\pm$  SD age  $57 \pm 14$ , range 18–82 years) with adrenal masses which, mostly, were incidentally discovered during imaging procedures: ultrasonography (USG), computed tomography (CT), or magnetic resonance imaging (MRI).

Routine hormonal determinations included: ACTH, cortisol (before and after 1 mg dexamethasone suppression test- DST), urine free cortisol, 17-OHCS and 17-KS in 24 hour urine, (and if indicated) androstendione, DHEA-S, and 17-hydroxyprogesterone. In patients with hypertension: concentration of aldosterone in serum and 24 hour urine, plasma renin activity (PRA) after a night's rest in supine position (0hr) and after two hours in an upright position (2hr), metanephrines (24hr urine). CT (or MRI) of adrenals with i.v. contrast was performed in all patients and 123-iodine-labelled metaiodobenzylguanidine (123-I-MIBG) scintigraphy only in some patients suspected of pheochromocytoma. The control group consisted of 50 blood donors (mean  $\pm$  SD age  $33 \pm 9$ , range 19–52 years).

Venous blood was centrifuged (ten minutes, 3,500 rpm) and plasma (EDTA<sub>2</sub>K) was frozen at  $-30^{\circ}\text{C}$  and stored until assayed.

Chromogranin A was measured by the immunoradiometric method (CIS bio, France). Analytical sensitivity was 1.5 ng/mL. The cut-off value suggested by the manufacturer for plasma-EDTA<sub>2</sub>K is 150 ng/mL. Intra-assay CV values were: 6% for 30 ng/mL, 3.8% for 144 ng/mL, and 2.2% for 996 ng/mL. Inter-assay CV values were: 8.5% for 29 ng/mL, 5.7% for 144 ng/mL and 5.3% for 996 ng/mL.

Metanephrines were measured by the high-performance liquid chromatography (HPLC) method in 24hr urine (at least two times) by a local laboratory. Reference value was: 100–1,000  $\mu\text{g}/24\text{hr}$ .

The study was approved by the Bioethics Committee of The Centre of Postgraduate Medical Education.

Data is expressed as median and as a range. The Kruskal-Wallis test, followed by Dunn's post-hoc test and the multiple Mann-Whitney U-test, were performed to estimate differences between groups. A p-value of  $< 0.05$  was considered to be significant and  $p < 0.001$  highly significant. All statistical analyses were performed using statistical software (PQStat ver. 1.4.2.324).

## Results

In tumours derived from adrenal chromaffin cells, pheochromocytomas ( $n = 8$ ), the median of CgA value was 660 ng/mL (range 266–1,478 ng/mL). The main findings from patients with confirmed pheochromo-

Table I. Patients with confirmed pheochromocytoma

Tabela I. Pacjenci z potwierdzonym pheochromocytoma

N°	Sex/age	CgA [ng/mL]	Metanephrines (urine) [ $\mu\text{g}/24\text{ h}$ ]	Confirmation
1.	M/63	428	1,500	123-I-MIBG scintigraphy Histopathology
2.	M/56	882	1,208	Histopathology
3.	F/57	297	1,572	Histopathology
4.	F/28	266	1,458	Histopathology
5.	F/71	962	1,750	Histopathology
6.	M/59	438	2,916	Histopathology
7.	F/46	1,069	6,974	123-I-MIBG scintigraphy Histopathology
8.	F/53	1,478	24,848	Histopathology

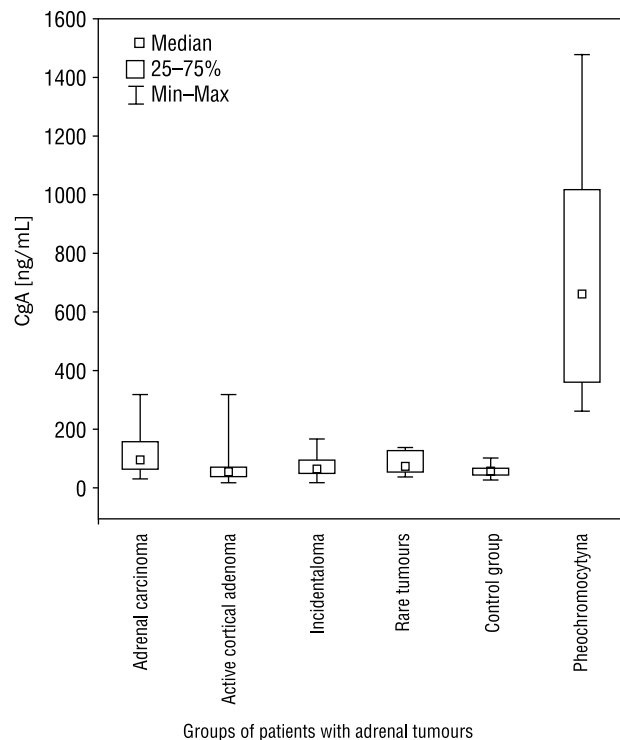


Figure 1. Plasma CgA concentration in patients with pheochromocytoma, active cortical adenomas, silent incidentalomas, adrenal carcinomas and in the control group

Rycina 1. Stężenie wyników osoczowego CgA w grupie pacjentów z pheochromocytoma, czynnymi i nieczynnymi guzami kory nadnerczy, w rakach nadnerczy oraz w grupie kontrolnej

cytoma are presented in Table I. Plasma CgA levels were significantly higher in patients with pheochromocytoma ( $p < 0.0001$ ) in relation to another group of patients with adrenal tumours (Fig.1). Notably, in

Table II. CgA in adrenal tumours

Tabela II. CgA w guzach nadnerczy

CgA in adrenal tumours	n	Median	Range (min/max) [ng/mL]	p value
Hormonally active medullary adenoma:				
Pheochromocytoma	8	660	266–1,478	
Hormonally active cortical adenomas:				
Cortisol				p < 0.0001*
CgA ≥ cut-off	3	225	150–319	
CgA < cut-off	13	53	21–127	
Aldosterone (aldosteronoma or adrenal hyperplasia)	14	47	20–158	
Androgens	8	51	31–66	
Mixed adenomas (cortisol/androgens)	2	63	54–72	
Adrenal carcinoma:				
with hypercortisolaemia	7**	96	54–319	p < 0.0001*
without hypercortisolaemia	13	96	34–196	
Incidentaloma (silent hormonally)	113	68	27–167	p < 0.0001*
Rare tumours of adrenal gland:				
Angiomyolipoma	12	74	40–138	p < 0.0002*
Myelolipoma				
Metastasis				
Paraganglioma (location outside of the adrenal)				
Control group (blood donors)	50	59	23–153	p < 0.0001*

\*pheochromocytoma v. non-chromaffin adrenal tumours [Mann-Whitney U-test]; \*\*in three of seven cases with marked hypercortisolaemia, CgA appeared markedly higher (range 152–319 ng/mL)

two observed cases of paraganglioma located outside the adrenal glands, CgA levels were not increased. In the control group consisting of blood donors (n = 50), the mean ± SD plasma CgA level was 59 ± 18 ng/mL (range 23–153 ng/mL).

Excluding the cases of pheochromocytoma, the median of plasma CgA concentrations in hormonally active adenomas (n = 40) was 54 ng/mL (range 20–319 ng/mL). In this group (n = 3), higher concentrations of CgA (range 150–319 ng/mL) were noted mainly in some of the adenomas secreting cortisol. In adrenal carcinoma (n = 20), the median of CgA was 96 ng/mL (range 34–319 ng/mL) and, again, in three of them with marked hypercortisolaemia, CgA also appeared markedly higher (range 152–319 ng/mL). In 113 cases with hormonally silent incidentalomas, the median concentration of CgA was 68 ng/mL (range 20–167 ng/mL); in other rare tumours of adrenal glands (n = 12) (myelolipoma, angiomyolipoma, paraganglioma and metastasis of other neoplasms), the median was 74 ng/mL (range 40–138 ng/mL). The results are presented in Table II.

## Discussion

Adrenal incidentaloma, usually defined as an adrenal mass unexpectedly detected by imaging procedures (USG, CT, MRI), can be hormonally silent or active and benign or malignant. Active adrenocortical adenomas may secrete cortisol, androgens, or aldosterone [9].

Pheochromocytoma, a catecholamine-producing tumour, with preferential localisation in the adrenal medulla, occurs in 0.1–0.6% patients of arterial hypertension [10, 11] and in about 2–5% of patients with adrenal incidentaloma [12]. Biochemical screening of pheochromocytoma in daily practice is based on 24-hour urine metanephrines and catecholamines. Recently CgA measurement was proposed as an additional means of investigation in this pathology. According to Giovanella et al. [13], sensitivity and specificity of CgA in pheochromocytoma is 92–96%. Unger et al. however reported lower sensitivity and specificity (around 74%) for a CgA threshold value of 215 µg/L [14].

In our study, the CgA concentration was above the cut-off value in eight observed cases of pheochromo-

cytoma and ranged 266–1,478 ng/mL (mean  $\pm$  SD 727  $\pm$  436 ng/mL). In the study of Bílek et al., who used the same CgA immunoradiometric method, the mean concentration of plasma CgA  $\pm$  SD in patients with pheochromocytoma was 635  $\pm$  451 ng/mL [15]. In interpreting the raised CgA level, we must consider the possible influence on CgA of some drugs (mainly proton pump inhibitors) and coincidental diseases (for example: atrophic gastritis, renal or hepatic insufficiency, and prostatic carcinoma) [7]. It is important to note that pheochromocytoma should be excluded before any invasive diagnostic or therapeutic procedure is undertaken to avoid the development of catecholaminergic crisis. It has been reported that in clinically silent cases of pheochromocytoma, after the administration of glucocorticoids in a dose exceeding 1 mg of dexamethasone, there is a potential threat of severe hypertensive crisis, with life-threatening symptoms (low dose DST — 1 mg orally — has not been associated with such crisis [16]).

Therefore, special care is necessary while planning the performance of high dose dexamethasone suppression tests in insufficiently diagnosed cases. Similar caution is advised when prescribing glucocorticoids as a pre-treatment before CT or MRI in patients allergic to contrast dye. For the above reasons, an additional test helping to confirm or exclude pheochromocytoma among patients with an asymptomatic adrenal tumour seems warranted.

In two cases of incidentaloma with concomitant paraganglioma, localised in one case very near the right adrenal gland, and in the second case in the pericardium, the levels of CgA were below the cut-off value. According to Seregni et al. [17], CgA levels are elevated only in 40–50% of extra-adrenal paraganglioma tumours.

Most adrenal incidentalomas are benign adrenal adenomas (they account for about 80–87% of all tumours), and for the most part they are non-functioning [18]. Cortisol secreting adenomas are the most common functional tumours [19].

In our study, in the majority of silent and hormonally active adenomas (secreting cortisol, androgens or aldosterone), adrenal carcinomas, and in some rare tumours (angiomyolipoma, myelolipoma, metastasis of various neoplasms), the CgA levels were below or around the cut-off value. A similar observation was presented in the study performed by Giovanelli [20]. In some cases of hormonally active adenomas and adrenal carcinomas secreting large amounts of cortisol, CgA levels were above the cut-off value, but not as high as in the observed cases of pheochromocytoma.

CgA measurements were also considered as a possible useful parameter, instead of or in addition to cortisol, in assessing the selectivity in adrenal venous

sampling in cases of primary aldosteronism. Seccia et al., however, does not support such a method, perhaps with the exception of rare cases of a tumour secreting both aldosterone and cortisol [21].

Chromogranin A is usually included in a panel of immunohistochemical markers for studying operated adrenal tumours. In a comprehensive study performed by Weissferdt et al. [22], however, only two of 40 cases of adrenal cancer showed positivity for CgA. Positive immunohistochemical staining for CgA was also reported in an extremely rarely diagnosed adrenocortical oncocytoma [23].

## Conclusions

- In the majority of patients with adrenal tumours not derived from neuroendocrine cells (chromaffin cells), and in some with adrenal carcinoma, except those with significant hypercortisolaemia, plasma CgA concentrations were below the cut-off value.
- In adrenal tumours derived from chromaffin cells (pheochromocytoma), CgA levels were markedly increased.
- In preliminary differential diagnosis of adrenal tumours, a non-increased CgA level might be useful screening evidence for the exclusion of pheochromocytoma.

## References

1. Kasperlik-Zaluska AA, Otto M, Cichocki A et al. 1,161 patients with adrenal incidentalomas: indications for surgery. *Langenbecks Arch Surg* 2008; 393: 121–126.
2. Kasperlik-Zaluska AA, Otto M, Cichocki A et al. Incidentally discovered adrenal tumors: a lesson from observation of 1444 patients. *Horm Metab Res* 2008; 40: 338–341.
3. Ng VW, Ma RC, So WY et al. Evaluation of functional and malignant adrenal incidentalomas. *Arch Intern Med* 2010; 170: 2017–2020.
4. Kos-Kudła B, Bolanowski M, Handkiewicz-Junak D et al. Diagnostic and therapeutic guidelines for gastrointestinal tumors (recommended by the Polish Network of Neuroendocrine Tumors) *Endokrynol Pol* 2008; 59: 41–56.
5. Nehar D, Lombard-Bohas C, Olivieri S et al. Interest of chromogranin A for diagnosis and follow-up of endocrine tumours. *Clin Endocrinol* 2004; 60: 644–652.
6. Bernini GP, Moretti A, Borgioli M et al. Plasma and tissue chromogranin in patients with adrenocortical adenomas. *J Endocrinol Invest* 2004; 27: 821–825.
7. Glinicki P, Jeske W. Chromogranin A (CgA) — the influence of various factors in vivo and in vitro, and existing disorders on its concentration in blood. *Endokrynol Pol* 2010; 61: 384–387.
8. Glinicki P, Kapuścińska R, Jeske W. The differences in chromogranin A (CgA) concentrations measured in serum and in plasma by IRMA and ELISA methods. *Endokrynol Pol* 2010; 61: 346–350.
9. Aron D, Terzolo M, Cawood TJ. Adrenal incidentalomas. *Best Pract Res Clin Endocrinol Metab* 2012; 26: 69–82.
10. Belowska-Bień K, Kucharski W, Janczak D et al. Pheochromocytoma of the adrenal gland selectively secreting dopamine — a case report. *Endokrynol Pol* 2012; 63: 391–395.
11. Stolk RF, Bakx C, Mulde J et al. Is the excess cardiovascular morbidity in pheochromocytoma related to blood pressure or to catecholamines? *J Clin Endocrinol Metab* 2013; 98: 1100–1106.
12. Algeciras-Schimnich A, Preissner CM, Young WF et al. Plasma chromogranin A or urine fractionated metanephrines follow-up testing improves the diagnostic accuracy of plasma fractionated metanephrines for pheochromocytoma. *J Clin Endocrinol Metab* 2008; 93: 91–95.

13. Giovannella L, Ceriani L, Balerna M et al. Diagnostic value of serum chromogranin A combined with MIBG scintigraphy in patients with adrenal incidentalomas. *Q J Nucl Med Mol Imaging* 2008; 52: 84–88.
14. Unger N, Hinrichs J, Deutschbein T et al. Plasma and urinary metanephrines determined by an enzyme immunoassay, but not serum chromogranin A for the diagnosis of pheochromocytoma in patients with adrenal mass. *Exp Clin Endocrinol Diabetes* 2012; 120: 494–500.
15. Bilek R, Šafařík L, Ciprova V et al. Chromogranin A, a member of neuroendocrine secretory proteins as a selective marker for laboratory diagnosis of Pheochromocytoma. *Physiol Res* 2008; 57 (Suppl. 1): 171–179.
16. Rosas AL, Kasperlik-Zaluska AA, Papierska L et al. Pheochromocytoma crisis induced by glucocorticoids: a report of four cases and review of literature. *Eur J Endocrinol* 2008; 158: 423–429.
17. Seregni E, Ferrari L, Bajetta W et al. Clinical significance of blood chromogranin A measurement in neuroendocrine tumors. *Ann Oncol* 2001; 12 (Suppl. 2): 69–72.
18. Terzolo M, Stigliano A, Chiodini I et al. AME position statement on adrenal incidentaloma. *Eur J Endocrinol* 2011; 164: 851–870.
19. Terzolo M, Bovio S, Reimondo G. Management of adrenal incidentaloma. *Best Pract Res Clin Endocrinol Metab* 2009; 23: 233–243.
20. Giovannella L. Serum chromogranin-A assay in differential diagnosis of incidentally discovered adrenal masses. *Anticancer Res* 2005; 25: 1547–1550.
21. Seccia TM, Miotto D, De Toni R et al. Chromogranin A measurement for assessing the selectivity of adrenal venous sampling in primary aldosteronism. *J Clin Endocrinol Metab* 2011; 96: E825–E829.
22. Weissferdt A, Phan A, Suster S et al. Adrenocortical carcinoma: a comprehensive immunohistochemical study of 40 cases. *Appl Immunohistochem Mol Morphol* 2013 doi:10.1097/PAI.06013e31828a96cf.
23. Rutkowska J, Bandurska-Stankiewicz E, Kuglarz E et al. Adrenocortical oncocytoma - a case report. *Endokrynol Pol* 2012; 63: 308–311.