Endokrynologia Polska
Tom/Volume 64; Numer/Number 1/2013
ISSN 0423–104X

Current concepts in the diagnosis and management of poorly differentiated gastrointestinal neuroendocrine carcinomas

Aktualne poglądy na diagnostykę i leczenie niskozróżnicowanych raków neuroendokrynnych przewodu pokarmowego

Anna Koumarianou[1], Eleftherios Chatzellis[2], Georgios Boutzios[2], Nikolaos Tsavaris[2], Gregory Kaltsas[2]

[1]*Second Department of Internal Medicine Propaedeutic and Research Institute, Attikon University Hospital, Athens Greece*
[2]*Department of Pathophysiology, National University of Athens, Athens, Greece*

Abstract

Poorly differentiated neuroendocrine carcinomas (PDNEC) are rare tumours that can originate from any site of the gastrointestinal tract exhibiting an overall aggressive behaviour that may vary between tumours according to the degree of cellular proliferation. The majority of PDNEC are locally advanced or metastatic at presentation, and are only infrequently associated with secretory hormonal syndromes. PDNEC exhibit aggressive histological features (high mitotic rate, high Ki67 labelling index and presence of necrosis) and are further subdivided into two morphological subgroups, small and large cell variants. As PDNEC express somatostatin receptors less frequently, somatostatin receptor scintigraphy is usually negative, whereas ^{18}F-fluorodeoxyglucose positron emission tomography appears to be the best method of evaluating disease spread and guiding further treatment. PDNEC have traditionally been treated similarly to small cell lung carcinoma, although they show a number of different clinical and histopathologic features. First line systemic chemotherapy with a platinum-based agent and etoposide is used for patients with metastatic disease, leading to variable response rates that are often of relative short duration. Sequential or concurrent chemoradiation is recommended for patients with locoregional disease. In patients with localised disease, complete surgical resection should be offered followed by adjuvant treatment (chemotherapy with or without radiotherapy); the value of neoadjuvant chemotherapy has not been evaluated as yet. The role of second line therapies is evolving, with temozolomide being a promising agent. However, the majority of data regarding PDNEC is hampered by the small number of series and their retrospective nature, making it important that multicentre co-operative studies be performed. **(Endokrynol Pol 2013; 64 (1): 60–72)**

Key words: *gastrointestinal (GI), poorly differentiated neuroendocrine carcinomas (PDNEC), Ki67 labelling index, etoposide, cisplatin, temozolomide*

Streszczenie

Niskozróżnicowane raki neuroendokrynne (PDNEC, *poorly differentiated neuroendocrine carcinomas*) to rzadkie nowotwory, które mogą wywodzić się z dowolnego miejsca w przewodzie pokarmowym, cechując się ogólnie agresywnym przebiegiem uzależnionym od stopnia nasilenia proliferacji komórek nowotworowych. Większość przypadków PDNEC w momencie rozpoznania stanowią nowotwory miejscowo zaawansowane lub przerzutowe i rzadko towarzyszą im zespoły chorobowe związane z wydzielanymi przez te nowotwory hormonami. PDNEC cechują się agresywnym obrazem histopatologicznym (duża liczba figur podziału, wysoki wskaźnik aktywności proliferacyjnej Ki67 i obecność martwicy) i wyróżnia się wśród nich dwie podgrupy morfologiczne — odmianę drobnokomórkową i wielkokomórkową. Ponieważ w PDNEC rzadziej stwierdza się ekspresję receptorów somatostatynowych, scyntygrafia receptorów somatostatynowych zwykle daje negatywne wyniki, natomiast pozytonowa tomografia emisyjna z ^{18}F-fluorodeoksyglukozą wydaje się być najlepszą metodą do oceny rozległości choroby i pomocną przy podejmowaniu decyzji dotyczących dalszego leczenia. PDNEC zwykle leczy się podobnie do drobnokomórkowego raka płuca, choć nowotwory te wykazują szereg różnic klinicznych i histopatologicznych. U pacjentów z chorobą rozsianą stosuje się układową chemioterapię pierwszego rzutu obejmującą pochodną platyny i etopozyd. Odsetek odpowiedzi na leczenie jest różny, a sama odpowiedź utrzymuje się względnie krótko. U pacjentów z chorobą lokoregionalną zaleca się stosowanie sekwencyjnej lub jednoczasowej chemioradioterapii. U pacjentów z chorobą zlokalizowaną stosuje się radykalne leczenie chirurgiczne z chemio- lub chemioradioterapią uzupełniającą. Nie ustalono dotychczas roli chemioterapii neoadiuwantowej. Schematy leczenia drugiego rzutu na razie ewoluują; obiecujący wydaje się być temozolomid. Wartość większości danych dotyczących PDNEC jest jednak ograniczona niezbyt dużą liczbą przypadków oraz ich retrospektywnym charakterem. Dlatego też tak ważne byłoby przeprowadzenie wieloośrodkowych badań kooperacyjnych. **(Endokrynol Pol 2013; 64 (1): 60–72)**

Słowa kluczowe: *przewód pokarmowy, niskozróżnicowane raki neuroendokrynne (PDNEC), wskaźnik aktywności proliferacyjnej Ki67, etopozyd, cisplatyna, temozolomid*

Introduction

Poorly differentiated neuroendocrine carcinomas (PDNEC) of the gastrointestinal (GI) tract are rare tumours composed of highly atypical, small-to-medium-sized tumour cells associated with necrosis, prominent angioinvasion, and/or perineural invasion [1]. Traditionally, small cell and the less common large cell lung carcinomas (SCLC and LCLC respectively), constitute the commonest sites of origin of PDNC; however, following

Gregory Kaltsas M.D., FRCP, Department of Pathophysiology, National University of Athens, Mikras Asias 75, 11527, Athens, Greece, tel.: +30 210 746 25 13, fax: +30 210 746 26 64, e-mail: gkaltsas@endo.gr

the newly introduced classification systems, carcinomas with prominent neuroendocrine (NE) differentiation can be detected in virtually all tissues [2]. PDNEC of the GI (GI-PDNEC) tract constitute the commonest location, accounting for 35–55% of all extra-pulmonary PDNEC mainly located in the oesophagus, stomach, pancreas and colon, but in up to 30% of GI-PDNEC no primary localisation is found [3, 4]. The recent World Health Organisation (WHO) classification system, along with others such as that of the European Neuroendocrine Tumour Society (ENETS), have highlighted the distinct nature of these tumours and the need to be distinguished from mixed exocrine-endocrine and exocrine tumours that contain only small numbers of endocrine cells [1, 4, 5]. Overall, the prognosis of GI-PDNEC is poor compared to other gastro-enteropancreatic neuroendocrine tumours (GEP-NETs) that, in their great majority, are well differentiated tumours (WDNET) exhibiting significantly high 5- and 10-year survival rates even in the presence of metastatic disease [6]. However, recent studies have shown that even within the group of PDNEC, clinical presentation, response to treatment and overall prognosis, although generally poor, may substantially differ between tumours [1, 3, 7–9].

Due to the rarity of GI-PDNEC there are very few large studies regarding their epidemiology, clinical presentation, genetic background, histopathology, natural history and appropriate treatment [1, 3, 8–12]. Only recently a comprehensive multicentre retrospective study has provided some consistent data confirming their overall poor prognosis and also verified their heterogeneity [7].

In this review, we aim to present currently existing data regarding GI-PDNEC in an attempt to provide evidence-based information, when present, and establish a basis for the registration of these tumours.

Epidemiology and histopathologic features

Epidemiology

Extra-pulmonary PDNEC are rare tumours that can originate anywhere in the GI tract, with a preponderance in areas of squamous GI epithelium such as the oesophagus and anus [13]; in the jejunum and ileum these tumours represent only 1% of all NETs [13]. Before the introduction of recently devised classification systems, previous studies have regarded extra-pulmonary SCC as uncommon malignant neoplasms with an incidence of 0.1–0.4% in the USA, accounting for 2.5–5.0% of all SCC [3, 11]. Based on the previous classifications, approximately 544 cases had been reported and analysed in a comprehensive older review [3,14]. In a more recent analysis of the Surveillance, Epidemiology and End Results (SEER) database, GI-PDNEC were found to have an incidence of $2/10^6$ inhabitants/year [7, 8]. However, in these studies, mixed tumours with some neuroendocrine component were also included and there was no prospective registration of these malignancies. A large multicentre prospective study from Italy employing recent classification systems evaluated several clinico-pathological parameters in 297 patients with pancreatic NETs (pNETs) and confirmed that PDNEC of the pancreas are indeed rare neoplasms, constituting only 7.7% of the total cases of pNETs [15]. In the same cohort, the majority of pancreatic PDNEC were non-functioning (95%) and, in agreement with the aggressive nature of this disease, were diagnosed at an advanced stage (39% with Stage III and 61% with stage IV disease) [15]. Furthermore, studies including larger numbers of patients have indicated that the relative heterogeneity of prognosis and response to treatment of these tumours is probably related to distinct clinico-pathological features such as the site of origin of the primary tumour, the value of Ki67 labelling (LI), and the expression of somatostatin receptors (sstr) [7, 16].

Due to their rarity, these tumours were initially considered to be similar to SCLC as they share common histopathologic features and also exert an aggressive behaviour [10, 13]. However, several studies have shown some differences at the molecular level, particularly as the apoptotic marker Bcl-2 has been found to be overexpressed in approximately 75–95% of patients with SCLC compared to 33% in GI-PDNEC patients [3]. In addition, unlike SCLC, extra-pulmonary PDNEC show retention of both arms of Chromosome 3 [12]. Since such cytogenetic differences between these tumours do exist, clinical features and outcome following the same treatment could also exhibit substantial differences [1,9]. Indeed several studies have tried to directly compare several features of pulmonary and extra-pulmonary PDNEC, demonstrating specific differences [3, 11, 14] (Table I).

Histopathologic and genetic features

PDNEC have been previously defined as poorly differentiated endocrine carcinomas in order to delineate their difference from the majority of GEP-NETs that are well differentiated and slowly growing tumours [6]. The concept of differentiation is based on the grade (G) of the tumours, although there are subtle differences between these two entities [2]. Differentiation refers to the extent to which the neoplastic cells resemble their non-neoplastic counterparts; WDNETs exhibit characteristic organoid arrangements of the tumour cells, with nesting, trabecular or gyriform patterns [1,2,9]. The cells are relatively uniform, producing abundant neurosecretory granules, as shown by the strong and diffuse immunoexpression of neuroendocrine markers

Table I. *Differences between pulmonary and extrapulmonary PDNEC*
Tabela I. *Różnice między PDNEC w lokalizacji płucnej i pozapłucnej*

	Extrapulmonary PDNEC	Small cell lung cancer	Large cell lung cancer
Median age at presentation	62 years [3, 7, 10]	60 years [60]	60 years [61]
Gender	Males more common [3, 7, 10]	Males more common but tend to become equal [62]	Male more common [63]
Past medical and family history	No associations recorded	Other heart or lung diseases related to smoking may coexist. No hereditary factors	No associations recorded
Symptoms	Most commonly weight loss, abdominal pain and obstructive symptoms [3]	Dyspnoea, cough, superior vena cava syndrome, hoarseness, stridor, dysphagia [64]	Haemoptysis, chest pain, dyspnoea and cough [64]
Para-neoplastic syndrome	Usually absent	Cushing's syndrome, syndrome of inappropriate secretion of antidiuretic hormone, Eaton-Lambert myasthenic syndrome [64]	Para-neoplastic syndromes are absent [65]
Alcohol / smoking	No smoking history	Smoking is the most common cause identified [66]	Smoking [61]
Staging system	TNM staging [64]	7th edition TNM system, limited/ extended disease [64], IASLC [64]	7th edition TNM system *Edge* [64]
Work up	Total body CT scans, bone scan, ^{18}F-FDG PET [13]	Total body CT scans, bone scan, baseline laboratory evaluation [64]	Total body CT scans, bone scan, baseline laboratory tests, ^{18}F-FDG PET [64]
Origin	Any GI tract	Centrally located [64]	Peripherally located [61]
Genetic profile	Abnormal expression of p53, Rb, bcl-2, p27 [24, 67]	Expression of tumour suppressor genes (e.g. p53) and protoncogenes (e.g. Bcl-1, IGF-1R) is altered [68]	Activation of the c-met pathway [69]
Histological workup	Tissue biopsy is a requirement. Cellular polymorphism, tumour necrosis, high mitotic rate and Ki67 [70]	Tissue biopsy is not easily diagnostic under the light microscope. Immunohistochemistry may be positive for cytokeratin markers AE1/AE3, CD56, chromogranin, and synaptophysin. TTF-1 70–80% positive, Ki-67 80–100% positive [64]	Tissue biopsy is a requirement. Neuroendocrine architecture is not always present and immunohistochemistry with synaptophysin, chromogranin NCAM and CD56 is necessary. TTF-1 positive in 41-75%. Ki-67 50-100% [61]. Positive keratin 7 and 18, E- and P-cadherins, beta-catenin, villin 1, retinoblastoma protein, c-met and alpha-enolase [71]
Surgery	Important treatment in limited disease [3]	Not an option in limited disease unless very limited disease to T1/T2 N0 [72] Nodal evaluation is required by diagnostic imaging such as PET-CT, mediastinoscopy or endobronchial ultrasound-guided transbronchial needle aspiration [73]	The role of surgery is not fully evaluated in this disease. Five-year survival varies between 13% and 57% [74]
Chemotherapy adjuvant/first line	Platinum-based and etoposide [46, 47]	Cisplatinum and etoposide [75]	Cisplatinum etoposide for adjuvant [76] and first line [77]
Chemotherapy second line	Irinotecan, topotecan [78]	Topotecan intravenously, topotecan orally, irinotecan, CAV intravenously (Cyclophosphamide Adriamycin Vincristin) [64]	No records in the literature except a few responses after rechallenging with platinum and etoposide [79]

PDNEC — poorly differentiated neuroendocrine carcinomas; ^{18}F-FDG PET — ^{18}F-fluorodeoxyglucose positron emission tomography; CT — computed tomography; GI — gastrointestinal tract

Table I. *Differences between pulmonary and extrapulmonary PDNEC*
Tabela I. *Różnice między PDNEC w lokalizacji płucnej i pozapłucnej*

	Extrapulmonary PDNEC	Small cell lung cancer	Large cell lung cancer
Radiotherapy	Rectal cancer [13]	In limited disease, thoracic and cranial prophylactic irradiation [80]	Sparse data but National Comprehensive Cancer Network guidelines recommend its use as for non small cell lung cancer [81]
Peptide Receptor Radiotherapy	Usually not expressing somatostatin receptors	Not applicable as it is a high grade tumour	No published data
Somatostatin analogues	Not useful as not expressing somatostatin receptors. Role in functional syndromes	Not applicable as it is a high grade tumour not expressing somatostatin receptors	No published trial but a study using 68Ga-DOTATATE, a novel selective somatostatin receptor 2 PET ligand, was negative [82]
Targeted therapy	No data available	Experimental. Promising data from IGF-1R inhibitors [83]	Experimental. Promising data from met inhibitors [84]
Response to treatment	67% [46]	55–73% [85]	50–68% [86]
Overall five-year survival	Depends on primary, stage and treatment, but overall very poor [7, 87]	6% http://www.cancer.org/Research/CancerFactsFigures/CancerFactsFigures/cancer-facts-and-figures-2010	13% [74]

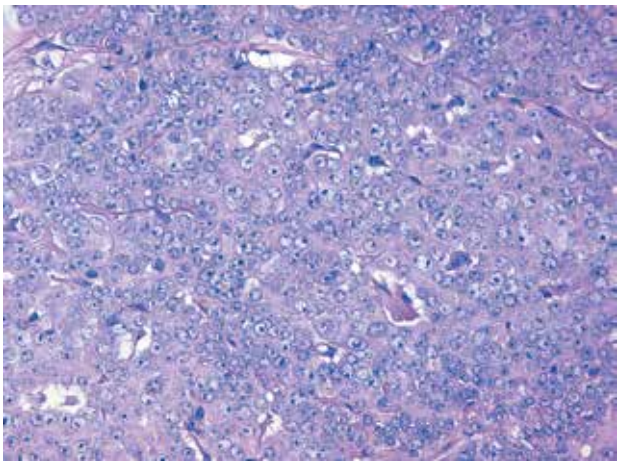

Figure 1. *Well-differentiated neuroendocrine tumour*
Rycina 1. *Wysokozróżnicowane nowotwory neuroendokrynne*

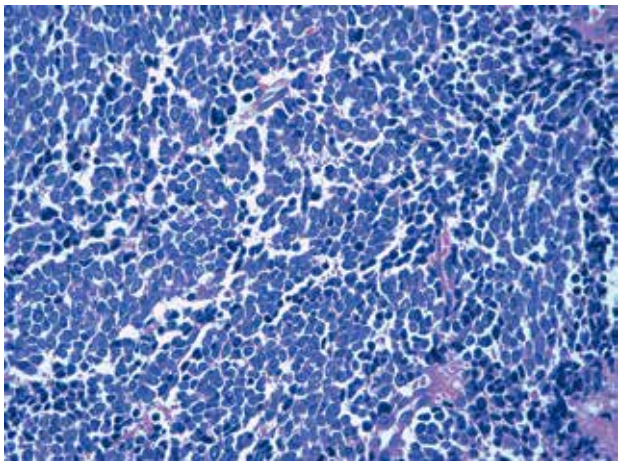

Figure 2. *Poorly differentiated neuroendocrine carcinoma*
Rycina 2. *Niskozróżnicowane raki neuroendokrynne*

such as chromogranin A (CgA) and synaptophysin [1,9] (Fig. 1). In contrast, PDNEC exhibit a more diffuse architecture, irregular nuclei with less cytoplasmic granularity whereas immunoexpression of neuroendocrine markers is relatively limited [1,9] (Fig. 2). In this concept, grading of the tumour has been introduced as an index of biologic aggressiveness, based on the number of mitoses, presence of necrosis and/or Ki67 LI, where all PDNEC are considered as high grade (G3) tumours being extremely aggressive, whereas intermediate grade (G2) tumours have a less predictable course. (Table II, III and Fig. 3). It has recently been proposed that there may be an overlap in clinical behaviour, response to treatment and overall prognosis even within tumours belonging to the same grading group. This holds true particularly between G2 tumours with high Ki67 LI values and G3 tumours with Ki67 LI values close to the 20% limit compared to those with higher values, particularly when the Ki67 values are greater than 60% [2, 17] (Table II). This has recently been confirmed by a number of studies

Table II. *Neuroendocrine classification: traditional versus current*
Tabela II. *Tradycyjna i aktualna klasyfikacja nowotworów neuroendokrynnych*

Mitotic count/10HPF*	Ki67 index (%)**	Traditional classification	ENETS/WHO classification
< 2	≤ 2	Carcinoid, islet cell, pancreatic (neuro)endocrine tumour	Neuroendocrine tumour grade 1
2–20	3–20	Carcinoid, atypical carcinoid***, islet cell, pancreatic (neuro)endocrine tumour	Neuroendocrine tumour grade 2
> 20	> 20	Small cell carcinoma Large cell neuroendocrine carcinoma	Neuroendocrine carcinoma, grade 3, small cell Neuroendocrine carcinoma grade 3, large cell

HPF — high-power field; ENETS — European Neuroendocrine Tumour Society; *HPF = 2 mm^2; at least 40 fields (at X magnification) in areas of highest mitotic density. Cutoff values were taken from American Joint Committee on Cancer staging system (seventh edition); **MIB1 antibody; percentage of 2,000 tumour cells in areas of highest nuclear labelling. Cutoff values were taken from American Joint Committee on Cancer staging system (seventh edition); ***The term atypical carcinoid only applies to immediate-grade neuroendocrine tumour of the lung

Table III. *Lung versus gastroenteropancreatic neuroendocrine tumours (GEP-NETs) classification system*
Tabela III. *Nowotwory neuroendokrynne płuc i nowotwory neuroendokrynne układu pokarmowego (GEP-NET)*

Grade	Lung and Thymus (WHO)	GEP-NETs (ENETS)	GEP-NETs (WHO)	Lung and thymus	Pancreas
Low grade	Carcinoid tumour	Neuroendocrine tumour, grade 1	Neuroendocrine neoplasm, grade 1	Neuroendocrine carcinoma, grade 1	Well-differentiated endocrine neoplasm, low grade
Intermediate grade	Atypical carcinoid tumour	Neuroendocrine tumour, grade 2	Neuroendocrine neoplasm, grade 2	Neuroendocrine carcinoma, grade 1	Well-differentiated endocrine neoplasm, intermediate grade
High grade	Small cell carcinoma Large cell neuroendocrine carcinoma	Neuroendocrine carcinoma, grade 3, small cell carcinoma Neuroendocrine carcinoma, grade 3, large cell carcinoma	Neuroendocrine carcinoma, grade 3, small cell carcinoma Neuroendocrine carcinoma, grade 3, large cell carcinoma	Neuroendocrine carcinoma, grade 3, small cell carcinoma Neuroendocrine carcinoma, grade 3, large cell carcinoma	Poorly differentiated endocrine carcinoma, small cell carcinoma Poorly differentiated endocrine carcinoma, large cell carcinoma

Adapted from Klimstra D et al, 'Pancreas' 2010; 39: 707–712

that have evaluated the response of GI-PDNEC to treatment and analysed their overall prognosis on the basis of specific parameters and particularly the Ki67 LI [7, 8, 18]. Similarly to WDNETs, where the site of origin within the GI-tract may be of significance for the overall prognosis of these tumours, there is evidence that this may also apply for PDNEC [7, 8].

Two histological variants of PDNEC, small and large cell, are defined; combined forms with elements of non-neuroendocrine carcinoma (mostly adenomatous or squamous) have also been recognised. However, there are no studies demonstrating that such a distinction is of relevant clinical significance [7]. PDNEC include small-to-medium-sized tumour cells growing in a solid sheet, exhibiting prominent angioinvasion and lymph node/ /distant metastases [19]. Tumour cells are strongly positive for cytosolic markers of neuroendocrine differentiation, such as neuron specific enolase (NSE) and PGP 9.5 protein, but exert relatively weak or absent positivity for CgA [20]. Positive CgA staining indicates a more mature tumour and the presence of both synaptophysin and CgA is regarded as a relatively good prognostic sign [8, 21].

However, this feature has been shown not to be of clinical significance in a recent study [7]. Histopathologically, GI-small cell carcinoma (SCC) is indistinguishable from pulmonary SCC with small cell tumour size, ap-

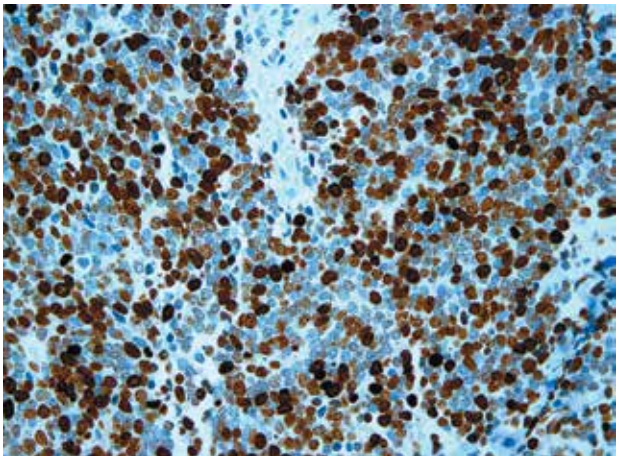

Figure 3. *Ki67 labelling index in poorly differentiated neuroendocrine carcinoma*

Rycina 3. *Wskaźnik aktywności proliferacyjnej Ki67 w niskozróżnicowanych rakach neuroendokrynnych*

proximately the size of three lymphocytes, with scant cytoplasm and round or spindle-shaped nuclei that exhibit nuclear modelling [9]. GI-SCC typically have > 10 mitoses/10 high power fields (HPF) (average 40–50), lymphovascular invasion and Ki67 LI > 20% (but usually higher than 75%) [3, 8]. Similarly, the large cell variant of GI-PDNEC consists of larger cells with more abundant cytoplasm and also exhibits similarities to SCLC but shows reduced expression of the transcription factor CDX2 and high microsatellite instability [9]. In an analysis of 44 cases of large-cell PDNEC that included 13 patients with GI-PDNEC and 15 with unknown primary origin, high mitotic count, low expression of neuroendocrine markers and a Bcl-2/Bax ratio > 1 were found to be unfavourable prognostic markers [21]**.** In a more recent study where histopathologic analysis was available in 305 patients with GI-PDNEC, 115 were found to have small-cell morphology mostly encountered in oesophageal and rectal tumours, and 148 had non-small-cell morphology mostly encountered in colonic primaries [7]. In the same study, it was shown that the Ki67 LI was > 55% mostly in primary gut tumours, whereas lower values were found in pancreatic PDNEC; however, there were neither Ki67 nor CgA immunostaining differences between small and non-small (large) PDNEC [7]. As the majority of these tumours are not associated with distinct clinical syndromes, tumour cells lack immunopositivity for hormonal products [1, 9].

Besides immunoreactivity for CgA and synaptophysin, PDNEC may also be positive for carcinoembryonic antigen (CEA) [9]. Keratin expression is common and in contrast to SCLC in which thyroid transcription factor-1 (TTF-1) is found to be present in 85-100% of cases, in GI-PDNEC it is only occasionally positive in approximately 17% of cases [22]. Although the precise aetiology of these neoplasms is largely unknown, several molecular aberrations have been detected such as overexpression of p53, telomerase activation and retinoblastoma (Rb) gene loss [9, 23, 24]. Recent evidence has also suggested that these tumours are more likely to develop through chromosomal rather than microsatellite instability [25].

Due to the late introduction of a TNM staging system in PDNEC, previous studies have been based on the American Joint Committee on Cancer consisting of two staging categories, *limited disease*, defined as a tumour contained within a localised anatomic region, with or without regional lymph node involvement, and *extensive disease*, defined as a tumour outside the locoregional boundaries [3, 26].

Clinical presentation according to location and site of origin

Patients with PDNEC can present with either localised regional or distant disease; however, most have already extensive disease at diagnosis [3, 7, 9, 13]. As the great majority of these tumours are not associated with a clinical syndrome, clinical presentation is guided by the local effects of the tumour and the effects that it may exert on adjacent tissues [3, 7]. In a large study including 305 patients, only 3% were found to have symptoms related to a secretory syndrome [7]. A further distinctive feature of extra-pulmonary PDNEC is the low propensity for development of brain metastases compared to SCLC [1, 3, 9, 14].

PDNEC of the stomach: These tumours account for approximately 6% of gastric NETs with a mean age at diagnosis of 64 years [27, 28]. The majority of tumours present as single lesions evenly distributed in the stomach with an average size of 4.2–6.3 cm [29, 30]. Common presenting symptoms are abdominal pain, GI-bleed and upper GI discomfort. Gastric PDNEC may contain an additional adenocarcinomatous or squamous component [29].

PDNEC of the duodenum: These are rare tumours primarily located in the ampulla of Vater [31] accounting for 2-3% of ampullary tumours [32]. The majority of patients present with jaundice and abdominal pain; mean tumour size is 2.5 cm and may be associated with adjacent mucosa adenomas in up to 50% of cases [33].

PDNEC of the pancreas: These tumours account for 1% of all malignant pancreatic tumours and are predominantly located in the pancreatic head, measuring 4 cm in diameter, invading surrounding organs and/or having developed metastases [34]. Common presenting symptoms include jaundice, weight loss, abdominal pain and more rarely symptoms attributed to hormonal hyperproduction such as Cushing's syndrome and carcinoid syndrome [1].

PDNEC of the colon and rectum: There is a paucity of information regarding this presence of PDNEC in this region, although this specific localisation may be associated with an overall worse prognosis [7, 9]. This is evident by the finding that although the prevalence of rectal carcinoids has increased, mainly as a result of the increased investigational procedures, the number of PDNEC has remained low [9]. This may also be related to the fact that some tumours may have been misdiagnosed as adenocarcinomas prior to the introduction of the new classification systems. The nationwide SEER study on rare tumours of the colon and rectum from the USA showed a significant increase of NET histologies, albeit without distinguishing between small and large cell variants, over the past decade [35]. However, data on the true incidence of PDNEC in relation to carcinomas with NE differentiation is still lacking [35].

PDNEC of unknown origin and localised in lymph nodes: In a significant number of PDNEC, the primary site of origin may be impossible to recognise [3, 7, 9]. However, since the majority of extra-pulmonary PDNEC arise from the GI tract, it is possible that most of them are probably GI-PDNEC. A previous study has raised some concern as to whether the localisation of PDNEC only in the lymph nodes represents a distinct clinical entity [11]. These authors identified 28 patients with such a diagnosis who were found to have a better outcome compared to patients with pulmonary or extra-pulmonary PDNEC [11]. The majority (75%) of these patients presented with limited disease localised only in the lymph nodes, showed a good response to surgery, chemotherapy or radiotherapy, and had an overall survival of 79% at three years [11]. Further studies are necessary to delineate if such a distinct entity exists, although a study evaluating large cell PDNEC showed that patients presenting with single lymph node involvement had a much better outcome [21].

Diagnostic procedures

Following the diagnosis of a PDNEC, it is important to exclude a primary pulmonary lesion and assess if the patient has limited or extensive disease. Diagnosed studies are aimed at affected areas employing modalities such as endoscopy and morphological imaging as well as staging procedures. There are no specific differences in the application of upper and/or lower GI endoscopic procedures and other conventional imaging modalities used to identify these tumours compared to other GEP-NETs that have recently extensively been described by ENETS [36, 37].

Imaging

Computed tomography (CT) and magnetic resonance imaging (MRI) scans are used to delineate local tumour extension particularly in the liver and bones [13]. However, there are no comparative studies evaluating the diagnostic accuracy of these modalities. In contrast to WDNETs, where sstr scintigraphy (SRS), either with ^{111}Inlabelled-octreotide or more recently ^{68}Gallium-DOTATE/TOC, is used for their diagnosis and staging, this modality is not equally useful in PDNEC as the majority of these tumours lack sstr expression [13, 16]. These tumours demonstrate intense metabolic activity, reflecting their proliferative activity, and therefore ^{18}F-fluorodeoxyglucose positron emission tomography (^{18}F-FDG PET) imaging is used for baseline staging and for monitoring response to treatment [13, 16]. This was shown in a recent prospective study of 96 patients with mostly GEP-NETs, 13 of whom had a Ki67 LI > 15%, who underwent imaging with ^{18}F-FDG PET, SRS, and ^{123}I-MIBG (metaiodobenzylguanidine) obtaining sensitivities of 92%, 69% and 46% respectively [16]. There is however increasing data demonstrating that SRS may be positive, albeit at a less intensity, in up to 60% of patients with PDNEC [8, 16, 21]. In a recent study, when SRS was performed in a large cohort of patients with GI-PDNEC, a high uptake was mainly found in primary pancreatic tumours; however, in that study SRS was performed mainly in patients with a relatively lower Ki67 LI albeit within the G3 grading group [7]. Because expression of sstr may indicate a less aggressive tumour behaviour, some authors have suggested that SRS could also be performed in PDNEC patients as it could represent a prognostic and predictive marker of response to specific chemotherapy (i.e. temozolomide) [38, 39]. It could even indicate whether peptide receptor radionuclide therapy (PRRT) could be an additional therapeutic option [38, 39]. Although this may specifically hold true for PDNEC with relatively low Ki67 LI, there is currently no data evaluating this form of treatment in patients with PDNEC and positive SRS [40].

Biochemical markers

The universal biochemical marker for NETs CgA is of relatively small value for either diagnosing or monitoring the response to treatment in PDNEC. This has been shown by a number of studies and it is probably related to the de-differentiation of these tumours [41]. In contrast, NSE may exert a relatively higher diagnostic utility [6, 42]. More importantly, a study investigating CgA and NSE sensitivity by tumour grading indicated that large cell and small cell NETs showed a statistically significant higher NSE sensitivity compared to G1 and G2 NETs, whereas the opposite effect was noticed with CgA levels [43]. In a recent retrospective study, CgA measurement was available in 188/305 patients with GI-PDNEC and was found to be elevated in approxi-

mately two thirds of them [7]. In the same study, urine-5-hydroxyindoloacetic acid (5HIAA) was measured in 94 patients and was found to be elevated in 24; however, most of these patients had tumours with relatively low Ki67 LI values [7]. Choice of tumour markers in patients with NETs is dependent on the histological grade, but both CgA and NSE could be used for the initial evaluation of the tumour; when found abnormal, their serial assessment could be valuable in monitoring the disease and response to treatment [41].

Newer evolving markers are currently being investigated. Progastrin-releasing peptide [proGRP) is a precursor form of gastrin-releasing peptide (GRP, mammalian bombesin) that is widely distributed throughout the GI and pulmonary tract [44]. ProGRP and cytokeratin fragments (CKfr, CK8, 18, 19) have been shown to be associated with survival in patients with SCLC and may also be of value in patients with extra-pulmonary PDNEC [43]. Furthermore, in a comprehensive comparative study of CgA, NSE, proGRP and cytokeratin fragments involving 280 patients with WDNET, 42 with LCNEC, 251 with SCNEC and 282 healthy controls, proGRP showed the highest sensitivity (73%) at 95% specificity in patients with SCNEC [43]. In a multivariate survival analysis, both Ckfr and NSE were associated with survival [43, 44].

Prognostic parameters

Patients can present with either localised, regional or distant disease [13] exerting a relatively poor prognosis with median survival durations of 34 months in patients with localised, and 14 and 5 months in patients with regional and distant disease, respectively [45]. Previous studies have documented that tumour extension (limited vs. extensive disease) and patient's performance status are strong predictors of survival [3, 7]. This has recently been verified by a large retrospective study including 305 patients with GI-PDNEC [7].

Treatment

Based on some similarities of PDNEC to SCLC, adjuvant chemotherapy treatment of SCLC including a platinum-based agent, cisplatin or carboplatin depending on patient comorbidities, and etoposide, is recommended (National Comprehensive Cancer Network clinical practice guidelines; 'Neuroendocrine Tumours' in www.nccn.org). Similar combinations of platinum-based agents and etoposide have also been used in metastatic GI-PDNEC, although some have questioned this rationale as there are many differences between pulmonary and GI PDNEC [3, 10, 13] (Table I). Two prospective studies have evaluated the efficacy of this regimen in patients with GI-PDNEC. In the first, 18 patients with metastatic PDNEC were treated, producing a response rate of 67% in patients with previously documented progressive disease with responses lasting for eight months and an overall median survival of 19 months [46]. In the second study, 53 patients (41 with PDNEC among whom 20 with GI-PDNEC) were treated with the same regimen showing a response rate of 42% with response duration of nine months and a median survival of 15 months [47]. However, in these studies, not only GI but various other extra-pulmonary sites of origin of primary tumours were included, precluding the extraction of precise data [7, 12, 13]. However, several other retrospective studies have validated the efficacy of this regimen in GI-PDNEC (Table IV). The regimen mostly involves the combination of etoposide 100 mg/m^2 on day 1 for three days and cisplatin 100 mg/m^2 on day 1 given by 2-h intravenous infusion, administered every 21 days [47].

Recent data has also shown that the combination of cisplatin and irinotecan (four-week cycles of 60mg/m^2 irinotecan on days 1, 8, and 15 and 60mg/m^2 cisplatin on day 1) in 44 patients with various extra-pulmonary PDNEC showed a response rate of 64% at first line and a progression free survival (PFS) of 7.3 months; there was a significant relationship with NSE elevation and poor survival [48]. The same combination was used in 12 patients with metastatic or recurrent PDNEC of the stomach, obtaining a response rate of 75%, a median PFS of 212 days and a median survival time of 697 days [49]. Following the analysis of a large number of patients with GI-PDNEC, it became evident that there was some heterogeneity of the responses obtained based on the primary location and proliferation rate [7]. In a previous retrospective study, 21 patients with hepatobiliary and pancreatic PDNEC were treated with the combination of cisplatin 80mg/m^2 given intravenously on day 1 and etoposide 100mg/m^2 intravenously on days 1–3 repeated every 3–4 weeks [12]; only three patients had a partial response (14%) whereas the median PFS was 1.8 months and median overall survival (OS) 5.8 months. The optimal duration of chemotherapy has not been clearly defined, although 4–6 cycles are usually administered; however, it has not been established whether treatment beyond four cycles offers a survival benefit [13]. A recent multicentre study has shown that there was no difference in response regarding tumour morphology or positive CgA IHC and/or the various platinum-based chemotherapy schedules used, i.e. cisplatin *v*. carboplatin [7].

While the mammalian target of rapamycin (mTOR) signalling pathway is a target for WDNET with the mTOR inhibitor everolimus, PDNEC are usually excluded from clinical trials (RADIANT 2, RADIANT

Table IV. *Summary of response rates obtained in patients with extra-pulmonary poorly differentiated NETs treated with etoposide- and platinum-based regimens*

Tabela IV. *Zestawienie danych dotyczących odsetka odpowiedzi na leczenie uzyskiwanych u pacjentów z pozapłucnymi niskozróżnicowanymi NET leczonymi wg schematów obejmujących etopozyd i pochodną platyny*

Treatment	Number of patients	Primary site	Response rate	Response duration	Reference
Cisplatin 45 mg/m^2 days 2, 3 and etoposide 130 mg/m^2 days 1, 2, 3	18 advanced disease	Any	67%	8 months	[46]
Cisplatin 100 mg/m^2 day 1 and etoposide 100 mg/m^2 days 1, 2, 3	53 advanced disease	Any	41.5%	4.5–23.5 months (median 9.2)	[47]
Cisplatin and etoposide ± paclitaxel	18 advanced disease	Any	17%	6.3 months	[88]
Cisplatin and etoposide	8 advanced disease	Colorectal	62%	4.5 months	[89]
Cisplatin 80 mg/m^2 day 1 and etoposide 100 mg/m^2 days 1, 2, 3	21 advanced disease	Pancreas and hepatobiliary	14%	2 months	[12]
Cisplatin or carboplatin and etoposide or CAV	64 limited and advanced disease	GI-SCNEC	36%	8 (4–16) months	[14]
Cisplatin or carboplatin and etoposide	252 advanced disease	GI-NEC	31%	11 months median survival	[7]
Cisplatin 45 mg/m^2 days 2, 3 and etoposide 100 mg/m^2 days 1, 2, 3	36 advanced disease	Any	55–80%	8–11 months	[90]
Cisplatin and Irinotecan	22 advanced disease	Stomach	75%	7 months	[49]
Cisplatin 60 mg/m^2 day 1 and irinotecan 60 mg/m^2 days 1, 8, 15	50 limited and advanced disease	Any	64%	7.3 months	[48]

GI — gastrointestinal; NEC — neuroendocrine carcinoma; SCNEC — small cell neuroendocrine carcinoma

3) due to their aggressive nature [50, 51]. However, recent data has shown that mTOR expression can be found in all NETs irrespective of the primary site of origin and/or proliferation rate as defined by the ki67 LI [52]. Therefore, the role of everolimus in this subset of patients may need to be defined further. Following the finding that PDNEC may show positive uptake in SRS, a recent study focused on the results following PRRT with ^{177}Lu-DOTA-octreotate in 81 patients with respect to proliferation rate [38]. Response rates in patients with Ki67 LI up to 20% were almost 80% (partial response and stable disease); however, only 2/7 patients with Ki67 LI > 20% exhibited a similar response rate, and in accordance with previous studies a positive correlation of uptake intensity and outcome was noted [38, 53]. However, as the proliferation rate can be heterogeneous even within the same tumour, fractionated therapy with PRRT could be considered a treatment option in patients with apparent PDNEC and high sstr expression [39].

Localised disease

PDNEC are characterised by a high tendency for metastatic dissemination even if localised, as almost all patients who were treated with surgery alone had recurrent disease [3, 13]. Several studies have evaluated the overall outcome in patients with PDNEC who were treated with surgery alone with an intention to obtain a surgical cure of the disease. However, none of the patients who underwent such a surgical procedure was found to be alive at three and five years of follow-up, compared to 100% and 85% of patients who had WDNETs and had the same treatment [54, 55]. It has therefore been suggested that even an apparent complete surgical resection adjuvant treatment with radiotherapy and/or chemotherapy should be given to eradicate any residual disease [13]. However, due to the rarity of cases there is no information regarding the need for such an approach in patients with relatively low Ki67 values albeit within the G3 range.

Second line therapy

Despite initial response, a significant number of patients will develop progressive disease. However, very few studies have evaluated response rates to second line therapy and most data is derived from similar data from relapsed SCLC that exhibit response rates ranging between 0% and 20% [13]. Patients that developed relatively late recurrences (more than 3–6 months) may receive retreatment with a platinum agent and etoposide or irinotecan [13,48], whereas oral topotecan has been shown to improve by three months median survival in patients with SCLC [56]. Such an approach may be useful in patients with GI-PDNEC, particularly those who have a relatively low performance status. Other agents that could be used based on experience from SCLC are paclitaxel, docetaxel, vinorelbine and gemcitabine [13, 57]. However, when progression develops following first line therapy, the disease is usually very aggressive despite the administration of several different second line regimens and patients may experience a relatively short survival [8]. Recently it was shown that the response rate in 26 patients who experienced progression to the same regimen was 42% (15% partial response and 27% stable disease), whereas the response rates following second-line chemotherapy with other agents in 84 patients was 51% (18% partial response and 33% stable disease), and after third-line chemotherapy in 29 patients 41% [7]. Based on the experience that temozolomide could be active in a small number of patients with PDNEC [18], a recent retrospective study evaluated the effect of temozolomide either alone or in combination with capecitabine or bevacizumab as second line therapy in patients with mostly GI-PDNEC. A response rate of 33% was obtained with a median duration of response of 19 months, whereas 71% of patients had at least stabilisation of the previously progressive disease; median PFS was six months and median OS was 22 months [8, 58]. Patients with Ki67 LI of < 60%, positive immunohistochemistry for CgA, positive SRS, and lack of response to first-line therapy seemed to respond better to the administration of temozolomide [8]. Adding capecitabine or bevacizumab to temozolomide did not seem to have any additional effect, although this should be regarded with caution as the number of patients included in each group was small [8]. Evaluation of O6methylguanidine-DNA methyltransferase (MGMT) expression, an enzyme that when present may predict poor response to temozolomide, did not seem to be necessary for predicting the response to treatment, as it was only positive in 1/17 tested patients [8]. Although this study has several limitations, as only patients with good performance status would be considered candidates for further therapy, it provides some evidence for using temozolomide particularly in patients with not extremely high Ki67 LI values who are probably those not responding to the first line treatment with cisplatin and etoposide.

Predictors of response — survival

A number of previous studies have shown differences between these tumours and SCLC [3, 7, 10, 11, 14, 59]. However, as in patients with SCLC, the median survival in patients not receiving chemotherapy is only one month, justifying aggressive management similar to SCLC using chemotherapy in such patients [7]. Although there may be a selection bias, as patients with low performance status were more likely not to be treated, chemotherapy is a powerful tool to improve survival necessitating the need to identify predictors of response and survival [3, 7, 13, 55, 57]. Several studies have shown that the extent of the disease and patient's performance status are the best predictors of response [3, 7, 13, 55, 57]. Recently, a multicentre retrospective study has provided useful information regarding predictors of response in a large cohort of 305 patients with GI-PDNEC [7]. Ki67 LI emerged as an important predictor of response. The best cut-off value regarding response rate for Ki67 by ROC analysis was 55%; responses were lower when Ki67 LI was > 55% (15% vs. 42%). Patients with worse performance status had a higher percentage of immediate disease progression than patients with good performance status (61% *v.* 265) [7].

In addition, a recent prospective study evaluated the role of ^{18}F-FDG PET as a predictor of survival in 98 patients with GEP-NETs. Fourteen of these patients had a PDNEC and in 13 of them ^{18}F-FDG PET was positive. Although the authors did not provide specific information in this particular group of patients it was shown that a SUVmax > 9 and a high Ki67 LI were significant predictors of OS with a hazard ratio of 8.8 and 2.6 respectively; however, in multivariate analysis a SUVmax > 3 was the only predictor of PFS [16]. Based on this data, it is highly possible that measurement of SUVmax in patients with PDNEC may prove to be a valuable predictor of either response to treatment or survival besides Ki67 LI [16].

Ki67 LI may also predict those with a survival benefit, as many more patients with a Ki67 < 55% were alive compared to only 7% when Ki67 > 55% [7]. Furthermore, patients with primary colon tumours had a shorter median survival compared to patients with pancreatic tumours (8 *v.* 15 months) in a large multicentre study [7]. This outcome was not related to either cisplatin or carboplatin use, histopathologic morphology (small *v.* large cell) or intensity of CgA im-

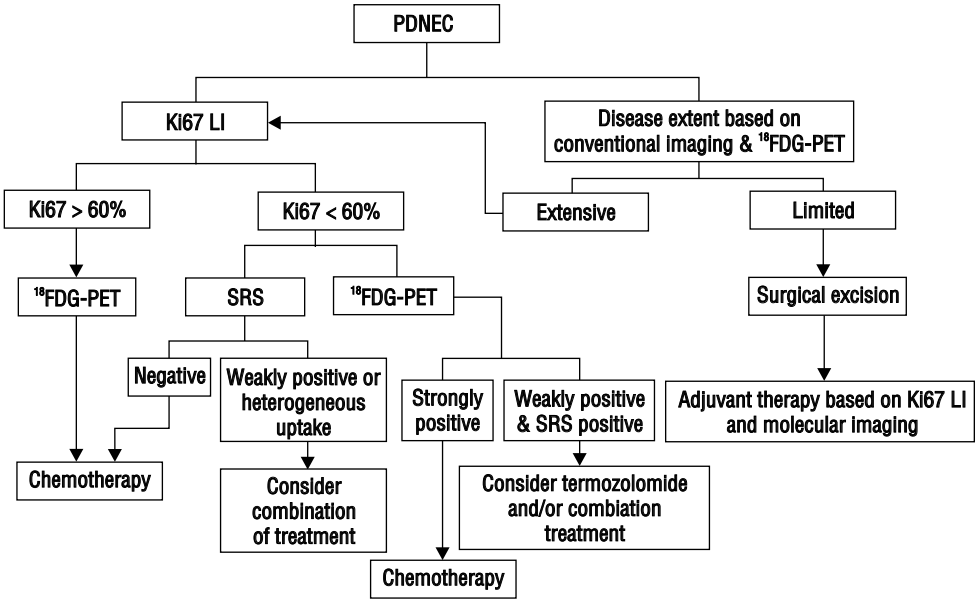

Figure 4. *Treatment algorithm for poorly differentiated neuroendocrine carcinomas. Data derived from [7, 8, 16]; PDNEC — poorly differentiated neuroendocrine carcinoma; LI — labelling index; SRS — somatostatin receptor scintigraphy; ^{18}F-FDG PET — ^{18}F-fluorodeoxyglucose positron emission tomography; Chemotherapy — platinum + etoposide or irinotecan*

Rycina 4. *Algorytm postępowania w niskozróżnicowanych rakach neuroendokrynnych*

munostaining [7]. Performance status has also evolved as a powerful predictor of survival, as patients with good performance status exhibited the best survival [7]. Following the results of a multivariate analysis, apart from the site of the primary tumour and performance status, blood levels of platelets and LDH were also strong predictors of survival: patients with the best performance status and normal platelet and LDH levels had a median survival of 26 months [7].

Summary

Poorly differentiated neuroendocrine carcinomas (PDNEC) are rare tumours that constitute a heterogeneous group of NEC with an overall aggressive behaviour associated with a short survival that have traditionally been subdivided histologically into large and small cell PDNEC. The majority of these tumours present with extensive disease that is best documented with the use of ^{18}F-FDG PET scan that can also be used to guide response to treatment (Fig. 4). Although SRS is not useful for staging of PDNEC, it may be of prognostic value reflecting the heterogeneity of these tumours and the need to develop further tools to clarify the biological behaviour of each tumour within that group. No ideal currently available tumour markers for PDNEC exist, although CgA may be more useful in LC PDNEC whereas NSE may be more useful in SC-PDNEC; however, there seems to be no difference regarding response to treatment and overall prognosis between these two histological variants.

The prognosis of PDNEC is associated with the extent of the disease, performance status of the patient, and the origin of the primary lesion, whereas absolute Ki67 LI expression may be a prognostic indicator of the response to treatment and of overall biological behaviour (Fig. 4). Platinum- and etoposide-based chemotherapy seems to obtain significant responses and improve survival in PDNEC and should be the first-line therapy. Other regimens also seem to have some activity but the majority of patients will develop recurrent disease necessitating further therapy with a variety of chemotherapeutic agents, albeit achieving lower response rates. For some of these patients, second line therapy with temozolomide may evolve as a reasonable option although this needs to be clarified by further prospective studies. The majority of clinical available data is based on a retrospective series of patients and thus most currently existing clinical guidelines are based on a low level of evidence data (expert opinion), making it urgent that larger multicentre studies be performed. Recently it has been argued that GI-PDNEC are not a single disease entity and additional clinical and molecular data are required to identify specific subgroups. However, as GI-PDNEC constitute a heterogeneous group of aggressive tumours, treatment should be initiated early when the performance status is still adequate as it represents a very strong indicator of survival.

References

1. Nilsson O, Van CE, Delle FG et al. Poorly differentiated carcinomas of the foregut (gastric, duodenal and pancreatic). Neuroendocrinology 2006; 84: 212–215.
2. Klimstra DS, Modlin IR, Coppola D et al. The pathologic classification of neuroendocrine tumors: a review of nomenclature, grading, and staging systems. Pancreas 2010; 39: 707–712.
3. Brenner B, Tang LH, Klimstra DS et al. Small-cell carcinomas of the gastrointestinal tract: a review. J Clin Oncol 2004; 22: 2730–2739.
4. Kloppel G, Scherubl H. [Neuroendocrine tumors of the stomach. Risk stratification and therapy]. Pathologe 2010; 31: 182–187.
5. Kloppel G, Rindi G, Perren A et al. The ENETS and AJCC/UICC TNM classifications of the neuroendocrine tumors of the gastrointestinal tract and the pancreas: a statement. Virchows Arch 2010; 456: 595–597.
6. Kaltsas GA, Besser GM, Grossman AB. The diagnosis and medical management of advanced neuroendocrine tumors. Endocr Rev 2004; 25: 458–511.
7. Sorbye H, Welin S, Langer SW et al. Predictive and prognostic factors for treatment and survival in 305 patients with advanced gastrointestinal neuroendocrine carcinoma (WHO G3): The NORDIC NEC study. Ann Oncol 2013; 24: 152–160.
8. Welin S, Sorbye H, Sebjornsen S et al. Clinical effect of temozolomide-based chemotherapy in poorly differentiated endocrine carcinoma after progression on first-line chemotherapy. Cancer 2011; 117: 4617–4622.
9. Ahlman H, Nilsson O, McNicol AM et al. Poorly-differentiated endocrine carcinomas of midgut and hindgut origin. Neuroendocrinology 2008; 87: 40–46.
10. Brennan SM, Gregory DL, Stillie A et al. Should extrapulmonary small cell cancer be managed like small cell lung cancer? Cancer 2010; 116: 888–895.
11. Cicin I, Karagol H, Uzunoglu S et al. Extrapulmonary small-cell carcinoma compared with small-cell lung carcinoma: a retrospective single-center study. Cancer 2007; 110: 1068–1076.
12. Iwasa S, Morizane C, Okusaka T et al. Cisplatin and etoposide as first-line chemotherapy for poorly differentiated neuroendocrine carcinoma of the hepatobiliary tract and pancreas. Jpn J Clin Oncol 2010; 40: 313–318.
13. Strosberg JR, Coppola D, Klimstra DS et al. The NANETS consensus guidelines for the diagnosis and management of poorly differentiated (high-grade) extrapulmonary neuroendocrine carcinomas. Pancreas 2010; 39: 799–800.
14. Brenner B, Shah MA, Gonen M et al. Small-cell carcinoma of the gastrointestinal tract: a retrospective study of 64 cases. Br J Cancer 2004; 90: 1720–1726.
15. Zerbi A, Falconi M, Rindi G et al. Clinicopathological features of pancreatic endocrine tumors: a prospective multicenter study in Italy of 297 sporadic cases. Am J Gastroenterol 2010; 105: 1421–1429.
16. Binderup T, Knigge U, Loft A et al. 18F-fluorodeoxyglucose positron emission tomography predicts survival of patients with neuroendocrine tumors. Clin Cancer Res 2010; 16: 978–985.
17. Ekeblad S, Skogseid B, Dunder K et al. Prognostic factors and survival in 324 patients with pancreatic endocrine tumor treated at a single institution. Clin Cancer Res 2008; 14: 7798–7803.
18. Ekeblad S, Sundin A, Janson ET et al. Temozolomide as monotherapy is effective in treatment of advanced malignant neuroendocrine tumors. Clin Cancer Res 2007; 13: 2986–2991.
19. Rindi G, Azzoni C, La RS et al. ECL cell tumor and poorly differentiated endocrine carcinoma of the stomach: prognostic evaluation by pathological analysis. Gastroenterology 1999; 116: 532–542.
20. Rindi G, Bordi C, Rappel S et al. Gastric carcinoids and neuroendocrine carcinomas: pathogenesis, pathology, and behavior. World J Surg 1996; 20: 168–172.
21. Faggiano A, Sabourin JC, Ducreux M et al. Pulmonary and extrapulmonary poorly differentiated large cell neuroendocrine carcinomas: diagnostic and prognostic features. Cancer 2007; 110: 265–274.
22. Ordonez NG. Value of thyroid transcription factor-1, E-cadherin, BG8, WT1, and CD44S immunostaining in distinguishing epithelial pleural mesothelioma from pulmonary and nonpulmonary adenocarcinoma. Am J Surg Pathol 2000; 24: 598–606.
23. Ho KJ, Herrera GA, Jones JM et al. Small cell carcinoma of the esophagus: evidence for a unified histogenesis. Hum Pathol 1984; 15: 460–468.
24. Yachida S, Vakiani E, White CM et al. Small cell and large cell neuroendocrine carcinomas of the pancreas are genetically similar and distinct from well-differentiated pancreatic neuroendocrine tumors. Am J Surg Pathol 2012; 36: 173–184.
25. Stelow EB, Moskaluk CA, Mills SE. The mismatch repair protein status of colorectal small cell neuroendocrine carcinomas. Am J Surg Pathol 2006; 30: 1401–1404.
26. Haider K, Shahid RK, Finch D et al. Extrapulmonary small cell cancer: a Canadian province's experience. Cancer 2006; 107: 2262–2269.
27. Kusayanagi S, Konishi K, Miyasaka N et al. Primary small cell carcinoma of the stomach. J Gastroenterol Hepatol 2003; 18: 743–747.
28. Namikawa T, Kobayashi M, Okabayashi T et al. Primary gastric small cell carcinoma: report of a case and review of the literature. Med Mol Morphol 2005; 38: 256–261.
29. Ballantyne GH, Savoca PE, Flannery JT et al. Incidence and mortality of carcinoids of the colon. Data from the Connecticut Tumor Registry. Cancer 1992; 69: 2400–2405.
30. Solcia E, Rindi G, Larosa S et al. Morphological, molecular, and prognostic aspects of gastric endocrine tumors. Microsc Res Tech 2000; 48: 339–348.
31. Kim T, Tao-Cheng JH, Eiden LE et al. Chromogranin A, an "on/off" switch controlling dense-core secretory granule biogenesis. Cell 2001; 106: 499–509.
32. Rindi G, Bordi C. Endocrine tumours of the gastrointestinal tract: aetiology, molecular pathogenesis and genetics. Best Pract Res Clin Gastroenterol 2005; 19: 519–534.
33. Kloppel G, Rindi G, Perren A et al. The ENETS and UICC TNM classification of neuroendocrine tumors of the gastrointestinal tract and the pancreas: comment. Pathologe 2010; 31: 353–354.
34. Vrouvas J, Ash DV. Extrapulmonary small cell cancer. Clin Oncol (R Coll Radiol) 1995; 7: 377–381.
35. Kang H, O'Connell JB, Leonardi MJ, Maggard MA, McGory ML, Ko CY. Rare tumors of the colon and rectum: a national review. Int J Colorectal Dis 2007; 22: 183–189.
36. Sundin A, Vullierme MP, Kaltsas G et al. ENETS Consensus Guidelines for the Standards of Care in Neuroendocrine Tumors: radiological examinations. Neuroendocrinology 2009; 90: 167–183.
37. Oberg K, Ferone D, Kaltsas G et al. ENETS Consensus Guidelines for the Standards of Care in Neuroendocrine Tumors: biotherapy. Neuroendocrinology 2009; 90: 209–213.
38. Ezziddin S, Sabet A, Heinemann F et al. Response and long-term control of bone metastases after peptide receptor radionuclide therapy with (177) Lu-octreotate. J Nucl Med 2011; 52: 1197–1203.
39. Garske U, Sandstrom M, Johansson S et al. Lessons on Tumour Response: Imaging during Therapy with (177)Lu-DOTA-octreotate. A Case Report on a Patient with a Large Volume of Poorly Differentiated Neuroendocrine Carcinoma. Theranostics 2012; 2: 459–471.
40. Ezziddin S, Opitz M, Attassi M et al. Impact of the Ki-67 proliferation index on response to peptide receptor radionuclide therapy. Eur J Nucl Med Mol Imaging 2011; 38: 459–466.
41. Oberg K. Circulating biomarkers in gastroenteropancreatic neuroendocrine tumours. Endocr Relat Cancer 2011; 18 (Suppl. 1): S17–S25.
42. Lindholm DP, Oberg K. Biomarkers and molecular imaging in gastroenteropancreatic neuroendocrine tumors. Horm Metab Res 2011; 43: 832–837.
43. Korse CM, Taal BG, Vincent A et al. Choice of tumour markers in patients with neuroendocrine tumours is dependent on the histological grade. A marker study of Chromogranin A, Neuron specific enolase, Progastrin-releasing peptide and cytokeratin fragments. Eur J Cancer 2012; 48: 662–671.
44. Korse CM, Taal BG, Bonfrer JM, Vincent A, van Velthuysen ML, Baas P. An elevated progastrin-releasing peptide level in patients with well-differentiated neuroendocrine tumours indicates a primary tumour in the lung and predicts a shorter survival. Ann Oncol 2011; 22: 2625–2630.
45. Yao JC, Hassan M, Phan A et al. One hundred years after "carcinoid": epidemiology of and prognostic factors for neuroendocrine tumors in 35,825 cases in the United States. J Clin Oncol 2008; 26: 3063–3072.
46. Moertel CG, Kvols LK, O'Connell MJ et al. Treatment of neuroendocrine carcinomas with combined etoposide and cisplatin. Evidence of major therapeutic activity in the anaplastic variants of these neoplasms. Cancer 1991; 68: 227–232.
47. Mitry E, Baudin E, Ducreux M et al. Treatment of poorly differentiated neuroendocrine tumours with etoposide and cisplatin. Br J Cancer 1999; 81: 1351–1355.
48. Nakano K, Takahashi S, Yuasa T et al. Feasibility and efficacy of combined cisplatin and irinotecan chemotherapy for poorly differentiated neuroendocrine carcinomas. Jpn J Clin Oncol 2012; 42: 697–703.
49. Okita NT, Kato K, Takahari D et al. Neuroendocrine tumors of the stomach: chemotherapy with cisplatin plus irinotecan is effective for gastric poorly-differentiated neuroendocrine carcinoma. Gastric Cancer 2011; 14: 161–165.
50. Pavel ME, Hainsworth JD, Baudin E et al. Everolimus plus octreotide long-acting repeatable for the treatment of advanced neuroendocrine tumours associated with carcinoid syndrome (RADIANT-2): a randomised, placebo-controlled, phase 3 study. Lancet 2011; 378: 2005–2012.
51. Yao JC, Shah MH, Ito T et al. Everolimus for advanced pancreatic neuroendocrine tumors. N Engl J Med 2011; 364: 514–523.
52. Catena L, Bichisao E, Milione M et al. Neuroendocrine tumors of unknown primary site: gold dust or misdiagnosed neoplasms? Tumori 2011; 97: 564–567.
53. Kwekkeboom DJ, de Herder WW, Kam BL et al. Treatment with the radiolabeled somatostatin analog [177 Lu-DOTA 0,Tyr3]octreotate: toxicity, efficacy, and survival. J Clin Oncol 2008; 26: 2124–2130.

54. Sellner F, Thalhammer S, Stattner S et al. TNM stage and grade in predicting the prognosis of operated, non-functioning neuroendocrine carcinoma of the pancreas--a single-institution experience. J Surg Oncol 2011; 104: 17–21.
55. Rothenstein J, Cleary SP, Pond GR et al. Neuroendocrine tumors of the gastrointestinal tract: a decade of experience at the Princess Margaret Hospital. Am J Clin Oncol 2008; 31: 64–70.
56. O'Brien ME, Ciuleanu TE, Tsekov H et al. Phase III trial comparing supportive care alone with supportive care with oral topotecan in patients with relapsed small-cell lung cancer. J Clin Oncol 2006; 24: 5441–5447.
57. Walenkamp AM, Sonke GS, Sleijfer DT. Clinical and therapeutic aspects of extrapulmonary small cell carcinoma. Cancer Treat Rev 2009; 35: 228–236.
58. Lindholm DP, Eriksson B, Granberg D. Response to temozolomide and bevacizumab in a patient with poorly differentiated neuroendocrine carcinoma. Med Oncol 2012; 29: 301–303.
59. Quinn AM, Blackhall F, Wilson G et al. Extrapulmonary small cell carcinoma: a clinicopathological study with identification of potential diagnostic mimics. Histopathology 2012; 61: 454–464.
60. Cuffe S, Moua T, Summerfield R, Roberts H, Jett J, Shepherd FA. Characteristics and outcomes of small cell lung cancer patients diagnosed during two lung cancer computed tomographic screening programs in heavy smokers. J Thorac Oncol 2011; 6: 818–822.
61. Travis WD. Advances in neuroendocrine lung tumors. Ann Oncol 2010; 21 (Suppl. 7): vii65–vii71.
62. Govindan R, Page N, Morgensztern D et al. Changing epidemiology of small-cell lung cancer in the United States over the last 30 years: analysis of the surveillance, epidemiologic, and end results database. J Clin Oncol 2006; 24: 4539–4544.
63. Paci M, Cavazza A, Annessi V et al. Large cell neuroendocrine carcinoma of the lung: a 10-year clinicopathologic retrospective study. Ann Thorac Surg 2004; 77: 1163–1167.
64. Shepherd FA, Crowley J, Van HP et al. The International Association for the Study of Lung Cancer lung cancer staging project: proposals regarding the clinical staging of small cell lung cancer in the forthcoming (seventh) edition of the tumor, node, metastasis classification for lung cancer. J Thorac Oncol 2007; 2: 1067–1077.
65. Asamura H, Kameya T, Matsuno Y et al. Neuroendocrine neoplasms of the lung: a prognostic spectrum. J Clin Oncol 2006; 24: 70–76.
66. Brownson RC, Chang JC, Davis JR. Gender and histologic type variations in smoking-related risk of lung cancer. Epidemiology 1992; 3: 61–64.
67. Grabowski P, Schrader J, Wagner J et al. Loss of nuclear p27 expression and its prognostic role in relation to cyclin E and p53 mutation in gastroenteropancreatic neuroendocrine tumors. Clin Cancer Res 2008; 14: 7378–7384.
68. Swarts DR, Ramaekers FC, Speel EJ. Molecular and cellular biology of neuroendocrine lung tumors: evidence for separate biological entities. Biochim Biophys Acta 2012; 1826: 255–271.
69. Song J, Li M, Tretiakova M et al. Expression patterns of PAX5, c-Met, and paxillin in neuroendocrine tumors of the lung. Arch Pathol Lab Med 2010; 134: 1702–1705.
70. Capella C, Heitz PU, Hofler H et al. Revised classification of neuroendocrine tumours of the lung, pancreas and gut. Virchows Arch 1995; 425: 547–560.
71. Sun L, Sakurai S, Sano T et al. High-grade neuroendocrine carcinoma of the lung: comparative clinicopathological study of large cell neuroendocrine carcinoma and small cell lung carcinoma. Pathol Int 2009; 59: 522–529.
72. Shepherd FA, Evans WK, Feld R et al. Adjuvant chemotherapy following surgical resection for small-cell carcinoma of the lung. J Clin Oncol 1988; 6: 832–838.
73. Inoue M, Sawabata N, Okumura M. Surgical intervention for small-cell lung cancer: what is the surgical role? Gen Thorac Cardiovasc Surg 2012; 60: 401–405.
74. Fernandez FG, Battafarano RJ. Large-cell neuroendocrine carcinoma of the lung. Cancer Control 2006; 13: 270–275.
75. Sundstrom S, Bremnes RM, Kaasa S et al. Cisplatin and etoposide regimen is superior to cyclophosphamide, epirubicin, and vincristine regimen in small-cell lung cancer: results from a randomized phase III trial with 5 years' follow-up. J Clin Oncol 2002; 20: 4665–4672.
76. Iyoda A, Hiroshima K, Moriya Y et al. Prospective study of adjuvant chemotherapy for pulmonary large cell neuroendocrine carcinoma. Ann Thorac Surg 2006; 82: 1802–1807.
77. Yamazaki S, Sekine I, Matsuno Y et al. Clinical responses of large cell neuroendocrine carcinoma of the lung to cisplatin-based chemotherapy. Lung Cancer 2005; 49: 217–223.
78. Phan AT, Oberg K, Choi J et al. NANETS consensus guideline for the diagnosis and management of neuroendocrine tumors: well-differentiated neuroendocrine tumors of the thorax (includes lung and thymus). Pancreas 2010; 39: 784–798.
79. Mazieres J, Daste G, Molinier L et al. Large cell neuroendocrine carcinoma of the lung: pathological study and clinical outcome of 18 resected cases. Lung Cancer 2002; 37: 287–292.
80. Pignon JP, Arriagada R, Ihde DC et al. A meta-analysis of thoracic radiotherapy for small-cell lung cancer. N Engl J Med 1992; 327: 1618–1624.
81. Glisson BS, Moran CA. Large-cell neuroendocrine carcinoma: controversies in diagnosis and treatment. J Natl Compr Canc Netw 2011; 9: 1122–1129.
82. Kayani I, Conry BG, Groves AM et al. A comparison of 68Ga-DOTATATE and 18F-FDG PET/CT in pulmonary neuroendocrine tumors. J Nucl Med 2009; 50: 1927–1932.
83. Yeh J, Litz J, Hauck P et al. Selective inhibition of SCLC growth by the A12 anti-IGF-1R monoclonal antibody correlates with inhibition of Akt. Lung Cancer 2008; 60: 166–174.
84. Rossi G, Cavazza A, Marchioni A et al. Role of chemotherapy and the receptor tyrosine kinases KIT, PDGFRalpha, PDGFRbeta, and Met in large-cell neuroendocrine carcinoma of the lung. J Clin Oncol 2005; 23: 8774–8785.
85. Nagy-Mignotte H, Guillem P, Vignoud L et al. Outcomes in recurrent small-cell lung cancer after one to four chemotherapy lines: a retrospective study of 300 patients. Lung Cancer 2012; 78: 112–120.
86. Sarkaria IS, Iyoda A, Roh MS et al. Neoadjuvant and adjuvant chemotherapy in resected pulmonary large cell neuroendocrine carcinomas: a single institution experience. Ann Thorac Surg 2011; 92: 1180–1186.
87. Faggiano A, Ferolla P, Grimaldi F et al. Natural history of gastro-enteropancreatic and thoracic neuroendocrine tumors. Data from a large prospective and retrospective Italian epidemiological study: the NET management study. J Endocrinol Invest 2012; 35: 817–823.
88. Deutschbein T, Unger N, Yuece A et al. Chemotherapy in patients with progressive, undifferentiated neuroendocrine tumors: a single-center experience. Horm Metab Res 2011; 43: 838–843.
89. Patta A, Fakih M. First-line cisplatin plus etoposide in high-grade metastatic neuroendocrine tumors of colon and rectum (MCRC NET): review of 8 cases. Anticancer Res 2011; 31: 975–978.
90. Fjallskog ML, Granberg DP, Welin SL et al. Treatment with cisplatin and etoposide in patients with neuroendocrine tumors. Cancer 2001; 92: 1101–1107.