



# The effects of cryptorchidism on the regulation of steroidogenesis and gap junctional communication in equine testes

Wpływ wnętrstwa na regulację procesu steroidogenezy i komunikację międzykomórkową w jądrach konia

Anna Hejmej, Barbara Bilińska

Department of Endocrinology and Tissue Culture, Institute of Zoology, Jagiellonian University, Krakow

## Abstract

**Introduction:** Evidence collected over the years has demonstrated that cryptorchidism is associated with a defect in spermatogenesis and, as a consequence, with either reduced fertility or infertility. However, the effect of cryptorchidism on Leydig cell function is less clear. The aim of our study therefore was to investigate the regulation of steroid hormone biosynthesis and, additionally, intercellular communication in the cryptorchid equine testes.

**Material and methods:** Testes of mature bilaterally cryptorchid horse and healthy stallions were used for this study. The expression of luteinising hormone receptor (LHR),  $3\beta$ -hydroxysteroid dehydrogenase ( $3\beta$ -HSD), aromatase and connexin43 (Cx43) was detected by means of immunohistochemistry. Testosterone and oestradiol levels were measured in testicular homogenates using appropriate radioimmunoassays.

**Results:** In the testes of both normal and cryptorchid stallions, immunostaining for LHR,  $3\beta$ -HSD and aromatase was confined to the Leydig cells. In the cryptorchid horse, the intensity of the staining for LHR and  $3\beta$ -HSD was weaker, whereas the staining for aromatase was clearly stronger than that of the normal stallion. Radioimmunological analysis revealed disturbance of the androgen-oestrogen balance in the cryptorchid testes. Additionally, in both the seminiferous tubules and interstitial tissue of the cryptorchid a clear reduction of the Cx43 signal was observed.

**Conclusions:** Decreased expression of LHR and  $3\beta$ -HSD and increased expression of aromatase in the cryptorchid testes suggest that hormonal imbalance was caused both by reduced testosterone synthesis and by increased androgen aromatisation. Impaired expression of Cx43 in the seminiferous tubules as well as in the interstitial tissue of the cryptorchid horse indicates that cryptorchidism affects intercellular communication in the testes. (*Pol J Endocrinol* 2008; 59 (2): 112–118)

**Key words:** cryptorchidism, stallion, steroidogenesis, connexin43, immunohistochemistry

## Streszczenie

**Wstęp:** Liczne badania wykazały, że wnętrstwo wiąże się z występowaniem nieprawidłowości w przebiegu procesu spermatogenezy, prowadzących do zaburzeń płodności. Natomiast słabiej poznano zmiany funkcjonalne w komórkach Leydiga. Stąd celem niniejszej pracy było określenie wpływu wnętrstwa na regulację biosyntezy androgenów i estrogenów, a dodatkowo także na komunikację międzykomórkową w jądrach konia.

**Materiał i metody:** Materiał badawczy stanowiły jądra dojrzałego konia z obustronnym wrodzonym wnętrstwem brzuszным oraz gonady zdrowych dojrzałych ogierów. Ekspresję receptora LH (LHR), dehydrogenazy  $3\beta$ -hydroksysteroidowej ( $3\beta$ -HSD), aromatazy oraz koneksyny 43 (Cx43) badano metodami immunohistochemicznymi, natomiast stężenia hormonów steroidowych, testosteronu i estradiolu, w gonadzie oznaczano techniką radioimmunologiczną.

**Wyniki:** Zarówno w jądrach ogierów kontrolnych, jak i wnętrza, obecność receptora LH,  $3\beta$ -HSD i aromatazy wykryto jedynie w komórkach Leydiga. W niezstąpionych jądrach wykazano spadek immunoekspresji LHR i  $3\beta$ -HSD, zaś wzrost ekspresji aromatazy w stosunku do jąder zwierząt kontrolnych. W jądrach wnętrza stwierdzono ponadto obniżone stężenie testosteronu i podwyższone stężenie estradiolu. Ekspresja Cx43 była znacznie zredukowana w zdegenerowanych kanalikach nasiennych oraz w komórkach Leydiga niezstąpionych jąder.

**Wnioski:** Obniżona — wskutek niedostatecznej stymulacji przez gonadotropiny — produkcja testosteronu i zwiększona aromatyzacja testosteronu do estradiolu mogą stanowić przyczynę zaburzenia równowagi między androgenami a estrogenami w niezstąpionych jądrach. Zredukowana ekspresja Cx43 w kanaliku plemnikotwórczym oraz w tkance interstycjalnej u ogiera wnętrza wskazuje na nieprawidłowości w bezpośredniej komunikacji międzykomórkowej w niezstąpionych jądrach. (*Endokrynol Pol* 2008; 59 (2): 112–118)

**Słowa kluczowe:** wnętrstwo, ogier, steroidogeneza, koneksyna 43, immunohistochemia

Supported by DS/IZ/BiNoZ/770/2007.



Anna Hejmej, M.D., Department of Endocrinology and Tissue Culture, Institute of Zoology, Jagiellonian University, ul. Ingardena 6, 30-060 Kraków, e-mail: a.hejmej@op.pl.

## Introduction

Cryptorchidism is a congenital anomaly in which one (unilateral cryptorchidism) or both (bilateral cryptorchidism) testes fail to descend into the scrotum. In most mammalian species the testis in the scrotum is kept at 4–5°C below body temperature. Multiple studies indicate that abdominal temperature negatively influences the development and differentiation of testicular somatic and germ cells [1–4]. Disruption of spermatogenesis may also be a result of a hypothalamic-pituitary-gonadal axis defect. Major clinical consequences of cryptorchidism are a high risk of infertility and testicular malignancy in adulthood [5, 6]. Most studies on alterations in the cryptorchid testes of adult animals have been performed on rodents with the testes surgically moved to the abdomen [7]. Such studies enable the effect of increased temperature on mature testes to be explained but are not adequate for a full understanding of testicular dysfunction in adult mammals with congenital cryptorchidism. Large domestic animals, in which undescended testes are a common problem, may be useful models for the study of naturally occurring cryptorchidism. In stallions the incidence of unilateral cryptorchidism is much higher than bilateral cryptorchidism [8]. In practice undescended testes are usually removed in young immature horses. The adult stallion with bilaterally retained testes is therefore a unique and especially interesting model for the study of congenital cryptorchidism.

The aim of the present study was to investigate the effect of cryptorchidism on the regulation of androgen and oestrogen biosynthesis and, additionally, on intercellular communication in the testes. Thus the expression of luteinising hormone receptor (LHR), 3 $\beta$ -hydroxysteroid dehydrogenase (3 $\beta$ -HSD), aromatase and connexin43 (Cx43) was examined in the testes of cryptorchid and control stallions.

## Material and methods

### Animals

Four-year-old Hucul stallion with bilaterally abdominal testes and three 5-year-old Hucul stallions without signs of reproductive system disease were used for this study. The testes were obtained from a slaughterhouse during the breeding season and immediately transferred to the laboratory. Small fragments of testicular tissue were fixed in 4% formaldehyde and embedded in paraplast or homogenised.

All procedures were performed in accordance with Polish legal requirements under the licence granted by the National Commission of Bioethics at the Jagiellonian University and also with the recommendations

contained in "Interdisciplinary Principles and Guidelines for the Use of Animals in Research, Testing and Education" issued by the Ad Hoc Committee on Animal Research of the New York Academy of Sciences.

### Immunohistochemistry

Immunohistochemistry was performed on deparaffinised and rehydrated 5  $\mu$ m paraplast sections. To optimise the staining, slices were immersed in 10 mM citrate buffer (pH 6.0) using the high temperature unmasking technique (2  $\times$  4 min, 650 W).

### ABC method

Non-specific staining was blocked twice: with 3% H<sub>2</sub>O<sub>2</sub> in methanol for 10 min and then with 5% normal goat serum for 15 min. Next, sections were incubated overnight at 4°C in a humidified chamber in the presence of primary antibodies:

- 1) a rabbit polyclonal antibody against LHR (1:10, Biotrend Chemikalien GmbH, Köln, Germany);
- 2) a rabbit polyclonal antibody against 3 $\beta$ -HSD (1:1500, a gift from Prof. Anita H. Payne, Stanford University Medical Center, San Francisco, CA, USA);
- 3) a rabbit polyclonal antibody against human placental aromatase (1:400, a gift from Dr. Yoshiro Osawa, Hauptman-Woodward Medical Research Institute, Buffalo, NY, USA).

Subsequently, biotinylated secondary antibody, goat anti-rabbit IgG (1:400, Vector Lab., Burlingame, CA, USA), was applied for 60 min. Finally, avidin-biotinylated horseradish peroxidase complex (StreptABCComplex-HRP, 1:100, Dako, Glostrup, Denmark) was used. After each step in these procedures sections were carefully rinsed with Tris-buffered saline (0.05 M Tris/HCl; 0.15 NaCl pH 7.4). Staining was performed by using 0.05% 3,3'-diaminobenzidine tetrachloride in TBS for 4 min. Finally, the sections were counterstained with Mayer's haematoxylin. The sections were processed immunohistochemically at the same time with the same treatment so that the staining intensities of testicular cells could be compared. Tissues incubated with normal goat serum devoid of primary antibodies were used as negative control.

The sections were examined with a Leica DMR microscope (Germany) using Nomarski interference contrast. Analysis of the immunohistochemistry was performed with public domain ImageJ software. The intensity of immunohistochemical staining was expressed as relative optical density (ROD) [9]. The data were statistically evaluated by Student's *t*-test, with significance set at \**p* < 0.05.

### Immunofluorescence

The sections were incubated at 4°C in a humidified chamber in the presence of primary polyclonal antibo-

dy against Cx43 (1:2000, Sigma, St Louis, MO, USA) for 24 h. Next, secondary antibody, tetramethyl rhodamine isothiocyanate (TRITC)-labelled goat anti-rabbit IgG (1:80, Sigma, St Louis, MO, USA) was used for 1.5 h. After each step in these procedures the sections were carefully rinsed with Tris-buffered saline (0.05 M Tris/HCl; 0.15 NaCl pH 7.4). Negative control was incubated in the presence of normal goat serum instead of the primary antibody. The sections were examined with a confocal microscope, LSM 510 META, Axiovert 200 M, ConfoCor3 (Carl Zeiss MicroImaging GmbH, Jena, Germany).

### Radioimmunological analysis

Homogenised testicular tissues from both the stallions and the cryptorchid were used for radioimmunological determination of testosterone [10] and oestradiol [11] levels. For testosterone and oestradiol assays 0.2 ml of each homogenate was extracted with 2.5 ml ethyl ether. Testosterone levels were assessed using [1,2,6,7-<sup>3</sup>H]-testosterone (The Radiochemical Centre, Nycomed Amersham, Buckinghamshire, England), specific activity, 88.0 Ci/mmol, as a tracer and antibody raised in rabbit against testosterone-3-*o*-carboxymethyl-oxime-bovine serum albumin (BSA), whereas oestradiol concentrations were determined using [2,4,6,7-<sup>3</sup>H]-oestradiol (The Radiochemical Centre, Nycomed Amersham, Buckinghamshire, England), specific activity, 140 Ci/mmol, as tracer and an antibody raised in rabbit against oestradiol 17 $\beta$ -6-oxime-BSA. Both assays were validated by demonstrating parallelism between serial dilutions of testicular homogenates and standard curve. Coefficients of variation within and between testosterone assays were 7.6% and 9.8% respectively, while within and between oestradiol assays they were 3.3% and 7.4% respectively. The recovery of unlabelled testosterone and oestradiol was also assessed (never less than 90% and 88%, respectively).

### Statistical analysis

The data were statistically evaluated by the Student's *t*-test, with significance set at \**p* < 0.05. The values are expressed as mean  $\pm$  standard error of the mean (SEM). All samples were assayed in triplicate. In case of the cryptorchid horse, both testes were used for radioimmunological analyses.

## Results

### Immunohistochemical localisation of LHR, 3 $\beta$ -HSD and aromatase

Both in the normal and in the cryptorchid stallions immunostaining for LHR, 3 $\beta$ -HSD and aromatase was restricted to the Leydig cells. In the control stallions the

intensity of the staining for LHR and 3 $\beta$ -HSD was strong (Fig. 1A, 1C), whereas in the cryptorchid stallion very weak staining was observed (Fig. 1B, 1D).

Individual cells in the Leydig cell clusters stained heterogeneously for aromatase (Fig. 1E). However, in the cryptorchid testes the intensity of the staining was stronger than in those of the control (Fig. 1F).

Quantitative evaluation of the intensity of immunohistochemical staining for LHR, 3 $\beta$ -HSD and aromatase in the Leydig cells, expressed as ROD, confirmed the qualitative data. There were statistically significant differences in the immunoexpression of LHR, 3 $\beta$ -HSD and aromatase between the Leydig cells of the control and those of the cryptorchid stallions (Table I).

No positive staining was observed when the primary antibodies were omitted (Fig. 1A, 1C, 1F — inserts).

### Immunofluorescent localisation of Cx43

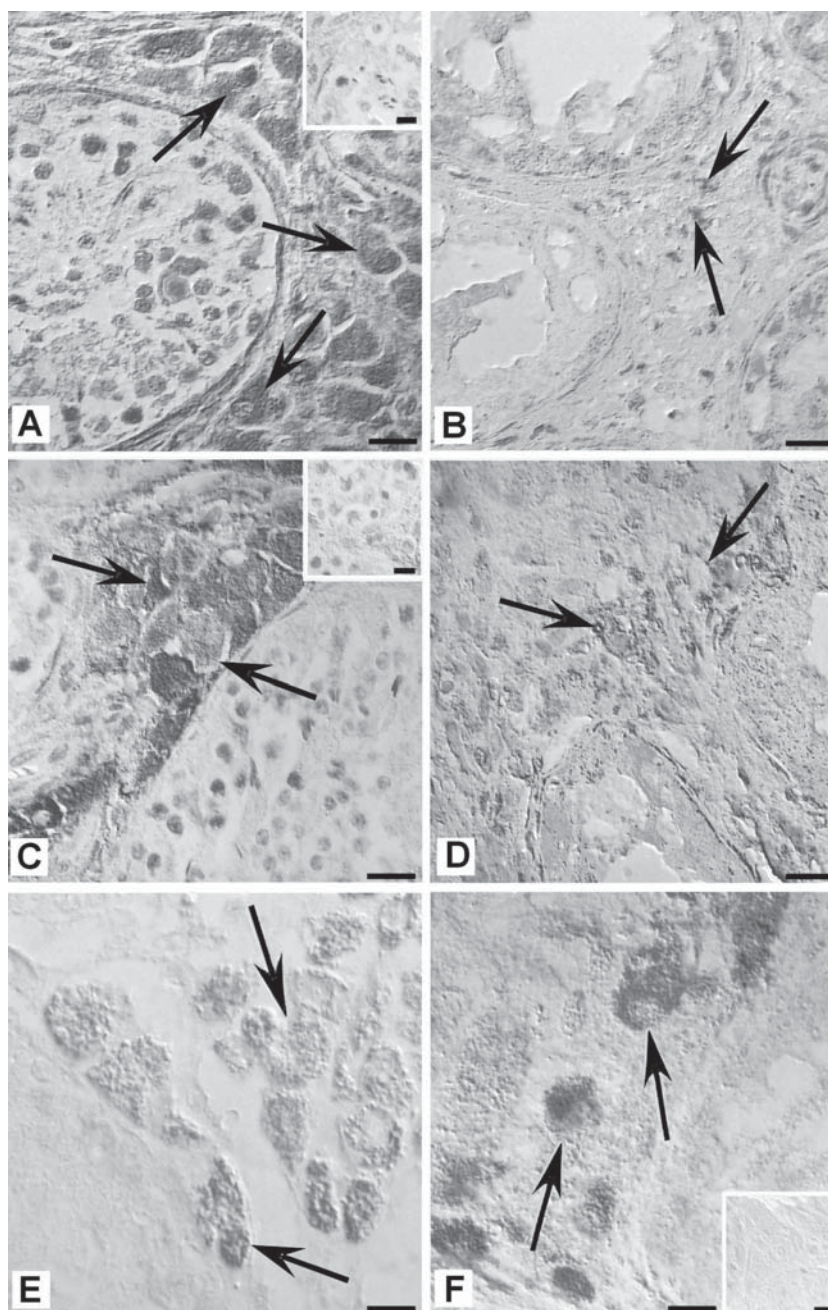
In the testes of normal stallions the most intense signal indicating the presence of Cx43 was located in the basal compartment of the seminiferous epithelium and in the Leydig cells (Fig. 2A, 2C). In the cryptorchid testes staining for Cx43 was observed only in the seminiferous tubules that contained spermatogonia, whereas no signal was detected in completely degenerated tubules depleted of germ cells. In the Leydig cells the intensity of the signal was clearly reduced (Fig. 2B, 2D). No positive signal was observed when the primary antibody was omitted (Fig. 2A — insert).

### Radioimmunological analysis of steroid hormones levels

Radioimmunological analysis revealed differences in steroid hormone levels between the testicular homogenates of the control stallion and those of the cryptorchid. Testosterone level was lower in the cryptorchid than in the normal stallions ( $7.4 \pm 0.2$  ng/100 mg tissue *vs.*  $4.0 \pm 0.4$  ng/100 mg tissue) (Fig. 3A). In contrast, the oestradiol level was significantly higher in the cryptorchid than in the controls ( $7.8 \pm 0.7$  ng/100 mg tissue *vs.*  $3.7 \pm 0.1$  ng/100 mg tissue) (Fig. 3B).

## Discussion

Steroidogenesis in the Leydig cells is regulated mainly by LH, the pituitary hormone that acts on target cells through membrane receptor, LHR. Our study has shown that in the testes of the stallion LHR is localised only in the Leydig cells, as previously described in other mammals [12]. The present findings corroborate the studies on human and rodent cryptorchid testes, indicating reduced expression of this receptor [13–15]. Moreover, in the cryptorchid horse a decrease was found in the expression of 3 $\beta$ -HSD, the enzyme that catalyses



**Figure 1.** Immunohistochemical localisation of LHR (A, B),  $3\beta$ -HSD (C, D) and aromatase (E, F) in the testes of normal (A, C, E) and cryptorchid stallion (B, D, F). Counterstaining with Mayer's haematoxylin (A–D). The presence of LHR (A),  $3\beta$ -HSD (C) and aromatase (E) is confined to Leydig cells (arrows). Note a clearly weaker staining for LHR (B) and  $3\beta$ -HSD (D) and stronger staining for aromatase (F) in the cryptorchid horse than for the healthy stallion. Control tissue sections of the testes show no immunostaining when the incubation was performed without the primary antibody (A, C, F — inserts). Bar = 20  $\mu$ m

**Rycina 1.** Immunohistochemiczna lokalizacja LHR (A, B),  $3\beta$ -HSD (C, D) i aromatazy (E, F) w jądrach ogiera kontrolnego (A, C, E) i wnętrza (B, D, F). Jądra komórkowe na zdjęciach A–D podbarwione hematoksyliną. W jądrach zdrowego konia LHR (A),  $3\beta$ -HSD (C) i aromataza (E) obecne są tylko w komórkach Leydiga (strzałki). W komórkach Leydiga ogiera wnętrza widoczny znaczny spadek intensywności reakcji na obecność LHR (B) i  $3\beta$ -HSD (D) oraz wzrost immunоекспresji aromatazy (F). Wstawki na zdjęciach A, C i F — negatywne kontrole reakcji immunohistochemicznych. Bar = 20  $\mu$ m

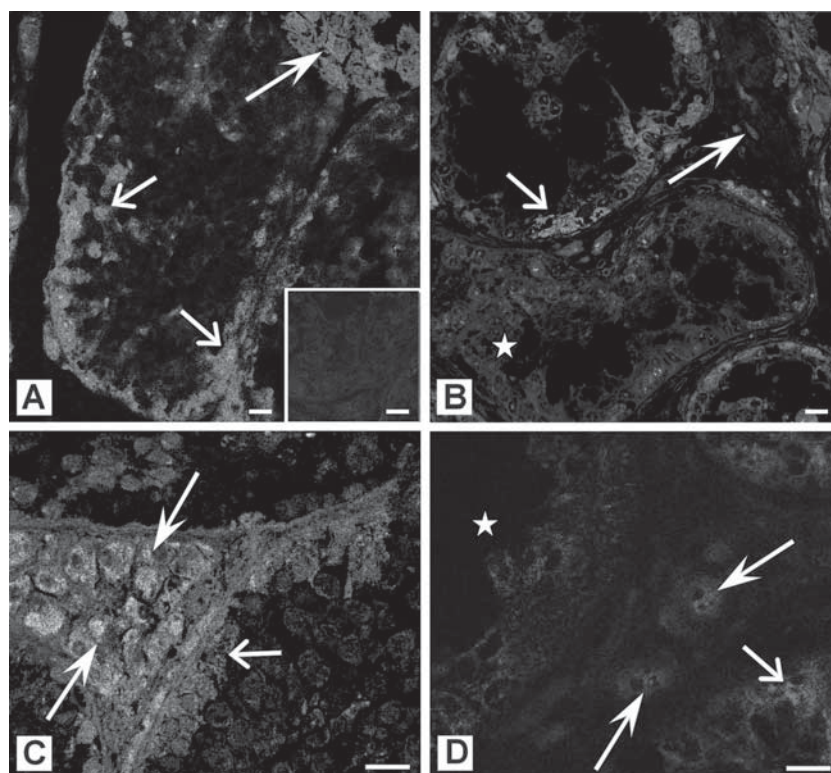
the conversion of delta 5- $3\beta$ -hydroxysteroids to delta 4-3-ketosteroids. This is in line with data showing reduced activity of  $3\beta$ -HSD in rats with experimentally induced cryptorchidism [16]. It seems likely that the

decreased testosterone concentration in the undescended testes of the horse is a result of reduced LHR and  $3\beta$ -HSD expression. Low testosterone levels have previously been detected in cryptorchid mice, stallions and

**Table I.** Intensity of immunohistochemical staining for LHR,  $3\beta$ -HSD and aromatase in the Leydig cells of control and cryptorchid stallion, expressed as the relative optical density (ROD) of diaminobenzidine brown reaction product. Values are means  $\pm$  SD; \* $p < 0.05$

**Tabela I.** Intensywność barwienia immunohistochemicznego na obecność LHR,  $3\beta$ -HSD i aromatazy w komórkach Leydiga ogiera kontrolnego i wnętrza, wyrażona jako względna gęstość optyczna (ROD) produktu reakcji z diaminobenzydyną. Wartości przedstawione jako średnia  $\pm$  SD; \* $p < 0,05$

LHR		$3\beta$ -HSD		Aromatase	
Control	Cryptorchid	Control	Cryptorchid	Control	Cryptorchid
3.18 $\pm$ 0.08	1.48 $\pm$ 0.14*	2.54 $\pm$ 0.26	1.36 $\pm$ 0.08*	1.83 $\pm$ 0.19	2.53 $\pm$ 0.16*



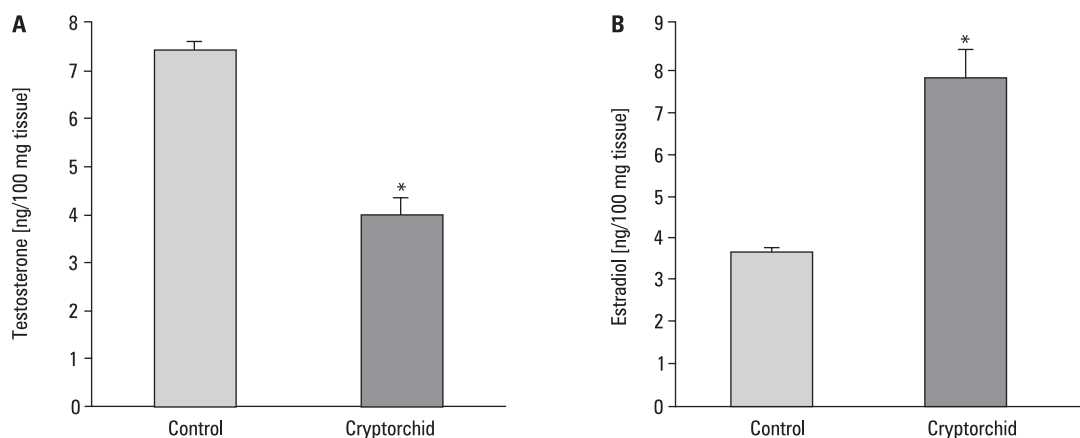
**Figure 2.** Immunofluorescent localisation of Cx43 in the testes of normal (A, C) and cryptorchid stallion (B, D). In normal testes a strong signal is visible in the Leydig cells (bold arrows) and in the basal compartment of the seminiferous tubules (open arrows) (A, C). Note a clearly reduced signal in the Leydig cells and in the degenerative seminiferous epithelium of the cryptorchid (asterisks) (B, D). Control tissue sections of the testes showed no immunostaining for Cx43 when the incubation was performed without the primary antibody (A — insert). Bar = 20  $\mu$ m

**Rycina 2.** Immunofluorescencyjna lokalizacja koneksyny 43 w jądrach zdrowego ogiera (A, C) i wnętrza (B, D). Mocny sygnał widoczny w komórkach Leydiga (duże strzałki) oraz w przypadkowym rejonie nabłonka plemnikotwórczego (strzałki bez wypełnienia) zdrowego konia (A, C). Znaczna redukcja intensywności sygnału w komórkach Leydiga oraz w zdegenerowanych kanalikach nasiennych ogiera wnętrza (gwiazdki) (B, D). Wstawka na zdjęciu A — negatywna kontrola reakcji. Bar = 20  $\mu$ m

dogs [17–19]. On the other hand, Ryan et al. [20] and Ren et al. [21] observed no significant changes in testosterone levels in cryptorchid stallions, boars and rats.

Our study revealed increased aromatase immunoproduction and high oestradiol levels in the testes of the cryptorchid stallion. These results are consistent with data obtained by Bilińska et al. [17] and Kawakami et al. [19] in mice and dogs with experimentally induced

cryptorchidism. Thus it may be suggested that the reduced testosterone level is a result, not only of decreased synthesis of this steroid, but also of increased conversion of androgens into oestrogens. It is interesting to note that similar alterations in testicular steroidogenesis were observed in LHR knockout mice. In the undescended testes of these mice, a reduction in the immunoproduction of  $3\beta$ -HSD, decreased te-



**Figure 3.** Testosterone (A) and oestradiol (B) levels in the testicular homogenates of normal and cryptorchid stallion. \*  $p < 0.05$   
**Rycina 3.** Poziomy testosteronu (A) i estrogenów (B) w homogenatach jąder ogierów kontrolnych i ogiera wnetra. \*  $p < 0,05$

stosterone levels and increased oestradiol levels were detected [22].

Numerous studies have provided evidence that oestrogens play a role in regulating reproductive function in the male. They are involved in the negative feedback effects of testosterone on the brain to control pituitary gonadotropin secretion. Oestrogens also act directly on the male reproductive system, modulating functions of testicular somatic and germ cells as well as of efferent ductules and epididymis [23, 24]. However, an increased level of oestrogens has a deleterious effect on testicular function and male fertility [25, 26]. It has already been accepted that these alterations are induced by disruption of the androgen-oestrogen balance [27]. It may therefore be suggested that hormonal imbalance is one of reasons for degenerative changes in the cryptorchid testes.

In addition to endocrine and paracrine controls, intercellular channels, called gap junctions, play an essential role in the regulation of the male reproductive system. Gap junctions that are formed by a multigene family of proteins named connexins allow direct exchange between adjacent cells. The predominant connexin in human and rodent testis is connexin43 (Cx43) [28]. The results presented show that in the testes of the stallion Cx43 is located in both the seminiferous tubules and interstitial tissue. In the seminiferous tubules of the horse this protein is distributed mainly in the basal compartment as previously described in human and rodent testes [29–31]. The expression of Cx43 in seminiferous tubules of the cryptorchid horse appears to be dependent on the severity of seminiferous degeneration: a signal was detected only in the tubules containing germ cells. This is in agreement with the previous studies of Steger et al. [29] and Batias et al. [32] showing lack of Cx43 in human and murine seminiferous tubules with Sertoli cell only syndrome (SOS). These results

suggest that expression of this protein is associated with the presence of germ cells. Reduced expression of Cx43 in the Sertoli cells of the cryptorchid may also be caused in part by an androgen-oestrogen imbalance. This hypothesis is consistent with results obtained by Fiorini et al. [33]. According to these authors exposure to oestrogen-like compounds (bisphenol A and *tert*-octylphenol) leads to a reduction in the Cx43 level in the Sertoli cells. On the other hand, Defamie et al. [34] suggest that impaired expression of Cx43 in degenerated seminiferous tubules may be an effect of altered Sertoli cell differentiation.

In the Leydig cells of the cryptorchid horse, the Cx43 signal was clearly reduced when compared to that of the normal stallion. To date Cx43 has been the only connexin detected in the Leydig cells of different species, but its role in the control of Leydig cell function has not been yet determined [28]. Results of recent studies on transgenic mice lacking Cx43 revealed that Cx43 is not as important for the control of steroidogenesis as was hypothesised previously [35]. It is worth mentioning that in mice with Leydig cell tumours impaired expression and delocalisation of Cx43 was observed. According to the authors, altered expression of this protein may be a result of uncontrolled proliferation and dedifferentiation of neoplastic cells [36]. It is thus possible that decreased Cx43 immunexpression indicates altered differentiation or maturation of the Leydig cells of the cryptorchid horse.

## Conclusion

The present findings revealed that naturally occurring cryptorchidism in the horse is associated with Leydig cell dysfunction and an altered balance between androgens and oestrogens in the undescended testes. Decre-

ased expression of LHR and  $3\beta$ -HSD and increased expression of aromatase in the cryptorchid testes may suggest that hormonal imbalance is caused both by reduced testosterone synthesis and by increased androgen aromatisation. Impaired expression of Cx43 in the seminiferous tubules as well as in the interstitial tissue indicates that cryptorchidism affects intercellular communication in both testicular compartments.

## Acknowledgements

The authors are grateful to Professor Kazimierz Kosiniak-Kamysz (Department of Horse Breeding, Agricultural University, Kraków, Poland) for a generous donation of equine tissues. The authors would like to thank Professor Elżbieta Pyza, Director of the Division of Scanning Confocal Microscopy, Institute of Zoology, Jagiellonian University for providing confocal microscopy facilities (LSM 510 META, Axiovert 200 M, ConfoCor3; Carl Zeiss MicroImaging GmbH, Jena, Germany).

This work is a part of doctoral thesis (A.H.) and was presented at the Congress of the Polish Society of Andrology, Kazimierz Dolny, Poland, 2007.

## References

- Pinart E, Sancho S, Briz MD et al. Ultrastructural study of the boar seminiferous epithelium: changes in cryptorchidism. *J Morphol* 2000; 244: 190–202.
- Pinart E, Bonet S, Briz M et al. Histochemical study of the interstitial tissue in scrotal and abdominal boar testes. *Vet J* 2002; 163: 68–76.
- Huff DS, Fenig DM, Canning DA et al. Abnormal germ cell development in cryptorchidism. *Horm Res* 2001; 55: 11–17.
- Kotula-Balak M, Wojciechowska J, Bilińska B. The site of aromatization in the mouse cryptorchid testis. *Folia Biol (Krakow)* 2001; 49: 279–283.
- Kaleva M, Toppari J. Cryptorchidism: an indicator of testicular dysgenesis? *Cell Tissue Res* 2005; 322: 167–172.
- Virtanen HE, Bjerknes R, Cortes D et al. Cryptorchidism: classification, prevalence and long-term consequences. *Acta Paediatr* 2007; 96: 611–616.
- Bergh A, Söder O. Studies of cryptorchidism in experimental animal models. *Acta Paediatr* 2007; 96: 617–621.
- Searle D, Dart AJ, Dart CM et al. Equine castration: review of anatomy, approaches, techniques and complications in normal, cryptorchid and monorchid horses. *Aust Vet J* 1999; 77: 428–34.
- Smolen AJ. Image analytic techniques for quantification of immunocytochemical staining in the nervous system. In: Conn PM (ed.). *Methods in Neurosciences*. Academic Press, San Diego 1990; 208–229.
- Dufau ML, Catt KJ, Tsuruhara T et al. Radioimmunoassay of plasma testosterone. *Clin Chim Acta* 1972; 37: 109–116.
- Hotchkiss J, Atkinson LE, Knobil E. Time course of serum estrogen and luteinizing hormone (LH) concentrations during the menstrual cycle of the rhesus monkey. *Endocrinology* 1971; 89: 177–183.
- Ascoli M, Fanelli F, Segaloff DL. The lutropin/choriogonadotropin receptor, a 2002 perspective. *Endocr Rev* 2002; 23: 141–174.
- Huhtaniemi I, Bergh A, Nikula H et al. Differences in the regulation of steroidogenesis and tropic hormone receptors between the scrotal and abdominal testes of unilaterally cryptorchid adult rats. *Endocrinology* 1984; 115: 550–555.
- Hovatta O, Huhtaniemi I, Wahlstrom T. Testicular gonadotrophins and their receptors in human cryptorchidism as revealed by immunohistochemistry and radioreceptor assay. *Acta Endocrinol (Copenh)* 1986; 111: 128–132.
- Tena-Sempere M, Kero J, Rannikko A et al. Experimental cryptorchidism induces a change in the pattern of expression of LH receptor mRNA in rat testis after selective Leydig cell destruction by ethylene dimethane sulfonate. *J Endocrinol* 1999; 161: 131–141.
- Wisner JR Jr, Gomes WR. Influence of experimental cryptorchidism on cholesterol side-chain cleavage enzyme and delta5-3beta-hydroxysteroid dehydrogenase activities in rat testes. *Steroids* 1978; 31: 189–203.
- Bilińska B, Kotula-Balak M, Gancarczyk M et al. Androgen aromatization in cryptorchid mouse testis. *Acta Histochem* 2003; 105: 57–165.
- Illera JC, Silvan G, Munro CJ et al. Amplified androstenedione enzyme-immunoassay for the diagnosis of cryptorchidism in the male horse: comparison with testosterone and estrone sulphate methods. *J Steroid Biochem Mol Biol* 2003; 84: 377–382.
- Kawakami E, Hori T, Tsutsui T. Function of contralateral testis after artificial unilateral cryptorchidism in dogs. *J Vet Med Sci* 1999; 61: 1107–1111.
- Ryan PL, Friendship RM, Raeside JI. Impaired estrogen production by Leydig cells of the naturally retained testis in unilaterally cryptorchid boars and stallions. *J Androl* 1986; 7: 100–104.
- Ren L, Medan MS, Ozu M et al. Effects of experimental cryptorchidism on sperm motility and testicular endocrinology in adult male rats. *J Reprod Dev* 2006; 52: 219–228.
- Lei ZM, Mishra S, Ponnuru P et al. Testicular phenotype in luteinizing hormone receptor knockout animals and the effect of testosterone replacement therapy. *Biol Reprod* 2004; 71: 1605–1613.
- O'Donnell L, Robertson KM, Jones ME et al. Estrogen and spermatogenesis. *Endocr Rev* 2001; 22: 289–318.
- Hess RA. Estrogen in the adult male reproductive tract: a review. *Reprod Biol Endocrinol* 2003; 1: 52.
- Toyama Y, Hosoi I, Ichikawa S et al. b-estradiol 3-benzoate affects spermatogenesis in the adult mouse. *Mol Cell Endocrinol* 2001; 178: 161–168.
- Gancarczyk M, Paziewska-Hejmej A, Carreau S et al. Dose- and photo-period-dependent effects of 17beta-estradiol and the anti-estrogen ICI 162,780 on testicular structure, acceleration of spermatogenesis, and aromatase immunoeexpression in immature bank voles. *Acta Histochem* 2004; 106: 269–278.
- Williams K, McKinnell C, Saunders PT et al. Neonatal exposure to potent and environmental oestrogens and abnormalities of the male reproductive system in the rat: evidence for importance of androgen-oestrogen balance and assessment of the relevance to man. *Hum Reprod Update* 2001; 7: 236–247.
- Pointis G, Fiorini C, Defamie N et al. Gap junctional communication in the male reproductive system. *Biochim Biophys Acta* 2005; 1719: 102–116.
- Steger K, Tetens F, Bergmann M. Expression of connexin 43 in human testis. *Histochem Cell Biol* 1999; 112: 215–220.
- Batias C, Defamie N, Lablack A et al. Modified expression of testicular gap-junction connexin 43 during normal spermatogenic cycle and in altered spermatogenesis. *Cell Tissue Res* 1999; 298: 113–121.
- Risley MS, Tan IP, Roy C et al. Cell-, age- and stage-dependent distribution of connexin43 gap junctions in testes. *J Cell Sci* 1992; 103: 81–96.
- Batias C, Siffroi JP, Fenichel P et al. Connexin43 gene expression and regulation in the rodent seminiferous epithelium. *J Histochem Cytochem* 2000; 48: 793–805.
- Fiorini C, Tilloy-Ellul A, Chevalier S et al. Sertoli cell junctional proteins as early targets for different classes of reproductive toxicants. *Reprod Toxicol* 2004; 18: 413–421.
- Defamie N, Berthaut I, Mograbi B et al. Impaired gap junction connexin43 in Sertoli cells of patients with secretory azoospermia: a marker of undifferentiated Sertoli cells. *Lab Invest* 2003; 83: 449–456.
- Kahiri CN, Khalil MW, Tekpetey F et al. Leydig cell function in mice lacking connexin43. *Reproduction* 2006; 132: 607–616.
- Segretain D, Decrouy X, Dompierre J et al. Sequestration of connexin43 in the early endosomes: an early event of Leydig cell tumor progression. *Mol Carcinog* 2003; 38: 179–187.