



Late diagnosis of type 2B multiple endocrine neoplasia (MEN 2B) in a 23 year-old patient

Późne rozpoznanie zespołu gruczolakowatości wewnątrzwydzielniczej typu 2 (MEN 2B) u 23-letniego pacjenta

Elżbieta Andrysiak-Mamos¹, Elżbieta Sowińska-Przepiera¹, Ewa Żochowska¹,
Agnieszka Kazimierczyk-Puchalska¹, Justyna Syrenicz¹, Jerzy Lubikowski², Bożena Birkenfeld³,
Anhell Syrenicz¹

¹Department of Endocrinology, Metabolic Diseases and Internal Diseases, Pomeranian Medical University, Szczecin, Poland

²Department of General and Transplantation Surgery, Westpomeranian Provincial Hospital in Szczecin, Poland

³Nuclear Medicine Department, Pomeranian Medical University, Szczecin, Poland

Abstract

We present a case of MEN 2B diagnosed in a 23 year-old patient on the basis of bilateral pheochromocytoma and medullary thyroid carcinoma. This young male patient also had multiple paragangliomas located along the spine, marfanoid features of body habitus and numerous mucosal neuromas of the oral cavity and intestinal ganglioneuromatosis. The patient was hospitalised several times between the ages of 11 and 14 due to heart rhythm disorders (tachycardia, multiple supraventricular beats) and pain in the precordial area. Elevated blood pressure was not observed at that time. In 2010, the patient was admitted to hospital due to abdominal pain, nausea, vomiting and hypertension; bilateral adrenal tumours were then detected. The patient was referred to the Department of Endocrinology in Szczecin, with suspected pheochromocytoma in order to continue the diagnostic process. This resulted in the diagnosis of bilateral pheochromocytoma and medullary thyroid carcinoma. On the basis of the whole clinical picture, the diagnosis of MEN 2B was established and subsequently confirmed with genetic test results. Following the removal of adrenal tumours and thyroidectomy, the patient was referred to the Cancer Centre and Institute of Oncology in Gliwice for further treatment (X-ray therapy and further surgery due to recurrence of medullary carcinoma). This article presents a case of late MEN 2B diagnosis despite the presence of clinical symptoms suggestive of Multiple Endocrine Neoplasia observed from early childhood. (*Pol J Endocrinol* 2011; 62 (6): 548–553)

Key words: medullary thyroid carcinoma, pheochromocytoma, MEN 2B syndrome

Streszczenie

W pracy przedstawiono przypadek zespołu MEN 2B u 23-letniego pacjenta na podstawie obecności obustronnych guzów chromochłonnych nadnerczy oraz raka rdzeniastego tarczycy. U młodego mężczyzny stwierdzono ponadto wiele przyzwojaki przykręgosłupowe, marfanoidalną budowę ciała oraz liczne włókniaki błon śluzowych jamy ustnej i przewodu pokarmowego. Pacjent był kilkakrotnie hospitalizowany w wieku 11–14 lat z powodu zaburzeń rytmu serca (tachykardii, licznych pobudzeń nadkomorowych) oraz bólów w okolicy przedsercowej. W tym okresie nie obserwowano podwyższonych wartości ciśnienia tętniczego. W 2010 roku chorego hospitalizowano z powodu bólów brzucha, nudności, wymiotów oraz nadciśnienia tętniczego, rozpoznano wówczas obustronne guzy nadnerczy. Chorego skierowano do dalszej diagnostyki z podejrzeniem *pheochromocytoma* do Kliniki Endokrynologii w Szczecinie, gdzie potwierdzono diagnozę obustronnych guzów chromochłonnych oraz dodatkowo rozpoznano raka rdzeniastego tarczycy. Na podstawie całości obrazu klinicznego postawiono rozpoznanie zespołu MEN 2B, potwierdzone w późniejszym okresie badaniem genetycznym. Pacjenta po usunięciu guzów nadnerczy oraz po tyroidektomii przekazano do dalszego leczenia (radioterapii i ponownego leczenia chirurgicznego z powodu wznowy raka rdzeniastego) do Centrum Onkologii w Gliwicach.

Celem pracy było przedstawienie przypadku późnego rozpoznania zespołu MEN typu 2B mimo występowania od wczesnego dzieciństwa objawów klinicznych mogących sugerować to rozpoznanie. (*Endokrynol Pol* 2011; 62 (6): 548–553)

Słowa kluczowe: rak rdzeniasty tarczycy, guz chromochłonny, zespół MEN 2B

Introduction

Type 2B multiple endocrine neoplasia (MEN 2B) is a rare congenital syndrome associated with hyperplasia and neoplasia affecting the thyroid gland, adrenal medulla as well as nervous and connective tissues. MEN 2B is

characterised by the development of medullary thyroid carcinoma (90%), uni- or bilateral pheochromocytoma (45–50%), marfanoid body habitus (65–75%) and other hyperplastic lesions such as neuromas of the tongue and mucous membrane, typically of lips, cheeks, tonsils and eye-lids as well as thickening of the corneal nerve



Elżbieta Andrysiak-Mamos, Department of Endocrinology, Metabolic Diseases and Internal Diseases, Pomeranian Medical University, ul. Unii Lubelskiej 1, 71-252 Szczecin, Poland, Tel: +48 91 425 35 40, fax: +48 91 425 35 42, e-mail: elamamos@tlen.pl

observed during examination with a slit lamp. Skeletal anomalies have also been reported, including kyphoscoliosis, lordosis, feet and femoral bone deformation and dislocation of joints [1, 2].

Medullary thyroid carcinoma originating from parafollicular cells (C-cells) producing calcitonin, associated with MEN 2B is very aggressive and has a poor prognosis [3]. Therefore, in early-diagnosed genetic MEN 2B, preventative removal of the thyroid gland as early as the first year of life is recommended. Cases of medullary thyroid carcinoma of 5 mm have been reported in 17 month-old children [4]. MEN 2B represents less than 10% of MEN 2 syndromes, and is associated with a higher mortality rate than MEN 2A [5].

Catecholamine-producing pheochromocytoma occurs in around 50% of MEN 2B cases, and is the first sign of the disease in around 25% of cases. Medullary carcinoma is the first sign of MEN 2B in 40% of cases. Pheochromocytoma is usually benign, and its bilateral occurrence is reported in 50–80% of cases [6, 7].

Case study

A 23 year-old male patient was referred to the Department of Endocrinology in Szczecin with suspected pheochromocytoma. Having analysed his medical history, we found that the clinical symptoms of MEN 2B had been present since early childhood. The patient was born with an orthopaedic anomaly affecting both feet, which was diagnosed at that time as bilateral inborn peroneal nerve paralysis with talipes equinovarus. Consequently, orthopaedic treatment was started when the patient was 11 months old. The boy began to walk unaided at the age of three. When he was still an infant, he suffered from severe constipation requiring additional treatment. In his second year of life, he presented considerable weight deficit (body weight below the 3rd percentile until the age of 18). At that time he also had diarrhoea. The boy was diagnosed for possible malabsorption syndrome. Between the ages of 11 and 14, he was admitted to hospital several times due to pain in the precordial area, palpitation, dyspnoea and fainting. He was exempt from PE classes in school because of problems with his legs, but every physical exercise was poorly tolerated: the boy had palpitation, shortness of breath and general weakness. Blood pressure, measured many times on such occasions, yielded normal results.

In 2006, the patient suffered from subcapsular rupture of the spleen as a result of an injury. Ultrasound examination of the abdomen performed at that time was difficult due to large amounts of fluid in the peritoneal cavity and consequently only showed spleen enlargement and intestinal foci of unclear aetiology. The rup-

tured spleen was removed during laparotomy, together with two tumours with diameters of 25 mm and 30 mm. Histopathologic examination of these tumours revealed the presence of fibrous tissue. The diagnostic process was discontinued at this stage. Postoperatively, the patient suffered from retrosternal pain and tachycardia up to 110 bpm. Apart from tachycardia, ECG findings included ST segment elevation in precordial leads V2 to V4, which resolved spontaneously several hours later. Blood pressure values during surgery, as well as in the perioperative period, were normal.

In January 2010, the patient was admitted to the regional hospital unit of internal medicine due to chest pain which has been increasing for ten days before admission, severe headache, dizziness, nausea, vomiting and blood pressure up to 220/130 mm Hg. CT of the abdomen performed during hospitalisation showed bilateral tumours in the projection of adrenal glands, with a tumour diameter of 65 mm. There were also other smaller tumours of a diameter not exceeding 20 mm located at various levels on both sides of the spine close to intervertebral foramina, and most likely originating from the ganglia. The patient was referred to Pomeranian Medical University's Department of Endocrinology in Szczecin for continuation of the diagnostic process and treatment.

Anomalies observed on the day of admission to hospital included marfanoid body habitus (leptosomic body type, height 176 cm, weight 50 kg, BMI 16.1 kg/m², high-arched palate, loose joints and elastopathy, long, thin arms and legs (armspan of 177 cm), flat abducted feet, multiple neuromas of mucous membrane and tongue, slight asymmetric enlargement of left thyroid lobe, silent systolic apex murmur, blood pressure 140/90 mm Hg despite antihypertensive treatment (metoprolol 50 mg, doxazosin 4 mg, amlodipine 10 mg) (Figure 1). Laboratory findings included thrombocytopenia, hyperuricaemia (9.22 mg/dl) and hyperglycaemia both in fasting condition and in half-daily profile (up to 185 mg/dl). OGTT after two hours yielded normal blood glucose results. High levels of metanephrines and vanillyl mandelic acid (VAM) were observed in 24-hour urine output and elevated serum levels of chromogranin A, calcitonin, carcinoembryonic antigen (CEA) and slightly elevated levels of cortisol and ACTH were detected (Table I). Ultrasound examination of the thyroid gland revealed a hypoechogenic focal lesion with microcalcifications. The lesion measured 9.7 × 8.5 × 19 mm in the right lobe and a similar lesion measuring 15.7 × 11 × 35 mm was located in the left lobe (Figure 2). Additionally, ultrasound examination revealed enlargement and blurred structure of lymph nodes located bilaterally along the sternocleidomastoid muscles (Figure 3). I-131 MIBG scintigraphy showed two

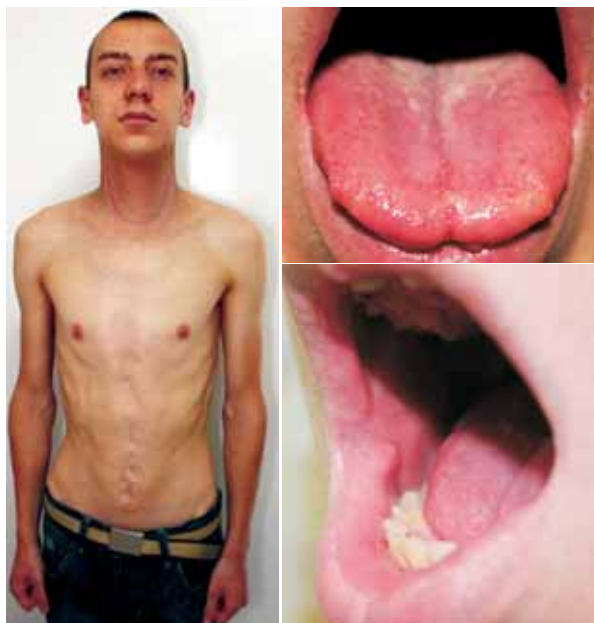

Figure 1. Marfanoid body habitus and neuromas of cheeks and tongue in a patient with MEN 2B

Rycina 1. Cechy marfanoidalne budowy ciała oraz nerwiakowłókniaki błon śluzowych policzków i języka u pacjenta z zespołem MEN 2B

Table I. Hormone levels and tumour markers in a patient with MEN 2B before treatment and after the removal of pheochromocytoma and complete removal of the thyroid gland

Tabela I. Stężenia hormonów oraz markerów nowotworowych przed leczeniem oraz po usunięciu guzów nadnerczy i po usunięciu tarczycy u pacjenta z zespołem MEN 2B

Hormones and tumour markers	Before treatment	Pheochromocytoma resection (one month after)	Thyroid resection (six months after)	Normal range Unit
Chromogranin A	2,034.0	370.0	425	20–150 ng/ml
Metanephrines	986.0	42.0	94.5	25–312 μ g/24 h
VAM	38.0	1.6	2.1	< 8 mg/24 h
Calcitonin	3,768.0	2,230.0	5,051.0	0–10 pg/ml
CEA	25.7	17.5	34.8	< 5 ng/ml
Cortisol	28.6	1.4	3.4	5–25 μ g/dl
ACTH	56.6	124.0	283.0	5–46 pg/ml

VAM — vanillyl mandelic acid; CEA — carcinoembryonic antigen

large foci of pathologic MIBG concentration located in left and right epigastrium (Figure 4). Octreoscan scintigraphy was also performed, detecting two foci with enhanced somatostatin receptor expression above the left kidney and in front of the right kidney. This location corresponded to the findings of the I-131-MIBG scintigraphy (Figure 5). After preoperative treatment with alpha- and beta-blockers, and while still awaiting the result of histopathologic examination of thyroid lesions, the patient was qualified for surgical removal of bilateral lesions in adrenal glands.

The surgery was performed at the Department of General and Transplantation Surgery, Westpomeranian Provincial Hospital in Szczecin and both lesions were removed. During surgery, there were considerable fluctuations in the patient's blood pressure, ranging from 50 to 260 mm Hg. After surgery, normal levels of metanephrines were observed, while chromogranin A levels decreased, although they were still beyond normal values (Table I). Histopathologic findings confirmed the presence of tissues corresponding to pheochromocytoma in both tumours, without cytologic signs of

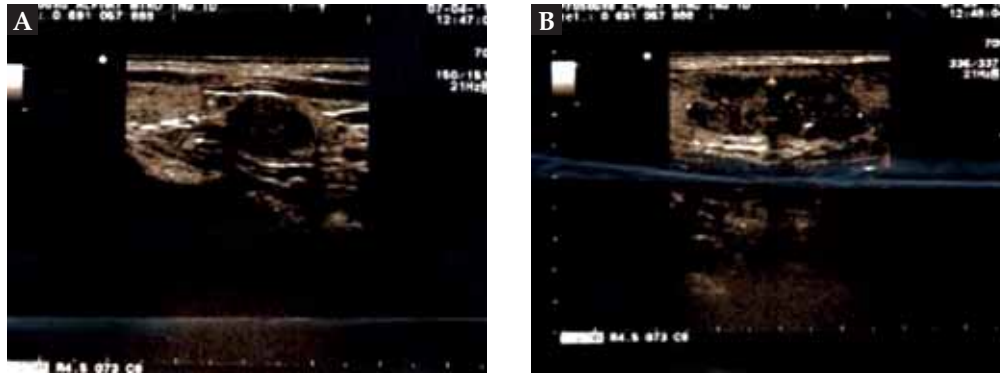


Figure 2. Foci of medullary thyroid carcinoma in the right (A) and left (B) thyroid lobe in a patient with MEN 2B
Rycina 2. Ogniska raka rdzeniastego tarczycy w prawym (A) i lewym (B) płacie tarczycy u pacjenta z zespołem MEN 2B

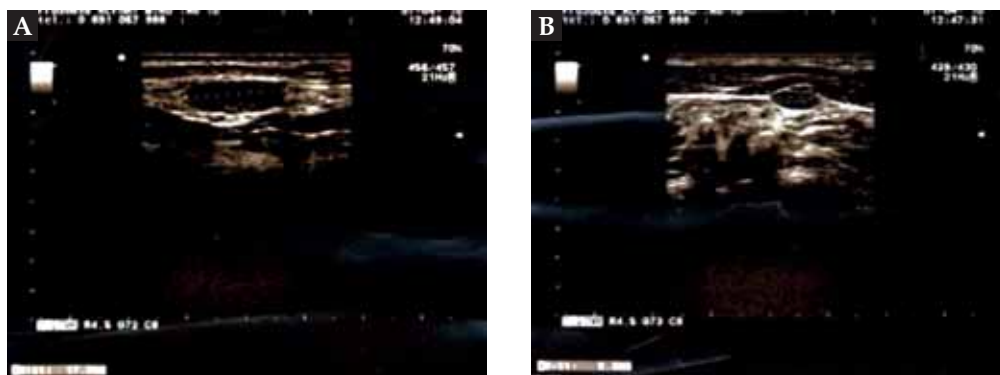


Figure 3. Enlarged lymph nodes with altered echostructure on the right (A) and left (B) in a patient with MEN 2B
Rycina 3. Powiększone, o zmienionej echo strukturze węzły chłonne po stronie prawej (A) i lewej (B) u pacjenta z zespołem MEN 2B

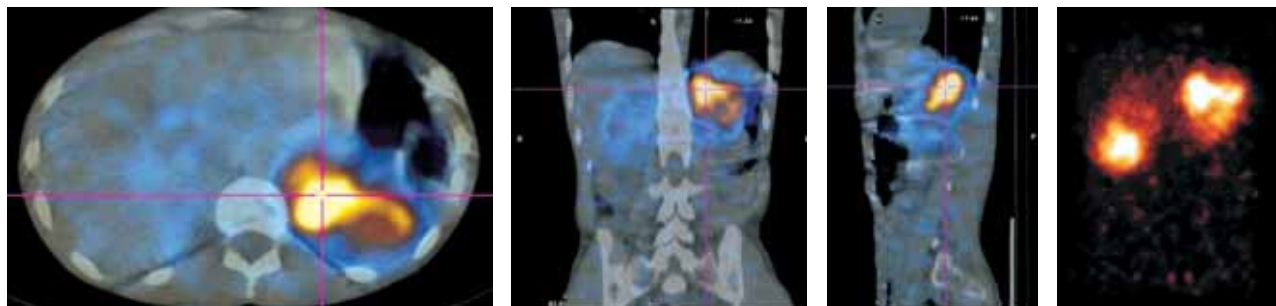


Figure 4. Foci with pathologic MIBG concentration in left and right epigastrium corresponding to adrenal tumours in a patient with MEN 2B
Rycina 4. Ogniska patologicznego gromadzenia MIBG w nadbrzuszu lewym oraz nadbrzuszu prawym, odpowiadające guzom nadnerczy u pacjenta z zespołem MEN 2B

malignancy. Infiltration of either the capsule or blood vessels was not found. The mitotic index was 1/50 hpf, MIB-1 positive in 2% of cells.

Two months after the removal of *pheochromocytomas*, in May 2010, the patient was referred to the Department

of Plastic and Endocrine Surgery for complete resection of thyroid together with left and right cervical, paralaryngeal and upper mediastinal lymph nodes. Calcitonin levels fell from 3768 at the first diagnosis to 2230 pg/ml after removal of *pheochromocytoma*. In July

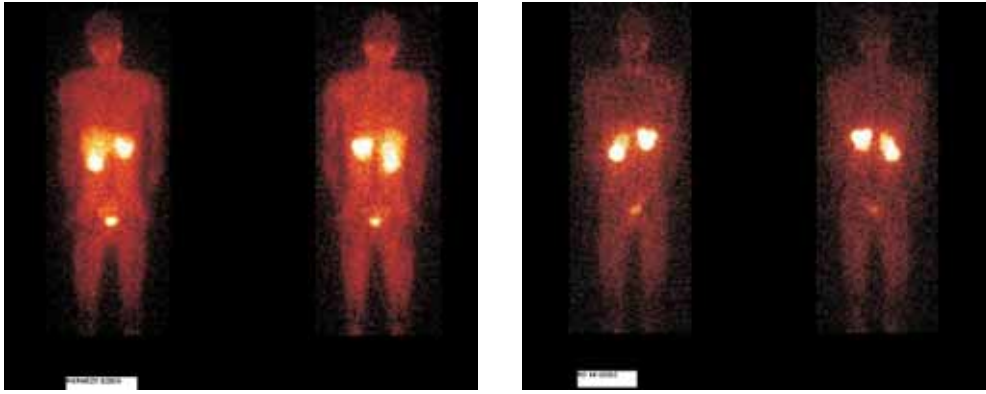


Figure 5. Foci with increased expression of somatostatin receptors above the left kidney and in front of the right kidney in octreoscan scintigraphy in a patient with MEN 2B

Rycina 5. Ogniska o wzmożonej ekspresji receptorów somatostatynowych nad nerką lewą oraz do przodu od nerki prawej w scyntygrafii receptorowej — octreoscan u pacjenta z zespołem MEN 2B

2010, after thyroidectomy calcitonin levels raised to 5051 pg/ml which was the evidence for the persistence of medullary cancer. The ^{68}Ga -DOTATATE PET/CT was performed which did not find evident foci that might correspond to neoplastic process with somatostatin receptor expression, the patient was qualified for reoperation — bilateral cervical lymphadenectomy (October 2010). After thyroid surgery, replacement therapy with L-thyroxin as well calcium and vitamin D3 treatment were started due to hypoparathyroidism. Medullary cancer metastases were found in one out of 18 lymph nodes on the left and in 12 out of 16 lymph nodes on the right; there was also infiltration of fat tissue around the lymph nodes. Between October 2010 and April 2011, calcitonin levels ranged from 4,550 pg/ml to 5,545 pg/ml and in the absence of alternative treatment, the patient was subject to radiotherapy. In March and April 2011, the patient reported to the Cancer Centre and Institute of Oncology in Gliwice where he received adjuvant radiotherapy of lymph nodes of the neck and upper mediastinum at a fractional dose of 2.0 Gy up to a total dose of 60.0 Gy. At present, the patient's condition is stable. He remains on replacement therapy with euthyrox, hydrocortisone, cortinef, calperos as well as alfadiol and biosterone.

Discussion

MEN 2 was first described in 1961 [5]. Since then, detailed descriptions of clinical syndromes associated with MEN 2 have followed; they are summarised in Table II [8]. MEN 2B is much less common than MEN 2A, and although its clinical signs have been described on many occasions and are highly characteristic, its diagnosis is still too late, except for cases of familial

MEN 2B occurrence. Our patient has had clinical symptoms of MEN 2B since the day he was born: i.e. congenital defects of the feet and marfanoid body habitus. Diarrhoea, which started as early as the second year of life and continues today, was probably associated with calcitonin secretion, first by the foci of C cell hyperplasia, and then by medullary cancer. It has been reported that children with familial medullary thyroid carcinoma, MEN 2 and RET protooncogene mutation demonstrate hyperplasia of thyroid C cells and metastases by the age of five [9]. Unilateral foci

Table II. Clinical syndromes associated with MEN 2

Tabela II. Zespoły kliniczne związane z zespołem MEN 2

Syndrome manifestation	Percentage (%)
Multiple endocrine neoplasia type 2A (MEN 2A)	
Medullary thyroid carcinoma	100
Pheochromocytoma	50
Hyperparathyroidism	10–20
MEN 2A variants	
Familial medullary thyroid carcinoma (FMTC)	
MEN 2A with cutaneous lichen amyloidosis (MEN 2A/CLA)	
MEN 2A with Hirschsprung disease	
Multiple endocrine neoplasia type 2B (MEN 2B)	
Medullary thyroid carcinoma	100
Pheochromocytoma	50
Parathyroid disease	0
Marfanoid attributes	> 90
Intestinal ganglioneuromatosis and mucosal neuromas	> 90

of medullary thyroid carcinoma with the diameter of 2 mm have been described in a 17 month-old patient [4] and children from families with MEN 2B have had medullary thyroid cancer metastases in their third year of life [10]. Skinder et al. and Gill et al. have also described microfoci of medullary carcinoma in children occurring as early as the first year of life [5, 11]. Jasin et al. were the first to describe a family with MEN 2B [12]. The mother had medullary thyroid carcinoma, bilateral pheochromocytoma and such phenotypic features as mucosal neuromas and marfanoid body type. The oldest of her three children, a five year-old son, had mucosal neuromas of the oral cavity and tongue as well as thyroid nodules and cervical lymphadenopathy. Calcitonin levels were at the limit of normal — 7.6 pg/mL, with age-adjusted normal range being < 8.4 pg/mL. Other biochemical markers i.e. chromogranin A, CEA, metanephrines, PTH and calcium, remained within normal ranges. His younger siblings, three year-old female twins, did not present phenotypic features of MEN 2B, no lesions were found in ultrasound examination of the thyroid, and enlargement of the lymph nodes was not observed. Calcitonin levels were 7.7 and 11.6 pg/mL, with the normal range being < 15 pg/mL.

One year later, calcitonin levels in the boy were normal while they had increased to 9.4 and 13.9 pg/mL respectively in the twins, but still no lesions were observed in ultrasound examination of the thyroid. Prophylactic removal of the thyroid in the siblings is being considered. This family had RET protooncogene mutation in exon 15, RET A883F. MEN 2B is associated with mutation at codons 883, 918 and 922, which represent 3–5% of mutations within the RET protooncogene [8]. It is believed that medullary carcinoma in patients with the RET protooncogene mutation at codon 918 is more aggressive, which is also reflected in the clinical picture of MEN 2B in our patient — genetic tests showed *de novo* M918T mutation in exon 16, which was not found in other family members [13]. Very similar cases have been described by Camacho et al. [14]. Their patients (two males and two females) demonstrated phenotypic features of MEN 2B such as neuromas of mucosa and tongue, osteoarticular disorders and corneal nerve thickening. Additionally, two patients showed marfanoid body habitus. Among these patients, the case of a 23 year-old man is similar to the one presented by our team. The only difference is that pheochromocytoma in the other adrenal gland developed two years after the diagnosis had been established. Both our patient

and the four patients mentioned above suffered from constipation during infancy. This is related to intestinal ganglioneuromatosis. There are reports of severe constipation in MEN 2B patients as early as the first year of life [15–17].

Full-blown MEN 2B with mucosal neuromas, pheochromocytoma and medullary thyroid carcinoma occurs in only 50% of cases and when the diagnosis is based on these symptoms it is too late to introduce preventative measures. It seems advisable that all patients with mucosal neuromas and intestinal ganglioneuromatosis should undergo screening for MEN 2B. Only then would it be possible to start MEN 2B prophylaxis, even if it is not familial occurrence of the disease.

In summary, despite characteristic clinical features, the diagnosis of MEN 2B comes too late, which greatly worsens the prognosis in these patients.

References

1. Brandi ML, Gagel RF, Angeli A et al. Guidelines for diagnosis and therapy of MEN type 1 and type 2. *J Clin Endocrinol Metab* 2001; 86: 5658–5671.
2. Schuman H, Laufer L, Barki Y et al. Ganglioneuroma an „incidentaloma” of childhood. *Eur Radiol* 1998; 8: 582–584.
3. Utiger RD. Medullary thyroid carcinoma, genes, and the prevention of cancer. *N Engl J Med* 1994; 331: 870–871.
4. Sanso GE, Domene HM, Garcia R et al. Very early detection of RET proto-oncogene mutation in crucial for preventive thyroidectomy in multiple endocrine neoplasia type 2 children: presence of C-cell malignant disease in asymptomatic carriers. *Cancer* 2005; 94: 323–330.
5. Skinner MA, DeBenedetti MK, Moley JF et al. Medullary thyroid carcinoma in children with multiple endocrine neoplasia types 2A and 2B. *J Pediatr Surg* 1996; 31: 177–181.
6. Marini F, Falchetti A, Del Monte F et al. Multiple endocrine neoplasia type 2. *Orphanet Journal of Rare Diseases* 2006; 1: 1172–1186.
7. Sippl J.H. The association of pheochromocytoma with carcinoma of the thyroid gland. *Am J Med* 1961; 31: 163–166.
8. Jimenez C, Gagel RF. Genetic testing in endocrinology: lessons learned from experience with multiple endocrine neoplasia type 2 (MEN2). *Growth Hormone & IGF Research* 2004; 14: 150–157.
9. Machens A, Niccoli-Sire P, Hoegel J et al. Early malignant progression of hereditary medullary thyroid cancer. *N Engl J Med* 2003; 349: 1517–1525.
10. Kaufman FR, Roe TF, Isaacs Jr H. Metastatic medullary thyroid carcinoma in young children with mucosal neuroma syndrome. *Pediatrics* 1982; 70: 263–267.
11. Gill JR, Reyes-Mugica M, Iyengar S et al. Early presentation of metastatic medullary carcinoma in multiple endocrine neoplasia type IIA: implication for therapy. *J Pediatr* 1996; 129: 459–464.
12. Jasin S, Ying AK, Waguespack SG et al. Multiple endocrine neoplasia type 2B with a RET proto-oncogene A883F mutation displays a more indolent form of medullary thyroid carcinoma compared with a RET M918T mutation. *Thyroid* 2011; 21: 189–192.
13. Lora MS, Waguespack SG, Moley JF, Walvoord EC. Adrenal ganglioneuroma in children with multiple endocrine neoplasia type 2: a report of two cases. *J Clin Endocrinol Metab* 2005; 90: 4383–4387.
14. Camacho CP, Hoff AO, Lindsey SC et al. Early diagnosis of multiple endocrine neoplasia type 2B: a challenge for physicians. *Arq Bras Endocrinol Metab* 2008; 52: 1254–1262.
15. Unruh A, Fitze G, Janig U et al. Medullary thyroid carcinoma in a 2-month-old male with multiple endocrine neoplasia 2B and symptoms of pseudo-Hirschsprung disease: a case report. *J Pediatr Surg* 2007; 42: 1623–1626.
16. Chang A, Chan WF, Lo CY, Lam KS. Multiple endocrine neoplasia 2B in a Chinese patient. *Hong Kong Med J* 2004; 10: 206–209.
17. Byard RW, Thorner PS, Chan HS et al. Pathological features of multiple endocrine neoplasia type IIb in childhood. *Pediatr Pathol* 1990; 10: 581–592.