



Comparison and assessment of thyroid morphology and function in inhabitants of Lower Silesia before and after administration of a single dose of iodine-containing contrast agent during cardiac intervention procedure

Ocena morfologii i funkcji tarczycy u mieszkańców regionu Dolnego Śląska przed i po jednorazowym obciążeniu pojedynczą, niefizjologiczną dawką jodu podczas kardiologicznych procedur interwencyjnych

Katarzyna Skórkowska-Telichowska¹, Joanna Kosińska¹, Rafał Szymczak¹, Dominika Tuchendler¹, Renata Tuchendler¹, Artur Telichowski², Grzegorz Szajn², Marek Bolanowski³

¹Endocrinology Department, Clinic of Internal Medicine, ^{4th} Military Hospital, Wrocław, Poland

²Cardiology Department, ^{4th} Military Hospital, Wrocław, Poland

³Chair and Department of Endocrinology, Diabetology and Isotope Therapy, Wrocław Medical University, Poland

Abstract

Introduction: Inhabitants living in areas with endemic dietary iodine intake deficiency develop nodular goitre. The aim of our study was to evaluate thyroid morphology and function among adults residing in Lower Silesia and to assess the effect on the thyroid gland of an iodine-based contrasting agent administered during a cardiac intervention procedure.

Materials and methods: The first part of the study (evaluation of thyroid gland) was carried out on 120 subjects (78 men and 42 women). From among this group, invasive cardiac procedures were performed on 60 subjects (38 men and 22 women) during the second part of the study. Endocrine tests were repeated one, three, and six months after the invasive procedure.

Results: 1) Within the studied group, pathological changes in thyroid morphology were found in 49.1%, and thyroid function disturbances in 9.3%, of all subjects. 2) A decrease in TSH concentration with a corresponding increase in fT3 concentration was seen at the second visit (four weeks after iodine administration) leading to the diagnosis of hyperthyroidism in 15% of subjects.

Conclusions: 1) Considering the multitude of silent thyroid pathologies, particular care is required before administering an iodine-based medium. 2) It is reasonable and advisable to monitor TSH and fT3 levels before and at four weeks after administration of an iodine-containing contrast agent. 3) Thyroid morphology and function disturbances after iodine administration do not necessitate treatment, as they are of transient character and only require monitoring. (*Endokrynol Pol* 2012; 63 (4): 294–299)

Key words: thyroid gland, nodular goitre, iodine intake deficiency, invasive cardiac procedures

Streszczenie

Wstęp: Wiadomym jest, że mieszkańcy terenów ubogich w jod rozwijają szereg niemych klinicznie patologii tarczycy. Celem badania była ocena morfologii i funkcji tarczycy w populacji dorosłych mieszkańców Dolnego Śląska oraz ocena wpływu na gruczoł tarczycowy jednorazowo podanej dawki jodu w postaci kontrastu w trakcie kardiologicznych procedur interwencyjnych.

Materiały i metody: Do pierwszej części badania, której celem była ocena morfologii i funkcji tarczycy u zdrowych mieszkańców Dolnego Śląska zakwalifikowano 120 osób (78 mężczyzn i 42 kobiety). Z tej grupy wyłoniono 60 osób (38 mężczyzn i 22 kobiety) które, z racji wskazań do inwazyjnych zabiegów kardiologicznych (koronarografii/PTCA), obciążono dużą dawką jodu oraz przeprowadzano u nich ocenę tyreologiczną po 1, 3 i 6 miesiącach od interwencji.

Wyniki: 1) Patologiczne zmiany w morfologii tarczycy stwierdzono u 49,1%, zaburzenia dotyczące stężeń hormonów tarczycy i przeciwciał przeciw tarczycowym stwierdzono u 17,6%, które przekładały się na zaburzenia funkcji tarczycy u 9,3% zdrowych tyreologicznie mieszkańców Dolnego Śląska. 2) Największe zmiany: obniżenie stężenia TSH i wzrost stężenia fT3 były widoczne 4 tygodnie po obciążeniu jodem, prowadząc do rozpoznania nadczynności tarczycy u 15% pacjentów.

Wnioski: 1) Z uwagi na dużą ilość klinicznie niemych zaburzeń morfologii i funkcji tarczycy ważna jest jej dokładna ocena przed obciążeniem chorego jodem. 2) Jest poparte dowodami i polecane monitorowanie stężenia TSH i fT3 przed i 4 tygodnie po obciążeniu chorego jodem. 3) Zaburzenia morfologii i funkcji tarczycy po podaniu pacjentowi jodu mają charakter przemijający, wymagają monitorowania, ale nie leczenia. (*Endokrynol Pol* 2012; 63 (4): 294–299)

Słowa kluczowe: tarczyca, wole guzowate, niedobór jodu, kardiologiczne procedury interwencyjne



Katarzyna Skórkowska-Telichowska MD, PhD, Endocrinology Department, Clinic of Internal Medicine, ^{4th} Military Hospital, ul. Rudolfa Weigla 5, 50-981 Wrocław, Poland, e-mail: cathcor@poczta.onet.pl

Introduction

Nodular goitre presents as a spectrum of pathology in thyroid morphology and function that is strongly associated with iodine deficiency, to date the best examined epidemiological risk factor involved in its pathogenesis. It has been observed that the prevalence of nodular goitre in a given population is strongly influenced by dietary iodine uptake. Iodine is a proven thyroid function regulator, influencing thyroid size, thyroid hormone levels, and thyroglobulin blood concentration, and is thus engaged in the organism's metabolism [1–5]. According to ultrasonographic thyroid gland screening population studies, the prevalence of nodular goitre in the adult population ranges between 30% and 40% among women, and 20% and 30% among men, residing in regions deficient in iodine [6].

It is well known that inhabitants living in regions characterised by insufficient dietary iodine intake tend to develop nodular goitre, and that this is not observed in subjects with sufficient iodine supplementation, including among residents of Poland where efficient (according to literature) obligatory prophylactic iodine supplementation programmes have been instituted since 1997 [7, 8].

Lastly, the number of invasive cardiac interventions performed has been steadily rising in Lower Silesia. Intravenous contrast agents routinely used as a standard part of coronary angioplasty are iodine-based. Such a single dose of iodine administered far exceeds the recommended daily allowance for adults, which may interfere with normal thyroid gland function. Under normal conditions, the adult person's iodine requirement is estimated to be 0.15–0.20 mg per 24 hours [7, 9, 10].

In the literature, there is a glaring lack of current epidemiological data on the presence of thyroid goitre among adult inhabitants of Lower Silesia as well as a lack of data on the effects on thyroid morphology and

function after the administration of such a high single dose of iodine as part of an interventional procedure. Lower Silesia was recently recognized as an endemic region of nodular goitre.

Aim of our study

To evaluate the effects on the thyroid gland morphology and function produced by administration of a single dose of iodine-based contrast agent during a cardiac intervention procedure in adults in Lower Silesia compared to the baseline morphology and function of the thyroid gland as assessed prior to the intervention.

Materials and methods

The first part of the study was carried out on 120 subjects (78 men and 42 women) aged 59.7 ± 7.8 years visiting an Outpatient Cardiology Clinic in the 4th Military Hospital in Wrocław over a period of six months (2009/2010). The demographic and clinical characteristics of the study group are set out in Tables I and II. None of the subjects included in the study had a previous history of thyroid disorders, and all had normal thyroid function parameters at the beginning of the study.

Prior to cardiac procedures using iodine-based contrast agents, the following tests were performed:

- thyroid hormone profile (TSH, fT3, fT4, TT3, TT4);
- anti-thyroid antibodies (TPO, ATG, TSHR antibodies);
- thyroid ultrasound;
- iodine uptake capacity using scintigraphy of thyroid gland;
- physical examination;
- urine iodine excretion.

From the group of 120 subjects previously qualified, 60 subjects (38 men and 22 women) were selected to the second part of the study. One man was excluded because of a new diagnosis of thyrotoxicosis in the course of Graves' disease. In the group of 59 subjects aged 58.7 ± 8.8 years, invasive cardiac procedures i.e.

Table I. Demographic data of the study group

Table I. Dane demograficzne badanej grupy

Parameter	Entire group	Male	Female
Number of subjects	120	78	42
Mean age [years]	59.7 ± 7.8	$58.0 (\pm 8.4)$	$62.4 (\pm 6.0)$
Mean height [m]	$1.7 (\pm 0.1)$	$1.7 (\pm 0.1)$	$1.6 (\pm 0.1)$
Mean weight [kg]	$82.2 (\pm 18.4)$	$89.9 (\pm 18.3)$	$69.1 (\pm 9.5)$
Mean BMI [kg/m ²]	$28.5 (\pm 4.9)$	$29.3 (\pm 5.0)$	$27.2 (\pm 4.6)$
Mean thyroid iodine uptake [%]	$24.3 (\pm 8.1)$	$23.4 (\pm 8.7)$	$25.9 (\pm 7.1)$
Mean thyroid volume [mL]	$15.6 (\pm 8.4)$	$18.4 (\pm 9.0)$	$10.8 (\pm 4.3)$

Table II. Clinical data of the studied group**Tabela II. Dane kliniczne badanej grupy**

Parameter			Number of subjects	Number of male	Number of female
Subjects included in the study			120	78	42
Subjects with thyroid pathology			59 (49.1%)	45 (37.5%)	14 (11.6%)
Changes in thyroid morphology	Physical examination	First stage goitre (palpable but not visible)	22 (18.3%)	16 (13.3%)	6 (5%)
		Second stage goitre (visible at normal anatomical position of neck)	6 (5%)	4 (3.3%)	2 (1.7%)
	Ultrasound examination	Heterogeneous echogenicity of the thyroid gland	47 (39.1%)	29 (24.2%)	18 (15%)
		Heterogeneous echostructure of thyroid gland	69 (57.5%)	46 (38.3%)	23 (19.2%)
		Nodules of the thyroid gland (all)	44 (37%)	30 (25%)	14 (12%)
		Numerous nodules (diameter < 1 cm and > 1 cm)	28 (23.5%)	20 (16.7%)	8 (6.6%)
		Single nodule (diameter > 1 cm)	4 (3.3%)	2 (1.65%)	2 (1.65%)
		Single nodule (diameter < 1 cm)	12 (10.2%)	8 (6.7%)	4 (3.3%)
Changes in antibodies (increase)	Anti-TSHR antibodies		1 (0.8%)	1 (0.8%)	–
	Anti-TPO antibodies		4 (3.3%)	2 (1.6%)	2 (1.6%)
	Anti-ATG antibodies		8 (6.6%)	2 (1.6%)	6 (5%)
Changes in hormones	↑ fT3 or fT4 and ⇌ TSH		10 (8.3%)	5 (4.2%)	5 (4.2%)
	↑ TT3		10 (8.3%)	–	10 (8.3%)
	↑ TT4		8 (6.6%)	4 (3.3%)	4 (3.3%)
	↑ TT3 and TT4		8 (6.6%)	8 (6.6%)	–

coronarography (41 subjects) and coronarography with PTCA (18 subjects), were performed. The single dose of iodine administered during the procedure ranged between 37 grams and 222 grams (Table III). Endocrine thyroid tests were repeated at one, three, and six months following the invasive procedure.

The study was approved by the local bioethics committee. All subjects enrolled in the study were provided with written information on the purpose and design of the study.

Statistical analysis

Statistical analysis was performed using the Statistica program 6.0. Differences between variables were assessed using the Student t-test. Pearson correlation and Spearman rank correlation were used in order to find relationships between variables. Comparison of two patient groups was made using the Tukey test and t-student test. All results were found to be statistically significant at $p < 0.05$.

Results

Changes in thyroid echogenicity, echostructure and changes in thyroid volume are depicted in Figure 1. At the end of our assessment, 34 patients (57.6%) had heterogeneous thyroid echostructure; newly formed nodules had a diameter of less than 1 cm, while the nodules which were initially present at the beginning of the study were found to have increased in size by more than 1 cm.

The volume of thyroid increased by about 1.5 ml after iodine administration, with maximum volume noted at the second visit, then, beginning at the third visit, the thyroid volume gradually decreased, but in none of the cases did it return to the original size noted at the first visit. Thyroid volume correlated positively with the size and number of thyroid nodules and negatively with TSH concentration — mostly between visits 1 and 2. Greater volume of the thyroid gland was associated with an increased neck discomfort.

Table III. Information about administered doses of iodine

Tabela III. Informacje o podawanych dawkach jodu

Parameter	Entire group	Male	Female
Number of subjects	59	37	22
Number of patients undergoing coronarography without PTCA	41	25	16
Number patients undergoing coronarography and PTCA	18	12	6
Mean dose of iodine administered during cardiac procedure [g]	60.75 (\pm 43.72)	63.62 (\pm 38.12)	55.92 (\pm 53.28)

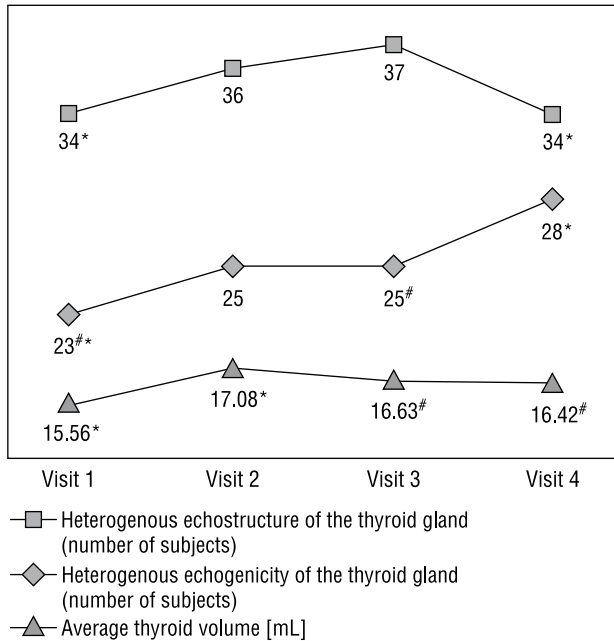


Figure 1. Changes in echostructure, echogenicity and volume of the thyroid gland at visits scheduled at one, three and six months after intervention with iodine administration; **statistically significant changes of illustrated parameters

Rycina 1. Zmiany w echostrukturze, echogeniczności i objętości gruczołu tarczowego wyjściowo oraz po 1, 3 i 6 miesiącach od podania jodu; **statystycznie istotne zmiany ilustrowanych parametrów

The changes in thyroid function observed are illustrated in Figure 2 below.

A decrease in TSH concentration with a corresponding increase in fT3 concentration was seen at the second visit (four weeks after iodine administration) leading to the diagnosis of hyperthyroidism in nine subjects (15%). Subclinical hyperthyroidism was diagnosed in three subjects. In six patients, clinically evident hyperthyroidism with symptoms of hypermetabolic state, mainly presenting as an arrhythmia during nights, was observed.

During the third visit, fT3 and fT4 concentrations returned to their normal range, although the level of TSH took longer to normalise than the other two parameters;

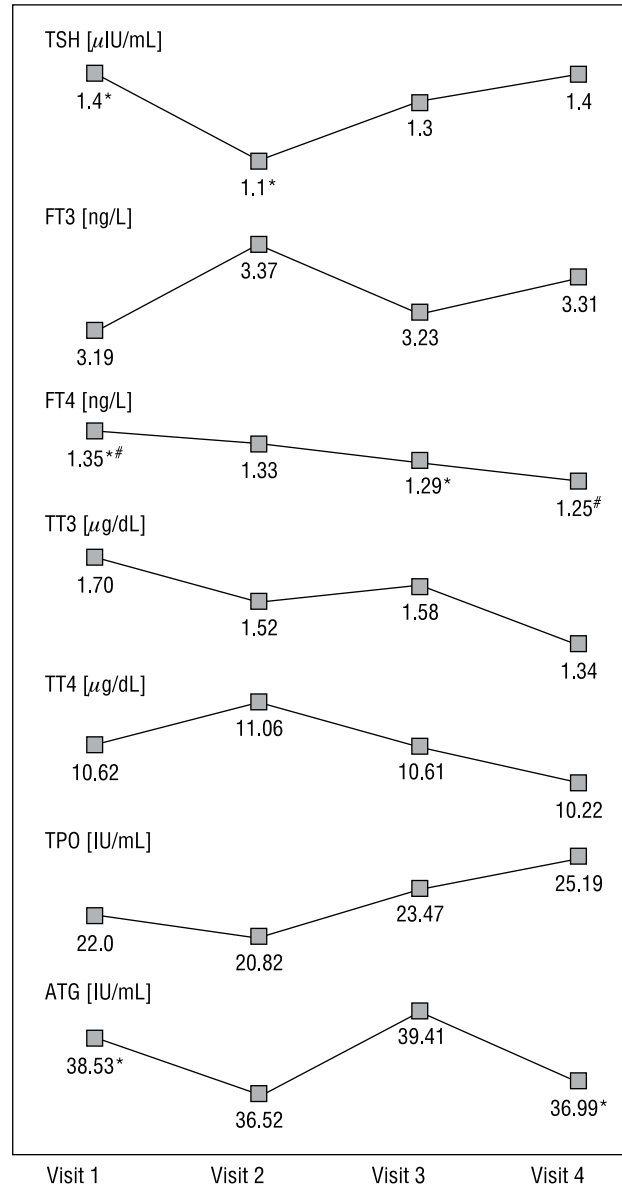


Figure 2. Changes expressed in thyroid hormone concentrations and anti-thyroid antibodies at visits scheduled at one, three and six months after intervention with iodine administration; **statistically significant changes of illustrated parameters

Rycina 2. Zmiany dotyczące stężenia hormonów tarczycy oraz przeciwciał przeciw tarczycowym wyjściowo oraz po 1, 3 i 6 miesiącach od podania jodu; **statystycznie istotne zmiany ilustrowanych parametrów

of these, one was a case of subclinical hyperthyroidism, one of hyperthyroidism, and one subject had subclinical hypothyroidism.

After six months, during the last (fourth) visit, we observed low TSH levels (subclinical hyperthyroidism) in two cases and in one we observed elevated TSH (subclinical hypothyroidism). In the remainder of the patients, thyroid function returned to the baseline status seen before iodine administration.

A comparison of the two patient groups produced the following observations regarding morphology of thyroid, iodine doses, iodine uptake and patient gender.

In the group with changes noted at the beginning of the study, statistically important differences in fT4 concentration were seen. In the group with initially normal thyroid morphology, fT3 changes were mostly observed. In the group that received more than 40 grams of iodine, only changes in TSH and anti-TPO antibody concentrations were seen, whereas in the group that received less than 40 grams of iodine, statistically significant changes in TSH, fT3, fT4 and anti-ATG antibody concentrations were noted.

All morphological and functional thyroid changes described in the study occurred in those subjects in whom the rate of thyroid iodine uptake was more than 20%. In those cases where uptake was less than 20%, there were no changes seen in the thyroid status.

Statistically important changes in the TSH concentration persisted longer in men compared to women, but there were no other noteworthy differences between the genders.

Discussion

In the period between 1981 and 2006, a significant number of articles addressed the effects of iodine administration during interventional cardiac procedures on the thyroid gland. Differences between these studies mostly concerned the various methods of assessment of thyroid morphology and parameters of thyroid function, the quantity of administered iodine, the period of time following the procedure during which the thyroid was periodically assessed, as well as the demographics of the observed populations [11–15].

The work of Fassbender et al. did not reveal any clinical or laboratory features of hyperthyroidism as evidenced by TSH, TT3, TT4, fT4 concentrations even though the population under study came from an iodine-deficient region with endemic nodular goitre. Additionally, the value of the Fassbender study was limited by the small sample groups of patients examined. The main difference was with respect to the much shorter follow-up patient time after the cardiac intervention procedure (only three weeks), while in our

work we focused on an expanded panel of laboratory parameters in which we noted the greatest changes in TSH and fT3 concentrations at four weeks after iodine administration.

In the Gartner et al. study, thyroid was assessed on a daily basis during the first seven days following iodine administration in all subjects qualified; while hyperthyroidism was observed in none of the cases, transient subclinical hypothyroidism was seen. The main distinctions between this study and our own mainly concerned differences in the populations under investigation (inhabitants of regions with sufficient iodine supplementation, small group of examined subjects: 16 persons vs. 120 persons from an iodine-deficient region) as well as a difference in the employed methodology.

In the two Russian works (Dedov et al., Egorov et al.), changes in the levels of thyroid hormones measured after iodine administration were noted. However, there was no investigation accompanying changes in thyroid morphology, which distinguished this study from our own, where we focused on both thyroid function and morphology [13, 14]. Hyperthyroidism was observed in half as many subjects, similarly as in our study, and interestingly in their study hypothyroidism was more frequently noted than in our own; the possible explanation for this difference could be the more heterogeneous group of patients included in the Russian study. As in our work, clinical manifestations of thyroid dysfunction were present. Significant changes in thyroid hormone levels in both of their articles were also observed at four weeks following iodine administration.

These common findings lead to a conclusion that iodine administration results in changes in thyroid function, and the range of these changes depends more on the baseline thyroid status at the time before administration (with regard to morphology and function) than on the doses of iodine administered.

Nolte et al. [15] went a step further, by administering a short course of antithyroid drugs before and after coronarography to patients with abnormal thyroid gland morphology, as a preventive measure against hyperthyroidism in the group of treated patients, while those in the control group with normal native thyroid gland did not receive such prophylactic treatment. In the Nolte et al. study there were no newly recognized cases of hyperthyroidism within the treated group. Administration of prophylactic thyreostatics in those with thyroid dysfunction is an interesting approach that warrants further investigation.

In the article by Hintze et al., hyperthyroidism was noted only in a fraction of the population studied (0.25%) despite the similarities among the studied groups of subjects (chosen non-selectively and from an endemic region). This finding contrasted with our

own, where hyperthyroidism was observed in as many as 15% of subjects; thus, conclusions drawn from this work completely differ with those that stem from our work, as well as those from all articles cited above.

One unique feature in this study is that previously, no extended assessment of thyroid status had been performed on the adult population of Lower Silesia.

Conclusions

The prevalence of unrecognised silent thyroid pathologies in patients from endemic areas warrants the exercise of particular judiciousness when making the decision to administer iodine during a diagnostic/therapeutic procedure.

In those cases where the thyroid status is unknown, it is advisable that clinicians carefully consider the diagnostic/therapeutic procedure chosen and, preferably, choose one that does not include iodine contrast agent.

An important aspect is monitoring thyroid function (TSH and fT3 level) before and four weeks after iodine-containing contrast agent administration, and informing patients about possible and reversible symptoms.

Thyroid morphology and function disturbances after iodine administration are of a transient character, and require monitoring but not necessarily treatment.

Disclosure

None of the authors have disclosed any relevant financial interest.

References

1. Maia A, Goemann I, Meyer E, Wajner S. Type 1 iodothyronine deiodinase in human physiology and disease. Deiodinases: the balance of thyroid hormone. *J Endocrinol* 2011; 209: 283–297.
2. Laurberg P, Nøhr S, Pedersen KM et al. Thyroid disorders in mild iodine deficiency. *Thyroid* 2000; 10: 951–62.
3. Delange F, de Benoist B, Pretell E et al. Iodine deficiency in the world: where do we stand at the turn of the century? *Thyroid* 2001; 11: 437–447.
4. Knudsen N, Bulow I, Jorgensen T et al. Goitre prevalence and thyroid abnormalities at ultrasonography: a comparative epidemiological study in two regions with slightly different iodine status. *Clin Endocrinol* 2000; 53: 479–485.
5. Krohn K, Führer D, Bayer Y et al. Molecular pathogenesis of euthyroid and toxic multinodular goiter. *Endocrine Rev* 2005; 26: 504–524.
6. Valentino R, Savastano S, Tommaselli AP et al. Screening a coastal population in Southern Italy: iodine deficiency and prevalence of goitre, nutritional aspects and cardiovascular risk factors. *Nutr Metab Cardiovasc Dis* 2004; 14: 15–19.
7. Roti E, Uberta ED. Iodine excess and hyperthyroidism. *Thyroid* 2001; 11: 493–500.
8. Szybiński Z, Jarosz M, Hubalewska-Dydejczyk A et al. Iodine-deficiency prophylaxis and the restriction of salt consumption — a 21st century challenge. *Profilaktyka jodowa a ograniczenie spożycia soli — wyzwanie XXI wieku. Endokrynol Pol* 2010; 61: 135–140.
9. Zimmermann MB, Adou P, Torresani T et al. Effect of oral iodized oil on thyroid size and thyroid hormone metabolism in children with concurrent selenium and iodine deficiency. *Eur J Clin Nutr* 2000; 54: 209–213.
10. Rasmussen LB, Ovesen L, Bülow et al. Relations between various measures of iodine intake and thyroid volume, thyroid nodularity, and serum thyroglobulin. *Am J Clin Nutr* 2002; 76: 1069–1076.
11. Fassbender WJ, Schlüter S, Stracke H. Thyroid function after iodine-containing contrast agent administration in coronary angiography: a prospective study of euthyroid patients. *Z Kardiol* 2001; 90: 751–759.
12. Gartner W, Weissel M. Do iodine-containing contrast media induce clinically relevant changes in thyroid function parameters of euthyroid patients within the first week? *Thyroid* 2004; 14: 521–524.
13. Dedov JJ, Melnicenko GA, Sviridenko NI et al. Diagnostics treatment and prevention of iatrogenic iodine-induced thyroid gland diseases. *Vestern Ross Akad Nauk* 2006; 2: 15–22.
14. Ergonov VS, Sviridenka NI, Platonova NM et al. Disturbances of thyroid function after coronary angiography. *Kardiologia* 2006; 46: 46–49.
15. Nolte W, Muller R, Siggelkow H et al. Prophylactic application of thyrostatic drugs during excessive iodine exposure in euthyroid patients with thyroid autonomy: a randomized study. *Eur J Endocrinol* 1996; 134: 337–341.