



Submitted: 16.04.2024
Accepted: 19.05.2024
Early publication date: 22.07.2024

Endokrynologia Polska
DOI: 10.5603/ep.100278
ISSN 0423–104X, e-ISSN 2299–8306
Volume/Tom 75; Number/Numer 4/2024

Recent guidelines for diagnostic and therapeutic management of accidentally detected adrenal tumours (incidentaloma) in adults

Katarzyna Janiak, Katarzyna Jóźwik-Plebanek, Grzegorz Kamiński

Department of Endocrinology and Radioisotope Therapy, Military Institute of Medicine — National Research Institute, Warsaw, Poland

Abstract

At the end of 2023, the European Journal of Endocrinology published the latest guidelines of the European Society of Endocrinology (ESE) on the management of accidentally detected adrenal tumours (incidentalomas) in adults. Comparing them with the previous version of the ESE recommendations from 2016, a tendency towards far-reaching individualisation of the therapeutic and diagnostic approach in patients with adrenal incidentaloma can be seen — it is reflected by changes in the initial assessment of the malignancy of the lesion, in the scope of the proposed hormonal assessment, and qualification for surgery.

The latest version of the guidelines includes 9 completely new recommendations, and 5 more recommendations have been significantly changed. Among the most important changes, the introduction of the term “mild autonomous cortisol secretion” (MACS) instead of the previously used term “autonomous cortisol secretion (ACS)” along with more precise recommendations regarding its management should be emphasised. An important novelty is also the modification of the criteria for benign adrenal adenoma, which does not require further imaging observation — due to the results of recent clinical studies, the authors have removed the criteria of size below 4 cm from the definition. Among others, the guidelines also encourage more proactive surgical treatment of indeterminate adrenal incidentaloma in people < 40 years of age and pregnant women. The authors of the recommendations repeatedly accentuate the importance of a multidisciplinary approach in making decisions regarding further management of patients with an unspecified adrenal tumour.

Despite a few significant differences compared to the previous version of guidelines, the authors emphasise the presence of gaps in the current scientific evidence, which would not allow for the formulation of more unambiguous recommendations. The need to optimise ordered diagnostic tests, which generate additional socio-economic burdens without negative impact on patients' health, is also an important aspect of the latest guidelines. (*Endokrynol Pol* 2024; 75 (4): 385–394)

Key words: adrenal incidentaloma; adrenal tumour; adrenal adenoma

Introduction

The first recommendations for the management of adrenal incidentaloma were published in 2002 by the National Institutes of Health [1]. Over time, in light of new scientific reports and simultaneously with the lack of large-scale prospective clinical studies, subsequent guidelines were issued, among others by the American Association of Clinical Endocrinologists (AAACE) and the American Association of Endocrine Surgeons (2009) [2], the Canadian Urological Association (2011) [3], the Italian Association of Clinical Endocrinologists (2011) [4], and the Korean Endocrine Society (KES) (2017) [5]. Most of these guidelines agreed on the initial hormonal and radiographic evaluation of incidental adrenal lesions; however, strategies regarding the management of hormonally active lesions or the management of lesions that do not qualify for surgery have evolved in recent years.

In 2023, the European Society of Endocrinology (ESE) published the latest guidelines on the management of accidentally detected adrenal tumours (incidentalomas) in adults. The current version of the guidelines includes the results of over 80 new clinical studies that have been published in the 8 years since the previous recommendations.

The 4 key issues discussed in detail in the guidelines include assessment of the risk of malignancy of the lesion, diagnosis and management of a new disease entity – mild autonomous cortisol secretion (MACS), qualifications for surgical treatment in patients with adrenal incidentaloma, and a scheme for monitoring patients not qualified for surgical treatment.

The most important novelties in relation to the previous guidelines that should be mentioned include the following:

— new criteria of benign adrenal lesions that do not need further imaging observation;



Katarzyna Janiak, Department of Endocrinology and Radioisotope Therapy, Military Institute of Medicine — National Research Institute, ul. Szaserów 128, 04–141 Warsaw, Poland; e-mail: kjaniak@wim.mil.pl

- defining the group of patients with mild autonomic cortisol secretion (MACS) as a group of patients without features of overt Cushing's syndrome and with serum cortisol after dexamethasone suppression test (DST) > 50 nmol/L (> 1.8 µg/dL), with new guidelines for clinical assessment and recommendations for surgical management in this group of patients;
- modification and specification of the approach to patients with lesions with an intermediate risk of malignancy, depending on the imaging characteristics;
- recommendations for surgical resection if an indeterminate adrenal mass appears on imaging in children, adolescents, pregnant women, and adults < 40 years of age;
- a new approach to the problem of bilateral adrenal incidentaloma.

Adrenal incidentaloma is an abnormal structural lesion of the adrenal gland (or both adrenal glands) detected accidentally in imaging tests performed for indications other than suspicion of hormonally active tumours of the adrenal cortex or medulla.

It is estimated that the incidence of adrenal incidentaloma is on average approximately 2% (1.0–8.7%) and increases noticeably with age [7–9]. This change is most often detected between the fifth and seventh decade of life.

Based on large population studies, the frequency of detecting focal lesions of the adrenal glands has increased approximately 10-fold over the last 3 decades, which is primarily explained by the increasing number of imaging tests performed [10]. Most of the focal adrenal lesions found are benign, hormonally inactive, or adenomas with mild cortisol secretion (Tab. 1).

Multidisciplinary team of experts

Similarly, to previous recommendations, the current guidelines constantly emphasise the role of a multidisciplinary team of experts, consisting of an experienced radiologist, endocrinologist, and surgeon, on whose opinion therapeutic decisions should be based, especially in cases of ambiguous, progressive, or hormonally active lesions.

The authors of the guidelines recommend making therapeutic decisions based on the above-mentioned group of experts in cases where at least one of the following criteria is met:

1. The lesion in the imaging examination has a phenotype other than benign;
2. Laboratory tests performed show excessive secretion of hormones (including mild autonomic cortisol secretion), which may cause or worsen the course of comorbidities;

Table 1. Aetiology and incidence of accidentally detected adrenal tumours in adults

Aetiology	Incidence in patients with adrenal incidentaloma
Adrenocortical adenoma or macroscopic bilateral adrenal hyperplasia	80–85%
Hormonally inactive	40–70%
Mild autonomic cortisol secretion	20–50%
Primary hyperaldosteronism	2–5%
Cushing's syndrome	1–4%
Pheochromocytoma	1–5%
Adrenal cortex cancer	0.4–4%
Other malignant lesions (most often metastatic lesions of extra-adrenal tumours)	3–7%
Other focal lesions	
Myelolipoma	3–6%
Cysts and pseudocysts	1.00%
Ganglioneuroma	1%
Schwannoma	< 1%
Haematomas	< 1%

3. Surgical treatment is considered;
4. The focal lesion is significantly enlarged in follow-up imaging examinations.

Malignancy risk assessment

The authors of the ESE 2023 guidelines recommend that all accidentally detected lesions in the adrenal glands should be assessed for the risk of malignancy with the highest possible precision at the first imaging assessment. For this purpose, non-contrast computed tomography (CT) is recommended as the first-choice method if it has not already been performed — to assess the homogeneity of the lesion and the lipid content.

Lesions with benign phenotype

In the case of focal lesions in the adrenal glands with a benign phenotype in non-contrast tomography (homogeneous lesions and basic density ≤ 10 HU), it is recommended that further diagnostic imaging be discontinued. Compared to the 2016 recommendations, the additional criterion of lesion size (< 4 cm) was removed for lesions with a density ≤ 10 HU.

Based on these criteria, no further imaging will be required in around 70% of incidentalomas.

Lesions with indeterminate phenotype

In the case of homogeneous focal lesions up to 4 cm in size, with a density between 11 and 20 HU, which are

still lesions with a low risk of malignancy, in patients in whom no significant abnormalities were noted in additional hormonal tests, it is suggested that additional imaging examinations immediately be performed [e.g. magnetic resonance imaging (MRI), ^{18}F -fluoro-2-deoxy-D-glucose positron emission tomography/computed tomography (^{18}F]FDG PET/CT), or CT with late contrast washout analysis] to avoid further long-term imaging follow-up.

An alternative to the above-proposed procedure is to perform follow-up imaging tests every 12 months using computed tomography (or MRI) without contrast.

Loss of signal intensity on out-phase imaging (chemical shift on MRI) or ^{18}F]FDG uptake on PET/CT examination lower than uptake of liver are evidence of the benign nature of the lesion.

Lesions with high risk of malignancy

In the case of focal lesions with a relatively high risk of malignancy, i.e. larger than 4 cm, heterogeneous lesions, or densities above 20 HU, it is recommended that the patient be discussed with a multidisciplinary expert team meeting. Although immediate surgery will be the treatment of choice in most cases, additional imaging (e.g. ^{18}F]FDG PET/CT) should be considered in some cases.

If the patient is qualified for surgical treatment, it is suggested that an initial assessment of the advancement of the disease be performed (including at least chest CT and/or ^{18}F]FDG PET/CT examination).

If surgical treatment is not performed, the authors of the guidelines recommend performing a follow-up imaging examination within 6–12 months.

Undetermined lesions

In the cases of patients whose adrenal lesions do not meet any of the above criteria (i.e. the focal lesion is over 4 cm in size and the density is 11–20 HU, or the focal lesion is below 4 cm and the density over 20 HU, or the size of the focal lesion is < 4 cm but it has a heterogeneous character in imaging studies), it is suggested that further therapeutic decisions should be made individually as part of a multidisciplinary meeting of experts. The probability of malignancy in this type of focal lesions is relatively low; therefore, in most cases the treatment of choice is to immediately perform additional imaging tests according to the experience and local availability. If, after additional imaging tests, the risk of the lesion remains undetermined and the patient is not qualified for surgical treatment, it is recommended to perform follow-up imaging tests every 6–12 months.

Biopsy of adrenal lesions is not recommended unless there is a high risk of extra-adrenal tumour metastasis to the adrenal gland. Moreover, in patients with a clinically

significant suspicion of adrenal cancer, it is suggested that sex hormones and steroidogenic precursors be measured (optimally by tandem mass spectrometry).

A diagram summarising the management of patients depending on the phenotype of the adrenal gland lesion is presented in Figure 1.

Hormonal assessment

It is recommended that each patient with an accidentally detected focal adrenal lesion undergo a thorough clinical evaluation to detect possible adrenal hormonal disorders.

To exclude autonomic cortisol secretion, it is recommended that a suppression test with 1 mg of dexamethasone (DST) be performed in each patient with a diagnosed adrenal incidentaloma. In patients with poor general condition and short expected survival, DST may not be justified. The authors of the guidelines suggest interpreting DST results as a continuous rather than a categorical variable (yes/no), although the diagnostic criterion excluding autonomic cortisol secretion is still 50 mmol/L (1.8 ug/dL).

It is recommended that in patients without clinical features of Cushing's syndrome, a cortisol concentration in the 1 mg dexamethasone suppression test above 50 mmol/L (1.8 ug/dL) should be interpreted as mild autonomous cortisol secretion (MACS), without further stratification of its severity depending on cortisol concentration.

In this group of patients, it is recommended that adrenocorticotrophic hormone (ACTH) independence of cortisol secretion be confirmed by demonstrating suppression or concentration in the lower limits of normal range in the morning ACTH measurement. It is also recommended that DST be repeated to confirm the autonomy of cortisol secretion in each patient. The authors of the guidelines suggest that although other biochemical methods assessing the degree of cortisol secretion may be useful in this group of patients, the main factors determining further treatment of patients are age, the presence of comorbidities that may result from hypercortisolaemia, and the general condition of the patient.

The 2023 experts' guidelines suggest avoiding the use of the current term "subclinical Cushing's syndrome" to describe this group of patients because, as recent studies show, this condition is clinically significantly different from overt Cushing's syndrome (CS), in which, in addition to the presence of comorbidities (such as such as diabetes, hypertension, or obesity), there are also clinical symptoms of catabolism, which is associated with increased mortality of patients. It should be emphasised that in patients with MACS, CS

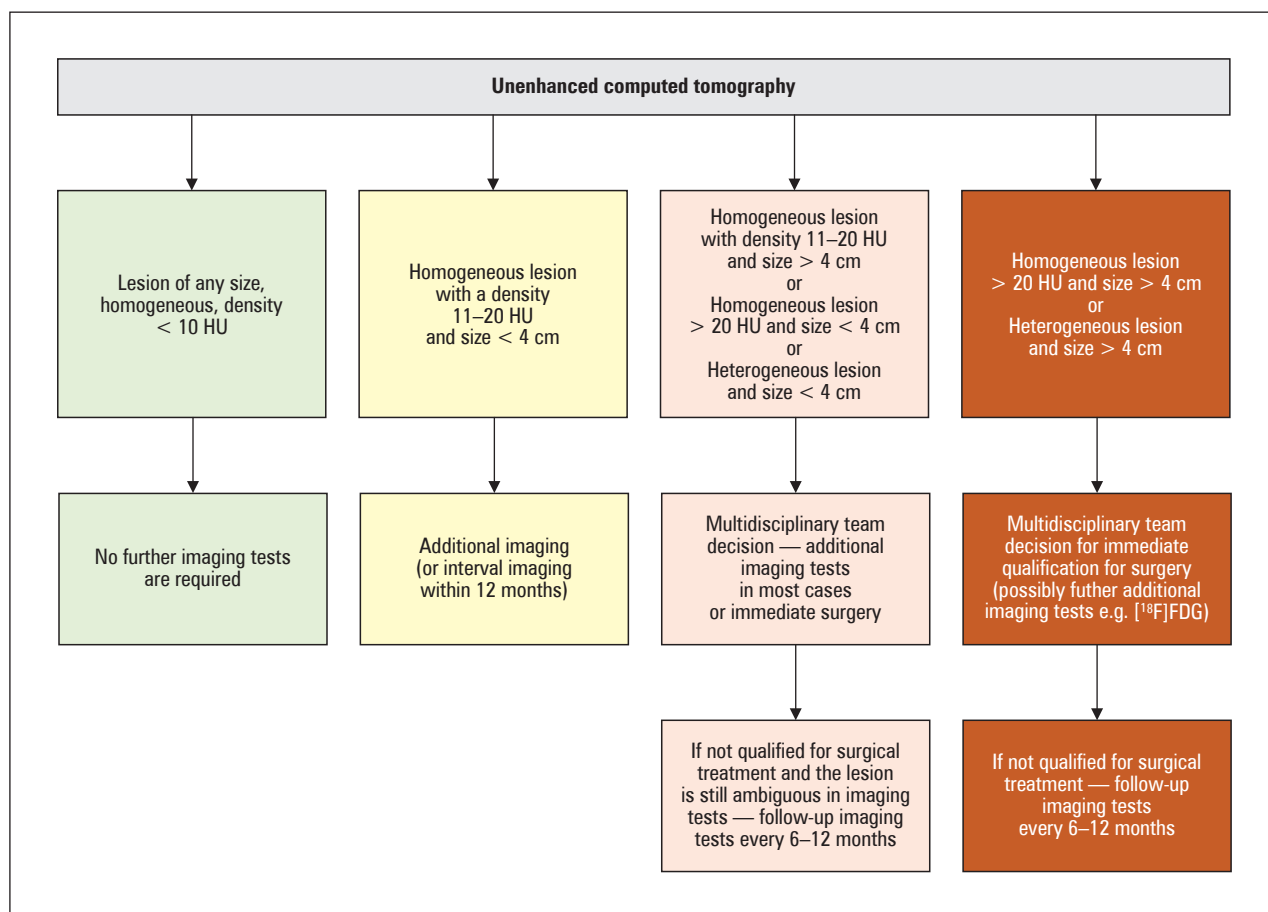


Figure 1. Algorithm of diagnostic and therapeutic procedures depending on the tomographic image of an accidentally detected lesion in the adrenal gland. ¹⁸F-FDG — ¹⁸F-fluoro-2-deoxy-D-glucose

will develop in less than 1% of patients, and this group of patients should not be unambiguously considered as patients at high risk of developing overt CS [11–15].

The authors also suggest not using the term “autonomic cortisol secretion (ACS)” for this group of patients due to the fact that ACS may include also patients with overt Cushing syndrome.

It has been shown that the presence of MACS increases the risk of developing cardiometabolic diseases such as diabetes, hypertension, or dyslipidaemia by 15–40%, which is a reason why ESE 2023 experts recommend screening for hypertension and type 2 diabetes in patients with incidentaloma of adrenal glands and biochemical features of mild autonomic cortisol secretion [16–19]. Due to the increased risk of asymptomatic vertebral fractures in patients with incidentaloma and MACS found in some studies, it is suggested to perform densitometry in this group of patients [20–23].

Due to the lack of clear scientific evidence that would determine the benefits of surgical treatment in patients with MACS, indications for surgery in this group of patients have not been defined currently. The decision on surgical treatment in each patient with

adrenal incidentaloma with diagnosed mild autonomic cortisol secretion should be individualised, made within a multidisciplinary team of experts, and the factors that should be taken into account primarily when making the decision are age, gender, general condition of the patient, degree of suppression of cortisol secretion in DST, comorbidities, and patient preferences.

Since it is not possible to predict the outcome of surgery based solely on the patient’s clinical phenotype, the authors of the recommendations jointly came to the conclusion that surgical treatment can be considered in patients with a unilateral focal lesion of the adrenal glands and cortisol concentration in DST > 50 nmol/L (> 1.8 ug/dL) and at least one feature of the comorbid disease that may be related to MACS, i.e. the comorbid disease is progressive, difficult to treat, is associated with age-inappropriate damage of internal organs, is atypical for age or inconsistent with family history, or simultaneous numerous comorbidities are present.

Two recently published large clinical studies suggest increased mortality in patients with MACS under 65 years of age [24, 25], and in one of these studies such conclusions concerned a mainly female population [24].

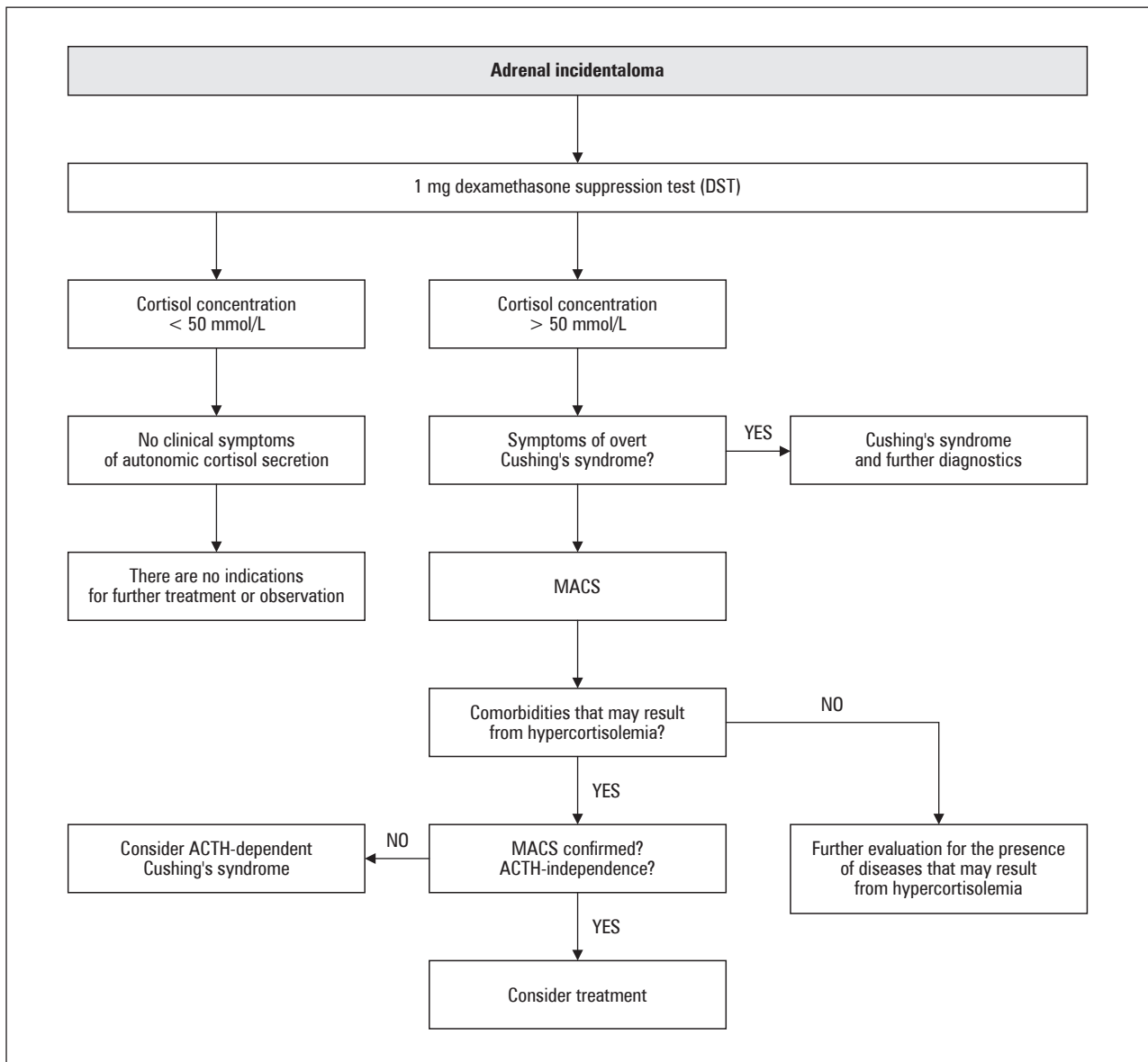


Figure 2. Diagnostic diagram of hypercortisolemia in patients with incidentally detected hypercortisolemia. MACS — mild autonomous cortisol secretion; ACTH — adrenocorticotropic hormone

A diagnostic diagram of hypercortisolemia in patients with incidentaloma is presented in Figure 2.

Pheochromocytoma

As recently published clinical studies have shown, the probability of pheochromocytoma occurrence, in the case of a focal lesion of the adrenal gland with a density < 10 HU in single-phase computed tomography, is close to zero [26–28]. That is why it is reasonable to avoid measuring the concentration of metanephrines in patients with an unambiguous image of an adenoma in imaging tests. If the adrenal lesion does not have a phenotype typical for a benign lesion, pheochromocytoma should be excluded even in the absence of clinical symptoms, especially when surgery or tumour biopsy

is planned. In a situation where single-phase computed tomography has not been performed, it is recommended to measure plasma-free metanephrines or fractionated metanephrines in 24-hour urine collection.

Primary hyperaldosteronism

In patients with concomitant hypertension or unexplained hypokalaemia, measurement of the aldosterone-renin index (ARO) is recommended to evaluate for primary hyperaldosteronism.

Steroid profile

It is recommended that the concentration of sex hormones and steroidogenic precursors (optimally using mass spectrometry) be measured only in patients

with clinical (e.g. rapid virilisation in women or rapidly developing gynecomastia in men) or radiological suspicion of adrenocortical cancer.

Recommendations regarding surgery

The ESE 2023 guidelines recommend adrenalectomy as standard treatment for unilateral adrenal lesions with clinically significant hormone excess. The authors of the recommendations emphasise that in the case of hormonally active focal lesions, the same principles of surgical approach should be applied as in the case of hormonally inactive lesions. In each patient with MACS, the decision about surgical treatment should be made individually based on the above-mentioned factors.

Surgical treatment is not recommended in the case of a single, unilateral focal lesion of the adrenal gland, hormonally inactive, with a radiological phenotype of a benign lesion. It should be emphasised that, although in the case of focal lesions of the adrenal gland with a benign phenotype, the size of the lesion does not influence decisions regarding surgical treatment, taking into account that some lesions of a significant size (e.g. large, gradually growing, e.g. myelolipoma) may cause the so-called mass effect, a more individualised approach may be considered in such cases.

If a patient with a benign adrenal gland lesion and confirmed hormonal activity (including MACS) is qualified for surgical treatment, a minimally inva-

sive method is recommended. The authors of the presented guidelines suggest adrenalectomy, performed by an experienced surgeon using a minimally invasive method, also in patients with unilateral adrenal gland lesions with radiological signs of malignancy and tumour diameter < 6 cm and without signs of local invasion. If a malignant process with local invasion is suspected, open adrenalectomy is recommended.

The ESE 2023 guidelines emphasise the important role of the experience of the operator performing the adrenalectomy, because in the case of adrenocortical cancer without distant metastases, the precision of the surgical procedure is of utmost importance in the further prognosis of patients. Although it is difficult to define a surgeon’s experience due to limited evidence, the authors of the recommendations assume a limit of 12 adrenalectomies per year [29–32].

Perioperative use of glucocorticosteroids is recommended in all patients undergoing adrenalectomy whose morning cortisol concentration in the suppression test with 1 mg of dexamethasone was above 50 nmol/L (1.8 ug/dL). The new ESE 2023 recommendation is that a patient diagnosed with MACS, who has undergone surgical treatment, should remain under endocrine monitoring until the return of normal function of the hypothalamic-pituitary-adrenal axis is documented.

The procedure for patients with adrenal incidental tumours scheduled for surgery is presented in Figure 3.

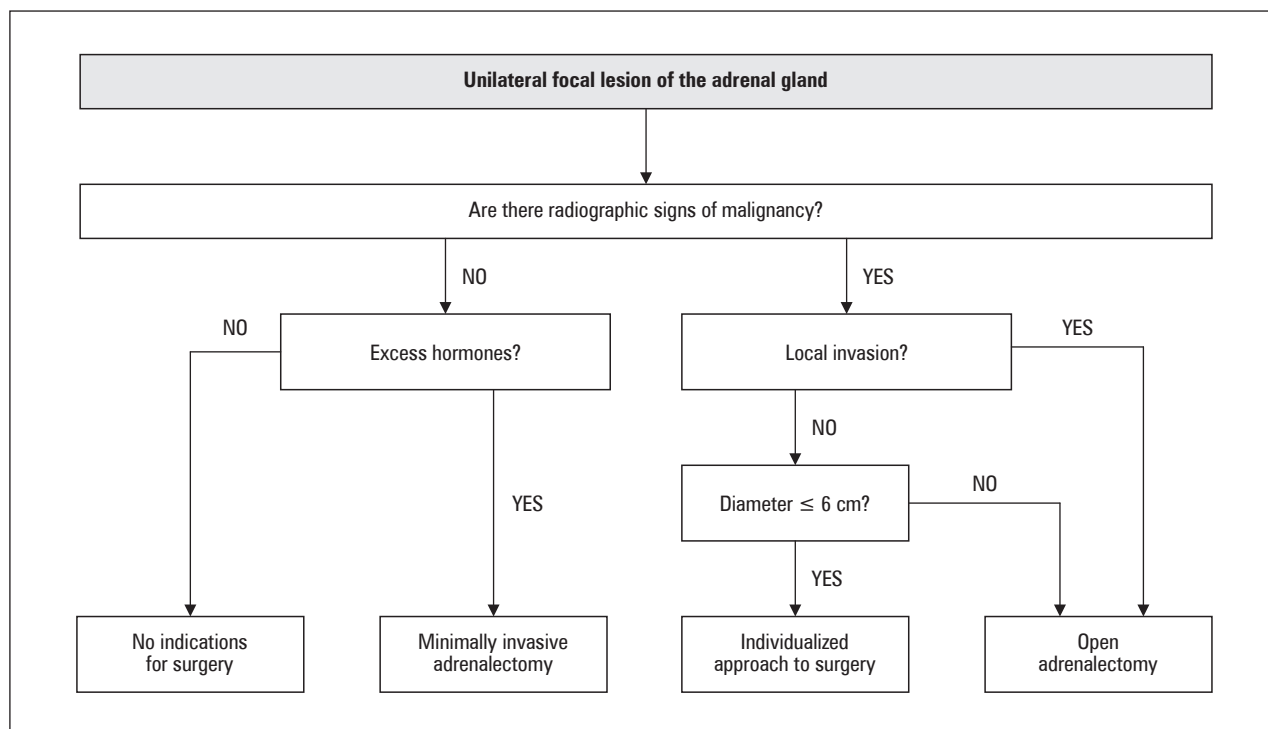


Figure 3. Scheme of management in patients with adrenal incidental tumours qualified for surgery

Observation of patients not undergoing surgical treatment

Hormonal monitoring

It is recommended to refrain from performing follow-up hormonal tests in patients with a focal lesion in the adrenal gland initially determined to be hormonally inactive if, during further observation, there are no new clinical symptoms that suggest the hormonal activity of the lesion, or the development or exacerbation of accompanying metabolic diseases (including, among others, hypertension and type 2 diabetes).

Observational studies involving 3000 patients with hormonally inactive adrenal adenoma confirmed that the risk of developing significant clinical excess of hormones is low and amounts 0.0–0.6% for the development of CS, 0.0–1.6% in the case of primary hyperaldosteronism, and 0.0–2.1% in the case of pheochromocytoma. Based on available data, the risk of development of MACS in patients with adrenal incidentaloma without previous hormonal activity is estimated at approximately 5%. Therefore, further annual clinical evaluation of this group of patients is recommended, as well as possible repetition of DST if deterioration of the clinical course of coexisting cardiometabolic diseases appears. In patients with MACS who have not undergone adrenalectomy, an annual clinical examination is recommended for the presence and severity of cardiometabolic comorbidities — it is suggested that the examination should be performed first by a primary care physician, and in the case of doubts or abnormalities the patient should be referred to an endocrinologist for re-examination, hormonal assessment, and establishing indications for surgery.

Imaging observation

Since the previous ESE recommendations in 2016, until the current guidelines were published, 5 large observational studies have been published, including a total of over 850 patients with unilateral, non-functioning adrenal adenomas [33–36]. During many years of follow-up, in most cases, the size of the lesions did not change significantly compared to the initial imaging tests, and more importantly, no malignant process occurred in any case. Considering the results of the above-mentioned studies, the authors of the ESE 2023 recommendation advise not to perform further follow-up imaging examinations in patients with focal lesions of the adrenal glands in whom initial imaging tests showed a phenotype of a benign lesion.

In patients with adrenal incidentaloma, in whom an unambiguous assessment of the risk of malignancy of the lesion was not possible at the stage of initial diagnosis, and a decision was made not to undergo surgery,

it is suggested that a single follow-up imaging examination (CT or MRI) be performed after 6–12 months to exclude any significant increase of the lesion's dimension. In the case of an increase in the dimensions of the lesion during this period by more than 20% of the maximum diameter (at the same time by at least 5 mm), surgical treatment is suggested. If an increase of size of the lesion is observed but less than 20%, follow-up imaging examinations may be considered after another 6–12 months.

Exceptional circumstances

Patients with bilateral adrenal lesions

In the case of patients with multiple or bilateral lesions in the adrenal glands, it is recommended that each lesion be assessed separately for the risk of malignancy according to the scheme for unilateral lesions.

In most cases, bilateral adrenal tumours are benign, i.e. bilateral adenomas, bilateral macroadenomatous hyperplasias, or bilateral nodules with normal or atrophic cortex. However, the possibility of metastatic lesions (especially in patients with a history of extra-adrenal cancer), adrenal lymphoma, or bilateral pheochromocytomas should always be considered.

The authors of the recommendations recommend that patients with bilateral adrenal incidentalomas, based on the results of hormonal and radiological diagnostics, should be assigned to one of the following categories:

- bilateral hyperplasia (macronodular) of the adrenal glands;
- bilateral adrenal adenomas;
- bilateral and morphologically identical focal lesions of the adrenal glands with a morphology other than adenoma;
- morphologically different bilateral focal lesions of the adrenal glands;

Further differentiation of bilateral adrenal lesions is summarised in Table 2.

Incidentaloma in elderly and young people

Evaluation of a focal adrenal lesion is recommended in pregnant women and in people under 40 years of age without delay due to the greater likelihood of malignancy and clinically significant excess hormones. The authors of the recommendations emphasise that time-consuming diagnostic procedures should be avoided in these groups of patients, and if the patient is qualified for surgery, it should not be delayed.

The authors of the guidelines suggest that in children, adolescents, pregnant women, and people < 40 years of age, lesions with an unclear risk of malignancy should be surgically removed.

Table 2. Differentiation of bilateral focal lesions of the adrenal gland

	Bilateral adrenal hyperplasia	Bilateral adrenal adenomas	Bilateral and morphologically identical focal lesions of the adrenal glands that are not adenomas	Morphologically different bilateral focal lesions of the adrenal glands
Imaging diagnostics	<p>There are 2 main types of hyperplasia:</p> <ol style="list-style-type: none"> 1. Diffuse type without obvious nodules 2. Macronodular type — both adrenal glands usually contain more than one nodule (usually with a density < 10 HU), the remaining part of the adrenal gland is usually thickened 	<p>Typically, both adrenal glands contain one distinct adenoma, the remaining limbs are within normal limits or thin</p>	<p>Focal lesions in CT/MRI not characteristic of benign lesions</p>	<p>The appearance of the tumours is clearly different on CT/MR/PET [¹⁸F]FDG, but at least one of them has features atypical for adenoma</p>
Hormonal diagnostics	<p>If bilateral CAH is suspected, especially in a patient with symptoms of hyperandrogenism, measurement of 17-OH progesterone should be considered</p>	<p>In case of symptoms/clinical features of hyperandrogenism it is recommended to measure 17-OH progesterone to exclude CAH</p>	<p>In the case of infiltrative lesions (e.g. lymphomas, metastatic lesions) or bilateral haemorrhages, it is necessary to exclude adrenal insufficiency</p>	<p>Standard hormonal assessment</p>
Clinical consequences	<ol style="list-style-type: none"> 1. If CAH is excluded, the diagnosis should be primary macronodular bilateral adrenal hyperplasia 2. In the presence of multiple nodules and ACTH-independent MACS, the patient should be offered genetic testing for pathogenic ARMC5 variants in the germline 3. In patients with MACS, unilateral adrenalectomy of the dominant lesion may be considered using an individual approach considering age, degree of excess cortisol concentration, general condition and patient preferences <p>*Bilateral adrenalectomy is not recommended for patients who do not present symptoms of Cushing's syndrome</p>	<p>In patients with MACS, the recommendations given in the guidelines should be followed. In selected individuals, unilateral adrenalectomy of the dominant lesion may be considered using an individualised approach.</p>	<ol style="list-style-type: none"> 1. In the case of pheochromocytomas, genetic testing for PGL-related genes is mandatory 2. If malignant lesions are suspected (except adrenocortical carcinoma), a biopsy should be considered 	<p>It is necessary to investigate the underlying aetiology of the disease</p>

CT — computed tomography; MRI — magnetic resonance imaging; PET — positron emission tomography; ¹⁸F-FDG — ¹⁸F-fluoro-2-deoxy-D-glucose; CAH — congenital adrenal hyperplasia; ACTH — adrenocorticotropic hormone; MACS — mild autonomous cortisol secretion; PGL — pheochromocytoma and paraganglioma; ARMC5 — armadillo repeat containing 5

Unlike typical patients with adrenal incidentaloma (i.e. > 50 years of age), in very young people it is recommended that one follow-up examination after 12 months be considered, also in the case of a benign lesion in the initial imaging evaluation.

It should be remembered that to minimise exposure to ionising radiation, magnetic resonance remains the preferred imaging modality in children, adolescents, and pregnant women. If there is no access or contraindications to MRI, a CT scan using a protocol with an appropriately adjusted low radiation dose may be considered.

In elderly patients without a history of extra-adrenal cancer, due to the much higher probability of a benign lesion, an imaging examination should be performed only when there is a reasonable suspicion of a malignant process, and the scope of the examination should be proportional to the patient's general clinical condition and the expected benefits resulting from the eventual treatment.

Based on an increasing number of scientific studies, it can be concluded that cortisol concentration in DST is more often elevated in elderly people, and it has lower clinical significance than in younger patients.

Patients with adrenal incidentaloma and a history of extra-adrenal cancer

In the case of patients with an unspecified focal lesion of the adrenal gland and a history of extra-adrenal cancer, the same diagnostic principles apply as in other groups of patients.

In the group of patients with adrenal incidentaloma and a history of extra-adrenal cancer, a high percentage of malignant tumours is observed, reaching up to 70%.

It is recommended that the metanephrine concentration in plasma and/or urine be measured in this group of patients in case of lesions of unclear nature, even if there is a suspicion that the focal adrenal lesion is metastatic. The decision to perform other additional hormonal tests should be considered individually.

Similarly, to other groups of patients, it is recommended that in the case of a benign phenotype of the lesion on non-contrast CT examination, no further imaging tests should be performed.

In patients with a history of extra-adrenal cancer, high [¹⁸F]FDG uptake in the adrenal gland in PET/CT suggests the presence of a metastatic lesion. In the case of no or moderate [¹⁸F]FDG uptake in the adrenal gland in PET/CT examination, it is recommended that the imaging diagnostics be extended, at least using single-phase computed tomography.

For a significant number of patients with advanced extra-adrenal malignancy, knowledge of the aetiology of incidentaloma will not change the clinical manage-

ment. However, if the diagnosis that the unspecified adrenal lesion is a metastasis results in a change in further treatment, further necessary diagnostics should be performed. In a situation where the focal lesion of the adrenal gland is most likely the only metastasis, and resection from an oncological point of view seems justified, adrenalectomy should be considered.

The authors of the ESE 2023 guidelines clearly formulate recommendations regarding qualification for biopsy of adrenal lesions. An adrenal biopsy may be performed in the following cases (all 3 criteria must be met):

1. The lesion is hormonally inactive (in particular, pheochromocytoma has been excluded);
2. The lesion in imaging tests was not characterised as benign;
3. Knowledge of histology diagnosis will change further clinical management of the patient.

When considering a biopsy of a focal adrenal lesion, it should be remembered that it may be associated with a significant percentage of non-diagnostic results and the possibility of complications. It is also a test that is particularly discouraged in cases of suspicion of adrenal cortical cancer, because it may spread the cancer and thus worsen the patient's prognosis.

Conclusions

The currently published guidelines certainly do not end the discussion on the management of patients with accidentally detected focal lesions in the adrenal glands. Despite significant differences compared to the previous version of ESE guidelines, the authors emphasise the need for further large-scale prospective clinical studies that will allow for the formulation of more precise recommendations.

The most important goal for the future work detailed by the authors of the newly published guidelines include, among others, the search for new biomarkers to identify patients with clinically significant cortisol excess, determining the connection between mild autonomic cortisol secretion and comorbidities, including osteoporosis, specifying second-line imaging modalities, determining the best MACS therapy based on randomised trials, or the creation of guidelines on the best surgical approach based on prospective studies.

Author contributions

Conceptualisation and supervision — G.K.; writing — original draft preparation: K.J., K.J.P.

Funding

Own funds.

Acknowledgments

None.

Conflict of interest

All the authors declare that they have no conflict of interest.

References

1. NIH state-of-the-science statement on management of the clinically inapparent adrenal mass (“incidentaloma”). NIH Consens State Sci Statements. 2002; 19(2): 1–25, indexed in Pubmed: 14768652.
2. Zeiger MA, Thompson GB, Duh QY, et al. The American Association of Clinical Endocrinologists and American Association of Endocrine Surgeons medical guidelines for the management of adrenal incidentalomas. *Endocr Pract*. 2009; 15(Suppl 1): 1–20.
3. Kapoor A, Morris T, Rebello R. Guidelines for the management of the incidentally discovered adrenal mass. *Can Urol Assoc J*. 2011; 5(4): 241–247, doi: 10.5489/auaj.11135, indexed in Pubmed: 21801680.
4. Terzolo M, Stigliano A, Chiodini I, et al. Italian Association of Clinical Endocrinologists. AME position statement on adrenal incidentaloma. *Eur J Endocrinol*. 2011; 164(6): 851–870, doi: 10.1530/EJE-10-1147, indexed in Pubmed: 21471169.
5. Lee JM, Kim MK, Ko SH, et al. Korean Endocrine Society, Committee for Clinical Practice Guidelines. Clinical Guidelines for the Management of Adrenal Incidentaloma. *Endocrinol Metab (Seoul)*. 2017; 32(2): 200–218, doi: 10.3803/EnM.2017.32.2.200, indexed in Pubmed: 28685511.
6. Fassnacht M, Arlt W, Bancos I, et al. Management of adrenal incidentalomas: European Society of Endocrinology Clinical Practice Guideline in collaboration with the European Network for the Study of Adrenal Tumors. *Eur J Endocrinol*. 2016; 172(2): G1–G34, doi: 10.1530/EJE-16-0467, indexed in Pubmed: 27390021.
7. Mansmann G, Lau J, Balk E, et al. The clinically inapparent adrenal mass: update in diagnosis and management. *Endocr Rev*. 2004; 25(2): 309–340, doi: 10.1210/er.2002-0031, indexed in Pubmed: 15082524.
8. Grumbach MM, Biller BMK, Braunstein GD, et al. Management of the clinically inapparent adrenal mass (“incidentaloma”). *Ann Intern Med*. 2003; 138(5): 424–429, doi: 10.7326/0003-4819-138-5-200303040-00013, indexed in Pubmed: 12614096.
9. Sherlock M, Scarsbrook A, Abbas A, et al. Adrenal Incidentaloma. *Endocr Rev*. 2020; 41(6): 775–820, doi: 10.1210/endrev/bnaa008, indexed in Pubmed: 32266384.
10. Ebbehøj A, Li D, Kaur RJ, et al. Epidemiology of adrenal tumours in Olmsted county, Minnesota, USA: a population-based cohort study. *Lancet Diabetes Endocrinol*. 2020; 8(11): 894–902, doi: 10.1016/S2213-8587(20)30314-4, indexed in Pubmed: 33065059.
11. Barzon L, Sonino N, Fallo F, et al. Prevalence and natural history of adrenal incidentalomas. *Br J Endocrinol*. 2003; 149(4): 273–285, doi: 10.1530/eje.0.1490273, indexed in Pubmed: 14514341.
12. Barzon L, Scaroni C, Sonino N, et al. Risk factors and long-term follow-up of adrenal incidentalomas. *J Clin Endocrinol Metab*. 1999; 84(2): 520–526, doi: 10.1210/jcem.84.2.5444, indexed in Pubmed: 10022410.
13. Bernini GP, Moretti A, Oriandini C, et al. Long-term morphological and hormonal follow-up in a single unit on 115 patients with adrenal incidentalomas. *Br J Cancer*. 2005; 92(6): 1104–1109, doi: 10.1038/sj.bjc.6602459, indexed in Pubmed: 15770213.
14. Fagour C, Bardet S, Rohmer V, et al. Usefulness of adrenal scintigraphy in the follow-up of adrenocortical incidentalomas: a prospective multicenter study. *Eur J Endocrinol*. 2009; 160(2): 257–266, doi: 10.1530/EJE-08-0299, indexed in Pubmed: 18974229.
15. Libe R, Dall’Asta C, Barbetta L, et al. Long-term follow-up study of patients with adrenal incidentalomas. *Eur J Endocrinol*. 2002; 147(4): 489–494, doi: 10.1530/eje.0.1470489, indexed in Pubmed: 12370111.
16. Deuschbein T, Reimondo G, Di Dalmazi G, et al. Age-dependent and sex-dependent disparity in mortality in patients with adrenal incidentalomas and autonomous cortisol secretion: an international, retrospective, cohort study. *Lancet Diabetes Endocrinol*. 2022; 10(7): 499–508, doi: 10.1016/S2213-8587(22)00100-0, indexed in Pubmed: 35533704.
17. Kjellbom A, Lindgren O, Puvaneswaralingam S, et al. Association Between Mortality and Levels of Autonomous Cortisol Secretion by Adrenal Incidentalomas: A Cohort Study. *Ann Intern Med*. 2021; 174(8): 1041–1049, doi: 10.7326/M20-7946, indexed in Pubmed: 34029490.
18. Di Dalmazi G, Vicennati V, Rinaldi E, et al. Progressively increased patterns of subclinical cortisol hypersecretion in adrenal incidentalomas differently predict major metabolic and cardiovascular outcomes: a large cross-sectional study. *Eur J Endocrinol*. 2012; 166(4): 669–677, doi: 10.1530/EJE-11-1039, indexed in Pubmed: 22267278.
19. Sbardella E, Minnetti M, D’Aluisio D, et al. Cardiovascular features of possible autonomous cortisol secretion in patients with adrenal incidentalomas. *Eur J Endocrinol*. 2018; 178(5): 501–511, doi: 10.1530/EJE-17-0986, indexed in Pubmed: 29510982.
20. Chiodini I, Guglielmi G, Battista V, et al. Spinal volumetric bone mineral density and vertebral fractures in female patients with adrenal incidentalomas: the effects of subclinical hypercortisolism and gonadal status. *J Clin Endocrinol Metab*. 2004; 89(5): 2237–2241, doi: 10.1210/jc.2003-031413, indexed in Pubmed: 15126547.
21. Chiodini I, Morelli V, Masserini B, et al. Bone mineral density, prevalence of vertebral fractures, and bone quality in patients with adrenal incidentalomas with and without subclinical hypercortisolism: an Italian multicenter study. *J Clin Endocrinol Metab*. 2009; 94(9): 3207–3214, doi: 10.1210/jc.2009-0468, indexed in Pubmed: 19549741.
22. Di Dalmazi G, Vicennati V, Rinaldi E, et al. Progressively increased patterns of subclinical cortisol hypersecretion in adrenal incidentalomas differently predict major metabolic and cardiovascular outcomes: a large cross-sectional study. *Eur J Endocrinol*. 2012; 166(4): 669–677, doi: 10.1530/EJE-11-1039, indexed in Pubmed: 22267278.
23. Eller-Vainicher C, Morelli V, Olivieri FM, et al. Bone quality, as measured by trabecular bone score in patients with adrenal incidentalomas with and without subclinical hypercortisolism. *J Bone Miner Res*. 2012; 27(10): 2223–2230, doi: 10.1002/jbmr.1648, indexed in Pubmed: 22549969.
24. Deuschbein T, Reimondo G, Dalmazi GD, et al. Age-dependent and sex-dependent disparity in mortality in patients with adrenal incidentalomas and autonomous cortisol secretion: an international, retrospective, cohort study. *Lancet Diabetes Endocrinol*. 2022; 10(7): 499–508, doi: 10.1016/S2213-8587(22)00100-0, indexed in Pubmed: 35533704.
25. Kjellbom A, Lindgren O, Danielsson M, et al. Association Between Mortality and Levels of Autonomous Cortisol Secretion by Adrenal Incidentalomas: A Cohort Study. *Ann Intern Med*. 2021; 174(8): 1041–1049, doi: 10.7326/M20-7946, indexed in Pubmed: 34029490.
26. Gruber L, Young WF, Bancos I, et al. Pheochromocytoma Characteristics and Behavior Differ Depending on Method of Discovery. *J Clin Endocrinol Metab*. 2019; 104(5): 1386–1393, doi: 10.1210/jc.2018-01707, indexed in Pubmed: 30462226.
27. Buitenwerf E, Korteweg T, Visser A, et al. Unenhanced CT imaging is highly sensitive to exclude pheochromocytoma: a multi-center study. *Eur J Endocrinol*. 2018; 178(5): 431–437, doi: 10.1530/EJE-18-0006, indexed in Pubmed: 29467230.
28. Canu L, Van Hemert JAW, Kerstens M, et al. CT Characteristics of Pheochromocytoma: Relevance for the Evaluation of Adrenal Incidentaloma. *J Clin Endocrinol Metab*. 2019; 104(2): 312–318, doi: 10.1210/jc.2018-01532, indexed in Pubmed: 30383267.
29. Cooper AB, Habra MA, Grubbs EG, et al. Does laparoscopic adrenalectomy jeopardize oncologic outcomes for patients with adrenocortical carcinoma? *Surg Endosc*. 2013; 27(11): 4026–4032, doi: 10.1007/s00464-013-3034-0, indexed in Pubmed: 23765427.
30. Mihai R, Donatini G, Vidal O, et al. Volume-outcome correlation in adrenal surgery — an ESES consensus statement. *Langenbecks Arch Surg*. 2019; 404(7): 795–806, doi: 10.1007/s00423-019-01827-5, indexed in Pubmed: 31701230.
31. Park HS, Roman SA, Sosa JA. Outcomes from 3144 adrenalectomies in the United States: which matters more, surgeon volume or specialty? *Arch Surg*. 2009; 144(11): 1060–1067, doi: 10.1001/archsurg.2009.191, indexed in Pubmed: 19917944.
32. Kerkhofs TM, Verhoeven RH, Bonjer HJ, et al. Surgery for adrenocortical carcinoma in The Netherlands: analysis of the national cancer registry data. *Eur J Endocrinol*. 2013; 169(1): 83–89, doi: 10.1530/EJE-13-0142, indexed in Pubmed: 23641018.
33. Elhassan YS, Alahdab E, Prete A, et al. Natural History of Adrenal Incidentalomas With and Without Mild Autonomous Cortisol Excess: A Systematic Review and Meta-analysis. *Ann Intern Med*. 2019; 171(2): 107–116, doi: 10.7326/M18-3630, indexed in Pubmed: 31234202.
34. Collienne M, Timmesfeld N, Bergmann SR, et al. Adrenal incidentaloma and subclinical Cushing’s syndrome: a longitudinal follow-up study by endoscopic ultrasound. *Ultraschall Med*. 2017; 38(04): 411–419, doi: 10.1055/s-0041-107996, indexed in Pubmed: 26529351.
35. Corwin MT, Chalfant JS, Loehfelm TW, et al. Incidentally Detected Bilateral Adrenal Nodules in Patients Without Cancer: Is Further Workup Necessary? *AJR Am J Roentgenol*. 2018; 210(4): 780–784, doi: 10.2214/AJR.17.18543, indexed in Pubmed: 29381378.
36. Goh Z, Phillips I, Hunt PJ, et al. Three-year follow up of adrenal incidentalomas in a New Zealand centre. *Intern Med J*. 2020; 50(3): 350–356, doi: 10.1111/imj.14332, indexed in Pubmed: 31058434.