

This is a provisional PDF only. Copyedited and fully formatted version will be made available soon.



## **Successful one-lung ventilation using the VivaSight-EB bronchial blocker tube for an emergency lung injury. A simulation pilot data**

**Authors:** Katarzyna Karczewska, Jacek Smereka, Lukasz Szarpak, Szymon Bialka

**DOI:** 10.5603/DEMJ.a2019.0025

**Article type:** ORIGINAL ARTICLES

**Submitted:** 2019-09-24

**Accepted:** 2019-09-24

**Published online:** 2019-10-28

This article has been peer reviewed and published immediately upon acceptance. It is an open access article, which means that it can be downloaded, printed, and distributed freely, provided the work is properly cited.

# SUCCESSFUL ONE-LUNG VENTILATION USING THE VIVASIGHT-EB BRONCHIAL BLOCKER TUBE FOR AN EMERGENCY LUNG INJURY. A SIMULATION PILOT DATA

Katarzyna Karczewska<sup>1</sup>, Jacek Smereka<sup>2</sup> , Lukasz Szarpak<sup>3</sup> , Szymon Bialka<sup>4</sup> 

<sup>1</sup>Department of Anaesthesiology, Mazovian Specialist Hospital, Radom, Poland

<sup>2</sup>Department of Emergency Medical Service, Wrocław Medical University, Wrocław, Poland

<sup>3</sup>Lazarski University, Warsaw, Poland

<sup>4</sup>Department of Anaesthesiology, Intensive Care and Emergency Medicine, Medical University of Silesia, Zabrze, Poland

---

## ABSTRACT

**INTRODUCTION:** The ability to perform endotracheal intubation is one of the basic skills that paramedics should demonstrate. However, in some cases where lung or bronchial injuries have occurred, it may be necessary to separate the lung by attaching a bronchial blocker and ventilating single lung.

The aim of the study was to evaluate the effectiveness of bronchial protection with VivaSight-EB bronchial blocker tube and one-lung ventilation by paramedics in conditions of simulated lung injury.

**MATERIAL AND METHODS:** The study was a prospective randomized cross-over simulation trial in which 27 paramedics took part. In the study, paramedics performed endotracheal intubation with ETVIEW SL and then introduced a VivaSight-EB bronchial blocker and one-lung ventilation. The bronchial protection procedure took place in two scenarios: (A) normal airway; (B) difficult airway. VivaSight-EB bronchial blocker introduction time (T1) and one-lung ventilation time (T2) and the efficacy of the procedure were analysed.

**RESULTS:** The efficacy of endotracheal intubation with ETVIEW SL tube was 100% during both Scenario A and Scenario B. The efficacy of endotracheal intubation with ETVIEW SL tube was 100%. The effectiveness of the first attempt to protect the bronchi with a bronchial blocker was 26% for both scenarios and the total effectiveness of bronchial protection was 100% in both cases. Time T1 for endotracheal intubation was 18sec for Scenario A (IQR; 16.5–25) and 20 sec for Scenario B (IQR; 17–25). The time to perform one-lung ventilation (Time T2) in scenarios A and B was 43 sec (IQR; 38–62.5) vs. 43.5 sec (38–65).

**CONCLUSIONS:** The simulation study confirmed the research hypothesis that the paramedics were able to perform one-lung ventilation using the ETVIEW-Blocker® bronchial blocker tube after a short training.

**KEY WORDS:** one-lung ventilation; paramedic; airway management; emergency medicine; lung injury; bronchial blocker

*Disaster Emerg Med J 2019; 4(4): 1–6*

---

## INTRODUCTION

Traumatic injury to the tracheobronchial tree or lungs requires prompt, accurate diagnosis for optimum surgical treatment [1, 2]. However, under the

conditions of a medical emergency team, one of the key elements is the airway management in such a patient. Endotracheal intubation and ventilation of both lungs in case of bronchial or lung injury may

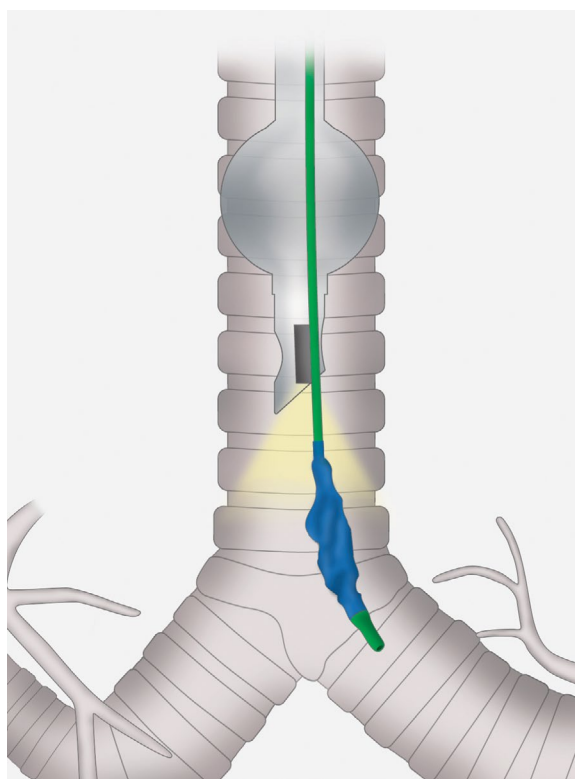
### ADDRESS FOR CORRESPONDENCE:

Jacek Smereka, Department of Emergency Medical Service, Wrocław Medical University, Wrocław, Poland  
E-mail: smereka.icu@gmail.com

adversely affect the haemodynamic of the patient, including multiple effects including the pneumothorax enlargement [3]. In this case, one-lung ventilation while blocking the other may be helpful.

One-lung ventilation during thoracotomy can be achieved via two basic techniques [4, 5]: use of a double-lumen endotracheal tube (DLT) consisting of an endotracheal and an endobronchial lumen allowing independent single-lung ventilation [6, 7]; or use of an endobronchial blocker (EBB) such as the Arndt blocker, which allows lung collapse distal to the occlusion [8, 9]. It has been recently demonstrated that DLT and endobronchial blocker are similar in their efficacy to achieve lung isolation for elective thoracic surgery [10]. In case of respiratory failure in pre-hospital conditions, endotracheal intubation is used, therefore the use of an endotracheal blocker may be more useful and easier to control by paramedics than intubation using a double-channel tube — which in the hands of personnel without adequate experience — may bring more complications than benefits to the patient [4]. A bronchial-blocker device consists of a small balloon that is purposefully inflated within the proximal portion of the main bronchus to isolate one of the lungs under bronchoscopic guidance. EBBs can be placed to achieve lung separation and may offer several advantages to patients with cardiac disease [11], or lung trauma [12]. The most significant advantage is the decrease in hemodynamic stress. Because the EBB is inserted through a single lumen tube, it is less stimulating than the insertion and manipulation of a double-lumen tube. Endobronchial blockers can be advantageous in patients with difficult airways or abnormal tracheobronchial trees.

An example of a bronchial blocker that can be used in prehospital conditions — on the event site — is the ETVIEW system. The ETVIEW SL endotracheal tube is a single lumen tube with an integrated camera that transmits images from the end of the distal endotracheal tube to the monitor attached to the endotracheal tube via a fibre optic cable. Thanks to this, a person performing endotracheal intubation in real-time can see the image from the end of the tube and is, therefore, able to perform endotracheal intubation more effectively — even in difficult Airways [13–15]. In case of one-lung ventilation using EBB, the endotracheal tube is inserted deeper than in the case of standard endotracheal intubation - in order to visualize the tracheal bifurcation, then during the insertion of the bronchial blocker it



**FIGURE 1.** Coaxial placement of endobronchial blocker

is possible to monitor in real-time the movement of the blocker and insert it to the appropriate depth into the specific bronchi (Fig. 1).

The aim of the study was to evaluate the effectiveness of bronchial blocker tube and one-lung ventilation by paramedics in the conditions of simulated lung injury. The research hypothesis is that after a short training period, paramedics are able to perform one-lung ventilation using the ETVIEW-Blocker® bronchial blocker tube.

## MATERIAL METHODS

The study was designed as a prospective randomized cross-over simulation study. The study protocol was approved by the Institutional Review Board of the Polish Society of Disaster Medicine (Approval no. 42.03.2019.IRB). Voluntary written informed consent was obtained from each participant. The data of this study were collected in May 2019. 27 paramedics with at least 1-year clinical experience participated in the study. None of the study participants had previous experience in intubation using bronchial blockers.

Each paramedic was given a standardized demonstration of EZ-Blocker® bronchial block-

er tube insertion. They were then allowed time (30 min.) to practice the one lung-ventilation on s Laerdal Airway Management Trainer (Laerdal, Stavanger, Norway). All intubations were performed using a 7.0mm cuffed single-lumen tracheal tube (ETView Ltd., Misgav, Israel).

During the target study, the subjects had to perform endotracheal intubation and then insert a bronchial blocker into the left bronchial tube, secure the blocker and ventilate with one lung using a self-inflating bag. Intubation was performed in two scenarios:

- A) Scenario A — normal airways;
- B) Scenario B — difficult airways. In order to simulate difficult airways, the simulator tongue was inflated with air in order to obtain intubation difficulties at the level of Cormack-Lehane 3 grade.

SimMan 3G (Laerdal, Stavanger, Norway) was used to simulate a patient with an injured lung and was placed on a flat surface. Both the order of participants and methods were random, using Research Randomized (Fig. 2).

## Measurements

The time to endotracheal intubation (Time T1), was defined as the time from the grasping the endotracheal tube to the inflation of the cuff sealing the endotracheal tube. T2 time was the time from grasping the intubation tube through the insertion of the bronchial blocker into the left bronchial tube, protection of the blocker until the first attempt to ventilate the right lung with the use of a self-inflating bag. The effectiveness of the procedure of introducing the bronchial blocker was considered a failure if it could not be accomplished within 150s

or in three attempts. Subjective evaluation of ease of use using a visual analogue scale score ranging from 1 (extremely easy) to 100 (extremely difficult) and overall success rate of intubation. Vocal cord visualization was assessed by using Cormack & Lehane classification [16].

## Statistical analysis

Statistical analysis was performed using the Statistical version 12.0 for Windows (StatSoft, Tulsa, OK) software. Data are presented as number (percentage), mean  $\pm$  standard deviation (SD), or median (IQR, interquartile range), as appropriate. Nonparametric tests were used for the data that did not have a normal distribution. All statistical tests were 2-sided. The Wilcoxon test for paired observations was used to compare the different times and to determine the statistical difference for each group. McNemar test was used to evaluate the differences in intubation success rates. Cormack-Lehane grade and ease of procedure score were evaluated using the Stuart-Maxwell test. A P value  $<$  0.05 was considered significant.

## RESULTS

Twenty-seven paramedics completed this study. Participants had a median of 3 years' experience (range from 1 to 8 years). No paramedic had prior experience of using ETView endotracheal tube as well as ETView bronchial blocker. all participants, However, had clinical experience with direct laryngoscopy.

The detailed specification of the parameters is presented in Table 1. The efficacy of endotracheal intubation with ETView SL tube was 100% during

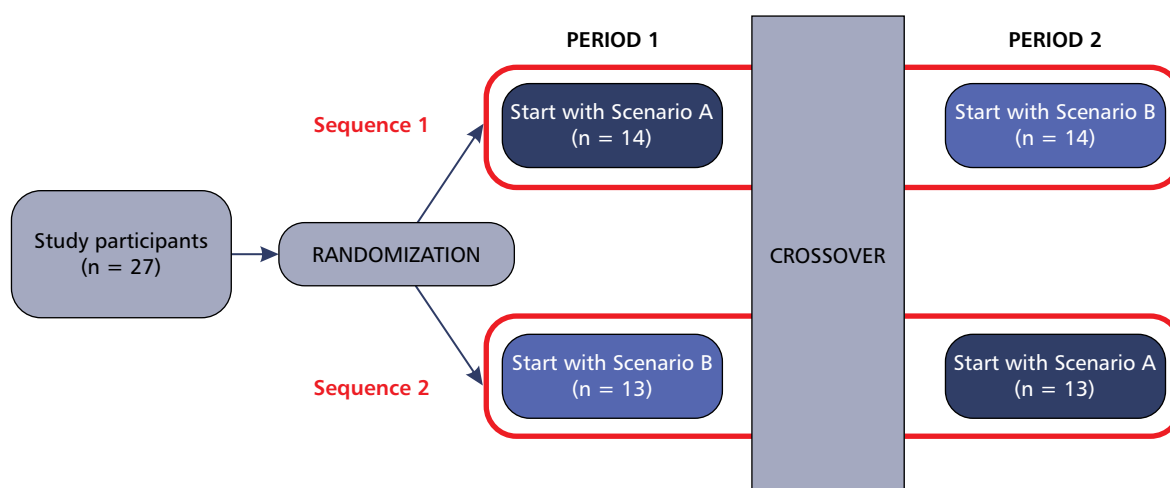


FIGURE 2. Randomization flow chart

Table 1. Comparison of study parameters		
Parameter	Scenario A	Scenario B
Time T1 — time to success intubation [s]	18 (16.5–25)	20 (17–25)
Time T2 — time to one-lung ventilation [s]	43 (38–62.5)	43.5 (38–65)
Effectiveness of endotracheal intubation	27 (100%)	27 (100%)
The total efficiency of the procedure	27 (100%)	27 (100%)
Effectiveness of bronchial protection attempts		
1	26 (96.3%)	26 (96.3%)
2	1 (3.7%)	1 (3.7%)
3	–	–
Cormack-Lehane grade		
1	27 (100%)	25 (92.6%)
2	–	2 (7.4%)
3	–	–
4	–	–
Ease of procedure	35 (30–50)	37 (30–55)

both Scenario A and Scenario B. The efficacy of endotracheal intubation with ETVIEW SL tube was 100%. The effectiveness of the first attempt to protect the bronchi with a bronchial blocker was 26% for both scenarios and the total effectiveness of bronchial protection was 100% in both cases.

Time T1 for endotracheal intubation was 18sec for Scenario A (IQR; 16.5–25) and 20 sec for Scenario B (IQR; 17–25). The difference in T1 intubation time was not statistically significant ( $p = 0.644$ ). The time to perform one-lung ventilation (Time T2) in scenarios A and B was 43 sec (IQR; 38–62.5) vs. 43.5 sec (38–65;  $p = 0.857$ ).

Cormack-Lehane grade in both scenarios was comparable and showed no statistically significant differences ( $p = 0.638$ ).

The ease of performing the procedure assessed on the VAS scale in Scenario A was 35 points (IQR; 30–50) and was slightly simpler to perform than in Scenario B — 37 points (30–55;  $p = 0.212$ ).

## DISCUSSION

Pre-hospital airway management is one of the key skills personnel working in medical rescue teams should have [17–19]. To the best of the authors' knowledge, this study is an innovative study that demonstrates for the first time the effectiveness of

bronchial protection by means of a bronchial blocker and one-lung ventilation.

In the case of high-energy injuries, where lung injuries or bronchial rupture occurred, it may be helpful to isolate the damaged lung and ventilate with one-lung ventilation, similarly as it is often the case during thoracic surgery or cardiac surgery.

In the study, both normal and difficult airway conditions, endotracheal intubation using an ETVIEW SL integrated endotracheal tube was 100% effective. ETVIEW SL is one of the types of video laryngoscopes. The effectiveness of this method is confirmed by numerous publications. In Gawlowski et al. [20], as in the case of Kurowski et al. [13] intubators were able to intubate with ETVIEW SL after a short training session with high efficacy in various emergency scenarios. Also, studies conducted by Truszczyński et al. [14] indicate high efficacy of ETVIEW intubation under normal conditions, chest compression during simulated cardiopulmonary resuscitation or cervical spine immobilization.

The median intubation time in the study ranged from 18 to 20 seconds depending on whether the intubation procedure was performed under normal or difficult airway conditions. Truszczyński et al. [14] recorded intubation time of 19.5 seconds under normal airway conditions and 23.5 seconds under cervical spine immobilization. A comparable time was also obtained by Madziara et al. Using ETVIEW intubation in face-to-face intubation of a patient trapped in a vehicle [21].

The insertion of the blocker, the subsequent inflation of the sealing cuff and the attempted single lung ventilation were obviously associated with a longer time, but it is worth mentioning that in clinical conditions when desaturation occurs, it is possible to oxygenate the patient using an intubation tube — before the insertion of the blocker. The effectiveness of the insertion of the blocker under visual control — which is allowed by the use of ETVIEW tubes — allowed paramedics to perform the procedure of isolating the left bronchus with 96.3% efficiency during the first attempt. The total effectiveness of this procedure in both normal and difficult airways was 100%.

It is also worth noting that despite the difficulties associated with tongue oedema and thus intubation conditions defined by an independent anaesthesiologist at grade 3 of the Cormack-Lehane Scale, the problem of difficult airways was eliminated with direct laryngoscopy using the ETVIEW tube. This is an

unquestionable advantage of video laryngoscopes, which are particularly useful in conditions of difficult glottis visibility such as cardiopulmonary resuscitation, cervical spine immobilization, tongue oedema or many other life-threatening conditions requiring emergency endotracheal intubation.

The conducted research has both strengths and weaknesses resulting from the nature of the conducted research. An unquestionable limitation of the conducted study is the fact that it was carried out in the conditions of medical simulation and not real medical activities with the use of real patients. However, as numerous studies show, medical simulation allows for full standardization of performed medical procedures and multiple possibilities to perform them without exposing patients to injuries resulting from performed procedures [22–24]. Another limitation of the study is the fact that only paramedics are included in the study, however, as indicated in the title itself, this is a pilot study and currently there are ongoing activities aimed at extending the target group to physicians, including anaesthesiologists, as well as increasing the study group and adding other research scenarios, including simulating airway bleeding in order to confirm the effectiveness of the camera lens flushing system used in EView [25, 26].

The choice of paramedics as a pilot group was deliberate and dictated by the fact that they rely on their skills and knowledge in the field of airway management. The conducted study also has strong points, such as randomized cross-over research, as well as the use of one of the most advanced adult patient simulators during the study.

## CONCLUSIONS

The simulation study confirmed the research hypothesis that the paramedics were able to perform one-lung ventilation using the EView-Blocker® bronchial blocker tube after a short training.

## REFERENCES:

- Varga S, Shupp JW, Maher D, et al. Trauma airway management: transition from anesthesia to emergency medicine. *J Emerg Med.* 2013; 44(6): 1190–1195, doi: [10.1016/j.jemermed.2012.11.074](https://doi.org/10.1016/j.jemermed.2012.11.074), indexed in Pubmed: [23473818](https://pubmed.ncbi.nlm.nih.gov/23473818/).
- Kosaka S. Tracheobronchial Injury. *Kyobu Geka.* 2015; 68(8): 660–664, indexed in Pubmed: [26197912](https://pubmed.ncbi.nlm.nih.gov/26197912/).
- Matthes G, Bernhard M, Kanz KG, et al. Emergency anesthesia, airway management and ventilation in major trauma. *Background and key messages of the interdisciplinary S3 guidelines for major trauma patients.* *Anaesthesist.* 2011; 60(11): 1027–1040, doi: [10.1007/s00101-011-1957-1](https://doi.org/10.1007/s00101-011-1957-1), indexed in Pubmed: [22089890](https://pubmed.ncbi.nlm.nih.gov/22089890/).
- Mourisse Jo, Liesveld J, Verhagen Ad, et al. Efficiency, efficacy, and safety of EZ-blocker compared with left-sided double-lumen tube for one-lung ventilation. *Anesthesiology.* 2013; 118(3): 550–561, doi: [10.1097/ALN.0b013e3182834f2d](https://doi.org/10.1097/ALN.0b013e3182834f2d), indexed in Pubmed: [23299364](https://pubmed.ncbi.nlm.nih.gov/23299364/).
- Moritz A, Irouschek A, Birkholz T, et al. The EZ-blocker for one-lung ventilation in patients undergoing thoracic surgery: clinical applications and experience in 100 cases in a routine clinical setting. *J Cardiothorac Surg.* 2018; 13(1): 77, doi: [10.1186/s13019-018-0767-9](https://doi.org/10.1186/s13019-018-0767-9), indexed in Pubmed: [29940993](https://pubmed.ncbi.nlm.nih.gov/29940993/).
- Hoogenboom EM, Ong C, Christodoulides G. Placement of VivaSight(TM) double lumen tube. *Anaesthesia.* 2016; 71(6): 725–726, doi: [10.1111/anae.13501](https://doi.org/10.1111/anae.13501), indexed in Pubmed: [27158993](https://pubmed.ncbi.nlm.nih.gov/27158993/).
- Loop T, Spaeth J. Airway Management in Thoracic Anesthesia with Double-Lumen Tube. *Anesthesiol Intensivmed Notfallmed Schmerzther.* 2018; 53(3): 174–185, doi: [10.1055/s-0043-114678](https://doi.org/10.1055/s-0043-114678), indexed in Pubmed: [29554710](https://pubmed.ncbi.nlm.nih.gov/29554710/).
- Sawasdiwipachai P, Boonsri S, Sukksompong S, et al. The uses of laryngeal mask airway ProSeal™ and endobronchial blocker for one lung anesthesia. *J Anesth.* 2015; 29(5): 660–665, doi: [10.1007/s00540-015-2004-1](https://doi.org/10.1007/s00540-015-2004-1), indexed in Pubmed: [25820271](https://pubmed.ncbi.nlm.nih.gov/25820271/).
- Lim HK, Ahn HS, Byon HJ, et al. Clinical experience of one lung ventilation using an endobronchial blocker in a patient with permanent tracheostomy after total laryngectomy. *Korean J Anesthesiol.* 2013; 64(4): 386–387, doi: [10.4097/kjae.2013.64.4.386](https://doi.org/10.4097/kjae.2013.64.4.386), indexed in Pubmed: [23646255](https://pubmed.ncbi.nlm.nih.gov/23646255/).
- Campos JH, Kernstine KH. A comparison of a left-sided Broncho-Cath with the torque control blocker univent and the wire-guided blocker. *Anesth Analg.* 2003; 96(1): 283–9, table of contents, doi: [10.1097/00000539-200301000-00056](https://doi.org/10.1097/00000539-200301000-00056), indexed in Pubmed: [12505967](https://pubmed.ncbi.nlm.nih.gov/12505967/).
- Al Shehri AM, El-Tahan MR, Al Metwally R, et al. Right ventricular function during one-lung ventilation: effects of pressure-controlled and volume-controlled ventilation. *J Cardiothorac Vasc Anesth.* 2014; 28(4): 880–884, doi: [10.1053/j.jvca.2013.09.012](https://doi.org/10.1053/j.jvca.2013.09.012), indexed in Pubmed: [24447503](https://pubmed.ncbi.nlm.nih.gov/24447503/).
- Pandharikar N, Sachdev A, Gupta N, et al. Chest trauma: A case for single lung ventilation. *Indian J Crit Care Med.* 2016; 20(4): 248–250, doi: [10.4103/0972-5229.180050](https://doi.org/10.4103/0972-5229.180050), indexed in Pubmed: [27303142](https://pubmed.ncbi.nlm.nih.gov/27303142/).
- Kurowski A, Szarpak L, Truszewski Z, et al. Can the EView VivaSight SL Rival Conventional Intubation Using the Macintosh Laryngoscope During Adult Resuscitation by Novice Physicians?: A Randomized Cross-over Manikin Study. *Medicine (Baltimore).* 2015; 94(21): e850, doi: [10.1097/MD.0000000000000850](https://doi.org/10.1097/MD.0000000000000850), indexed in Pubmed: [26020389](https://pubmed.ncbi.nlm.nih.gov/26020389/).
- Truszewski Z, Krajewski P, Fudalej M, et al. A comparison of a traditional endotracheal tube versus EView SL in endotracheal intubation during different emergency conditions: A randomized, crossover cadaver trial. *Medicine (Baltimore).* 2016; 95(44): e5170, doi: [10.1097/MD.00000000000005170](https://doi.org/10.1097/MD.00000000000005170), indexed in Pubmed: [27858851](https://pubmed.ncbi.nlm.nih.gov/27858851/).

15. Markic S. Endotracheal tube ETView as a tool for airway management. *Disaster and Emergency Medicine Journal*. 2018; 3(4): 152–153, doi: [10.5603/demj.2018.0032](https://doi.org/10.5603/demj.2018.0032).
16. Glosser L. Assessment of endotracheal tube intubation. Review of existing scales. *Disaster and Emergency Medicine Journal*. 2017; 2(2): 91–93, doi: [10.5603/demj.2017.0017](https://doi.org/10.5603/demj.2017.0017).
17. Lockey DJ, Healey B, Crewdson K, et al. Advanced airway management is necessary in prehospital trauma patients. *Br J Anaesth*. 2015; 114(4): 657–662, doi: [10.1093/bja/aeu412](https://doi.org/10.1093/bja/aeu412), indexed in Pubmed: [25540067](https://pubmed.ncbi.nlm.nih.gov/25540067/).
18. Duchateau FX, Beardmore M, Gauss T, et al. Advanced prehospital airway management in patients with traumatic brain injury. *Eur J Emerg Med*. 2016; 23(5): 395, doi: [10.1097/MEJ.0000000000000359](https://doi.org/10.1097/MEJ.0000000000000359), indexed in Pubmed: [27571279](https://pubmed.ncbi.nlm.nih.gov/27571279/).
19. Jeong S, Ahn KiOk, Shin SDo. The role of prehospital advanced airway management on outcomes for out-of-hospital cardiac arrest patients: a meta-analysis. *Am J Emerg Med*. 2016; 34(11): 2101–2106, doi: [10.1016/j.ajem.2016.07.025](https://doi.org/10.1016/j.ajem.2016.07.025), indexed in Pubmed: [27503061](https://pubmed.ncbi.nlm.nih.gov/27503061/).
20. Gawlowski P, Smereka J, Madziala M, et al. Comparison of the ETView Single Lumen and Macintosh laryngoscopes for endotracheal intubation in an airway manikin with immobilized cervical spine by novice paramedics: A randomized crossover manikin trial. *Medicine (Baltimore)*. 2017; 96(16): e5873, doi: [10.1097/MD.00000000000005873](https://doi.org/10.1097/MD.00000000000005873), indexed in Pubmed: [28422820](https://pubmed.ncbi.nlm.nih.gov/28422820/).
21. Madziala A, Majer J, Madziala M. Comparison of ETView SL, Airtraq, and Macintosh laryngoscopes for face-to-face tracheal intubation: a randomized crossover manikin trial. *Am J Emerg Med*. 2016; 34(9): 1893–1894, doi: [10.1016/j.ajem.2016.06.074](https://doi.org/10.1016/j.ajem.2016.06.074), indexed in Pubmed: [27372222](https://pubmed.ncbi.nlm.nih.gov/27372222/).
22. Issenberg SB, McGaghie WC, Petrusa ER, et al. Features and uses of high-fidelity medical simulations that lead to effective learning: a BEME systematic review. *Med Teach*. 2005; 27(1): 10–28, doi: [10.1080/01421590500046924](https://doi.org/10.1080/01421590500046924), indexed in Pubmed: [16147767](https://pubmed.ncbi.nlm.nih.gov/16147767/).
23. Sawyer T, Gray MM. Procedural training and assessment of competency utilizing simulation. *Semin Perinatol*. 2016; 40(7): 438–446, doi: [10.1053/j.semperi.2016.08.004](https://doi.org/10.1053/j.semperi.2016.08.004), indexed in Pubmed: [27692475](https://pubmed.ncbi.nlm.nih.gov/27692475/).
24. Abellsson A. Learning through simulation. *Disaster and Emergency Medicine Journal*. 2017; 2(3): 125–128, doi: [10.5603/demj.2017.0027](https://doi.org/10.5603/demj.2017.0027).
25. Grensemann J, Eichler L, Hopf S, et al. Feasibility of an endotracheal tube-mounted camera for percutaneous dilatational tracheostomy. *Acta Anaesthesiol Scand*. 2017; 61(6): 660–667, doi: [10.1111/aas.12904](https://doi.org/10.1111/aas.12904), indexed in Pubmed: [28493334](https://pubmed.ncbi.nlm.nih.gov/28493334/).
26. Barak M, Assalia A, Mahajna A, et al. The use of VivaSight™ single lumen endotracheal tube in morbidly obese patients undergoing laparoscopic sleeve gastrectomy. *BMC Anesthesiol*. 2014; 14: 31, doi: [10.1186/1471-2253-14-31](https://doi.org/10.1186/1471-2253-14-31), indexed in Pubmed: [24817827](https://pubmed.ncbi.nlm.nih.gov/24817827/).