

ULTRASOUND ASSESSMENT OF THE OPTIC NERVE SHEATH AS AN INDIRECT METHOD OF DIAGNOSIS OF INCREASED INTRACRANIAL PRESSURE

Kurt Ruetzler¹, Maciej Dudek², Dominika Dunder², Lukasz Szarpak²

¹Department of Outcomes Research, Anesthesiology Institute, Cleveland Clinic, Cleveland, USA;
Department of General Anesthesiology, Anesthesiology Institute, Cleveland Clinic, Cleveland, USA

²Lazarski University, Warsaw, Poland

ABSTRACT

Ultrasonography is a diagnostic technique that has been used clinically for 30 years. Due to the increased availability of ultrasound machines as well as the reduction of their size and making them more mobile, ultrasound has found its place in early diagnosis in emergency medicine settings. One of the important, however, an underestimated ultrasound examination is the measurement of the thickness of the optic nerve sheath. The optic nerve is the second cranial nerve, meaning the same sheath surrounds it as the brain. At the moment of intracranial pressure increase, cerebrospinal fluid flows into the subarachnoid space causing an increase in intracranial pressure and thus increasing the diameter of the optic nerve sheath. therefore, ONSD imaging is a quick non-invasive test aimed at detecting and monitoring changes in intracranial pressure. Optic nerve sheath ultrasound is a simple, safe and inexpensive bedside diagnostic test. Ophthalmic ultrasound usually uses the frequency between 5 and 10.5 MHz to evaluate the eye and the orbit.

KEY WORDS: ultrasound test; emergency medicine; intracranial pressure; optic nerve

Disaster Emerg Med J 2019; 4(1): 14–17

INTRODUCTION

Ultrasound assessment of the orbits is used widely in the assessment of patients in life-threatening situations. This method of ultrasound is used in the assessment of patients after blunt injuries of the eye and head. In the ultrasound examination, we can recognize eye rupture, lens displacement, vitreous haemorrhage or retrobulbar bleeding.

At present, ultrasound is used frequently in the non-invasive intracranial pressure (ICP) diagnosis. For this purpose, the assessment of the width of the optic nerve sheath is in the retrobulbar segment [1]. The optic nerve is relatively easy to assess for the

being part of the nervous system that connects directly to the brain. The optic nerve is the second cranial nerve and is surrounded by the same sheath as the brain [2]. When intracranial pressure increases, the cerebrospinal fluid flows into the subarachnoid space causing an increase in pressure (enlarging the diameter) of the optic nerve [3]. Knowing this relationship, we can indirectly determine intracranial pressure (ICP) [4].

The assessment of the thickness of the optic nerve sheath can be performed in patients with blunt head injuries and unconscious for unknown reasons [5, 6], or for indeterminate headaches [7]. The test may be

ADDRESS FOR CORRESPONDENCE:

Lukasz Szarpak, Lazarski University, 43 Swieradowska Str., 02–662 Warsaw, Poland; e-mail: lukasz.szarpak@gmail.com

particularly useful in emergency medical conditions, including emergency medical service, where a radiological diagnosis is not available [8, 9].

ULTRASOUND EXAMINATION METHODS

The measurement is carried out using an 8–11 MHz high-frequency linear transducer. Of course, if such a transducer is unavailable, any available linear probe may be used. Regardless of the frequency range of the transducer in use, it is important to remember to increase the frequency (higher Hertz number) on the device to increase the probe resolution. The depth of penetration on the device (Depth) is set at about 3.5–4 cm, with the device displaying on the monitor screen 1.5–2 cm from the posterior wall of the orbital globe.

The patient should be on his or her back or in a semi-sitting position; this is important as the gel has a relatively thin consistency and may run down in a vertical position. During the examination, the patient's eyelids must be closed, because a transducer will be applied directly to them. The eye of the patient can also be protected with "vener" so that the gel does not get under the eyelid. Gel pad (spacer) can also be used, thanks to which the gel will not have contact with the patient's eyelids. The method is optional; however, we must remember the fundamental principle that there must be no air between the probe and the eyelid which would prevent imaging. The structure of the eye is permeable to ultrasonic waves so that the test can be performed with high accuracy every time. The test time should not exceed one minute.

The transducer should be gripped gently (just like a pencil) and applied gently and evenly in one or two planes to the eye. Pressure should be controlled to avoid any possible injury to the eyeball. A simple method to control the degree of pressure is to lightly support one's finger on the subject's nose, which will allow an easily maintained correct distance. If the patient is conscious, ask the patient to look straight ahead during the examination.

Measure the diameter of the optic nerve using the "3 X 5" principle meaning that the calculation is made 3 mm from the posterior wall of the orbital globe, where 5 mm means an impassable limit of the correct width of the optic nerve with the capsule (Fig. 1). The correct diameter of the optic nerve for an adult does not exceed 5 mm, for a child 4.5 mm, and for infants 4 mm.

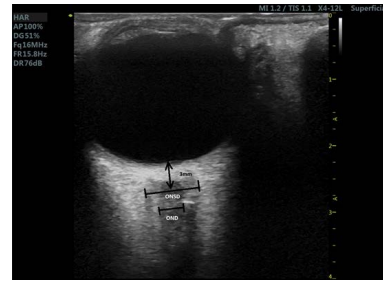

FIGURE 1. Optic nerve (OND) and optic nerve sheath (ONSD)

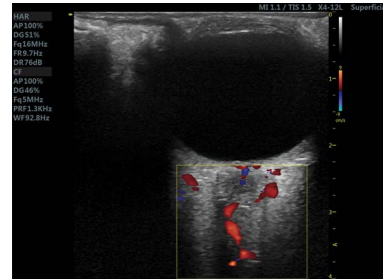

FIGURE 2. Central retinal artery

The optic nerve diameter (OND) is represented on the image as a hypoechoic structure (darker than the environment). The optic nerve sheath diameter (ONSD) is brighter than the optic nerve but still darker than the surrounding tissues.

If there is a problem with the location of the nerve, coloured Doppler may be used (Fig. 2). Anatomically, the artery and vein of the retina run inside the optic nerve; information marked with colour will allow for precise determination the position of the nerve.

The method is simple and provides accurate information although it is not always possible to perform (Fig. 3). Results may appear distorted by alcohol, drugs, orbital wounds, optic nerve atrophy, eye injuries, or optic neuritis.

CONCLUSIONS

As Karami indicated, ultrasound methods have been proposed as a safe alternative technique for invasive ICP measuring methods [10]. Other researchers also came to similar conclusions [11–13].

As indicated by Betcher, optic nerve sheath measurement can be accurately performed by novice ultrasonographers after a brief training session [14]. Szarpak et al. also indicated that ultrasound examination of the optic nerve is a simple measure of intracranial pressure and can be performed with

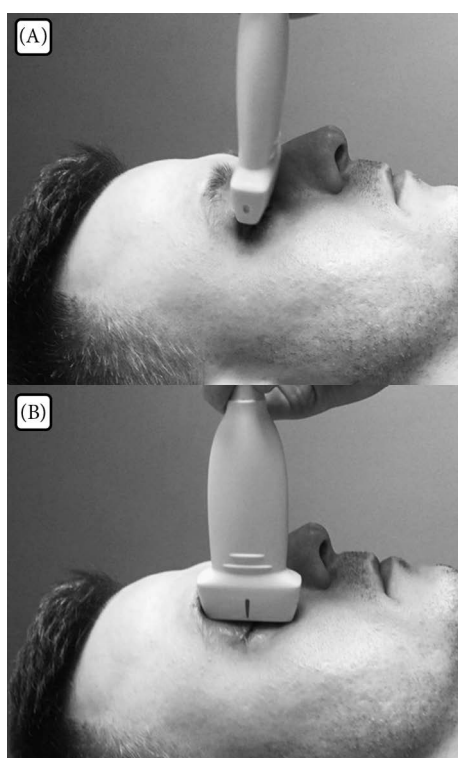


FIGURE 3. The method of applying the ultrasound head: (A) Axial View; (B) Sagittal View

high efficiency by paramedics after a short training [15]. The optography examination of the optic nerve should be considered as a routine indirect method of intracranial pressure measurement. It has a high predictive value. Shirodkar et al. found a positive correlation between ocular ultrasonography and magnetic resonance imaging of ONSD [16]. In turn, Yesilaras et al. indicated that in patients with spontaneous subarachnoid haemorrhage (SAH), the optic nerve sheath diameter measured in the orbital sections of a non-contrast head computed tomography is strongly correlated with a SAH diagnosis [17]. Badamoe Zeiler et al. [18] suggests a significant finite learning curve associated with ONSD measurements.

REFERENCES

1. Ohle R, Mclsaac SM, Woo MY, et al. Sonography of the Optic Nerve Sheath Diameter for Detection of Raised Intracranial Pressure Compared to Computed Tomography: A Systematic Review and Meta-analysis. *J Ultrasound Med.* 2015; 34(7): 1285–1294, doi: [10.7863/ultra.34.7.1285](https://doi.org/10.7863/ultra.34.7.1285), indexed in Pubmed: [26112632](https://pubmed.ncbi.nlm.nih.gov/26112632/).
2. Hylkema C. Optic Nerve Sheath Diameter Ultrasound and the Diagnosis of Increased Intracranial Pressure. *Crit Care Nurs Clin North Am.* 2016; 28(1): 95–99, doi: [10.1016/j.cnc.2015.10.005](https://doi.org/10.1016/j.cnc.2015.10.005), indexed in Pubmed: [26873762](https://pubmed.ncbi.nlm.nih.gov/26873762/).

3. Dudek M, Szarpak L, Ruetzler K. Application of interventional ultrasound in emergency medicine conditions. *Disaster and Emergency Medicine Journal.* 2018; 3(4): 137–147, doi: [10.5603/demj.2018.0029](https://doi.org/10.5603/demj.2018.0029).
4. Goel RS, Goel P. Optic nerve sheath diameter as ICP marker. *J Neurosurg.* 2016; 124(3): 890–891, doi: [10.3171/2015.9.JNS152178](https://doi.org/10.3171/2015.9.JNS152178), indexed in Pubmed: [26771850](https://pubmed.ncbi.nlm.nih.gov/26771850/).
5. Thotakura AK, Marabathina NR, Danaboyina AR, et al. Role of serial ultrasonic optic nerve sheath diameter monitoring in head injury. *Neurochirurgie.* 2017; 63(6): 444–448, doi: [10.1016/j.neuchi.2017.06.001](https://doi.org/10.1016/j.neuchi.2017.06.001), indexed in Pubmed: [29122307](https://pubmed.ncbi.nlm.nih.gov/29122307/).
6. Dubourg J, Javouhey E, Geeraerts T, et al. Ultrasonography of optic nerve sheath diameter for detection of raised intracranial pressure: a systematic review and meta-analysis. *Intensive Care Med.* 2011; 37(7): 1059–1068, doi: [10.1007/s00134-011-2224-2](https://doi.org/10.1007/s00134-011-2224-2), indexed in Pubmed: [21505900](https://pubmed.ncbi.nlm.nih.gov/21505900/).
7. Canakci Y, Koksak O, Durak VA. The value of bedside ocular ultrasound assessment of optic nerve sheath diameter in the detection of increased intracranial pressure in patients presenting to the emergency room with headache. *Niger J Clin Pract.* 2018; 21(6): 778–782, doi: [10.4103/njcp.njcp_119_17](https://doi.org/10.4103/njcp.njcp_119_17), indexed in Pubmed: [29888727](https://pubmed.ncbi.nlm.nih.gov/29888727/).
8. Oberfoell S, Murphy D, French A, et al. Inter-rater Reliability of Sonographic Optic Nerve Sheath Diameter Measurements by Emergency Medicine Physicians. *J Ultrasound Med.* 2017; 36(8): 1579–1584, doi: [10.7863/ultra.16.05055](https://doi.org/10.7863/ultra.16.05055), indexed in Pubmed: [28370143](https://pubmed.ncbi.nlm.nih.gov/28370143/).
9. Aksoy Y, Eyi YE. The Bedside Ultrasound: A Rapid Way of Measuring Optic Nerve Sheath Diameter in Emergency. *J Emerg Med.* 2016; 51(2): e25–e26, doi: [10.1016/j.jemermed.2015.06.090](https://doi.org/10.1016/j.jemermed.2015.06.090), indexed in Pubmed: [27283482](https://pubmed.ncbi.nlm.nih.gov/27283482/).
10. Karami M, Shirazinejad S, Shaygannejad V, et al. Transocular Doppler and optic nerve sheath diameter monitoring to detect intracranial hypertension. *Adv Biomed Res.* 2015; 4: 231, doi: [10.4103/2277-9175.167900](https://doi.org/10.4103/2277-9175.167900), indexed in Pubmed: [26645016](https://pubmed.ncbi.nlm.nih.gov/26645016/).
11. Pal A, Dhar P, Goyal N. Perioperative monitoring of intracranial pressure using optic nerve sheath diameter in paediatric liver transplantation. *Indian J Anaesth.* 2018; 62(11): 892–895, doi: [10.4103/ija.IJA_104_18](https://doi.org/10.4103/ija.IJA_104_18), indexed in Pubmed: [30532327](https://pubmed.ncbi.nlm.nih.gov/30532327/).
12. Terkawi AS, Karakitsos D, Elbarbary M, et al. Ultrasound for the anesthesiologists: present and future. *ScientificWorldJournal.* 2013; 2013: 683685, doi: [10.1155/2013/683685](https://doi.org/10.1155/2013/683685), indexed in Pubmed: [24348179](https://pubmed.ncbi.nlm.nih.gov/24348179/).
13. Kane SC, Khong SuL, da Silva Costa F. Diagnostic Imaging: Ultrasound. *Methods Mol Biol.* 2018; 1710: 1–8, doi: [10.1007/978-1-4939-7498-6_1](https://doi.org/10.1007/978-1-4939-7498-6_1), indexed in Pubmed: [29196990](https://pubmed.ncbi.nlm.nih.gov/29196990/).
14. Betcher J, Becker TK, Stoyanoff P, et al. Military trainees can accurately measure optic nerve sheath diameter after a brief training session. *Mil Med Res.* 2018; 5(1): 42, doi: [10.1186/s40779-018-0189-y](https://doi.org/10.1186/s40779-018-0189-y), indexed in Pubmed: [30572931](https://pubmed.ncbi.nlm.nih.gov/30572931/).
15. Szarpak Ł, Truszewski Z, Kurowski A, et al. Knowledge, attitude, and practices of paramedics regarding optic nerve sheath diameter ultrasonography. *Am J Emerg Med.* 2016; 34(6): 1160–1161, doi: [10.1016/j.ajem.2016.02.063](https://doi.org/10.1016/j.ajem.2016.02.063), indexed in Pubmed: [26994678](https://pubmed.ncbi.nlm.nih.gov/26994678/).

16. Shirodkar CG, Munta K, Rao SM, et al. Correlation of measurement of optic nerve sheath diameter using ultrasound with magnetic resonance imaging. *Indian J Crit Care Med.* 2015; 19(8): 466–470, doi: [10.4103/0972-5229.162465](https://doi.org/10.4103/0972-5229.162465), indexed in Pubmed: [26321806](https://pubmed.ncbi.nlm.nih.gov/26321806/).
17. Yesilaras M, Kilic TY, Yesilaras S, et al. The diagnostic and prognostic value of the optic nerve sheath diameter on CT for diagnosis spontaneous subarachnoid hemorrhage. *Am J Emerg Med.* 2017; 35(10): 1408–1413, doi: [10.1016/j.ajem.2017.04.022](https://doi.org/10.1016/j.ajem.2017.04.022), indexed in Pubmed: [28431869](https://pubmed.ncbi.nlm.nih.gov/28431869/).
18. Zeiler FA, Ziesmann MT, Goeres P, et al. A unique method for estimating the reliability learning curve of optic nerve sheath diameter ultrasound measurement. *Crit Ultrasound J.* 2016; 8(1): 9, doi: [10.1186/s13089-016-0044-x](https://doi.org/10.1186/s13089-016-0044-x), indexed in Pubmed: [27501699](https://pubmed.ncbi.nlm.nih.gov/27501699/).