







Gurusha Bahl¹ , Dinesh K. Upadhyay¹ , Madhumati Varma² , Rajveer Singh¹ ,
Subhankar Das¹ , Md Sadique Hussain¹ 

¹School of Pharmaceutical Sciences, Jaipur National University, Jaipur, 302017, Rajasthan, India

²Department of Medicine, Jaipur National University Institute for Medical Sciences and Research Center, Jaipur, 302017, Rajasthan, India

Chronic Calcific Pancreatitis Presented with Secondary Diabetes and Diabetic Ketoacidosis: A Case Report

Introduction

Diabetes is a group of metabolic disorders mainly characterized by hyperglycemia, polyphagia, polydipsia, and polyuria resulting from defects in insulin secretion, insulin action, or both [1]. Pancreatogenic Diabetes is classified as a form of secondary diabetes by the American Diabetes Association (ADA) and refers to diabetes secondary to an existing disease or condition of the exocrine pancreas [2, 3]. This patient was diagnosed with pancreatic secondary diabetes with diabetic ketoacidosis (DKA).

Case report

A 36-year-old male patient with worsening glycaemic control and with complaints of polyuria, polydipsia along with progressive and gradual abdominal pain was presented to the male medicine ward in November 2022. Patient's HbA1c value at the time of admission was 13.7% (normal: less than 5.7%, for prediabetes: 5.7–6.4%, and for diabetes: more than 6.5%) and random plasma glucose was found to be 405 mg/dL. Other laboratory investigations showed

normal hemoglobin levels but slightly decreased total leukocyte count along with sodium and mild elevation in globulin was observed. A computed tomography (CT) of the abdomen revealed chronic calcific pancreatitis with intraductal calculi and dilated pancreatic duct (Fig. 1A). Atrophic pancreas was seen which showed diffuse parenchymal calcification (Fig. 1B) and calculus of size 8 mm was seen in duct region of body of the pancreas and another calculus of 11 mm was seen in the duct region of head of the pancreas (Fig. 1C).

Patient was given intravenous fluid, normal saline 1000 mL in 2 hours followed by 120 mL per hour and insulin 12 unit initially followed by 15 unit and 20 unit before breakfast and 14, 20, 24 units before lunch and 12, 20 and 24 units before dinner and insulin glargine 10 unit was started initially followed by 20 units. Also metformin 500 mg tablet twice daily was given after meal. Patient was discharged with insulin regular 20 units before breakfast, 24 units before lunch and 24 units before dinner and 30 minutes before meal and insulin glargine was given 20 units subcutaneously at night. Patient was placed on certain diet and diabetes related teaching was provided to the patient during the hospital admission. Patient was told to follow up with the primary care physician. The patient was further advised for magnetic resonance cholangiopancreatography (MRCP).

Discussion

Around 10% of the total individuals suffering from diabetes have been diagnosed with chronic pancreatitis (CP). Development of diabetes in CP occurs mainly due

Address for correspondence:

Mr. Md Sadique Hussain
School of Pharmaceutical Sciences
Jaipur National University, Jaipur, Rajasthan, 302017, India
phone: 8235463635
email: sadiquehussain007@gmail.com
Clinical Diabetology 2023, 12; 3: 209–210
DOI: 10.5603/DK.a2023.0015
Received: 11.03.2023 Accepted: 19.04.2023
Early publication date: 30.05.2023

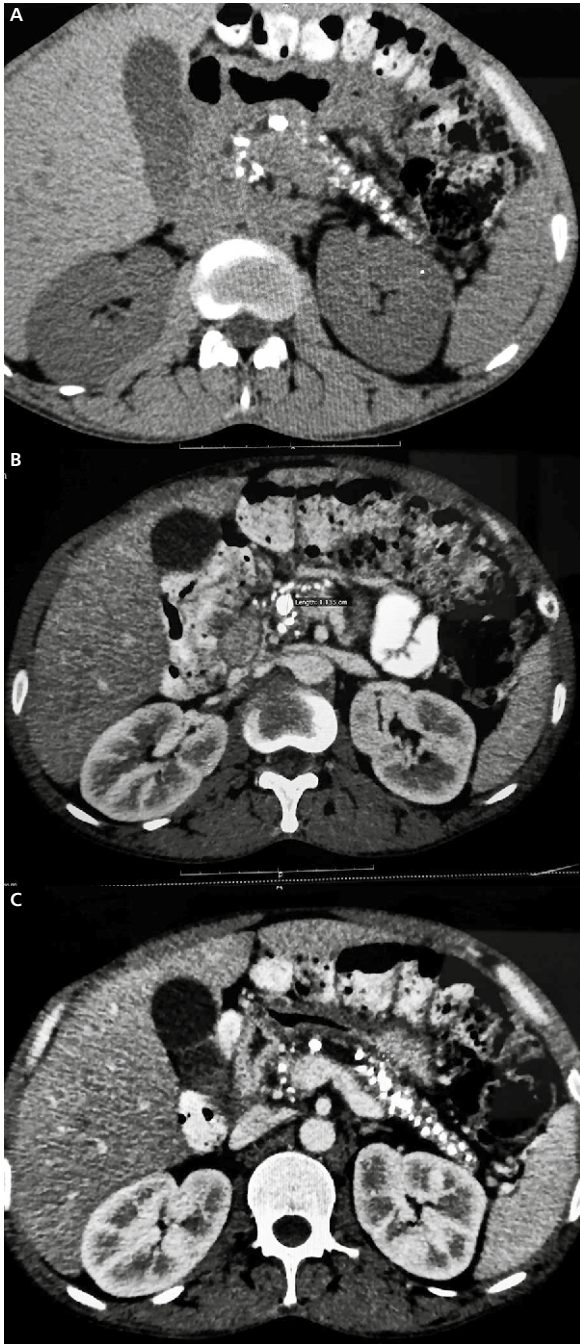


Figure 1. CECT Scan of Abdomen Showing **A.** Diffuse Parenchymal Calcifications and Dilated Pancreatic Duct; **B.** Chronic Calcific Pancreatitis with Intra Ductal Calculi; **C.** Multiple Calcifications Involving the Head, Body, and Tail of Pancreatic Parenchyma

to destruction of the islet cells by pancreatic inflammation. Nutrient maldigestion also leads to impaired incretin secretion resulting in reduced insulin release from the remaining β -cells [4]. Chronic calcific pancreatitis is one of the most common causes of secondary diabetes which is commonly underdiagnosed or misdiagnosed [5].

Conclusions

Secondary diabetes is a rare condition, often overlooked, underdiagnosed, or mistaken for type 1 or type 2 diabetes. So, in patients suffering from CP presenting with DKA it is important to consider about secondary diabetes for planning effective long-term management. CT scan and MRI play an important role in the diagnosis of the small subset of the population affected with secondary diabetes which should be considered. The limitations of the study is lack of islet antibodies or c-peptide measurements.

Declarations

Ethics approval and consent to participate

Informed consent was obtained from the patient for publication of this case report including the clinical information and accompanying images.

Consent for publication

The patient was assured that their name and initials will not be published.

Availability of data and material

This work has been carried out by us and we assure you that it can be provide to you whenever required.

Funding

Not applicable.

Acknowledgements

I take this opportunity to thank my parents and all the faculty members for their continuous support and guidance to publish this case report.

Conflict of interest

None declared.

REFERENCES

1. Kumari R, Kaur J, Hussain S. Management of Diabetes with Covid-19: A Review. *Int J Pharm Pharm.* 2020; 12(12): 1–6, doi: [10.22159/ijpps.2020v12i12.39968](https://doi.org/10.22159/ijpps.2020v12i12.39968).
2. ElSayed NA, Aleppo G, Aroda VR, et al. 2. Classification and Diagnosis of Diabetes: Standards of Care in Diabetes-2023. *Diabetes Care.* 2023; 46(Suppl 1): S19–S40, doi: [10.2337/dc23-S002](https://doi.org/10.2337/dc23-S002), indexed in Pubmed: [36507649](https://pubmed.ncbi.nlm.nih.gov/36507649/).
3. Ewald N, Bretzel RG. Diabetes mellitus secondary to pancreatic diseases (Type 3c)--are we neglecting an important disease? *Eur J Intern Med.* 2013; 24(3): 203–206, doi: [10.1016/j.ejim.2012.12.017](https://doi.org/10.1016/j.ejim.2012.12.017), indexed in Pubmed: [23375619](https://pubmed.ncbi.nlm.nih.gov/23375619/).
4. Melki G, Laham L, Karim G, et al. Chronic Pancreatitis Leading to Pancreatogenic Diabetes Presenting in Diabetic Ketoacidosis: A Rare Entity. *Gastroenterology Res.* 2019; 12(4): 208–210, doi: [10.14740/gr1203](https://doi.org/10.14740/gr1203), indexed in Pubmed: [31523331](https://pubmed.ncbi.nlm.nih.gov/31523331/).
5. Duggan SN, Ewald N, Kelleher L, et al. The nutritional management of type 3c (pancreatogenic) diabetes in chronic pancreatitis. *Eur J Clin Nutr.* 2017; 71(1): 3–8, doi: [10.1038/ejcn.2016.127](https://doi.org/10.1038/ejcn.2016.127), indexed in Pubmed: [27406162](https://pubmed.ncbi.nlm.nih.gov/27406162/).