

# Cutaneous metastasis from breast carcinoma — case report and review of the literature

## Przerzut raka piersi do skóry — opis przypadku i przegląd piśmiennictwa

**Konrad Wroński<sup>1, 2</sup>, Leszek Frąckowiak<sup>1</sup>, Luiza Kańczuga-Koda<sup>3</sup>**

<sup>1</sup>Department of Oncology, Faculty of Medicine, University of Warmia and Mazury in Olsztyn, Olsztyn, Poland (Katedra Onkologii, Wydział Nauk Medycznych Uniwersytetu Warmińsko-Mazurskiego w Olsztynie)

<sup>2</sup>Department of Surgical Oncology, Hospital Ministry of Internal Affairs with Warmia and Mazury Oncology Centre, Olsztyn, Poland (Oddział Chirurgii Onkologicznej, Zakład Opieki Zdrowotnej Ministerstwa Spraw Wewnętrznych z Warmińsko-Mazurskim Centrum Onkologii w Olsztynie)

<sup>3</sup>Department of Patomorphology, Maria Skłodowska Curie Memorial Cancer Centre, Białystok, Poland (Zakład Patomorfologii, Białostockie Centrum Onkologii im. Marii Skłodowskiej Curie w Białymstoku)

---

### Abstract

Cutaneous metastasis may occur from different carcinomas. The most common carcinomas to metastasize to the skin are malignant melanoma and breast carcinoma. Breast cancer is the most common cause of skin metastases in female population. Cutaneous breast metastases are observed mainly on the chest wall but head and neck, are also common sites. The presence of skin metastases signifies widespread systemic disease and a poor prognosis for patients.

This article presents a case of an 86-year-old Caucasian woman who was treated in the hospital due to skin metastasis from breast cancer. The authors performed a literature review on skin metastases from breast cancer.

**Key words:** breast cancer, skin metastasis, treatment

Polish Surgery 2014, 16, 1, 94–96

### Streszczenie

Przerzuty do skóry mogą wystąpić z różnych nowotworów. Najczęstszymi nowotworami dającymi przerzuty do skóry są czerniak i rak piersi. Rak piersi jest najczęstszą przyczyną przerzutów do skóry wśród populacji kobiet. Przerzuty z raka piersi są głównie obserwowane w skórze klatki piersiowej, ale także w skórze głowy i szyi. Obecność przerzutów skórnych oznacza rozsianą chorobę nowotworową i złe rokowanie dla pacjentów.

W artykule przedstawiono przypadek 86-letniej kobiety rasy białej, która była leczona w szpitalu z powodu przerzutu raka piersi do skóry. Autorzy przeprowadzili przegląd piśmiennictwa na temat przerzutów raka piersi do skóry.

**Słowa kluczowe:** rak piersi, przerzut do skóry, leczenie

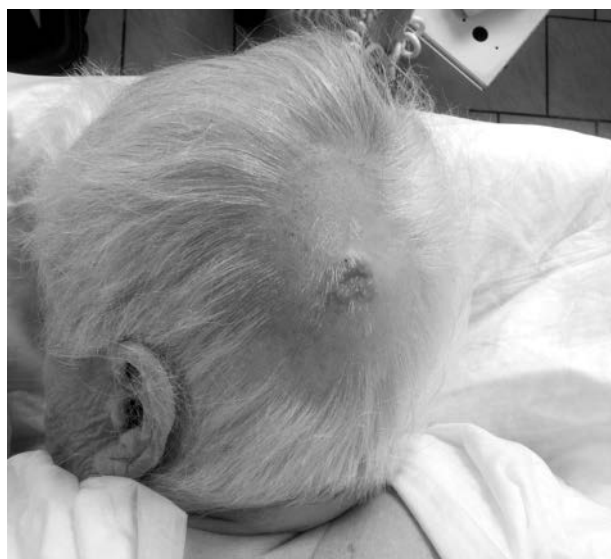Chirurgia Polska 2014, 16, 1, 94–96

---

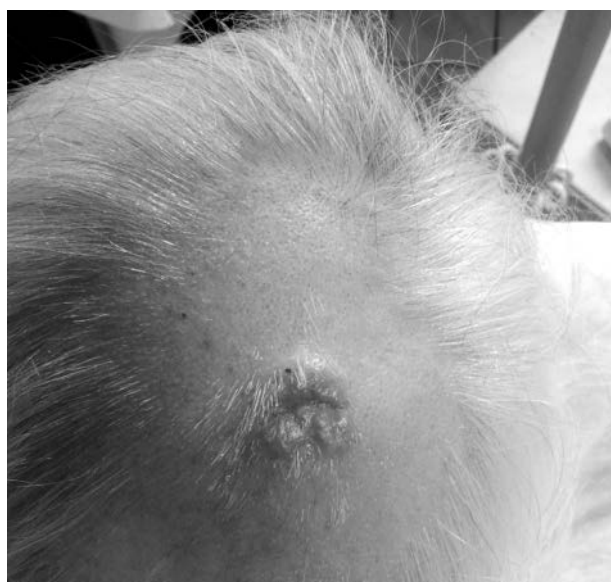## Introduction

Cutaneous metastasis may occur from different carcinomas [1]. The most common carcinomas to metastasize

to the skin are malignant melanoma and breast carcinoma [1, 2]. Breast cancer is the most common cause of skin metastases in female population [3]. Cutaneous breast metastases mainly are observed on the chest wall but



**Figure 1.** The diameter of the skin tumour in palpable examination was 20 mm and it was located on the scalp

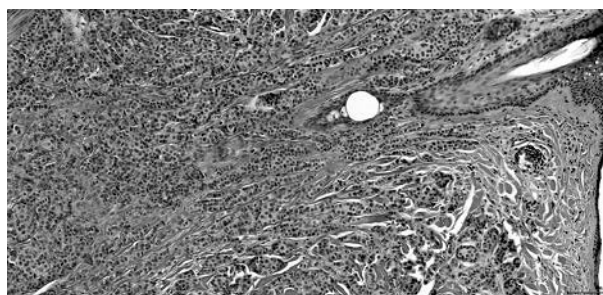


**Figure 2.** Cutaneous metastasis from breast carcinoma

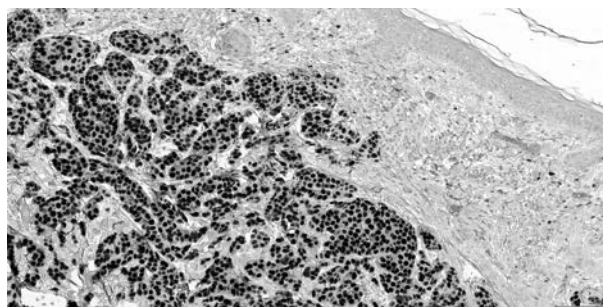
head and neck, are also common sites [4]. The presence of skin metastases signifies widespread systemic disease and a poor prognosis for patients.

### Case report

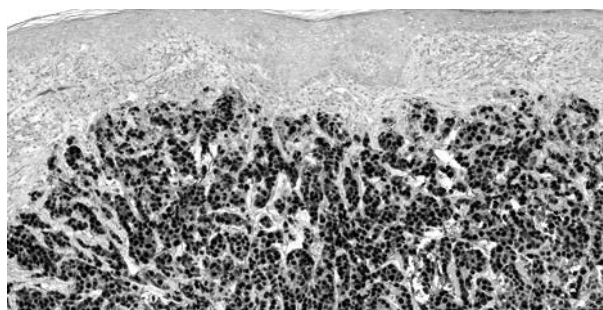
An 86-year-old Caucasian woman was referred to the Department of Surgical Oncology due to skin tumour. The diameter of this tumour in palpable examination was 20 mm and it was located on the scalp of the head (Figure 1 and 2). The patient's medical history revealed that six years ago she was treated for diagnosed with infiltrating ductal breast carcinoma and successfully treated by mastectomy with axillary lymph node. She had a history of axillary lymph node metastases that



**Figure 3.** Infiltration of malignant cells in the dermis (HE, 200x)



**Figure 4.** Tumour cells are positive to oestrogen receptors in 100% (100x)



**Figure 5.** Tumour cells are positive to progesterone receptors in 100% (100x)

were successfully treated with chemotherapy. The patient was treated with hormone therapy for five years. One year after hormone therapy, the patient has seen rapid growth of the skin tumour in the scalp of the head. She had no other symptoms; there was no history of weight loss or loss of appetite. The patient was treated chronically for ischaemic heart disease. She had negative family history for carcinoma. Blood test and other routine haematological examinations and biochemical tests were within normal limits.

In the Department of Surgical Oncology the patient underwent surgical resection of the skin tumour. Next day after the surgery, the patient left the department.

Pathological diagnosis showed skin metastasis from breast carcinoma (Figure 3). Tumour cells were ER (+) in 100% neoplasm cells, PR (+) in 100% neoplasm cells, CKAE1/AE3 (+), CK7 (+), CK20 (-), S-100 (-), TTF (-) and CDX-2 (-) (Figure 4-6).

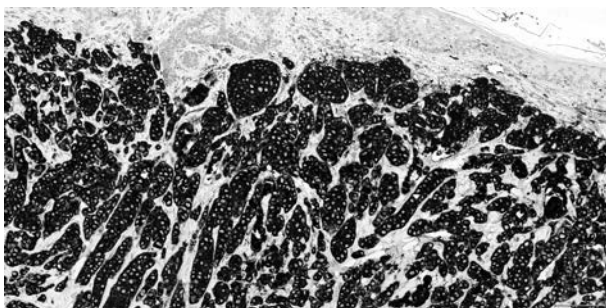


Figure 6. Tumour cells are positive to CK7 (100x)

The patient is now under the care of oncological out-patient clinic at our hospital. The patient has resumed hormone therapy and she feels good. Fourth months after surgery, there was no recurrence or metastasis.

## Discussion

The skin metastases from internal malignancies are rare and were observed in up to 9% autopsies of cancer patients [5]. Metastasis is defined as a neoplastic lesion arising from another neoplasm with which it is no longer in contiguity or is not in close proximity with the same tissue [2]. In the majority of cases, skin metastases are from malignant melanoma and breast carcinoma [1, 2]. Skin metastases from carcinoma of the lung, oral cavity, stomach, colon, kidney and ovary have been observed [4].

Most cutaneous metastases are observed on the chest and abdomen wall but head and neck are also common sites [2, 4]. Metastases to extremities are rare [1, 2, 4]. Metastases in scalp associated with alopecia are known as Alopecia-neoplastica.

Metastasis to the skin may be haematogenous or via lymphatics. Breast and oral cavity carcinoma spread (metastasize) via lymphatics. Solitary skin metastasis can be misdiagnosed as primary skin tumour [4]. Sometimes, skin metastases are observed before the symptoms of the primary disease occur [1, 2, 4]. There are many morphological variants of the skin metastases such as solitary or multiple erythematous infiltrating papules and nodules, carcinoma en cuirasse, alopecia neoplastica, carcinoma teleangiectaticum, inflammatory crease and zosteriform pattern [2, 3].

The skin metastases are treated locally or systemically [4, 5, 7, 8]. Surgical treatment together with hormone therapy, when ER/PR are positive, are acceptable as in this case. ER/PR- negative patients should be treated with systemic chemotherapy [7, 8].

The presence of skin metastases signifies widespread systemic disease and a poor prognosis for patients [3, 6]. Median overall survival in metastatic breast carcinoma is about 36 months [9]. In retrospective research by Hu *et al.*, mean survival time in breast cancer patients with only cutaneous metastases was 57.43 months [10].

Diseases that should be consider in the differential diagnosis of skin metastases include: branchial cleft cyst, cellulitis, dermatofibroma, herpes zoster and pyogenic granuloma.

## Conclusion

1. Cutaneous metastasis may derive from different carcinomas.
2. In the majority of cases, skin metastases are from malignant melanoma and breast carcinoma.
3. Most cutaneous metastases are observed on the chest and abdomen wall.
4. The skin metastases should be treated locally or systemically.

## References

1. Naser AMB, Zaki MS, Brunner M *et al.* Cutaneous metastasis in internal malignancy. *Egyptian Dermatol Online J.* 2007; 3: 1.
2. Rolz-Cruz G and Kim CC. Tumor invasion of the skin. *Dermatol Clin.* 2008; 26: 89–102.
3. Santos-Juanes J, Lopez-Escobar M, Palicio NV *et al.* Zosteriform cutaneous metastasis from a breast carcinoma. *Med Cutan Iber Lat Am.* 2007; 35: 89–93.
4. Krathen RA, Orengo IF, Rosen T. Cutaneous metastasis: a meta-analysis of data. *South Med J.* 2003; 96: 164–167.
5. Raingold IM. Cutaneous metastasis from internal carcinoma. *Cancer* 1966; 19: 162–168.
6. Schwartz RA. Cutaneous metastatic disease. *J Am Acad Dermatol.* 1995; 33: 161–182.
7. Snoj M, Cemazar M, Slekovec Kolar B, Sersa G. Effective treatment of multiple unresectable skin melanoma metastases by electrochemotherapy: case report. *Croat Med J.* 2007; 48: 345–349.
8. Gothelf A, Mir LM, Gehl J. Electrochemotherapy: results of cancer treatment using enhanced delivery of bleomycin by electroporation. *Cancer Treat Rev.* 2003; 29: 371–387.
9. Pal SK, Gupta R, Somlo G *et al.* Lack of survival benefit in metastatic breast cancer with new chemotherapeutic agents: The City of Hope experience. *J Clon Oncol.* 2008; 26 (15) [Abstract 17510].
10. Hu SC, Chen GS, Lu YW *et al.* Cutaneous metastases from different internal malignancies: a clinical and prognostic appraisal. *J European Academy of Dermatology and Venereology* 2008; 22: 735–740.

### Address for correspondence:

Konrad Wroński MD, PhD, MBA, General Surgery Consultant  
Department of Surgical Oncology, Faculty of Medicine  
University of Warmia and Mazury in Olsztyn, Poland  
Al. Wojska Polskiego 37, 10–228 Olsztyn, Poland  
e-mail: konradwronski@wp.pl