

‘Idiopathic’ acute myocardial infarction in a young patient with noncompaction cardiomyopathy

Tolga Sinan Güvenç¹, Hatice Betül Erer², Servet Altay²,
Erkan İlhan³, Nurten Sayar², Mehmet Eren²

¹Department of Cardiology, Kafkas University School of Medicine, Kars, Turkey

²Department of Cardiology, Siyami Ersek Thoracic and Cardiovascular Surgery Center,
Training and Research Hospital, Istanbul, Turkey

³Department of Cardiology, Van Erciş State Hospital, Van, Turkey

Abstract

Isolated left ventricular noncompaction (LVNC) is a rare hereditary cardiomyopathy characterized by prominent intraventricular trabeculations separated by deep intertrabecular recessus. While cardiac ischemia due to microvascular dysfunction is common in these patients, ST-segment elevation myocardial infarction (STEMI) is rare and usually seen as a consequence of coincidental coronary artery disease.

We report the case of a 20 year-old male patient admitted to our emergency department with a complaint of squeezing chest pain who was subsequently diagnosed with STEMI according to electrocardiographic findings, although an emergent coronary angiogram demonstrated normal coronary arteries. Echocardiography revealed isolated LVNC, and the diagnosis was confirmed via magnetic resonance imaging. Repeat coronary catheterization with acetylcholine infusion and coronary flow reserve measurement failed to demonstrate vasospasm or microvascular dysfunction. As no apparent cause was found, this case was designated ‘idiopathic’ myocardial infarction. Coronary thromboembolism due to stagnation of blood in the left ventricular cavity remained as the most probable mechanism underlying myocardial infarction. (Cardiol J 2012; 19, 4: 429–433)

Key words: noncompaction, myocardial infarction, coronary flow reserve

Introduction

Isolated left ventricular noncompaction (LVNC) is an unclassified cardiomyopathy characterized by persistence of fetal trabeculations in the LV [1, 2]. It is believed that a failure in the fetal ‘compaction’ process causes maintenance of hypertrabeculated segments in the apical and endocardial segments of the LV myocardium. The main clinical manifestations of this disorder are heart failure, arrhythmias and, to a lesser extent, systemic embolism [3].

While no abnormalities in the growth of epicardial coronary arteries could be demonstrated as yet, myocardial ischemia and associated chest pain could be present in patients with LVNC. Failure in cardiac microvasculature has been demonstrated as the causative mechanism of ischemia in some of these patients [4].

ST-segment elevation myocardial infarction (STEMI) is a rather unexpected complication in these patients and rarely reported in the literature. Mostly, this combination is a result of coexistent

Address for correspondence: Tolga Sinan Güvenç, MD, Kafkas University School of Medicine, Department of Cardiology, Kars, Turkey, tel: +904742251150-3021, fax: +904742251193, e-mail: TSGuvenç@gmail.com

Received: 17.04.2011

Accepted: 30.05.2011

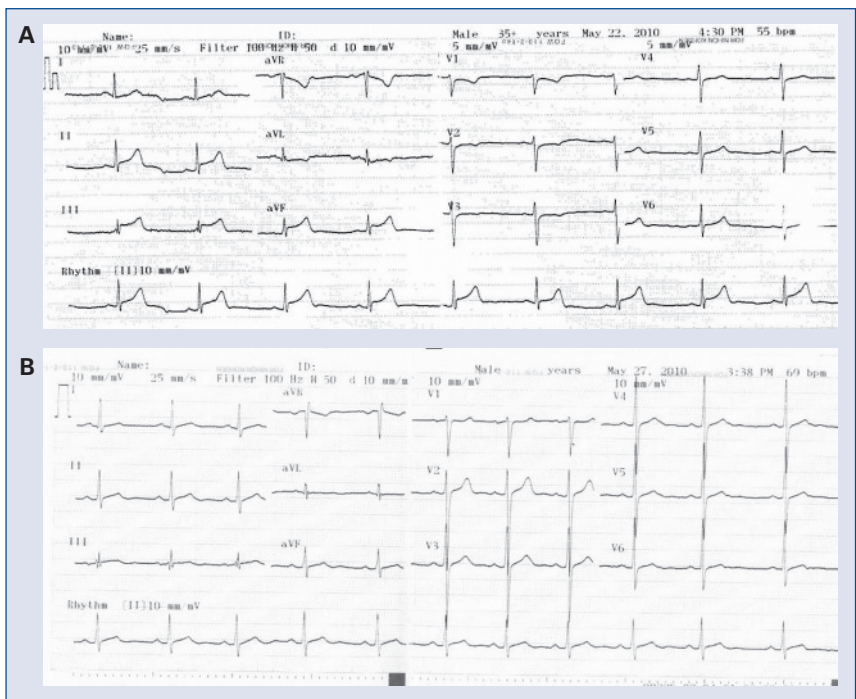

Figure 1. Electrocardiogram taken at admission (A) and immediately after the relief of pain (B). Note ST elevation in inferior leads, accompanied by ST depression in lead aVL.

LVNC and atherosclerotic coronary disease, rather than a direct causal relationship. In some instances, however, STEMI could be directly caused by thromboembolic material dislodged from the LV cavity [5] or by microvascular dysfunction [6].

In this report, a 20 year-old male patient with no apparent risk factors for ischemic heart disease was diagnosed as STEMI. Further evaluation revealed isolated LVNC. No apparent cause for ischemia was found, as he had normal coronary arteries without vasospastic tendency and normal coronary flow reserve (CFR) measurements. Thromboembolism with subsequent canalization was considered as the most likely mechanism.

Case report

A 20 year-old male patient was admitted to our emergency department with squeezing chest pain and diaphoresis that had begun half an hour before admission. His past medical and family history were unremarkable. He did not smoke cigarettes or use illicit drugs. On physical examination, his blood pressure was 125/75 mm Hg, heart rate was 80 bpm, and body temperature was 36.2°C. No notable findings were found during physical examination. Electrocardiogram demonstrated 1 mV ST segment eleva-

tion in leads DII, DIII and aVF, along with reciprocal ST segment depression in lead aVL (Fig. 1A). Cardiac biomarkers were significantly elevated, with a creatine kinase-MB level of 129 U/L and troponin I level of 13 ng/dL. Other laboratory tests, including leucocyte count, C-reactive protein and sedimentation rate, were normal. In the coronary care unit, his pain remitted with a subsequent normalization of electrocardiogram (Fig. 1B). As his findings were compatible with STEMI, he was taken to the catheterization laboratory for an emergent angiogram, after obtaining his consent. Coronary angiography revealed normal coronary arteries with normal ostial localization and course (Fig. 2A, B). Although he had normal coronary arteries, treatment with antiplatelet and beta-blocking agents was initiated and an echocardiogram was obtained to evaluate other causes of ischemia. Echocardiography demonstrated highly trabeculated areas separated by deep, blood-bathed recessus in the apicoinferior, apicolateral, mid-inferior and lateral walls of the LV, along with mild hypokinesia of the inferior wall (Fig. 3A). Other findings were unremarkable, including chamber dimensions and right ventricular function. In the trabeculated areas, the endocardial-to-epicardial myocardium ratio was 2.2. To further support the diagnosis, cardiac magnetic

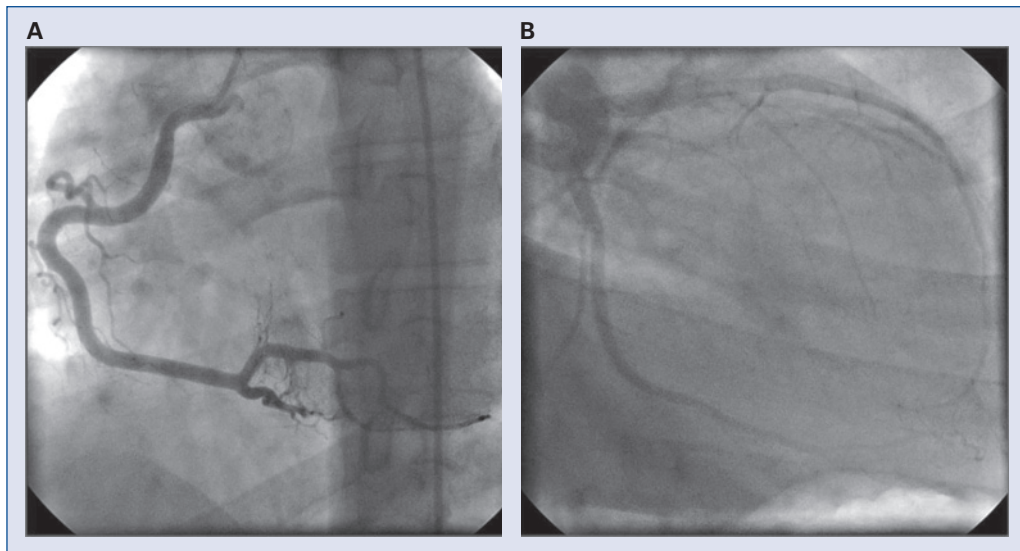


Figure 2. Emergency coronary angiogram depicting normal right (A) and left (B) coronary arteries.

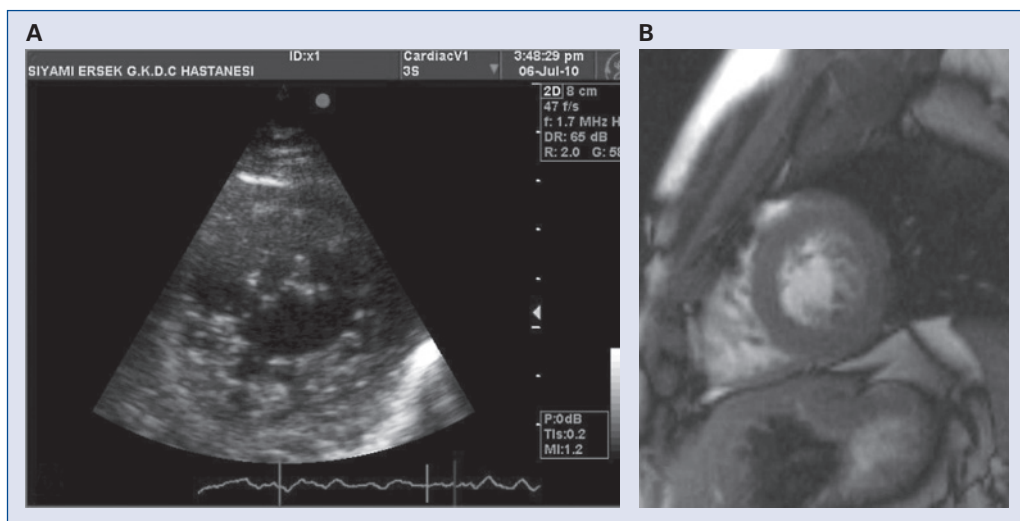


Figure 3. Echocardiogram (A) and cardiac magnetic resonance imaging (B) depicting noncompacted areas in lateral and inferior walls of left ventricle.

resonance imaging (MRI) was obtained, which revealed similar findings (Fig. 3B).

Ten days after the initial admission, the patient was free of symptoms, and after obtaining his consent, noninvasive and invasive tests were performed to understand the nature of ischemia and STEMI. A sub-maximal exercise electrocardiography examination performed to evaluate residual ischemia and microvascular dysfunction did not demonstrate any abnormal findings. A repeat coronary catheterization was performed for CFR measurement and vasospasm provocation. CFR measurement was performed with adenosine (42 μ g and

54 μ g for right and left coronary arteries, respectively) and the ratio of flow at peak hyperemia to baseline flow was 5.6 for the right coronary artery (Fig. 4A) and 3.8 for the left coronary artery. Vasospasm provocation was performed with incremental doses of acetylcholine up to 50 μ g to each coronary artery. No response could be elucidated in either coronary artery (Fig. 4B). Before hospital discharge, a repeat echocardiogram was obtained and segments that were previously hypokinetic were found to be normally contracting this time. While no cause for STEMI was found, aspirin and metoprolol therapy was continued, and the patient

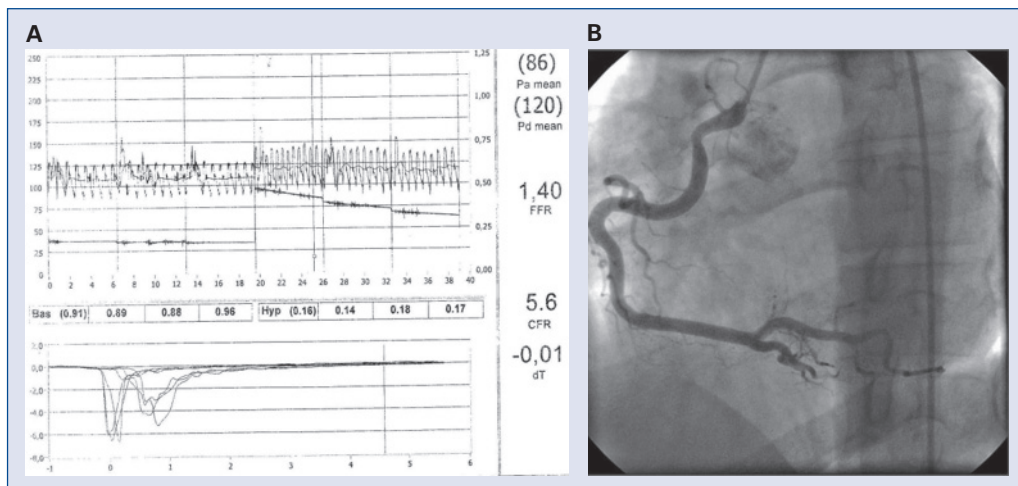


Figure 4. A. Coronary flow reserve measurement in right coronary artery. Coronary flow reserve was found to be 5.6 after induction of maximal hyperemia with adenosine; **B.** Angiogram of right coronary artery after vasospasm provocation with acetylcholine. Right coronary artery demonstrated here, as it was considered the culprit artery for acute myocardial infarction.

was discharged from hospital on the twelfth day after admission.

Discussion

Isolated LVNC is a distinct cardiomyopathy assumed to be caused by an embryonic failure of the myocardial compaction process, which results in prominent trabeculations separated by deep intracavitary recessus in the affected areas [7, 8]. The main clinical features of LVNC include heart failure due to systolic LV dysfunction, arrhythmias of ventricular and supraventricular origin, and arterial thromboembolic events. Heart failure and related symptoms are present in most patients, while arterial embolism is rare, especially when other associated risk factors are absent [7, 9]. It is also possible to incidentally diagnose this condition in patients referred to echocardiography laboratory, with no symptoms that could be attributable to LVNC [10]. The primary diagnostic tool is transthoracic echocardiography, while cardiac MRI is emerging as a valuable tool both for ascertaining diagnosis and quantifying the amount of noncompacted myocardium. The echocardiographic criteria suggested by Jenni et al. [9] and Stöllberger et al. [11] for LVNC include at least three prominent trabeculations separated by deep recessus that are in contact with the LV cavity, clearly differentiable noncompacted and compacted segments in apex, inferior and lateral walls, with a endocardial-to-epicardial myocardium ratio of at least 2 which is measured at the end-systole, and the absence of

other cardiac abnormalities. A ratio of 2.3 is considered to be a cut-off point for cardiac MRI [12]. The first manifestation in our patient was myocardial infarction, and the diagnosis was reached using the aforementioned echocardiographic criteria and verified by MRI during in-hospital evaluation.

Cardiac ischemia is a known feature of LVNC and considered to be a consequence of microvascular dysfunction. Jenni et al. [4] have shown that LVNC patients exhibit decreased coronary flow reserve in both compacted and noncompacted segments. Subendocardial perfusion defects have been demonstrated in a patient with LVNC and normal coronary arteries [13]. Pediatric patients with LVNC have been reported to experience in utero transmural MI, presumably caused by microvascular dysfunction [6].

In adult patients with LVNC, ischemic symptoms could be present even if coronary arteries are angiographically normal [14]. However, in the few adult patients with reported STEMI and LVNC, ischemia is mainly related to underlying coronary artery disease and seems irrelevant to LVNC [15]. In our patient, angiographic coronary artery disease was not present despite ECG and biochemical manifestations suggestive of STEMI. Besides, other causes of STEMI, such as abnormal coronary take-off or vasospastic angina, were not present. Indeed, CFR measurements were normal, thus ruling out microvascular dysfunction as the cause of ischemia and STEMI.

Our case suggests that STEMI without any obvious cause could be experienced by LVNC pa-

tients, even young adults. Coronary thromboembolism due to thrombotic material dislodgement from the LV cavity suggests a possible mechanism. It is well known that LVNC patients are prone to arterial thromboembolism [3]. Everett et al. [5] reported a patient with LVNC, LV apical thrombus and simultaneous thrombotic occlusion of the left anterior descending artery, thereby suggesting a possible dislodgement as an etiologic factor. While we are unable to observe intracavitary thrombus, a dislodged thrombus with subsequent recanalization is the most likely mechanism in our patient. *De novo* thrombosis is highly unlikely, as angiography did not suggest underlying atherosclerotic vascular disease, although an intravascular ultrasound examination is needed to completely rule out this possibility.

In conclusion, we report myocardial infarction in a young LVNC patient without any identifiable cause, although thromboembolism remains as the highest possibility. Currently, anticoagulants are particularly advised for LVNC patients with risk factors for thromboembolism. However, we advise careful consideration for thrombosis prevention even in asymptomatic young subjects, as unexpected manifestations of acute arterial occlusion with a possible thromboembolic mechanism may occur.

Conflict of interest: none declared

References

- Jenni R, Oechslin E, Schneider J, Attenhofer Jost C, Kaufmann PA. Echocardiographic and pathoanatomical characteristics of isolated left ventricular non-compaction: A step towards classification as a distinct cardiomyopathy. *Heart*, 2001; 86: 666–671.
- Yousef ZR, Foley PW, Khadjooi K. Left ventricular non-compaction: Clinical features and cardiovascular magnetic resonance imaging. *BMC Cardiovasc Disord*, 2009; 9: 37.
- Endberding R, Stöllberger C, Ong P, Yelbuz TM, Gerecke BJ, Breithardt G. Isolated non-compaction cardiomyopathy. *Dtsch Arztebl Int*, 2010; 107: 206–213.
- Jenni R, Wyss CA, Oechslin EN, Kaufmann PA. Isolated ventricular noncompaction is associated with coronary microcirculatory dysfunction. *J Am Coll Cardiol*, 2002; 39: 450–454.
- Everett ME, Kirkpatrick JN, Lang RM. Noncompaction of the myocardium complicated by coronary artery embolism. *J Am Soc Echocardiogr*, 2005; 18: 194–196.
- Whitham JK, Hasan BS, Schamberger MS, Johnson TR. Use of cardiac magnetic resonance imaging to determine myocardial viability in an infant with in utero septal myocardial infarction and ventricular noncompaction. *Pediatr Cardiol*, 2008; 29: 950–953.
- Engberding R, Yelbuz TM, Breithardt G. Isolated noncompaction of the left ventricular myocardium: A review of the literature two decades after the initial case description. *Clin Res Cardiol*, 2007; 96: 481–488.
- Freedom RM, Yoo SJ, Perrin D, Taylor G, Petersen S, Anderson RH. The morphological spectrum of ventricular noncompaction. *Cardiol Young*, 2005; 15: 345–364.
- Jenni R, Oechslin EN, van der Loo B. Isolated ventricular non-compaction of the myocardium in adults. *Heart*, 2007; 93: 11–15.
- Nagavalli S, Vacek JL. Approach to incidentally diagnosed isolated ventricular noncompaction of myocardium. *South Med J*, 2010; 103: 662–668.
- Stollberger C, Finsterer J, Blazek G. Left ventricular hypertrabeculation/noncompaction and association with additional cardiac abnormalities and neuromuscular disorders. *Am J Cardiol*, 2002; 90: 899–902.
- Petersen SE, Selvanayagam JB, Wiesmann F. Left ventricular non-compaction: Insights from cardiovascular magnetic resonance imaging. *J Am Coll Cardiol*, 2005; 46: 101–105.
- Soler R, Rodriguez E, Monserrat L, Alvarez N. MRI of subendocardial perfusion deficits in isolated left ventricular noncompaction. *J Comput Assist Tomogr*, 2002; 26: 373–375.
- Namazi, MH, Eslami V, Norouzi S. Isolated noncompaction of left ventricular myocardium with an unusual presentation of angina pectoris. *Rev Cardiovasc Med*, 2009; 10: 232–235.
- Correia E, Santos LF, Rodrigues B, Gama P, Cabral C, Santos O. Noncompaction of the myocardium in a patient with acute myocardial infarction. *Arq Bras Cardiol*, 2010; 94: e62–e64, e125–e127.