

# ST segment elevation following sinoventricular rhythm in a patient with diabetic ketoacidosis

Ersan Tatli, Armagan Altun and Mustafa Yilmaztepe

Department of Cardiology, Trakya University School of Medicine, Edirne, Turkey

## Abstract

*Diabetic ketoacidosis is a major cause of morbidity and mortality in patients with insulin dependent diabetes. Myocardial infarction is an uncommon but well-recognised precipitating cause of diabetic ketoacidosis, accounting for 1% of cases. Many diabetic patients with ketoacidosis initially present with hyperkalemia, which may affect the electrocardiographic morphology. We present a patient with diabetic ketoacidosis and hyperkalemia, whose initial electrocardiogram showed a sinoventricular rhythm and subsequently pseudoinfarction pattern. (Cardiol J 2007; 14: 497–499)*

**Key words: diabetic ketoacidosis, hyperkalemia, sinoventricular rhythm, pseudoinfarction pattern**

## Introduction

Around 2–8% of all hospital admissions of diabetic patients are for ketoacidosis. Plasma potassium concentrations at presentation are usually normal or high. Potassium concentrations above 6.0 mmol/L have been reported in 20–30% cases at presentation [1, 2]. Hyperkalemia has a profound effect on myocardial conduction and repolarisation and hence on the surface electrocardiogram. We present a patient with diabetic ketoacidosis and hyperkalemia, whose initial electrocardiogram showed a sinoventricular rhythm and subsequently pseudoinfarction pattern.

## Clinical case

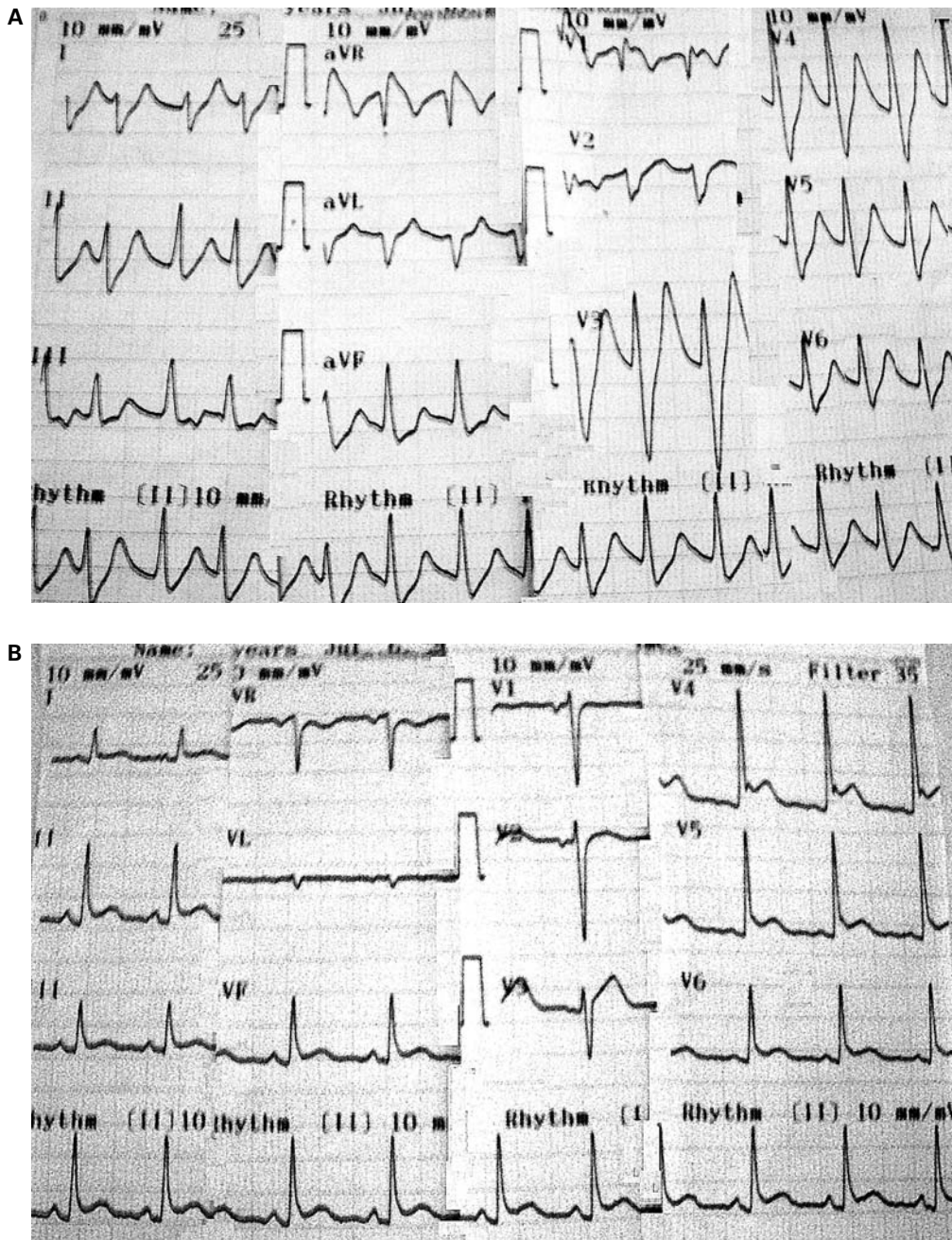
A 20-year-old man with a history of type 1 diabetes mellitus presented to the emergency depart-

ment with nausea, vomiting and epigastric pain of 4 hours duration. Diabetic ketoacidosis was diagnosed based on a glucose level of 740 mg/dL, pH of 7.1 and a positive urine dipstick for ketones. Serum potassium measured 7.7 mmol/L. Initial electrocardiography revealed sinoventricular rhythm and tall, peaked T waves (Fig. 1A). Six hours after the patient received intravenous fluid, calcium gluconate, bicarbonate and insulin, ST segment elevation in leads D2, D3, AVF and V4–V6 was seen in the electrocardiography (Fig. 1B). Serum potassium then measured 4.7 mmol/L. Coronary angiography was carried out. His coronary arteries and ventriculography were seen as a normal. When the electrocardiogram was repeated several hours later, the ST-segment elevation disappeared completely, but T wave inversion was seen in leads V4–V6 (Fig. 2). Creatine kinase, creatine kinase-MB and troponin I values were normal. At the time of discharge, the patient was in good condition with normal electrocardiography.

## Discussion

Hyperkalemia can cause several characteristic electrocardiographic abnormalities that are often progressive. Initially, the T wave becomes tall,

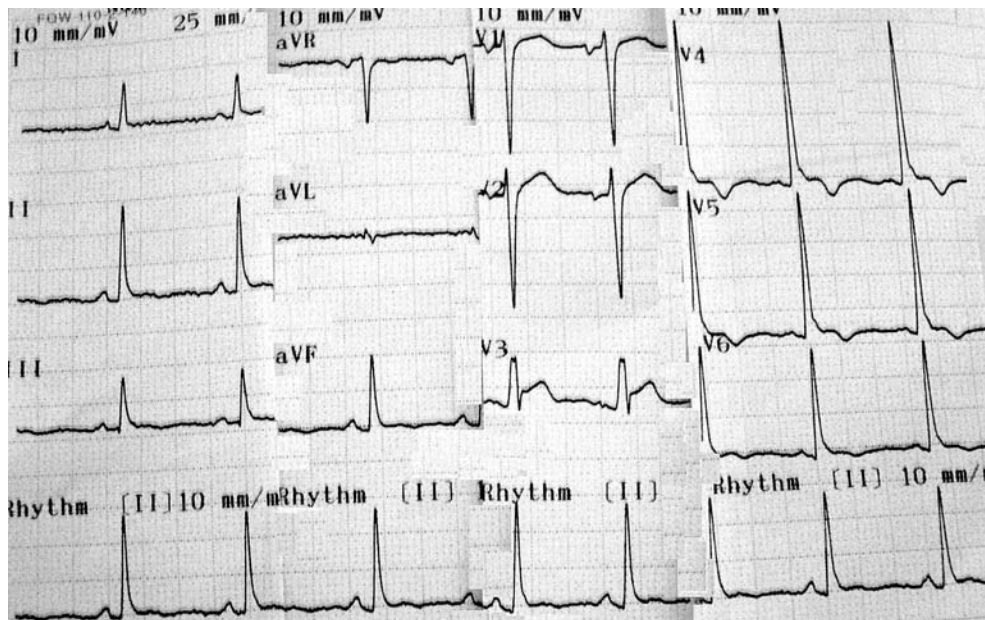
Address for correspondence: Ersan Tatli, MD  
Department of Cardiology  
Trakya University School of Medicine, Edirne, Turkey  
Tel: 902842357641/2150; Mobile: 905056789099  
Fax: 902842357652; e-mail: ersantatli@yahoo.com  
Received: 18.03.2007 Accepted: 27.07.2007



**Figure 1.** A. Electrocardiography at presentation, sinoventricular rhythm and tall, peaked T waves; B. Electrocardiography 6 hours after presentation and pseudoinfarction pattern in leads D2, D3, AVF and V4–V6.

symmetrically peaked and tented. The P wave progressively diminishes in amplitude and eventually disappears when serum potassium concentrations are above 7.5 mmol/L. This may lead to a sinoventricular rhythm. Intraventricular conduction defect is manifested as a widening of the QRS, which often resembles a right bundle branch block with either a left anterior or a left posterior hemiblock [3]. Intraventricular conduction delay is well recognised

in hyperkalemia, but ST segment elevation or pseudoinfarction has been infrequently reported in diabetic ketoacidosis [4–7]. It is debatable whether the ST elevation is a primary repolarisation abnormality or an artefact caused by merging of the terminal R' portion of the QRS with the T wave. It is also unclear whether the changes are due to acidosis or other metabolic abnormalities specific to diabetic ketoacidosis [7].



**Figure 2.** Electrocardiography 14 hours after presentation and T wave inversion in leads V4–V6.

This case shows that hyperkalemia can simulate myocardial infarction and alter the electrocardiographic appearance. Myocardial infarction is a well-known precipitating factor of diabetic ketoacidosis. Thrombolysis is important for reducing morbidity and mortality resulting from coronary artery disease; however, it should be remembered that metabolic abnormalities can sometimes alter the electrocardiographic appearance.

### References

1. Chiasson JL, Aris-Jilwan N, Belanger R et al. Diagnosis and treatment of diabetic ketoacidosis and the hyperglycemic hyperosmolar state. *CMAJ*, 2003; 168: 859–866.
2. Delaney MF, Zisman A, Kettle WM. Diabetic ketoacidosis and hyperglycemic hyperosmolar nonketotic syndrome. *Endocrinol Metab Clin N Am*, 2000; 29: 683–705.
3. Schamroth L. An introduction to electrocardiography. 7<sup>th</sup> ed. Oxford University Press, Oxford 1990.
4. Lim YH, Anantharaman V. Pseudo myocardial infarct-electrocardiographic pattern in a patient with diabetic ketoacidosis. *Singapore Med J*, 1998; 39: 504–506.
5. Sweterlitsch EM, Murphy GW. Acute electrocardiographic pseudoinfarction pattern in the setting of diabetic ketoacidosis and severe hyperkalemia. *Am Heart J*, 1996; 132: 1086–1089.
6. Cohen A, Utarnachitt RV. Electrocardiographic changes in patients with hyperkalemia and diabetic acidosis associated with acute anteroseptal pseudomyocardial infarction and bifascicular block. *Angiology*, 1981; 32: 361–364.
7. Moulik PK, Nethaji C, Khaleeli AA. Lesson of the week: Misleading electrocardiographic results in patients with hyperkalemia and diabetic ketoacidosis. *BMJ*, 2002; 325: 1346–1347.