

Percutaneous reconstruction of the continuity of a functionally interrupted aortic arch using a stent

Jacek Kusa, Małgorzata Szkutnik and Jacek Białkowski

Division of Congenital Heart Disease and Pediatric Cardiology,
Silesian Centre for Heart Disease, Zabrze, Poland

Abstract

A case of a 26-year-old man without continuity of blood flow in the level of the isthmus of the aorta is described. During interventional catheterization, we reconstructed this continuity and implanted a vascular stent. (Cardiol J 2008; 15: 80–84)

Key words: aortic coarctation, stent

Introduction

Coarctation of the aorta (CoA) is a common congenital cardiovascular defect [1]. It is usually diagnosed in children but occasionally in adults. The latter patients are usually asymptomatic, and the diagnosis of CoA is made during an attempt to identify the cause of high blood pressure. Untreated CoA most commonly leads to death by the fifth decade of life [2, 3]. Early symptoms include intermittent claudication, headaches, vomiting, nausea and dizziness. Less common clinical manifestations have also been reported, including congestive heart failure, infectious endocarditis involving aortic intima, true ascending or descending aortic aneurysm, aortic dissection and cerebrovascular events [3, 4]. Surgical treatment of CoA was described for the first time in 1945, with a number of methods of surgical repair of the aorta introduced since that time. In 1979 a postmortem study showed the feasibility of balloon angioplasty of lesions, and the first percutaneous balloon angioplasty of CoA in an infant with heart failure was performed in 1982. Soon this procedure was also introduced in adult patients. Due

to suboptimal results caused by vessel hypoplasia, elastic recoil or restenosis, modifications of balloon angioplasty were sought to solve these problems. In 1993 the first stent implantation into the aortic isthmus was performed in clinical practice by Soares de Lezo (followed by the publication of these results in 1995) [2, 5, 6], and since that time this method has become widely used in all age groups [4, 7–10].

In this report, we present a patient with critical CoA, also known as functionally [11] or physiologically interrupted aortic arch, with coexisting atrial septal defect who was treated with percutaneous stent implantation into the aortic isthmus.

Case report

A 26-year-old man, a foreigner, was presented to our centre for percutaneous treatment of CoA. The defect was diagnosed in childhood, but the parents of the patient did not consent to the suggested surgical treatment. The patient grew and developed normally during childhood, but he required treatment for his hypertension. For six years blood pressure was well controlled using two antihypertensive drugs. In addition, intermittent claudication developed, leading to progressively more severe symptoms.

On admission, the patient was in a good general clinical condition. No pulses within the lower limbs were noted during the physical examination, and heart auscultation revealed fixed splitting of the second heart sound and late systolic murmur in the

Address for correspondence: Dr n. med. Jacek Kusa
Clinic of Congenital Heart Disease and Pediatric Cardiology
Silesian Centre for Heart Disease, Zabrze
Szpitalna 2, 41–800 Zabrze, Poland
Tel./fax: +48 32 271 34 01; e-mail: jkusa@poczta.onet.pl
Received: 23.05.2007 Accepted: 21.11.2007

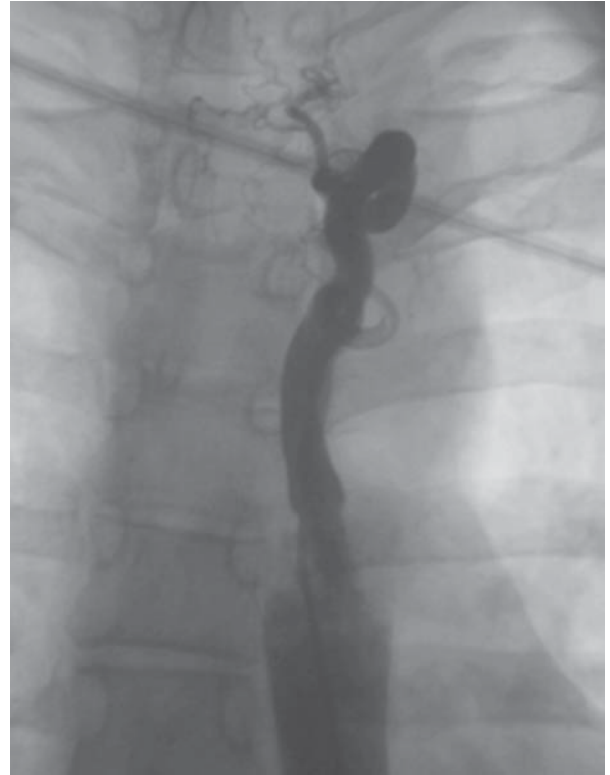
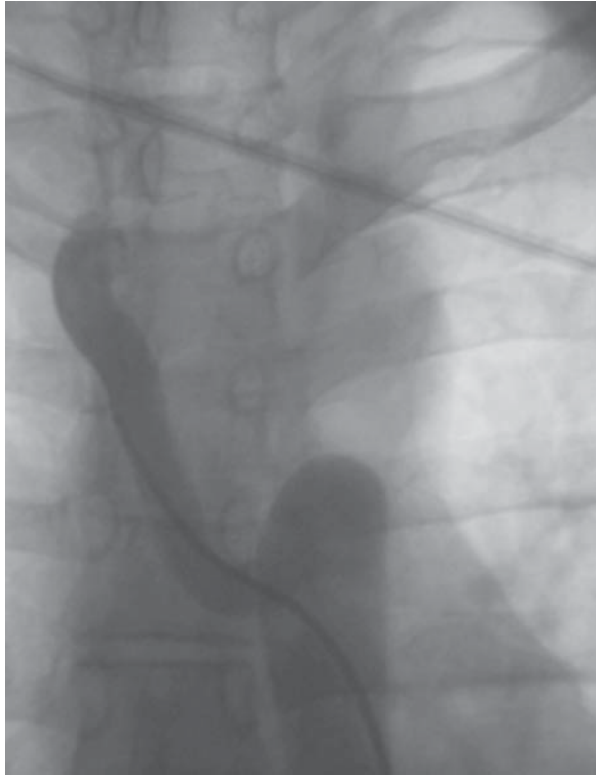
Figure 1. Collateral vessels.

left interscapular area and in the 2nd–3rd left intercostal space. Blood pressure on the upper limbs was 155/95 mm Hg. Chest radiography showed normal cardiac silhouette, abnormal contour of the aorta and rib notching. Echocardiography revealed morphologically severe stenosis of the aortic isthmus with a pressure gradient that was difficult to measure, and slow flow in the abdominal aorta. Cardiac chamber dimensions were normal for body mass, and the thickness of left ventricular myocardium was increased by 22%. In addition, bileaflet aortic valve and an atrial septal defect with a diameter of 12 mm and a left-to-right shunt were found. The patient was scheduled for an attempt at percutaneous dilatation of CoA. Simultaneous closure of the atrial septal defect was also contemplated but the patient did not agree to the latter due to financial reasons.

Cardiac catheterization was performed following intravenous sedation using midazolam and morphine, under antibiotic coverage (cephazolin), by percutaneous femoral artery approach using 6 F sheath. A multipurpose catheter was introduced into the descending aorta, and multiple attempts to cross the coarctation were made using various guidewires (Teflon, hydrophilic and coronary), but the catheter only entered numerous wide collateral vessels (Fig. 1).

The multipurpose catheter was replaced with a 6 F pigtail catheter used for aortography below the aortic isthmus but no uncontrasted blood flow to the descending arm of the aortic arch was seen (Fig. 2). The aortic diameter at the level of the diaphragm was 21 mm. Interruption of the aortic arch was then suspected and a 6 F multipurpose catheter was introduced through the right femoral vein (via a 6 F sheath) to the left atrium, left ventricle and the ascending aorta. Using a 260 cm-long 0.035-inch guidewire, the multipurpose catheter was replaced with a pigtail catheter used for aortography of the ascending aorta. Again, no flow through the entire length of the aorta could be seen (Fig. 3), and the descending aorta was visualized after a delay necessary for the inflow of contrasted blood through collateral vessels. Anatomic continuity of aortic walls was found, with the vessel lumen not seen (atresia? septating membrane?) at a length of only 1 mm (14 mm below the origin of the left subclavian artery) and a clearly visible cone of blind-ended proximal aorta. During multiple attempts to cross the presumed CoA, a 0.035-inch hydrophilic Terumo guidewire entered the descending aorta (perforation of an aortic septating membrane? crossing narrow minimal CoA lumen that was not seen in

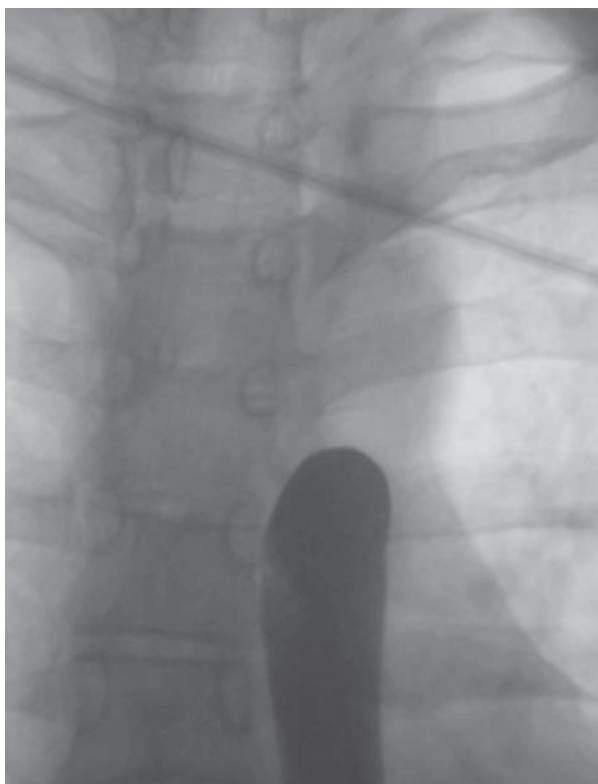


Figure 2. Aortography below the isthmus does not reveal 'negative' contrast.

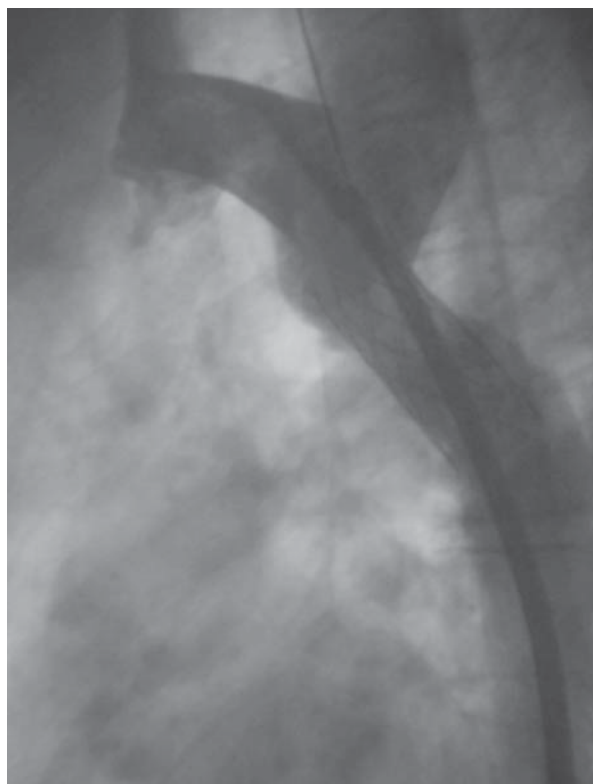

Figure 4. Aortography after stent implantation.

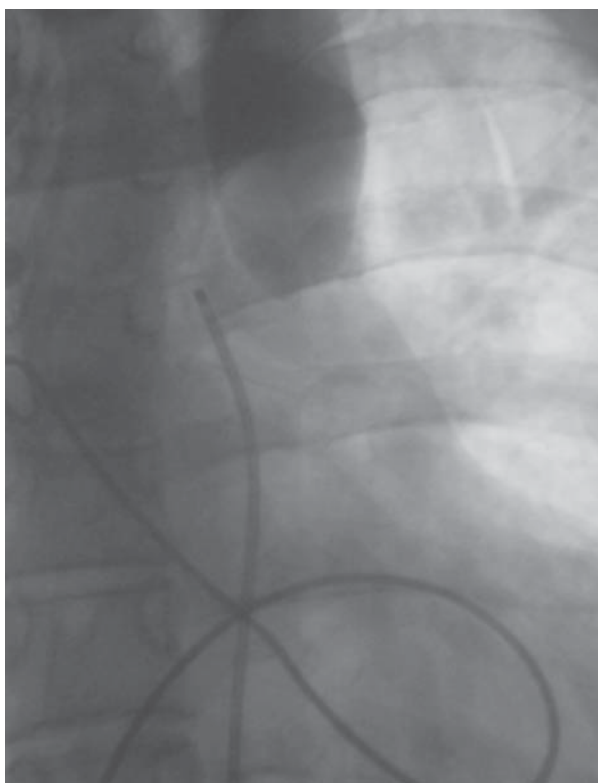


Figure 3. Aortography reveals stopped blood flow in the isthmus of the aorta.

aortography?). Using this guidewire, a multipurpose catheter was introduced into the descending aorta and the guidewire was replaced with a 260 cm-long 0.035-inch Teflon guidewire, with the tip of the latter left in the abdominal aorta. The pressure gradient between the ascending and descending aorta was estimated at 61 mm Hg. Subsequently, a Microvena snare catheter advanced through the femoral artery sheath was used to catch and exteriorize the guidewire tip. Using this arteriovenous loop, and after replacing the femoral artery sheath with a long 12 F Mullins sheath, a 16 mm × 4 cm Maxi balloon with mounted P 4014 stent (Johnson & Johnson) was introduced into CoA. The stent was expanded just below the origin of the left subclavian artery, resulting in dilatation of the stenosed aortic segment to 16 mm (Fig. 4). Following the procedure, the pressure gradient decreased to zero. Follow-up aortography showed a minimal aneurysm and incomplete apposition of the stent to the aortic walls above and below the site of previous stenosis. A follow-up catheterization with a view to repeated stent dilatation was scheduled for six months later. The patient presented for the follow-up evaluation 18 months later. During that time he had no symptoms, and antihypertensive drugs were initially

used in reduced doses and later completely withdrawn. Blood pressure was 120/80 to 135/85 mm Hg. Physical examination showed normal pulses in the lower limbs, and echocardiography revealed normal flow in the abdominal aorta with a minimal diastolic plateau. Pressure gradient at the aortic isthmus was estimated at 20 mm Hg. The atrial septal defect size decreased from 12 to 7 mm. The patient did not give consent for stent dilatation.

Discussion

Coarctation of the aorta may be treated surgically or percutaneously. The choice of the therapeutic option should be based on patient preference. This patient presented to our centre for percutaneous treatment.

Diagnostic evaluation revealed an extreme form of CoA that occurs very rarely in this age group and is the functional equivalent of an interrupted aortic arch. Nevertheless, we decided to rise to the challenge and attempt percutaneous restoration of the aortic lumen [12] using a transvenous approach to the ascending aorta (through the atrial septal defect).

Having the choice between balloon angioplasty and percutaneous stent implantation, we decided to perform the latter. Conventional indications for stenting include unfavourable anatomy for balloon angioplasty, such as tubular coarctation, hypoplasia of the isthmus, long stenosed aortic segment [2, 8] and the lack of the effect of balloon angioplasty or restenosis following angioplasty. However, stents are now used more commonly and in some centres they have become a first line treatment in all adult patients, and in some centres stents are used as a palliative treatment even in small children [5]. Literature review suggests that the advantages of stents compared to balloon angioplasty include significantly lower residual pressure gradient and lower rates of restenosis and direct aortic wall damage [5, 10]. According to Suarez de Lezo et al. [5], even a long time after balloon angioplasty there is a 10 to 15 percent risk of the development of an aneurysm. Data are inconsistent in regard to the rate of aneurysm development following both types of percutaneous treatment: some authors suggest that this occurs at a similar rate following both stenting and balloon angioplasty, estimated at 6–7%, but other investigators reported more frequent aneurysm development following balloon angioplasty [5, 6, 13]. Aneurysms develop due to damage of the aortic media, and overestimation of the diameter of the bal-

loon used for angioplasty is suggested as a contributing cause [6]. In some cases, stents may protect against such complications, so the rate of aneurysm development might be lower following stenting [13]. Appropriate sizing of the balloon is very important. The balloon diameter should be 1–2 mm smaller than the diameter of the aortic isthmus (most commonly at the level of the origin of the left subclavian artery), and it should not be larger than the diameter of the aorta at the level of the diaphragm [6, 14]. If an aneurysm develops, it might be occluded percutaneously using coils or a covered stent [7, 9, 15]. Stent implantation may also result in other complications including stent fracture or migration, thromboembolic events or aortic rupture [7, 8]. The risk of the latter may be reduced by the use of an appropriately sized balloon, but on the other hand, the use of a smaller balloon to expand the stent may be responsible for incomplete apposition of the stent to the aortic wall below the treated segment [10], as was the case in our patient. However, if the stenosis is very severe, a two-stage approach is advocated, with repeated procedure at approximately six months. During this time, a scar forms in the area of previous angioplasty, and then stent redilatation is performed using balloons to shape appropriately the stent as dictated by the vessel morphology. Another decision is the choice between balloon predilatation and primary stenting. Most of the available data from the literature suggest that primary stenting reduces the risk of aortic wall damage and this approach is used in most centres [2, 7, 8]. In our experience, balloon predilatation is helpful in cases of restenosis following surgical treatment as this approach allows assessment of the aortic wall susceptibility to expansion, an important issue with hard, incompressible lesions. With this information, we can avoid implanting a stent that could not be successfully dilated later.

Our patient had critically narrow CoA. Due to the risk of aortic rupture, we considered implantation of a covered stent. However, this is associated with a risk of obstructing blood flow to intercostal arteries supplying the spinal cord [9, 16, 17], so we decided to implant a regular uncovered stent, having a covered stent at our disposal in case of any adverse effects of stenting. During subsequent follow-up, the patient's blood pressure lowered, although dilatation of the stenosed aortic isthmus, either surgical or percutaneous, does not always lead to blood pressure normalization due to persisting receptor dysregulation [6]. In fact, this effect is less often seen in patients above 4–6 years of age. Available data suggest that blood pressure normalization

following dilatation of CoA occurs in 50–79% of patients [6].

Unfortunately, even successful lowering of the pressure gradient does not fully protect the patient from increased cardiovascular morbidity during adult life, although this risk is significantly lower. Potential sequelae include hypertension, aneurysm development, premature coronary artery disease, inflammation of the intima and formation of a fistula [4]. As a result, such patients require subsequent periodic cardiovascular evaluation.

Percutaneous intervention performed in our patient resulted in a significant reduction of the shunt through the abnormal communication at the level of the interatrial septum, driven by reduced left ventricular pressures, and possibly also reduced left atrial pressures (due to increased diastolic ventricular compliance). As the diameter of the atrial septal defect decreased by 40%, it did not require closure any longer.

Conclusions

Percutaneous treatment of CoA is feasible even in patients with functionally interrupted aortic arches or extremely severe forms of CoA. For such procedures to be performed, all necessary equipment including covered stents must be available in the cardiac catheterization laboratory. In addition, immediate access to cardiac surgery is required in case surgical treatment should become necessary.

Acknowledgements

The authors appreciate help of dr Piotr Jędrusik with preparation of the authorized English version of the manuscript.

Patient provided written consent for performing procedure consisting of stent placement.

The authors do not report any conflict of interest regarding this work.

References

1. Rocchini AP. Coarctation of the aorta and interrupted aortic arch. In: Moller JH, Hoffman JIE ed. Pediatric cardiovascular medicine. Churchill Livingstone, New York 2000: 567–593.
2. Zabal C, Attie F, Rosas M, Buendia-Hernandez A, Garcia-Montes JA. The adult patient with native coarctation of the aorta: balloon angioplasty or primary stenting? *Heart*, 2003; 89: 77–83.
3. Ramnarine I. Role of surgery in the management of the adult patient with coarctation of the aorta. *Postgrad Med J*, 2005; 81: 243–247.
4. Oliver JM, Gallego P, Gonzalez A, Arorca A, Bret M, Mesa JM. Risk factors for aortic complications in adults with coarctation of the aorta. *J Am Coll Cardiol*, 2004; 44: 1641–1647.
5. Suarez de Lezo J, Pan M, Romero M et al. Percutaneous interventions on severe coarctation of the aorta: a 21-year experience. *Pediatr Cardiol*, 2005; 26: 176–189.
6. Fawzy ME, Awad M, Hassan W, Al Kadhi Y, Shoukri M, Fadley F. Long-term outcome (up to 15 years) of balloon angioplasty of discrete native coarctation of the aorta in adolescents and adults. *J Am Coll Cardiol*, 2004; 43: 1062–1067.
7. Chessa M, Carrozza M, Butera G et al. Results and mid-long-term follow-up of stent implantation for native and recurrent coarctation of the aorta. *Eur Heart J*, 2005; 26: 2728–2732.
8. Thanopoulos BD, Hadjinikolaou L, Konstadopoulou GN, Tsaousis GS, Triposkiadis F, Spirou P. Stent treatment for coarctation of the aorta: intermediate term follow up and technical consideration. *Heart*, 2000; 84: 65–70.
9. Kusa J, Bialkowski J, Szkutnik M. Percutaneous implantation of stent in 52-year old man with severe coarctation of the aorta and congestive heart failure. *Folia Cardiol*, 2003; 10: 225–229.
10. Harrison DA, McLaughlin PR, Lazzam C, Connelly M, Benson LN. Endovascular stents in the management of coarctation of the aorta in the adolescent and adult: One-year follow-up. *Heart*, 2001; 85: 561–566.
11. Ewert P, Schubert S, Peters B, Abdul-Khaliq H, Nagdyman N, Lange PE. The CP stent-short, long, covered-for treatment of aortic coarctation, stenosis of pulmonary arteries and caval veins, and Fontan anastomosis in children and adults: An evaluation of 60 stents in 53 patients. *Heart*, 2005; 91: 948–953.
12. Joseph G, Mandalay A, Rajendiran G. Percutaneous recanalization and balloon angioplasty of congenital isolated local atresia of the aortic isthmus in adults. *Catheter Cardiovasc Inter*, 2001; 53: 535–541.
13. Pedra CA, Fontes VF, Esteves CA et al. Stenting vs. balloon angioplasty for discrete unoperated coarctation of the aorta in adolescents and adults. *Catheter Cardiovasc Inter*, 2005; 64: 495–506.
14. Ovaert C, McCrindle BW, Nykanen D, McDonald C, Freedom RM, Benson LN. Balloon angioplasty of native coarctation: clinical outcomes and predictors of success. *J Am Coll Cardiol*, 2000; 35: 988–996.
15. Cheatham JP. Stenting of coarctation of the aorta. *Catheter Cardiovasc Inter*, 2001; 54: 112–125.
16. Duke C, Qureshi SA. Aortic coarctation and recoarctation: To stent or not to stent? *J Interv Cardiol*, 2001; 14: 283–298.
17. Connolly JE. Hume memorial lecture. Prevention of spinal cord complication in aortic surgery. *Am J Surg*, 1998; 176: 92–101.