

Non-invasive imaging techniques in patients with coronary chronic total occlusions: A key for successful diagnosis, revascularization, and post-intervention outcomes

Marta Mielniczuk[✉], Paweł Krzesiński, Beata Uziębło-Życzkowska, Jarosław Kowal, Małgorzata Kurpaska, Grzegorz Gielerak

Department of Cardiology and Internal Diseases, Military Institute of Medicine — National Research Institute, Warsaw, Poland

Abstract

Coronary chronic total occlusions (CTOs) are a common finding on coronary angiograms of patients with coronary artery disease, with an incidence ranging from 15% to 25%. Despite this high incidence, the proper treatment strategy in those patients often remains unclear. There are some observational studies suggesting that successful revascularization of a CTO can reduce angina symptoms, improve quality of life, improve the left ventricular ejection fraction, and lower mortality. However, not all patients will benefit from revascularization. Pre-procedural assessment of left ventricular function, ischemic burden, and viability seems to be crucial for a good outcome of the revascularization. The aim of this review is to compare currently available non-invasive imaging modalities with regard to utility in evaluation of patients with CTOs. (Cardiol J 2023; 30, 6: 1038–1048)

Key words: coronary artery disease, coronary chronic total occlusions, angiography, echocardiography, single-photon emission computed tomography, positron emission tomography, cardiac magnetic resonance, computed tomography

Introduction

Coronary chronic total occlusions (CTOs) are a common finding on coronary angiograms of patients with coronary artery disease (CAD), with an incidence ranging from 15% to 25% [1]. Data from observational studies suggest that successful revascularization of a CTO can reduce angina symptoms, improve quality of life, improve the left ventricular (LV) ejection fraction, and lower mortality [2, 3]. However, percutaneous coronary intervention (PCI) of a CTO is a challenging procedure with a higher complication rate, and greater radiation exposure and iodine-containing contrast exposure than PCIs performed for other lesions.

Moreover, not all patients will benefit from revascularization. Taking all these facts into consideration, proper pre-procedural assessment and patient selection is crucial for a good outcome with this procedure. According to the European Society of Cardiology (ESC) guidelines, PCI of a CTO should be considered in patients with angina symptoms resistant to medical therapy or with a large area of ischemia documented within the territory of the occluded vessel — class of recommendation IIa [4].

The myocardium supplied by a CTO may display variable pathophysiological characteristics ranging from normal perfusion, stress-induced ischemia, resting ischemia, and hibernation, to

Address for correspondence: Dr. Marta Mielniczuk, Military Institute of Medicine — National Research Institute, ul. Szaserów 128, 04–141 Warszawa, Poland, tel: +48 663 726 696, e-mail: mmielniczuk@wim.mil.pl

Received: 13.10.2022

Accepted: 29.03.2023

Early publication date: 8.05.2023

This article is available in open access under Creative Commons Attribution-Non-Commercial-No Derivatives 4.0 International (CC BY-NC-ND 4.0) license, allowing to download articles and share them with others as long as they credit the authors and the publisher, but without permission to change them in any way or use them commercially.

necrosis [5]. The decision is easier for patients suffering from angina despite optimal medical treatment; however, asymptomatic patients must be evaluated by paying attention to the presence of ischemia and the viable myocardium supplied by a CTO vessel before considering CTO revascularization [6]. In general, revascularization is recommended for patients with a myocardium ischemia burden > 10% [4, 6, 7].

Since a complex, non-invasive assessment seems to be key to proper revascularization, this article aimed to review the imaging modalities used to evaluate LV function, contractility, ischemia, myocardial viability, and the anatomy of coronary arteries in patients with CTO.

Echocardiography

Transthoracic echocardiography is usually one of the first tests to be used in patients with suspected or known cardiovascular disease. It is feasible, inexpensive, and not as time-consuming as other tests. It provides information about left and right ventricular function, global and regional LV wall contractility, and valve competency. However, the accuracy of the examination depends on the quality of visualization, which is imperfect in most patients.

Normal regional LV function of the myocardium supplied by the CTO excludes non-viability [8]. On the other hand, akinetic segments with LV wall thinning are traditionally thought to be markers for scarring, with an end-diastolic wall thickness cut point of < 6 mm [9]. However, there is a prospective study demonstrating that 18% of thinned regions had limited scar burden assessed by cardiac magnetic resonance ($\leq 50\%$ of total extent) and showed LV function improvement after revascularization [10].

Dobutamine stress echocardiography (DSE) is a thoroughly investigated modality for the assessment of myocardial viability, with a mean sensitivity of 84% and a mean specificity of 81% [11]. Asl et al. [12] showed good agreement between low-dose DSE and low-dose dobutamine-gated single-photon emission computed tomography (SPECT) scans for the evaluation of inotropic reserve in dysfunctional areas.

For contractile reserve assessment, dobutamine is used at low doses (5–20 $\mu\text{g}/\text{kg}/\text{min}$) [13]. Dysfunctional hypokinetic or akinetic LV segments with preserved viability should display improved performance in response to a sympathetic stimulus. The presence or absence of

contractile responses enables the differentiation between nonviable myocardium with transmural or extensive non-transmural infarction and stunned or hibernating myocardium [14].

Using higher doses of dobutamine (20–40 $\mu\text{g}/\text{kg}/\text{min}$) might reveal ischemia and worsening contractility. DSE is usually well-tolerated by patients and does not have many contraindications (e.g. ventricular arrhythmias, recent myocardial infarction, unstable angina, and severe hypertension). However, the reliability of the results depends on good image quality and the investigator's experience.

Speckle tracking echocardiography techniques, especially global longitudinal strain (GLS), are considered to be good parameters for detecting early subclinical LV dysfunction. These techniques have gained interest as potential markers of myocardial ischemia [15–17]. However, more research is needed before they become routine practice for this indication (Fig. 1).

Recently, the novel echocardiography parameter myocardial work was introduced as a promising tool for the detection of significant CAD. The technique is based on the non-invasive LV pressure-strain loop, counted from speckle-tracking echocardiography indexed to systolic blood pressure. Global constructive work is defined as the sum of myocardial shortening during systole and myocardial lengthening during isovolumic relaxation. Global wasted work represents the opposite, i.e. myocardial lengthening in systole and shortening in isovolumic relaxation. Global myocardial work efficiency is the ratio of constructive work to the sum of constructive work and wasted work. Edwards et al. [18] examined 115 patients referred for coronary angiography and demonstrated that global myocardial work was superior to GLS in predicting significant CAD in those patients.

To summarize, the wide availability of echocardiography makes it a useful diagnostic tool for the assessment of LV function, contractile reserve, and viability. However, its accuracy is greatly dependent on the investigator's experience.

CMR

In recent years, cardiac magnetic resonance imaging (CMR) has become one of the main non-invasive modalities for complex cardiovascular assessment. It is the gold standard for the evaluation of cardiac morphology, left and right ventricle regional and global function, and ventricular volumes. Due to its high tissue contrast and resolution with electrocardiogram-gating and breath-holding

techniques, the image quality is better than in echocardiography. CMR contrast-enhanced sequences provide information about ischemia and viability.

Gadolinium-based contrast agents used in magnetic resonance imaging have a very low risk of allergic reaction and other adverse events [19]. According to the current guidelines, renal impairment with estimated glomerular filtration rate (eGFR) < 30 mL/min/1.73 m² is no longer a contraindication for the administration of gadolinium-based agents, when medically necessary [20, 21]. In patients with eGFR < 30 mL/min/1.73 m² and in dialysis-dependent patients, macrocyclic agents or newer linear agents (group II agents) should be administered [21].

Myocardial perfusion is evaluated by the first pass perfusion of the myocardium using gadolinium-based contrast documenting ischemia at the segmental myocardial level [22]. Three LV short-axis slices (base, mid, and apex) are assessed during rest and stress perfusion sequences [23]. Stress perfusion hyperemia is achieved by using either vasodilators (e.g. adenosine, dipyridamole, regadenoson) or dobutamine. Compared to invasive angiography and measurements of fractional flow reserve, CMR myocardial perfusion imaging proved to be non-inferior to fractional flow

reserve with respect to major adverse cardiac events [24].

Over the last couple of years, there has been rapid development of quantitative myocardial perfusion mapping techniques. Kellman et al. [25] implemented a fully automated quantitative technique for quantification of myocardial blood flow. The myocardial blood flow and myocardial perfusion reserve measured with automated perfusion mapping CMR showed comparable repeatability to positron emission tomography (PET), which is considered a reference standard for non-invasive measurement of myocardial blood flow [26].

The late gadolinium enhancement (LGE) sequences are used for the detection of myocardial scar, which indirectly reflects myocardial viability. Contrast agents accumulate in regions of increased extracellular volume, such as areas of scarring or fibrosis. The pattern of LGE is crucial for the differentiation between ischemic and non-ischemic myocardial injury [27]. An ischemic scar extending from the subendocardium to the epicardium can present with a subendocardial (non-transmural) or transmural pattern on LGE [28]. Studies have confirmed that the extent of LGE can determine myocardial viability and predict function improvement after revascularization [29]. In general,

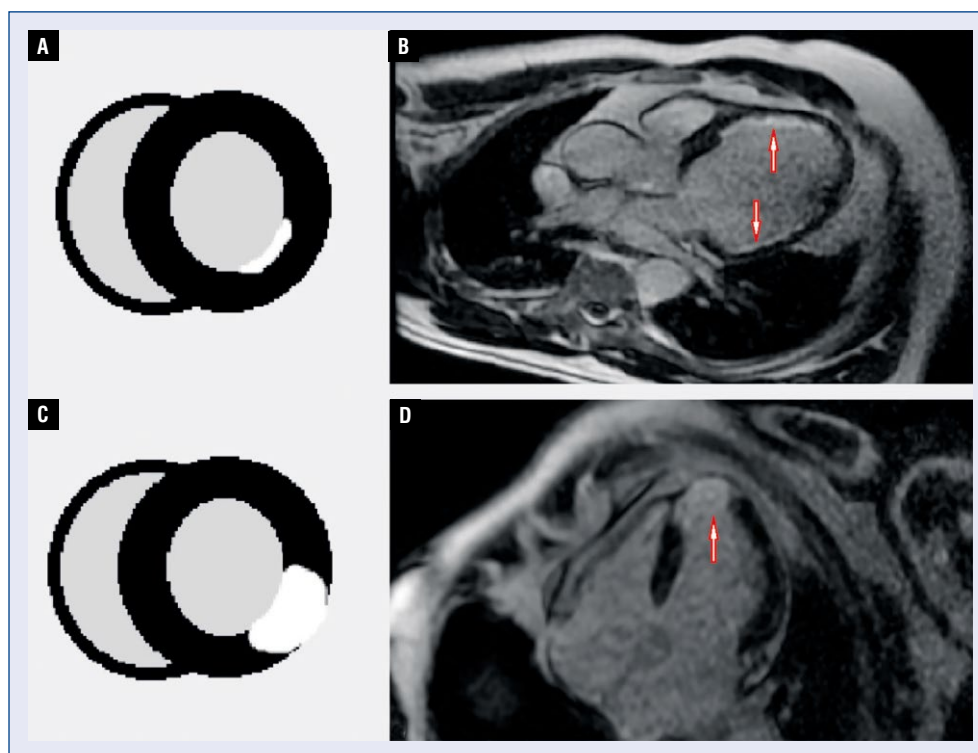


Figure 2. A, B. Subendocardial (non-transmural) pattern of late gadolinium enhancement (LGE) pointed with arrows; C, D. Transmural pattern of LGE pointed with an arrow.

segments with less than 50% of transmural LGE are considered viable. Compared to PET as the reference standard, CMR assessment of myocardial viability in patients with CTO has proven to have high sensitivity, specificity, and accuracy [30]. In patients with contraindications to gadolinium-based contrast agents, viability can also be assessed using low-dose dobutamine stress CMR — similarly to DSE (Fig. 2).

Nowadays, new CMR techniques (T1 and T2 mapping) have gained interest in tissue characterization and viability evaluation with promising results [31]. CMR T1 mapping techniques give an opportunity for tissue characterization and ischemia testing without contrast administration [32]. Native rest and stress T1 mapping allow for the differentiation of normal from infarcted and ischemic myocardium due to their different T1 values [33].

Considering the diversity of diagnostic possibilities, CMR seems to be a perfect tool for the assessment of CTO patients. It can also identify patients who are likely to benefit from revascularization by demonstrating inducible perfusion defects and myocardial viability in CTO territories [34].

Nonetheless, CMR has some patient limitations such as arrhythmias which worsen image

quality, claustrophobia, and the presence of CMR-unsafe devices (e.g. epicardial leads or older types of pacemakers and cardioverter-defibrillators). Most pacemakers and defibrillators implanted nowadays have CMR-safe or CMR-conditional statuses, making them feasible for CMR examination.

CT

Computed tomography (CT) is a well-established non-invasive method for diagnosing CAD. Computed tomography coronary angiography (CTCA) images can be reconstructed into a three-dimensional (3D) view allowing the evaluation of the coronary tree anatomy in any desired plane with no loss of spatial resolution [35]. In addition to the visualization of the coronary artery lumen, CTCA allows the assessment of plaque morphology and classification of lesions as calcified, non-calcified, or partially calcified [36]. In the presence of CTOs, CTCA is a useful tool for predicting the success of intervention and for pre-procedural planning. Studies have identified some lesion features on CTCA that can predict an unfavorable PCI outcome such as: occlusion length > 15 mm, severe calcification, and blunt stump morphology

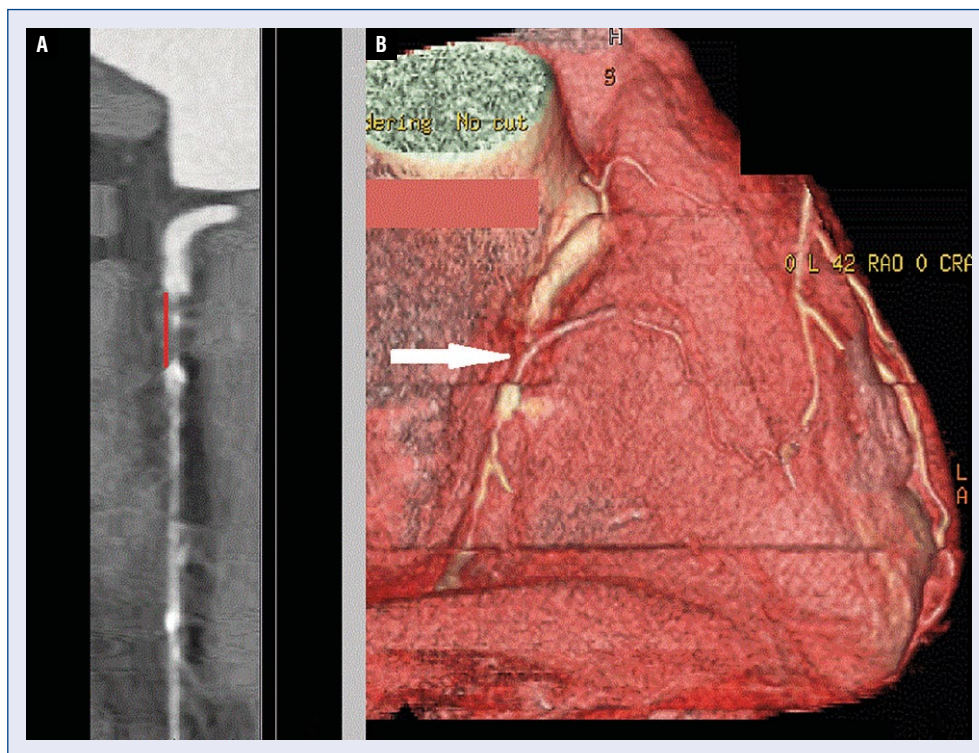


Figure 3. A. Right coronary artery coronary chronic total occlusion (CTO) with lesion length measured with red line; **B.** Right coronary artery three-dimensional reconstruction with CTO pointed with an arrow.

[37]. Opolski et al. [38] developed and validated a Computed Tomography Registry of Chronic Total Occlusion Revascularization (CT-RECTOR) score as a prediction rule for grading CTO difficulty by predicting the successful crossing of a guidewire within 30 minutes.

Advantages of CTCA pre-procedural planning include the assessment of proximal cap calcification, occlusion length, artery tortuosity, and the evaluation of collateral circulation. These factors allow the cardiologist to choose the most suitable interventional approach (antegrade versus retrograde).

Currently, CTCA gives mostly anatomical insight into CAD. Recently, there has been increasing interest in myocardial perfusion and viability assessments using CTCA [39]. However, due to the lack of standardization and concerns regarding radiation exposure and contrast dose, these techniques have not been used in routine clinical practice so far.

Computed tomography coronary angiography is a useful tool to optimize the revascularization strategy for treating a CTO with the ability to characterize the plaque composition of the occluded artery, as well as visualize the lesion length, the

course of the distal artery, and the associated side branches (Fig. 3) [35].

SPECT

Single-photon emission computed tomography is a radionuclear modality utilizing gamma rays. This technique uses radioisotopes bound to a special ligand with the ability to bind to certain types of tissues. Currently, the most common radioisotopes used are technetium-99m (Tc-99m) and thallium-201 (Tl-201) [40]. Nowadays, hybrid SPECT/CT imaging is used in routine clinical practice allowing the co-registering of images with functional and structural information provided by the two imaging modalities [41, 42]. Radiation exposure during the test is 6–13 mSV [43]. SPECT provides information on LV systolic function, myocardial perfusion, and viability.

Assessment of myocardial perfusion is one of the main indications for SPECT and has a sensitivity of 83% and specificity of 77% [44]. During the test, stress and rest images are registered. Stress images are achieved by injecting radiotracers during maximal hyperemia caused by physical exercise (e.g. treadmill test) or pharmacological agents

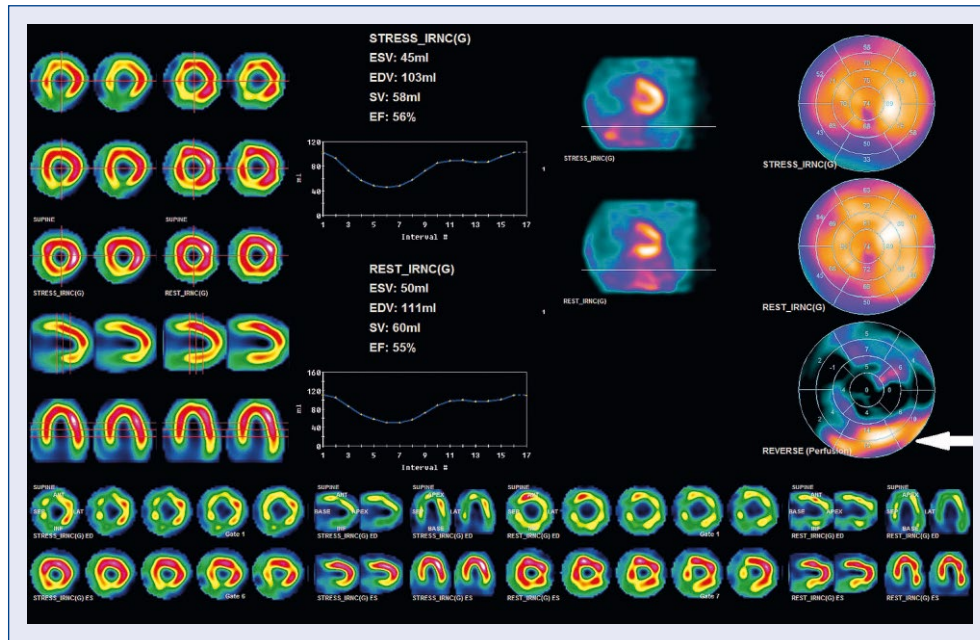


Figure 4. Single-photon emission computed tomography polar map display with reversible perfusion defect in basal and mid segments of inferior and posterior left ventricular wall (pointed with an arrow).

such as adenosine, dipyridamole, regadenoson, or dobutamine. Adenosine is a vasodilator, which results in a 3.5- to 4-fold increase in myocardial blood flow [45]. The mechanism of adenosine-induced myocardial perfusion defects is due to a greater increase in coronary flow in normal arteries and a lesser increase in stenotic arteries [46]. Dipyridamole is a nonselective adenosine agonist. Both adenosine and dipyridamole are widely used as pharmacological stress agents, with moderate frequency of minor side effects such as dizziness, dyspnea, chest pain, headache, abdominal pain, and flushing [47, 48]. The main contraindications for both adenosine and dipyridamole admission are bronchospastic lung disease with ongoing wheezing or history of significant reactive airway disease and advanced conduction abnormalities, including 2nd- or 3rd-degree atrioventricular block [49]. Regadenoson is a highly specific adenosine A2A receptor agonist with a 9-fold stronger affinity for A2A receptors than adenosine, the stimulation of which provokes coronary vasodilation. Moreover, regadenoson affinity for other types of adenosine receptors (A1, A2B, and A3), the stimulation of which may cause severe side effects including atrioventricular block or broncho-constriction, is residual [50]. With fewer side effects than adenosine and dipyridamole, regadenoson has gained a leading role in pharmacological stress perfusion tests. If the use of vasodilators is contraindicated,

dobutamine represents an alternative stress modality [51]. Dobutamine is an inotropic agent, which increases coronary blood flow by increasing myocardial workload [52].

After image registration, stress and rest myocardial perfusion are compared using polar map displays and semiquantitative segmental scoring. A stress perfusion defect in a region with normal rest perfusion, called a reversible defect, is suggestive of myocardial ischemia [53]. Segments with similar stress and rest perfusion defects, called fixed defects, can be an area of myocardial infarction or, less commonly, hibernating myocardium (Fig. 4).

The detection of a myocardial reversible perfusion defect is crucial when considering coronary intervention, due to its association with improved outcomes and more favorable risk stratification. Based on previous research, a myocardial ischemic burden of > 10% is considered to be severe and is an indication for revascularization, which has been proven to reduce the absolute and relative risks of cardiac death compared to medical therapy [54].

Myocardial hibernation is a state of persistent myocardial dysfunction (down-regulation of contractility) with preserved viability caused by insufficient myocardial blood flow [13]. SPECT can be a useful instrument in differentiating between hibernating myocardium and scar, which helps predict the likelihood of LV functional recovery after revascularization [55]. Whereas SPECT is more

widely available and less expensive, the diagnostic value for viability detection is lower than PET and is associated with a sensitivity of 83–87% and a specificity of 65–69% [7].

PET

Positron emission tomography is another radionuclear modality that measures photons produced after positron emission from a radionuclide-tagged tracer molecule that binds to the target tissue. Most of the radionuclides used for PET imaging (e.g. oxygen-15, nitrogen-13, fluoride-18) are cyclotron products with short half-lives, making it necessary to have an onsite cyclotron [7], which makes this method less available and quite expensive. Like SPECT, a PET scan can be combined with CT (PET/CT) to provide both functional and anatomical images. PET myocardial perfusion imaging allows measurement of myocardial perfusion with approximately 89% sensitivity and 89% specificity [56]. The diagnostic performance of PET is superior to that of SPECT because it has higher spatial resolution allowing for the detection of even small perfusion defects, which may be underestimated in SPECT [8]. Moreover, PET enables myocardial blood flow to be quantified in absolute terms and the calculation of coronary flow reserve [8].

Positron emission tomography/computed tomography is recognized as the gold standard for assessing myocardial viability [57]. With the use of an 18F-fluorodeoxyglucose (18F-FDG) radiotracer as a marker of metabolism, its regional myocardial uptake reflects viable myocytes [58]. PET with 18F-FDG combined with perfusion assessment provides a complete picture of the condition of myocardial tissue. Normal resting perfusion is a sign of intact capillary and sarcolemmal membranes and viable myocardium [8]. An irreversible perfusion defect (present on both stress and rest images) can represent either a myocardial scar or hibernating viable myocardium [8]. The differentiation of these two conditions is possible using metabolic imaging. Reduced perfusion with preserved 18F-FDG uptake (perfusion-metabolism mismatch) signifies hibernating myocardium [5]. A rest perfusion defect in an area with no 18F-FDG uptake is indicative of a scar. The diagnostic accuracy for viability assessment using PET has proven to be excellent with a mean sensitivity of 88–93% and specificity of 58–73% [7].

To summarize, PET enables precise perfusion and viability assessments with less radiation exposure (2–5 mSv) [43] and a shorter time of image acquisition compared to SPECT. However,

it is less available and more expensive, making it hard to implement as a routine CAD diagnostic tool.

CPET and ICG

Among patients with CAD, objectification of their symptoms might be difficult due to comorbid diseases such as heart failure, obesity, or chronic obstructive pulmonary disease, which can all manifest with dyspnea, chest pain, or impaired exercise tolerance. Cardiopulmonary exercise testing (CPET) allows the differentiation between pulmonary, cardiovascular, muscular, and cellular oxidative system disorders that can lead to exercise intolerance. Several CPET parameters such as peak oxygen uptake (VO_2), ventilation/carbon dioxide production (VE/VCO_2) slope, and work efficiency ($\Delta\text{VO}_2/\Delta\text{WR}$) have a well-established role in CAD patient assessment [59, 60].

Exercise impedance cardiography (ICG) is another non-invasive modality to evaluate cardiovascular hemodynamic parameters during exercise. This method is based on measuring electrical signals received from tissues and analyzing impedance signal changes during exercise [61]. ICG can assess stroke volume, cardiac output, cardiac index, and systemic vascular resistance. Even more importantly, it can assess changes in the above parameters in response to increasing exercise loads. A decrease in stroke volume during exercise, as measured by ICG, was proven to precede symptoms and ST changes in patients with ischemic myocardium (Fig. 5) [62].

Combining ICG and CPET examinations provides detailed insight into the hemodynamic changes occurring during physical exercise and can identify the underlying cause of the impaired physical capacity. Both methods are non-invasive, accessible, and offer added value to CAD patient assessment.

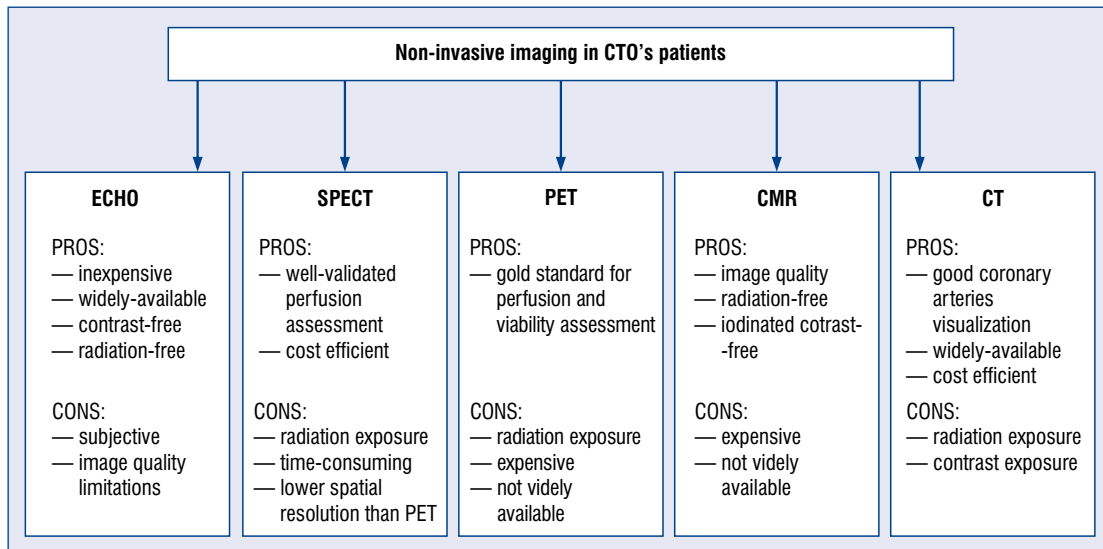
Conclusions

When choosing a non-invasive diagnostic modality for the assessment of a CTO patient, several aspects should be taken into consideration. Each modality has advantages and disadvantages, making it impossible to point to one perfect diagnostic tool. Instead, a patient-tailored approach is the best solution (Central illustration).

Because the PCI of a CTO is associated with significant exposure to radiation, additional radiation doses during non-invasive evaluation should be avoided or reduced to the minimum range, especially in younger patients. Nowadays, thanks to the

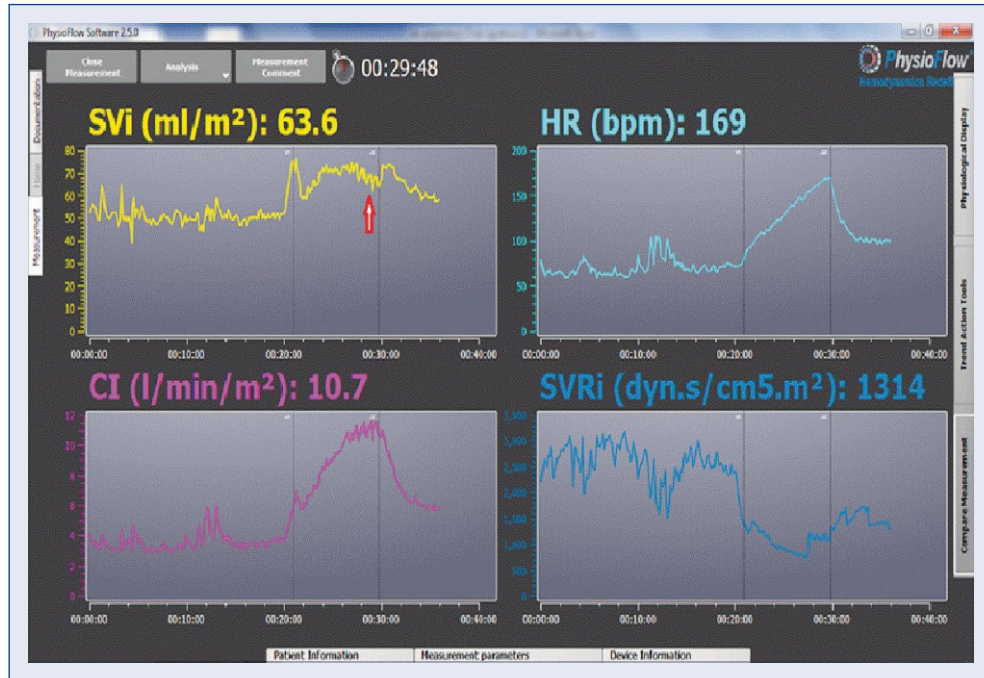

Figure 5. Impedance cardiography diagram with a decrease in stroke volume during exercise (pointed with an arrow).



Central illustration. Main advantages (PROS) and disadvantages (CONS) of non-invasive modalities in coronary advancement in imaging techniques, the average chronic total occlusion (CTO) patient evaluation; ECHO — echocardiography, SPECT — single-photon emission computed tomography, PET — positron emission tomography; CMR — cardiac magnetic resonance, CT — computed tomography. renal impairment, which limits the use of CTCA and CMR. In these patients, echocardiography or nuclear medicine techniques should be preferred. Supraventricular and ventricular arrhythmias, especially atrial fibrillation, worsen the image

quality in modalities using electrocardiogram-gating techniques such as CMR and CTCA. Several patient-related issues, such as claustrophobia or difficulties holding one's breath, may also reduce the diagnostic value of CMR.

Cost-effectiveness and accessibility are other important factors to consider, especially in countries with underfunded health care systems.

Based on the characteristics of each modality, the authors would like to propose a non-invasive diagnostic algorithm for CTO patients. Once the CTO is diagnosed, each patient should undergo echocardiography with global and regional LV wall contractility assessment. The second step should be ischemia and viability evaluation, preferably using PET, CMR, or SPECT, depending on local availability and patient characteristics. If none of the above is available, DSE may be utilized. In the case of pre-procedural planning difficulties, CTCA may be useful.

In some patients with ambiguous symptoms or inconsistent results of imaging modalities, additional examinations with CPET and ICG can be performed to evaluate the cardiovascular hemodynamic response to exercise.

In summary, there is a wide range of possibilities for the non-invasive evaluation of patients with CTOs. The choice of test depends on patient characteristics and regional availability. Some patients will benefit from a combined assessment with more than one imaging modality. Overall, the key to a better outcome is correct identification of patients who require revascularization versus medical therapy based on their symptoms of ischemia, and taking into consideration the objective evidence of myocardial perfusion abnormalities and viability in the CTO region.

Acknowledgments

This study was conducted as part of a WIM/MNiSW statutory project (no. 562).

The authors would like to express their gratitude to the Department of Radiology in the Military Institute of Medicine in Warsaw, especially to Dr n. med. Artur Maliborski and Dr Arkadiusz Koroniecki for the CTCA and CMR images used in the figures.

Conflict of interest: None declared

References

1. Werner GS, Martin-Yuste V, Hildick-Smith D, et al. EUROCTO trial investigators. A randomized multicentre trial to compare

- revascularization with optimal medical therapy for the treatment of chronic total coronary occlusions. *Eur Heart J.* 2018; 39(26): 2484–2493, doi: [10.1093/eurheartj/ehy220](https://doi.org/10.1093/eurheartj/ehy220), indexed in Pubmed: [29722796](https://pubmed.ncbi.nlm.nih.gov/29722796/).
2. Hoebbers LP, Claessen BE, Elias J, et al. Meta-analysis on the impact of percutaneous coronary intervention of chronic total occlusions on left ventricular function and clinical outcome. *Int J Cardiol.* 2015; 187: 90–96, doi: [10.1016/j.ijcard.2015.03.164](https://doi.org/10.1016/j.ijcard.2015.03.164), indexed in Pubmed: [25828320](https://pubmed.ncbi.nlm.nih.gov/25828320/).
3. Christakopoulos GE, Christopoulos G, Carlino M, et al. Meta-analysis of clinical outcomes of patients who underwent percutaneous coronary interventions for chronic total occlusions. *Am J Cardiol.* 2015; 115(10): 1367–1375, doi: [10.1016/j.amjcard.2015.02.038](https://doi.org/10.1016/j.amjcard.2015.02.038), indexed in Pubmed: [25784515](https://pubmed.ncbi.nlm.nih.gov/25784515/).
4. Sousa-Uva M, Neumann FJ, Ahlsson A, et al. 2018 ESC/EACTS Guidelines on myocardial revascularization. *Eur J Cardiothorac Surg.* 2019; 55(1): 4–90, doi: [10.1093/ejcts/ezy289](https://doi.org/10.1093/ejcts/ezy289), indexed in Pubmed: [30165632](https://pubmed.ncbi.nlm.nih.gov/30165632/).
5. Wang Li, Lu MJ, Feng L, et al. Relationship of myocardial hibernation, scar, and angiographic collateral flow in ischemic cardiomyopathy with coronary chronic total occlusion. *J Nucl Cardiol.* 2019; 26(5): 1720–1730, doi: [10.1007/s12350-018-1241-8](https://doi.org/10.1007/s12350-018-1241-8), indexed in Pubmed: [29516366](https://pubmed.ncbi.nlm.nih.gov/29516366/).
6. Brilakis ES, Mashayekhi K, Tsuchikane E, et al. Guiding principles for chronic total occlusion percutaneous coronary intervention. A global expert consensus document. *Circulation.* 2019; 140(5): 420–433.
7. Kersten J, Eberhardt N, Prasad V, et al. Non-invasive imaging in patients with chronic total occlusions of the coronary arteries: what does the interventionalist need for success? *Front Cardiovasc Med.* 2021; 8: 713625, doi: [10.3389/fcvm.2021.713625](https://doi.org/10.3389/fcvm.2021.713625), indexed in Pubmed: [34527713](https://pubmed.ncbi.nlm.nih.gov/34527713/).
8. Stuijzand WJ, Rajmakers PG, Driessen RS, et al. Value of hybrid imaging with PET/CT to guide percutaneous revascularization of chronic total coronary occlusion. *Curr Cardiovasc Imaging Rep.* 2015; 8(7): 26, doi: [10.1007/s12410-015-9340-2](https://doi.org/10.1007/s12410-015-9340-2), indexed in Pubmed: [26029338](https://pubmed.ncbi.nlm.nih.gov/26029338/).
9. Garcia MJ, Kwong RY, Scherrer-Crosbie M, et al. State of the art: imaging for myocardial viability: a scientific statement from the american heart association. *Circ Cardiovasc Imaging.* 2020; 13(7): e000053, doi: [10.1161/HCI.0000000000000053](https://doi.org/10.1161/HCI.0000000000000053), indexed in Pubmed: [32833510](https://pubmed.ncbi.nlm.nih.gov/32833510/).
10. Shah DJ, Kim HW, James O, et al. Prevalence of regional myocardial thinning and relationship with myocardial scarring in patients with coronary artery disease. *JAMA.* 2013; 309(9): 909–918, doi: [10.1001/jama.2013.1381](https://doi.org/10.1001/jama.2013.1381), indexed in Pubmed: [23462787](https://pubmed.ncbi.nlm.nih.gov/23462787/).
11. Bax JJ, Wijns W, Cornel JH, et al. Accuracy of currently available techniques for prediction of functional recovery after revascularization in patients with left ventricular dysfunction due to chronic coronary artery disease: comparison of pooled data. *J Am Coll Cardiol.* 1997; 30(6): 1451–1460, doi: [10.1016/s0735-1097\(97\)00352-5](https://doi.org/10.1016/s0735-1097(97)00352-5), indexed in Pubmed: [9362401](https://pubmed.ncbi.nlm.nih.gov/9362401/).
12. Asl MT, Mandegar MH, Roshanali F, et al. Comparison of stress dobutamine echocardiography and stress dobutamine gated myocardial SPECT for the detection of viable myocardium. *Nucl Med Rev Cent East Eur.* 2014; 17(1): 18–25, doi: [10.5603/NMR.2014.0005](https://doi.org/10.5603/NMR.2014.0005), indexed in Pubmed: [24610648](https://pubmed.ncbi.nlm.nih.gov/24610648/).
13. Mari C, Strauss WH. Detection and characterization of hibernating myocardium. *Nucl Med Commun.* 2002; 23(4): 311–322, doi: [10.1097/00006231-200204000-00004](https://doi.org/10.1097/00006231-200204000-00004), indexed in Pubmed: [11930184](https://pubmed.ncbi.nlm.nih.gov/11930184/).

14. Khemka A, Sawada SG. Dobutamine echocardiography for assessment of viability in the current era. *Curr Opin Cardiol*. 2019; 34(5): 484–489, doi: [10.1097/HCO.0000000000000658](https://doi.org/10.1097/HCO.0000000000000658), indexed in Pubmed: [31261177](https://pubmed.ncbi.nlm.nih.gov/31261177/).
15. Laufer-Perl M, Arnold JH, Moshkovits Y, et al. Evaluating the role of left ventricle global longitudinal strain in myocardial perfusion defect assessment. *Int J Cardiovasc Imaging*. 2022; 38(2): 289–296, doi: [10.1007/s10554-021-02399-6](https://doi.org/10.1007/s10554-021-02399-6), indexed in Pubmed: [34498200](https://pubmed.ncbi.nlm.nih.gov/34498200/).
16. Pastore MC, Mandoli GE, Contorni F, et al. Speckle tracking echocardiography: early predictor of diagnosis and prognosis in coronary artery disease. *Biomed Res Int*. 2021; 2021: 6685378, doi: [10.1155/2021/6685378](https://doi.org/10.1155/2021/6685378), indexed in Pubmed: [33623788](https://pubmed.ncbi.nlm.nih.gov/33623788/).
17. Biswas K, Mukherjee A, Nandi S, et al. Utility of global longitudinal strain to detect significant coronary artery disease, its extent and severity in patients with stable ischemic heart disease. *Echocardiography*. 2020; 37(12): 2000–2009, doi: [10.1111/echo.14908](https://doi.org/10.1111/echo.14908), indexed in Pubmed: [33099804](https://pubmed.ncbi.nlm.nih.gov/33099804/).
18. Edwards NFA, Scalia GM, Shiino K, et al. Global myocardial work is superior to global longitudinal strain to predict significant coronary artery disease in patients with normal left ventricular function and wall motion. *J Am Soc Echocardiogr*. 2019; 32(8): 947–957, doi: [10.1016/j.echo.2019.02.014](https://doi.org/10.1016/j.echo.2019.02.014), indexed in Pubmed: [31043359](https://pubmed.ncbi.nlm.nih.gov/31043359/).
19. Uhlig J, Al-Bourini O, Salgado R, et al. Gadolinium-based contrast agents for cardiac MRI: use of linear and macrocyclic agents with associated safety profile from 154 779 European patients. *Radiol Cardiothorac Imaging*. 2020; 2(5): e200102, doi: [10.1148/ryct.2020200102](https://doi.org/10.1148/ryct.2020200102), indexed in Pubmed: [33778622](https://pubmed.ncbi.nlm.nih.gov/33778622/).
20. Minton L, Pandit R, Porter K. Contrast-enhanced MRI: history and current recommendations. *Applied Radiology*. 2021: 15–19, doi: [10.37549/ar2776](https://doi.org/10.37549/ar2776).
21. Schieda N, Blachman JI, Costa AF, et al. Gadolinium-Based contrast agents in kidney disease: a comprehensive review and clinical practice guideline issued by the canadian association of radiologists. *Can J Kidney Health Dis*. 2018; 5: 2054358118778573, doi: [10.1177/2054358118778573](https://doi.org/10.1177/2054358118778573), indexed in Pubmed: [29977584](https://pubmed.ncbi.nlm.nih.gov/29977584/).
22. Jones RE, Karamasis GV, Dungu JN, et al. Stress perfusion cardiovascular magnetic resonance and serial fractional flow reserve assessment of the left anterior descending artery in patients undergoing right coronary artery chronic total occlusion revascularization. *Cardiol J*. 2022; 29(1): 80–87, doi: [10.5603/CJ.a2020.0007](https://doi.org/10.5603/CJ.a2020.0007), indexed in Pubmed: [32037503](https://pubmed.ncbi.nlm.nih.gov/32037503/).
23. Hamirani YS, Kramer CM. Cardiac MRI assessment of myocardial perfusion. *Future Cardiol*. 2014; 10(3): 349–358, doi: [10.2217/fca.14.18](https://doi.org/10.2217/fca.14.18), indexed in Pubmed: [24976472](https://pubmed.ncbi.nlm.nih.gov/24976472/).
24. Nagel E, Greenwood J, McCann G, et al. Magnetic resonance perfusion or fractional flow reserve in coronary disease. *N Engl J Med*. 2019; 380(25): 2418–2428, doi: [10.1056/nejmoa1716734](https://doi.org/10.1056/nejmoa1716734).
25. Kellman P, Hansen MS, Nelles-Vallespin S, et al. Myocardial perfusion cardiovascular magnetic resonance: optimized dual sequence and reconstruction for quantification. *J Cardiovasc Magn Reson*. 2017; 19(1): 43, doi: [10.1186/s12968-017-0355-5](https://doi.org/10.1186/s12968-017-0355-5), indexed in Pubmed: [28385161](https://pubmed.ncbi.nlm.nih.gov/28385161/).
26. Brown LAE, Oniciu SC, Broadbent DA, et al. Fully automated, inline quantification of myocardial blood flow with cardiovascular magnetic resonance: repeatability of measurements in healthy subjects. *J Cardiovasc Magn Reson*. 2018; 20(1): 48, doi: [10.1186/s12968-018-0462-y](https://doi.org/10.1186/s12968-018-0462-y), indexed in Pubmed: [29983119](https://pubmed.ncbi.nlm.nih.gov/29983119/).
27. Matusik PS, Bryll A, Matusik PT, et al. Ischemic and non-ischemic patterns of late gadolinium enhancement in heart failure with reduced ejection fraction. *Cardiol J*. 2021; 28(1): 67–76, doi: [10.5603/CJ.a2020.0009](https://doi.org/10.5603/CJ.a2020.0009), indexed in Pubmed: [32037500](https://pubmed.ncbi.nlm.nih.gov/32037500/).
28. Thygesen K, Alpert JS, Jaffe AS, et al. Fourth Universal Definition of Myocardial Infarction (2018). *Circulation*. 2018; 138(20): e618–e651, doi: [10.1161/CIR.0000000000000617](https://doi.org/10.1161/CIR.0000000000000617), indexed in Pubmed: [30571511](https://pubmed.ncbi.nlm.nih.gov/30571511/).
29. Kim RJ, Wu E, Rafael A, et al. The use of contrast-enhanced magnetic resonance imaging to identify reversible myocardial dysfunction. *N Engl J Med*. 2000; 343(20): 1445–1453, doi: [10.1056/NEJM200011163432003](https://doi.org/10.1056/NEJM200011163432003), indexed in Pubmed: [11078769](https://pubmed.ncbi.nlm.nih.gov/11078769/).
30. Li JN, He Y, Dong W, et al. Comparison of cardiac MRI with PET for assessment of myocardial viability in patients with coronary chronic total occlusion. *Clin Radiol*. 2019; 74(5): 410.e1–410.e9, doi: [10.1016/j.crad.2019.01.021](https://doi.org/10.1016/j.crad.2019.01.021), indexed in Pubmed: [30803813](https://pubmed.ncbi.nlm.nih.gov/30803813/).
31. Dastidar AG, Pontecorvoli G, Harries I, et al. Non-contrast assessment of myocardial viability in chronic myocardial infarction by native T1 and T2 mapping at 1.5T CMR: comparison with late gadolinium enhancement technique. *Heartjnl*. 2017; -311677.4.
32. Bazmpani MA, Nikolaidou C, Papanastasiou CA, et al. Cardiovascular magnetic resonance parametric mapping techniques for the assessment of chronic coronary syndromes. *J Cardiovasc Dev Dis*. 2022; 9(12), doi: [10.3390/jcdd9120443](https://doi.org/10.3390/jcdd9120443), indexed in Pubmed: [36547440](https://pubmed.ncbi.nlm.nih.gov/36547440/).
33. Piechnik SK, Neubauer S, Ferreira VM. State-of-the-art review: stress T1 mapping-technical considerations, pitfalls and emerging clinical applications. *MAGMA*. 2018; 31(1): 131–141, doi: [10.1007/s10334-017-0649-5](https://doi.org/10.1007/s10334-017-0649-5), indexed in Pubmed: [28914389](https://pubmed.ncbi.nlm.nih.gov/28914389/).
34. Bucciarelli-Ducci C, Auger D, Di Mario C, et al. CMR guidance for recanalization of coronary chronic total occlusion. *JACC Cardiovasc Imaging*. 2016; 9(5): 547–556, doi: [10.1016/j.jcmg.2015.10.025](https://doi.org/10.1016/j.jcmg.2015.10.025), indexed in Pubmed: [27085432](https://pubmed.ncbi.nlm.nih.gov/27085432/).
35. Cheung SCW, Lim MCL, Chan CWS. The role of coronary CT angiography in chronic total occlusion intervention. *Heart Asia*. 2010; 2(1): 122–125, doi: [10.1136/ha.2010.002261](https://doi.org/10.1136/ha.2010.002261), indexed in Pubmed: [27325959](https://pubmed.ncbi.nlm.nih.gov/27325959/).
36. Nerlekar N, Ha FJ, Cheshire C, et al. Computed tomographic coronary angiography-derived plaque characteristics predict major adverse cardiovascular events: a systematic review and meta-analysis. *Circ Cardiovasc Imaging*. 2018; 11(1): e006973, doi: [10.1161/CIRCIMAGING.117.006973](https://doi.org/10.1161/CIRCIMAGING.117.006973), indexed in Pubmed: [29305348](https://pubmed.ncbi.nlm.nih.gov/29305348/).
37. Mollet NR, Hoyer A, Lemos PA, et al. Value of preprocedure multislice computed tomographic coronary angiography to predict the outcome of percutaneous recanalization of chronic total occlusions. *Am J Cardiol*. 2005; 95(2): 240–243, doi: [10.1016/j.amjcard.2004.09.009](https://doi.org/10.1016/j.amjcard.2004.09.009), indexed in Pubmed: [15642558](https://pubmed.ncbi.nlm.nih.gov/15642558/).
38. Opolski MP, Achenbach S, Schuhbäck A, et al. Coronary computed tomographic prediction rule for time-efficient guidewire crossing through chronic total occlusion: insights from the CT-RECTOR multicenter registry (Computed Tomography Registry of Chronic Total Occlusion Revascularization). *JACC Cardiovasc Interv*. 2015; 8(2): 257–267, doi: [10.1016/j.jcin.2014.07.031](https://doi.org/10.1016/j.jcin.2014.07.031), indexed in Pubmed: [25700748](https://pubmed.ncbi.nlm.nih.gov/25700748/).
39. Rodríguez-Granillo GA, Ingino CA, Lylyk P. Myocardial perfusion imaging and infarct characterization using multidetector cardiac computed tomography. *World J Cardiol*. 2010; 2(7): 198–204, doi: [10.4330/wjc.v2.i7.198](https://doi.org/10.4330/wjc.v2.i7.198), indexed in Pubmed: [21160751](https://pubmed.ncbi.nlm.nih.gov/21160751/).
40. Patel RAG, Beller GA. Prognostic role of single-photon emission computed tomography (SPECT) imaging in myocardial viability. *Curr Opin Cardiol*. 2006; 21(5): 457–463, doi: [10.1097/01.hco.0000240582.83967.d8](https://doi.org/10.1097/01.hco.0000240582.83967.d8), indexed in Pubmed: [16900008](https://pubmed.ncbi.nlm.nih.gov/16900008/).
41. Montes C, Tamayo P, Hernandez J, et al. Estimation of the total effective dose from low-dose CT scans and radiopharmaceutical

- administrations delivered to patients undergoing SPECT/CT explorations. *Ann Nucl Med.* 2013; 27(7): 610–617, doi: [10.1007/s12149-013-0724-6](https://doi.org/10.1007/s12149-013-0724-6), indexed in Pubmed: [23568252](https://pubmed.ncbi.nlm.nih.gov/23568252/).
42. Miernik S, Dziuk M. Metody hybrydowe (SPECT-CT, PET-CT) w diagnostyce choroby wieńcowej i ocenie żywotności mięśnia sercowego. *Choroby Serca i Naczyń.* 2008; 5(2): 93–101.
 43. Allahwala UK, Brilakis ES, Kiat H, et al. The indications and utility of adjunctive imaging modalities for chronic total occlusion (CTO) intervention. *J Nucl Cardiol.* 2021; 28(6): 2597–2608, doi: [10.1007/s12350-020-02381-0](https://doi.org/10.1007/s12350-020-02381-0), indexed in Pubmed: [33025478](https://pubmed.ncbi.nlm.nih.gov/33025478/).
 44. Xu J, Cai F, Geng C, et al. Diagnostic performance of CMR, SPECT, and PET imaging for the identification of coronary artery disease: a meta-analysis. *Front Cardiovasc Med.* 2021; 8: 621389, doi: [10.3389/fcvm.2021.621389](https://doi.org/10.3389/fcvm.2021.621389), indexed in Pubmed: [34026862](https://pubmed.ncbi.nlm.nih.gov/34026862/).
 45. Henzlva MJ, Duvall WL, Einstein AJ, et al. ASNC imaging guidelines for SPECT nuclear cardiology procedures: Stress, protocols, and tracers. *J Nucl Cardiol.* 2016; 23(3): 606–639, doi: [10.1007/s12350-015-0387-x](https://doi.org/10.1007/s12350-015-0387-x), indexed in Pubmed: [26914678](https://pubmed.ncbi.nlm.nih.gov/26914678/).
 46. Verani MS. Pharmacological stress with adenosine for myocardial perfusion imaging. *Semin Nucl Med.* 1991; 21(3): 266–272, doi: [10.1016/s0001-2998\(05\)80045-5](https://doi.org/10.1016/s0001-2998(05)80045-5), indexed in Pubmed: [1948115](https://pubmed.ncbi.nlm.nih.gov/1948115/).
 47. Voigtländer T, Schmermund A, Bramlage P, et al. The adverse events and hemodynamic effects of adenosine-based cardiac MRI. *Korean J Radiol.* 2011; 12(4): 424–430, doi: [10.3348/kjr.2011.12.4.424](https://doi.org/10.3348/kjr.2011.12.4.424), indexed in Pubmed: [21852902](https://pubmed.ncbi.nlm.nih.gov/21852902/).
 48. Lee SD, Huang WC, Peng NJ, et al. Dipyridamole-induced adverse effects in myocardial perfusion scans: dynamic evaluation. *Int J Cardiol Heart Vasc.* 2017; 14: 14–19, doi: [10.1016/j.ijcha.2016.11.002](https://doi.org/10.1016/j.ijcha.2016.11.002), indexed in Pubmed: [28616557](https://pubmed.ncbi.nlm.nih.gov/28616557/).
 49. Lak HM, Ranka S, Goyal A. Pharmacologic Stress Testing. In: *StatPearls* [Internet]. Treasure Island (FL), StatPearls Publishing 2022 Jan; PMID: 32310423.
 50. Oleksiak A, Kruk M, Śpiewak M, et al. Safety of regadenoson with theophylline reversal during dynamic computed tomography perfusion and magnetic resonance imaging in patients with coronary artery disease. *Kardiologia Pol.* 2020; 78(7-8): 709–714, doi: [10.33963/KP.15356](https://doi.org/10.33963/KP.15356), indexed in Pubmed: [32395975](https://pubmed.ncbi.nlm.nih.gov/32395975/).
 51. Geleijnse ML, Elhendy A, Fioretti PM, et al. Dobutamine stress myocardial perfusion imaging. *J Am Coll Cardiol.* 2000; 36(7): 2017–2027, doi: [10.1016/s0735-1097\(00\)01012-3](https://doi.org/10.1016/s0735-1097(00)01012-3), indexed in Pubmed: [11127435](https://pubmed.ncbi.nlm.nih.gov/11127435/).
 52. Travain MI, Wexler JP. Pharmacological stress testing. *Semin Nucl Med.* 1999; 29(4): 298–318, doi: [10.1016/s0001-2998\(99\)80018-x](https://doi.org/10.1016/s0001-2998(99)80018-x), indexed in Pubmed: [10534233](https://pubmed.ncbi.nlm.nih.gov/10534233/).
 53. Dvorak RA, Brown RKJ, Corbett JR. Interpretation of SPECT/CT myocardial perfusion images: common artifacts and quality control techniques. *Radiographics.* 2011; 31(7): 2041–2057, doi: [10.1148/rg.317115090](https://doi.org/10.1148/rg.317115090), indexed in Pubmed: [22084188](https://pubmed.ncbi.nlm.nih.gov/22084188/).
 54. Hachamovitch R, Hayes SW, Friedman JD, et al. Comparison of the short-term survival benefit associated with revascularization compared with medical therapy in patients with no prior coronary artery disease undergoing stress myocardial perfusion single photon emission computed tomography. *Circulation.* 2003; 107(23): 2900–2907, doi: [10.1161/01.CIR.0000072790.23090.41](https://doi.org/10.1161/01.CIR.0000072790.23090.41), indexed in Pubmed: [12771008](https://pubmed.ncbi.nlm.nih.gov/12771008/).
 55. Malhotra S, Gomez J, Doukky R. Assessment of myocardial viability using single-photon emission computed tomography myocardial perfusion imaging. *Curr Opin Cardiol.* 2019; 34(5): 473–483, doi: [10.1097/HCO.0000000000000646](https://doi.org/10.1097/HCO.0000000000000646), indexed in Pubmed: [31219878](https://pubmed.ncbi.nlm.nih.gov/31219878/).
 56. Nakazato R, Berman DS, Alexanderson E, et al. Myocardial perfusion imaging with PET. *Imaging Med.* 2013; 5(1): 35–46, doi: [10.2217/iim.13.1](https://doi.org/10.2217/iim.13.1), indexed in Pubmed: [23671459](https://pubmed.ncbi.nlm.nih.gov/23671459/).
 57. Klocke FJ, Baird MG, Lorell BH, et al. ACC/AHA/ASNC guidelines for the clinical use of cardiac radionuclide imaging: executive summary: a report of the American College of Cardiology/American Heart Association Task Force on Practice Guidelines (ACC/AHA/ASNC Committee to Revise the 1995 Guidelines for the Clinical Use of Cardiac Radionuclide Imaging). *Circulation.* 2003; 108(11): 1404–1418, doi: [10.1161/01.CIR.0000080946.42225.4D](https://doi.org/10.1161/01.CIR.0000080946.42225.4D), indexed in Pubmed: [12975245](https://pubmed.ncbi.nlm.nih.gov/12975245/).
 58. Dong W, Li J, Mi H, et al. Relationship between collateral circulation and myocardial viability of F-FDG PET/CT subtended by chronic total occluded coronary arteries. *Ann Nucl Med.* 2018; 32(3): 197–205, doi: [10.1007/s12149-018-1234-3](https://doi.org/10.1007/s12149-018-1234-3), indexed in Pubmed: [29380138](https://pubmed.ncbi.nlm.nih.gov/29380138/).
 59. Popovic D, Guazzi M, Jakovljevic DG, et al. Quantification of coronary artery disease using different modalities of cardiopulmonary exercise testing. *Int J Cardiol.* 2019; 285: 11–13, doi: [10.1016/j.ijcard.2019.03.012](https://doi.org/10.1016/j.ijcard.2019.03.012), indexed in Pubmed: [30879940](https://pubmed.ncbi.nlm.nih.gov/30879940/).
 60. Chaudhry S, Arena R, Bhatt DL, et al. A practical clinical approach to utilize cardiopulmonary exercise testing in the evaluation and management of coronary artery disease: a primer for cardiologists. *Curr Opin Cardiol.* 2018; 33(2): 168–177, doi: [10.1097/HCO.0000000000000494](https://doi.org/10.1097/HCO.0000000000000494), indexed in Pubmed: [29240566](https://pubmed.ncbi.nlm.nih.gov/29240566/).
 61. Kurpaska M, Krzesiński P, Gielerek G, et al. Impedance cardiography during exercise – new technology, new possibilities. *Pediatrics i Medycyna Rodzinna.* 2017; 13(3): 303–310, doi: [10.15557/pimr.2017.0031](https://doi.org/10.15557/pimr.2017.0031).
 62. Dupuis JM, Bour J, Abraham P, et al. Detection of coronary artery disease (CAD) during bicycle exercise, using new generation impedance cardiography. *Heart J.* 2000; 83(Suppl II).