

Hematic mold of the bronchial tree after balloon pulmonary angioplasty

Hiroto Tamura¹, Yu Taniguchi², Tatsuya Kokawa¹, Muneyuki Kadota³

¹Division of Cardiology, Tokushima Red Cross Hospital, Takoushima, Japan

²Division of Cardiovascular Medicine, Department of Internal Medicine, Kobe University Graduate School of Medicine, Kobe, Japan

³Department of Cardiovascular Medicine, The University of Tokushima Graduate School of Health Biosciences, Tokushima, Japan

A 72-year-old woman with peripheral-type chronic thromboembolic pulmonary hypertension underwent balloon pulmonary angioplasty (BPA). Initial right heart catheterization revealed a pulmonary arterial pressure of 60/15 mmHg, mean pressure of 31 mmHg, pulmonary arterial wedge pressure of 8 mmHg, and pulmonary vascular resistance of 5.94 Wood units. The right A1, A3, A5, A8, A9, and A10 segments and the left A8, A9, and A10 segments were treated for 1st BPA (Fig. 1A, B, **Suppl. Video 1**). Ten minutes after the procedure, the patient developed hemoptysis. Pulmonary vessel injury was suspected, and non-invasive positive pressure ventilation was initiated. After 3 hours, hemoptysis disappeared. Echocardiography showed improved pulmonary hypertension; however, hypoxia persisted. Computed tomography

showed an infiltrative shadow in the right superior apical and middle medial lobes. Moreover, a space occupying lesion was detected in the right intermediate bronchus (Fig. 1C, D). The patient experienced a hacking cough and spontaneously expectorated a large blood clot shaped like a bronchial tree (Fig. 1E). After the removal of the blood clot, her oxygenation and dyspnea symptoms improved.

This is a rare case of expectorated hematic mold of the bronchial tree after BPA. Although hemoptysis stopped, the blood drifted to the right intermediate and inferior lobar bronchi. Further, the blood coagulated and was molded into the bronchial tree. This caused pulmonary atelectasis, which resulted in hypoxia. It should be noted that even if hemoptysis can be managed during BPA, blood clots can stay in the bronchi.

Conflict of interest: None declared

Address for correspondence: Hiroto Tamura, MD, Department of Cardiology, Tokushima Red Cross Hospital, 103 Irinokuchi, Komatsushima-cho, Komatsushima, Tokushima 773-8502, Japan, tel: +81-88-532-2555, fax: +81-88-532-6350, e-mail: hiroto.tamura2118@gmail.com

Received: 16.12.2022

Accepted: 31.01.2023

This article is available in open access under Creative Commons Attribution-Non-Commercial-No Derivatives 4.0 International (CC BY-NC-ND 4.0) license, allowing to download articles and share them with others as long as they credit the authors and the publisher, but without permission to change them in any way or use them commercially.

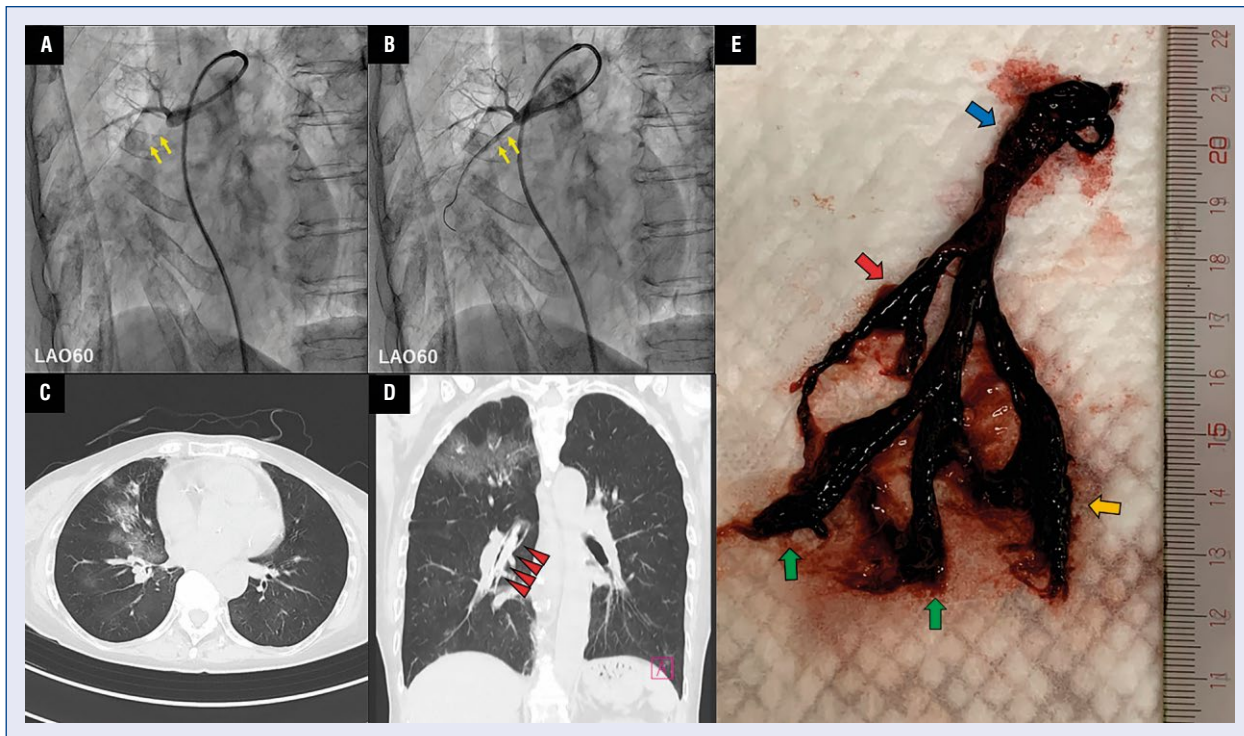


Figure 1. The process of balloon pulmonary angioplasty, computed tomography performed after balloon pulmonary angioplasty, and the expectorated blood clot; **A.** Pulmonary angiography showing chronic total occlusion in right A5 segment (yellow arrows); **B.** Revascularization of right A5 segment after balloon pulmonary angioplasty (yellow arrows); **C.** Computed tomography showing an infiltrative shadow in the right middle medial lobe; **D.** Computed tomography showing an infiltrative shadow in the right superior apical lobe and a space occupying lesion detected in inferior lobar bronchus (red arrowheads); **E.** Blood clot shaped like a bronchial tree, consisting of inferior lobar bronchus (blue arrow), anterior basal branch (red arrow), lateral basal branch (green arrows), and posterior basal branch (orange arrow).