

Chimney stent deployment to overcome an acute right coronary occlusion due to a small right coronary sinus during transcatheter aortic valve implantation procedure

Mario García Gómez¹, Sandra Santos Martínez¹, Ana Serrador Frutos,
Tania Rodríguez Gabella, Ignacio J. Amat Santos¹

Servicio de Cardiología, Instituto de Ciencias del Corazón (ICICOR), Hospital Clínico Universitario, CIBER de Enfermedades Cardiovasculares, Valladolid, Spain

An 84-year-old woman with degenerative aortic stenosis was admitted for planned transcatheter aortic valve replacement procedure. The baseline tomography showed the following measurements: aortic annulus (maximum, minimum, and mean diameters of 22.5, 17.8, and 20.2 mm, respectively, perimeter 64.8 mm, area 322 mm²), the Agatston score was 1300, sinuses of Valsalva (left 27.7 mm, right 23.8 mm, noncoronary 28.1 mm) (Fig. 1A). Likewise, an unusual takeoff of the right coronary artery (RCA) was encountered, without a clear definition within a small right coronary sinus (Fig. 1B); the height of left coronary ostia was normal (Fig. 1C). Based on previous measurements, a 23 mm Portico bioprosthesis was selected. After predilatation using an 18 mm true dilatation balloon, the patency of RCA was checked with the balloon inflated. Subsequently, the prosthesis was deployed and the patient started with signs of hemodynamic instability. Then, an RCA occlusion was found in a control

angiography (Fig. 1D). Therefore, it was decided to remove the prosthesis, reassess the RCA patency (Fig. 1E) and position an undeployed 4 × 30 mm Onyx stent at the RCA (Fig. 1F). Straightaway, the prosthesis was released and simultaneously the stent at the RCA was successfully deployed according to the “chimney stent” technique [1] (Fig. 1G). Finally, the proper position and expansion of the prosthesis, the absence of periprosthetic leak and the patency of the RCA were verified (Fig. 1H). Ultimately, the correct expansion of the stent was confirmed using intravascular ultrasound (Fig. 1I).

Conflict of interest: None declared

References

1. González-García A, Hernández-Matamoros H, Jurado-Román A, et al. Valve in valve procedure and left main stent: To deliver or not to deliver. *Cardiol J.* 2020; 27(1): 87–88, doi: [10.5603/CJ.2020.0018](https://doi.org/10.5603/CJ.2020.0018), indexed in Pubmed: [32103481](https://pubmed.ncbi.nlm.nih.gov/32103481/).

Address for correspondence: Ignacio J. Amat Santos, MD, PhD, FESC, Instituto de Ciencias del Corazón (ICICOR), Hospital Clínico Universitario de Valladolid, Ramón y Cajal 3, 47005, Valladolid, Spain, tel: +34 983 42 00 26, fax: +34 983 25 53 05, e-mail: ijamat@gmail.com

Received: 27.07.2020

Accepted: 29.07.2020

This article is available in open access under Creative Commons Attribution-Non-Commercial-No Derivatives 4.0 International (CC BY-NC-ND 4.0) license, allowing to download articles and share them with others as long as they credit the authors and the publisher, but without permission to change them in any way or use them commercially.

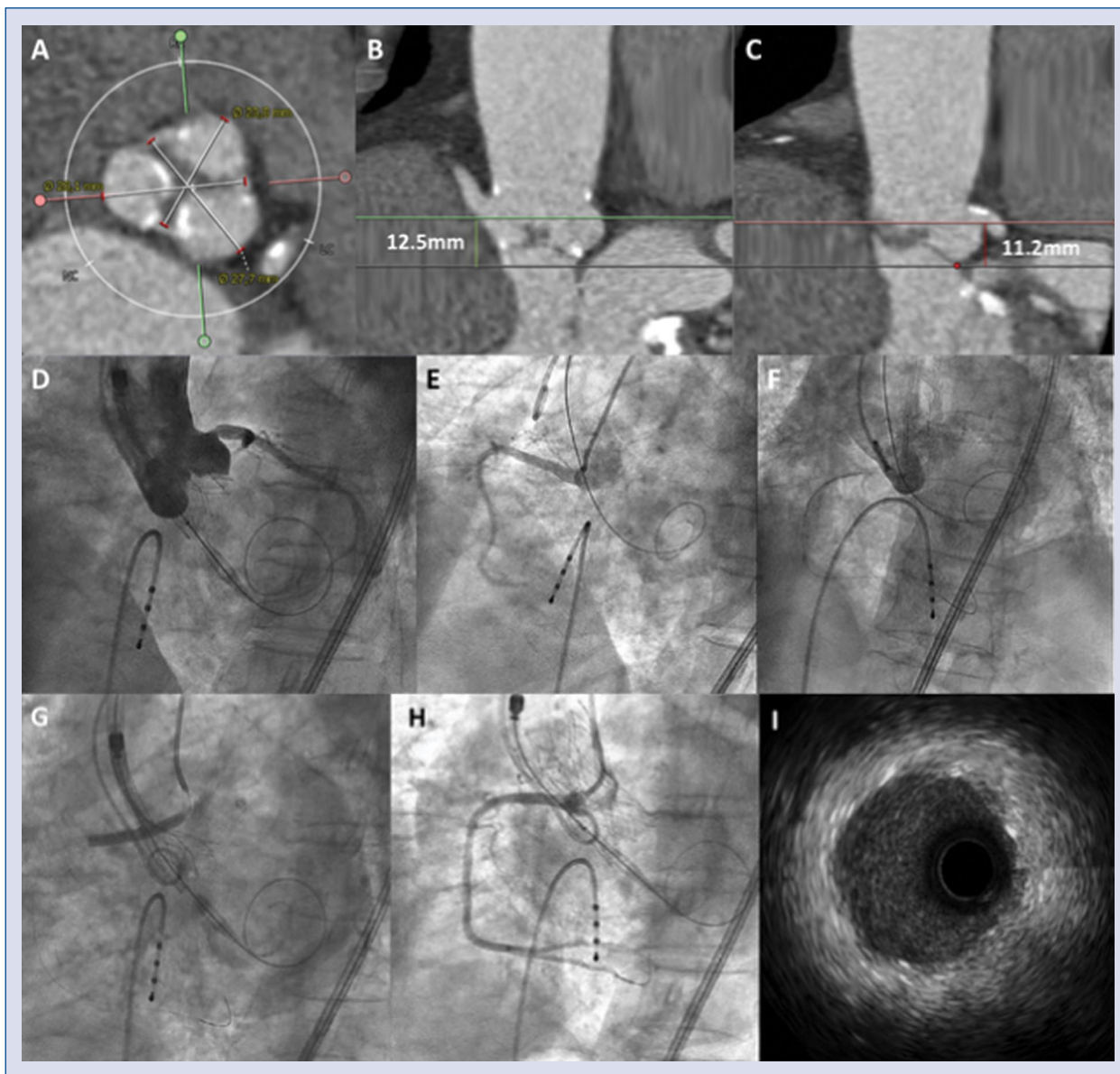


Figure 1. **A.** Tomographic image at the level of sinuses of Valsalva showing its measurements (left 27.7 mm, right 23.8 mm, noncoronary 28.1 mm); **B.** Tomographic image showing lack of a clear definition of the origin of the right coronary artery (RCA) within a small right coronary sinus; **C.** Tomographic image showing a normal origin of the left main coronary artery; **D.** Angiographic image performed after deployment of the prosthesis showing acute occlusion of the RCA; **E.** Angiographic image performed after the prosthesis was recaptured showing patency of the RCA; **F.** Angiographic image showing the guidewire and progress of a stent in the RCA; **G.** Angiographic image showing the release of the prosthesis and implantation of the stent with the “chimney stent” technique in the RCA; **H.** Final aortography showing the proper position and expansion of the prosthesis, absence of periprosthetic leak and patency of the RCA; **I.** Intracoronary imaging using intravascular ultrasound showing correct expansion of the stent implanted in the RCA.